



# Radiology of Anomalies of Pulmonary Veins

Mukund Dattatray Rahalkar<sup>1</sup> Anand M. Rahalkar<sup>1</sup>

<sup>1</sup>Department of Radiology, Sahyadri Hospitals, Deccan Gymkhana, Pune, Maharashtra, India

Indian J Radiol Imaging 2021;31:975–978.

Address for correspondence Dr. Mukund Dattatray Rahalkar, MD, FRCR, Department of Radiology, Sahyadri Hospitals, Plot No. 30-C, Erandvane, Karve Rd, Deccan Gymkhana, Pune, Maharashtra 411004, India (e-mail: mdrahalkar@hotmail.com).

## Abstract

A study of 43 cases of suspected congenital diseases of heart was performed in Sahyadri Hospital, Pune, over a period of 5 to 6 years with dual source computed tomography (CT) in adolescents as well as children. Only the images of anomalies of pulmonary veins are presented.

## Keywords

- congenital diseases
- inferior vena cava
- vertical vein

Compared with different radiological techniques, CT offers many advantages, as it can be undertaken even in neonates, yields more information than MR in a very little time, is better than 2D echo, when there is a small inter-costal window in some infants and is noninvasive. This study proved useful for further medical/surgical management.

## Introduction

MDCT (multidetector computed tomography) is simple and efficient method of imaging congenital anomalies of heart and great vessels. Compared with different radiological techniques, CT offers many advantages, as it can be undertaken even in neonates, yields more information than MR in a very little time, is better than 2D echo, when there is a small inter-costal window in some infants and is noninvasive.

## Material and Methods

A study of 43 cases of suspected congenital diseases of heart was performed in Sahyadri Hospital, Pune, over a period of 5 to 6 years with dual source CT in children as well as adults. Only the images of anomalies of pulmonary veins are presented.

## Introduction

A study of 43 cases of suspected congenital diseases of heart was performed in Sahyadri Hospital, Pune, over a period of 5 to 6 years with dual source CT in adolescents well as children. Only the images of anomalies of pulmonary veins are presented.

## Settings and Design

Selection of cases—the adolescents, infants, and children, of both sexes, from day 1 to 15 years and who had clinical signs of CVS and positive 2D echo findings were selected. The dose of contrast and radiation dose were kept as per the recommendations. MDCT was performed on Dual Source CT (Siemens Co Ltd.) which has a high isotropic resolution with 0.6 mm resulting into high quality orthogonal images.<sup>1,2</sup>

## Introduction

### Technique of MDCT Angiography

1. Age group: day 1 to 15 years.
2. Inclusion criteria:

Patients presenting to the hospital with congenital heart disease referred for cardiac MDCT were included.

3. Exclusion criteria:

- a. Patients coming for postoperative follow-up or complications.
- b. Patients coming with recurrent disease.
- c. Contrast enhanced CT was performed using (SIEMENS SOMATOM 64 dual source) MDCT scanner, under light sedation if required.

published online  
January 10, 2022

DOI <https://doi.org/10.1055/s-0041-1739377>.  
ISSN 0971-3026.

© 2022. Indian Radiological Association. All rights reserved.  
This is an open access article published by Thieme under the terms of the Creative Commons Attribution-NonDerivative-NonCommercial-License, permitting copying and reproduction so long as the original work is given appropriate credit. Contents may not be used for commercial purposes, or adapted, remixed, transformed or built upon. (<https://creativecommons.org/licenses/by-nc-nd/4.0/>)  
Thieme Medical and Scientific Publishers Pvt. Ltd., A-12, 2nd Floor, Sector 2, Noida-201301 UP, India

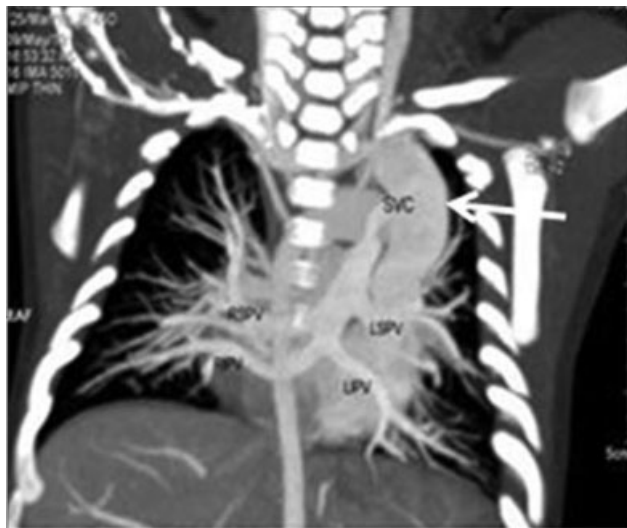- d. Sedation—chloral hydrate or IV sedation or general anesthesia (GA)—if SOS. Early cases were done without GA but in some cases, study had to be repeated. Hence GA was given in infants and con co-operative children.
- e. Injection of contrast—manual in neonates, 20 to 24 size needle, pressure injector in older children (1.5–4 mL/s). It was used to dilute contrast, so that a greater volume of 3 mL/kg could be used at a volume of 2 mL/kg.
- f. Pitch of 1.2, 0.75, or 1-mm slice thickness,  $64 \times 0.625$  mm collimation, gantry rotation 0.33 seconds.
- g. Field of view (FOV) for cardiac anomalies—from the level of sterna notch up to diaphragm.
- h. If major aortopulmonary collateral arteries (MAPCA) are suspected—from neck to inferior vena cava (IVC).
- i. Low radiation—80 to 120 mA, 80 to 120 KV.
- j. Scanning: (a) at the end for right heart and (b) bi-phasic for Lt heart: with bolus tracking.
- k. Multiplanar reconstruction (MPR), maximum intensity projection (MIP) (with varying slice thickness), axial, coronal, sagittal, or oblique recons, rotate images, volume rendering technique (VRT) images were used.
- l. In some cases, conventional pulmonary angiography was performed.

## Discussion

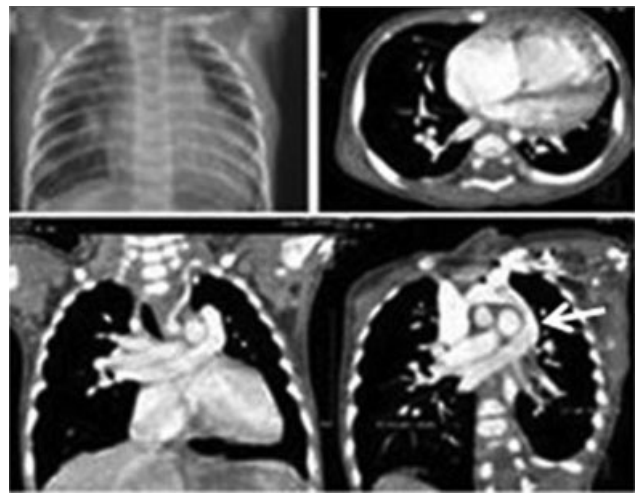
The anomalies of pulmonary veins can be grouped as follows:

### Type I: Supracardiac

Anomalous pulmonary veins terminate at the supracardiac level. Pulmonary veins converge to form a *left vertical vein*, which drains to either *brachiocephalic vein*, superior



**Fig. 1** A female neonate, presented with respiratory distress and cyanosis soon after birth. MPR image of MDCT shows supracardiac type of total anomalous return of pulmonary veins (white arrow). MDCT, multidetector computed tomography.

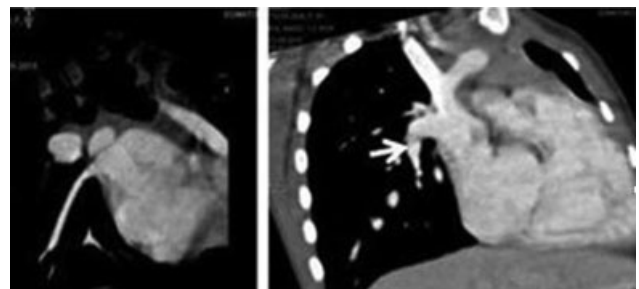


**Fig. 2** In this child CXR was normal. CT showed supra-cardiac type of TAPVR with all pulmonary veins on right draining into left SVC (vertical vein, marked by a white arrow), then into right brachiocephalic vein and normal SVC. TAPVR, total anomalous pulmonary venous return.

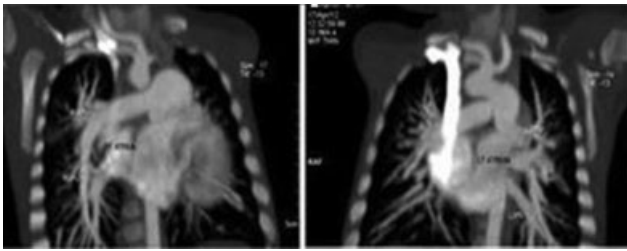
vena cava (SVC), or *azygos vein*. The supracardiac variant can classically depict a *snowman appearance* (*figure of eight heart* or *cottage loaf heart*) on a frontal chest radiograph. In this child MDCT showed the vertical vein even when Chest X-ray was normal (►Figs. 1 and 2).<sup>3</sup> This is a left to right shunt. This can be TAPVR (total anomalous pulmonary venous return) or PAPVR (partial anomalous pulmonary venous return).

### Type II: Cardiac

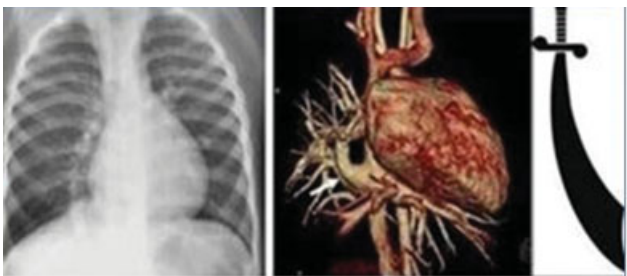
Pulmonary veins drain into the coronary sinus and then the right atrium or SVC (►Figs. 3, 4, and 5). A specific variant is a *meandering pulmonary vein* (►Fig. 6). It is an anomalous pulmonary vein, taking a circuitous route through the lung to enter into (in contrast to scimitar syndrome) the left atrium, rather than the IVC. Meandering pulmonary veins can occur on the left side or both sides and coincide with features of scimitar syndrome. This is a left to left shunt.



**Fig. 3** A 7-year-old female with ASD. MDCT shows a small tributary of RIPV opening into SVC—cardiac type (marked by arrows). MDCT, multidetector computed tomography.



**Fig. 4** A 5-month-old male child with poor growth and lethargy and cardiomegaly on chest X-ray. MPR images of MDCT show right superior and inferior pulmonary veins are draining into right atrium (marked by a thick arrow) and left superior and inferior pulmonary veins draining into left atrium (marked by a thin arrow). due to partial anomalous pulmonary venous return. MDCT, multidetector computed tomography.



**Fig. 5** CXR shows a curved density to the right of heart and increasing in size inferiorly, mimicking a Turkish sword with a curved blade that broadens inferiorly. MPR image of MDCT shows a scimitar vein to the right of RA and having a shape of a scimitar.

### Type III: Infracardiac

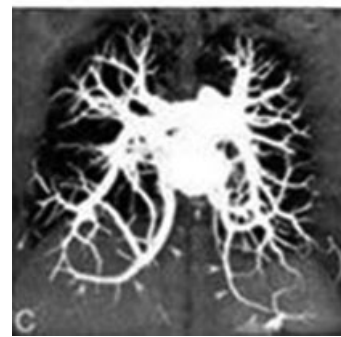
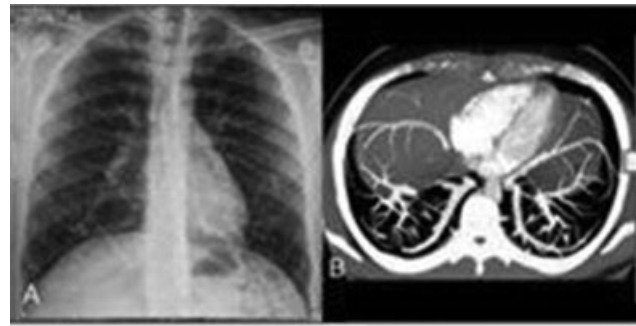TAPVR, in which all four pulmonary veins drain abnormally to the right atrium instead of the left atrium. This becomes a left to left shunt.

PAPVR is a congenital malformation in which pulmonary vein enters the systemic veins, e.g., in Scimitar syndrome. This is a left to right shunt. All pulmonary veins may drain into *hepatic veins, portal vein or IVC*. An inferior pulmonary vein may have a meandering course before ending in right atrium, IVC, or even portal vein (pulmonary veno-arterial or systemic venous shunt).

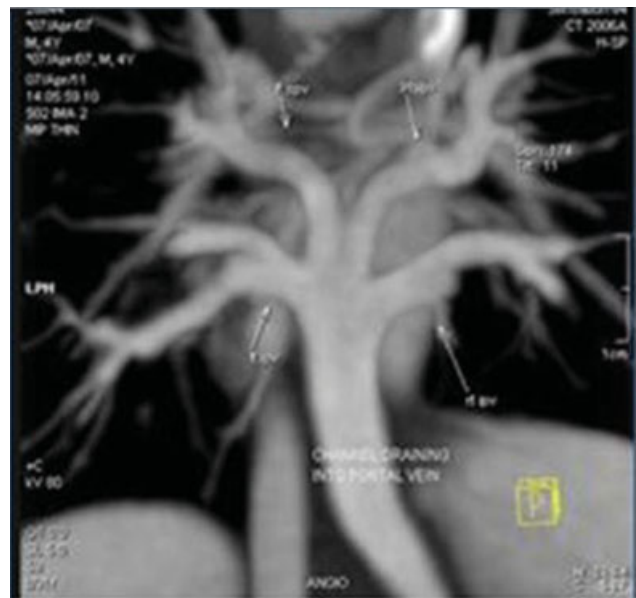Rarely the pulmonary veins may join behind the left atrium to form a common vertical descending vein, coursing anterior to the esophagus and passing through the diaphragm at the esophageal hiatus and then joining the portal system.

There have been a few studies in the literature describing the technique of CT of heart in pediatric patients (►Figs. 5, 7).

Type IV—miscellaneous anomalies—pulmonary AVM and pulmonary varix (►Figs. 6, 8, and 9).



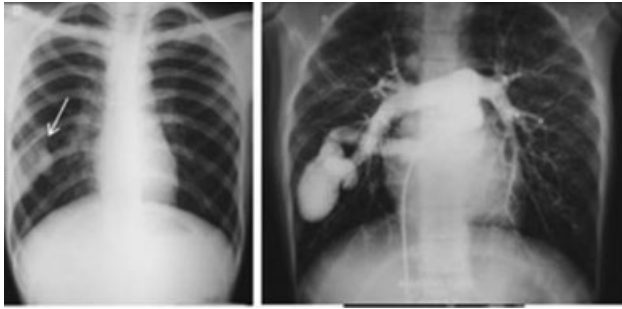
**Fig. 6** A male neonate, presented with respiratory distress and cyanosis soon after birth. MPR image of MDCT shows infracardiac type of total anomalous pulmonary of venous return into portal veins.



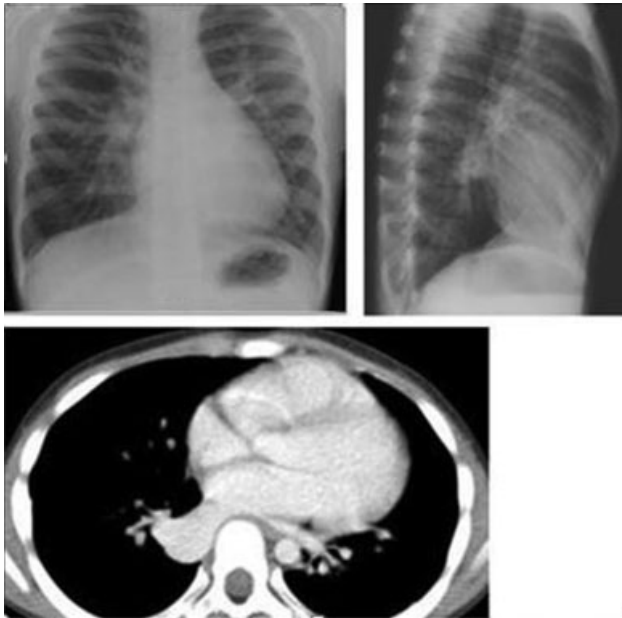
**Fig. 7** CXR showed a round and lobulated density in right lower zone. On close view vascular shadows were noted around it. Pulmonary angiography showed this to be AVM supplied by a pulmonary artery and drained by a pulmonary vein.

### Summary

A study of 43 suspected congenital diseases of heart supported by 2D echo was performed in children and adults. Only anomalies of pulmonary veins are



**Fig. 8** CXR in this adolescent showed a round density to the right and behind right hilum (arrow). A nodal mass or a vascular lesion was suspected. CT showed this to be a pulmonary venous angioma (arrowhead.). CT, computed tomography.



**Fig. 9** PA view of CXR shows bilateral anomalous curvilinear vessels in the lower pulmonary regions. MDCT with axial and coronal MIPs demonstrates bilateral pulmonary veins with anomalous routes in the lower pulmonary regions but draining normally into the left atrium. Coronal volume-rendering 3D reconstruction shows the anomalous veins and normal pulmonary arteries. PA, posteroanterior; 3D, three dimensional; MDCT, multidetector computed tomography.

presented. These were better accepted by clinicians. In most cases it tallied with 2D echo but in some cases it did not, as there can be difference in interpretation between the two cardiologists.

#### Source of Funding

None.

#### Conflict of Interest

None declared.

#### Acknowledgment

None.

#### References

- 1 Gilkeson RC, Ciancibello L, Zahka K. Pictorial essay. Multi-detector CT evaluation of congenital heart disease in pediatric and adult patients. *AJR Am J Roentgenol* 2003;180(04): 973–980
- 2 Lee T, Tsai IC, Fu YC, Jan SL, Wang CC, Chang Y. Using multi-detector-row CT in neonates with complex congenital heart disease to replace diagnostic cardiac catheterization for anatomical investigation: initial experiences. *Pediatr Radiol* 2006;36(12):1273–1282
- 3 Shi G, Zhu Z, Chen J, Ou Y, Hong H, Nie Z, et al. Total anomalous pulmonary venous connection: the current management strategies in a pediatric cohort of 768 patients. *Circulation* 2017;135:48–58