



Nasal mucoepidermoid carcinoma after radiotherapy: Case report

Carcinoma mucoepidermoide nasal pós-radioterapia em macroadenoma hipofisário recidivante: Relato de caso

Breno Nery¹ Victor Ribeiro Xavier Costa² Glaudir Donato Pinto Júnior³ Andrey Maia Silva Diniz³
Lucas Ribeiro de Moraes Freitas³ Davi Coutinho Marcelino Guerra Leone³
José Alencar de Sousa Segundo⁴ Mariana Junqueira Reis Enout⁵ Eduardo Quaggio¹
Renan Lopez Rivero⁶

¹ Department of Neurosurgery, São Francisco Hospital, Ribeirão Preto, SP, Brazil

² Faculdade de Ciências Médicas da Paraíba, João Pessoa, PB, Brazil

³ Centro de Ciências Médicas, Universidade Federal da Paraíba, João Pessoa, PB, Brazil

⁴ Department of Neurosurgery, Hospital Beneficência Portuguesa, Ribeirão Preto, SP, Brazil

⁵ Department of Otolaryngology, Universidade Federal de São Paulo, São Paulo, SP, Brazil

⁶ School of Medical Sciences, University of Bristol, Bristol, United Kingdom

Address for correspondence Lucas Ribeiro de Moraes Freitas, Fourth Year Medicine Student, Universidade Federal da Paraíba, Rua Engenheiro José Jaime Gomes Pessoa Filho – 58036-155–Bessa, João Pessoa, Paraíba, Brazil (e-mail: lucasribeirodemf@gmail.com).

Arq Bras Neurocir 2022;41(1):e85–e89.

Abstract

Introduction Mucoepidermoid carcinoma (MEC) is a tumor originated from the epithelium of the glandular excretory ducts and has highly variable biological potential. It is the most prevalent cancer of the salivary glands. The present report aims to describe a case of nasal mucoepidermoid carcinoma that developed after adjuvant radiotherapy (RT) treatment of a recurrent pituitary macroadenoma.

Case Report Male patient, 62 years old, presented with recurrent nasal epistaxis on the right, associated with intense pulsatile headache, visual analogical scale (VAS) 10/10, with improvement only with the use of opioids and morphine. After undergoing oncological screening and study by imaging exams, the presence of an expansive seal lesion with suprasellar extension was seen, involving the medial wall of the cavernous segment of the right carotid artery and the anterior cerebral artery, as well as the presence of a new expansive lesion in the right nasal cavity, with ethmoid bone invasion superiorly and medial orbit wall invasion laterally, compressing the ipsilateral optic nerve canal.

Discussion Sinonasal neoplasms represent a small portion of all malignancies of the upper aerodigestive tract, accounting for < 5% of these neoplasms. The development

Keywords

- ▶ mucoepidermoid carcinoma
- ▶ neurosurgery
- ▶ radiotherapy
- ▶ pituitary adenoma

received
March 8, 2021
accepted
June 16, 2021
published online
January 10, 2022

DOI <https://doi.org/10.1055/s-0041-1739269>.
ISSN 0103-5355.

© 2022. Sociedade Brasileira de Neurocirurgia. All rights reserved. This is an open access article published by Thieme under the terms of the Creative Commons Attribution-NonDerivative-NonCommercial-License, permitting copying and reproduction so long as the original work is given appropriate credit. Contents may not be used for commercial purposes, or adapted, remixed, transformed or built upon. (<https://creativecommons.org/licenses/by-nc-nd/4.0/>)
Thieme Revinter Publicações Ltda., Rua do Matoso 170, Rio de Janeiro, RJ, CEP 20270-135, Brazil

of MEC involves risk factors such as occupational issues, history of trauma and surgery involving the nasal area, and radiation exposure, as in previous RT.

Conclusion Mucoepidermoid carcinoma is an uncommon neoplasia and can be associated with RT treatment, as used in cases of recurrent pituitary macroadenoma. In general, surgical resection to obtain free margins of neoplastic tissue is the aimed treatment, seeking better prognosis.

Resumo

Introdução O carcinoma mucoepidermoide (CME) é um tumor que se origina do epitélio dos ductos excretores glandulares e possui potencial biológico altamente variável. Trata-se do câncer de maior prevalência nas glândulas salivares. O objetivo do presente relato é reportar um caso de carcinoma mucoepidermoide nasal que se desenvolveu após tratamento radioterápico adjuvante de um macroadenoma hipofisário recidivante.

Relato de caso Paciente do sexo masculino, 62 anos, apresentou epistaxe nasal recorrente à direita, associada a cefaleia pulsátil intensa, escala visual analógica (EVA) 10/10, com melhora unicamente com o uso de opioides e morfina. Após realização de screening oncológico e estudo por exames de imagem, foi visualizada presença de lesão expansiva selar com extensão suprasselar, envolvendo a parede medial do segmento cavernoso da artéria carótida direita e a artéria cerebral anterior, assim como presença de nova lesão expansiva em cavidade nasal à direita, com invasão do etmoide, superiormente, e da parede medial da órbita, lateralmente, exercendo compressão em canal do nervo óptico ipsilateral.

Discussão O desenvolvimento do CME, com base nos relatos deste tema, envolve fatores de risco como questões ocupacionais, antecedentes de traumas e cirurgias na área nasal e exposição radioativa, como em radioterapias prévias. De forma geral, a conduta de ressecção cirúrgica com a obtenção de margens livres de tecido neoplásico é o tratamento objetivado, visando melhores prognósticos.

Palavras-chave

- ▶ carcinoma mucoepidermoide
- ▶ neurocirurgia
- ▶ radioterapia
- ▶ neoplasias hipofisárias

Introduction

Mucoepidermoid carcinoma (MEC) is a tumor that originates from the epithelium of the glandular excretory ducts¹ with highly variable biological potential.² It is the most prevalent cancer in the salivary glands, especially in the parotids (between 60 and 70% of cases).³ Although there are reports of involvement in other epitheliums of the head and neck, there are still few cases linked to the nasal mucosa. A study by Calderón-Garcidueñas et al.,⁴ including 256 patients with nasosinusal malignancy, did not observe any case of mucoepidermoid carcinoma in this location.

Regarding the etiology, occupational factors related to contact with harmful substances to the nasal mucosa are predisposing to minor trauma and chronic irritation, which can lead to cancers of this characteristic.^{1,4} Furthermore, there are reports that mention previous nasal lesions and a history of surgical procedures⁵ in these areas as possible explanations for the development of these malignancies. In addition, radiation exposure is also identified as a risk factor⁴ in such cases.

The purpose of the present report is to describe a case of nasal MEC that had developed after an adjuvant radiotherapy (RT) treatment of a recurrent pituitary macroadenoma.^{6,7}

This is a rare case due to the circumstances surrounding the appearance of this tumor, as well as its anatomical region, which represents a tiny portion of the head and neck tumors. After a literature review, it was found that the topic in question is rarely discussed, and no similar reports to what is described in the present report were found.

Case Report

A 62-year-old male patient, in November 2019, sought a specialist after presenting with recurrent right-sided nasal epistaxis, associated with intense pulsatile headache, visual analogue scale (VAS) 10/10, with improvements only with the use of opioids and morphine. He initially resorted an otorhinolaryngology service, which performed a biopsy of a lesion visualized in the nasal cavity through nasofibroscopy and confirmed a malignant lesion whose etiology remained to be defined.

Because of the previous history of endonasal transsphenoidal surgery for resection of a recurrent pituitary macroadenoma in 2005 and 2006 in another health service, as well as local adjuvant RT in 2007 after the second surgery, tranexamic acid was prescribed in doses of 240 mg, every 8 hours, and the patient was referred to our care.

After oncological screening and study by computed tomography (CT) and magnetic resonance imaging (MRI) of the skull and the face with thin slices and contrast, an expansive sellar tumor with suprasellar extension was seen, involving the medial wall of the right carotid artery cavernous segment, as well as the cerebral anterior artery (without evident growth compared with annual serial imaging exams undergone by the patient).

In that same exam, it was also observed the presence of a new expansive lesion in the right nasal cavity, characterized by its invasive nature, homogeneous contrast highlight, with invasion of the ethmoid bone superiorly and of the medial orbit wall laterally, compressing ipsilaterally the optic nerve canal. The neoplasm was apparently contiguous with the sellar lesion in a study conducted in the region, with an apparent separation plan between the tumors. The preoperative work-up is described in ►Figs. 1–3 and 4.

Thus, a multidisciplinary team (neurosurgery, otorhinolaryngology, and head and neck surgery) decided on the initial attempt to resect the lesion in the right cavity by the transnasal route and, depending on the intraoperative freezing of the sellar lesion portion, resection of the sellar and

suprasellar portion would be indicated by the endonasal transsphenoidal route.

In the intraoperative period, a neoplasm of malignant behavior was found, infiltrating the medial wall of the orbit (papyraceous lamina) and the ethmoid bone superiorly, bleeding and friable (►Figs. 5 and 6), occupying the upper portion of the nasal cavity on the right. After total macroscopic resection of the tumor, freezing biopsy was performed on all margins of the lesion, confirming that they were free from malignant infiltration.

Regarding the freezing biopsy of the posterior portion of the lesion (sellar portion), a benign lesion that, in an anatomopathological study, confirmed a pituitary macroadenoma without signs of malignancy, became evident. Thus, after finding evidence of absence of malignancy at the posterior limit of the lesion, it was decided to conclude the surgery to not add morbidity to the case (sellar and suprasellar lesion without evidence of growth and without associated symptoms).

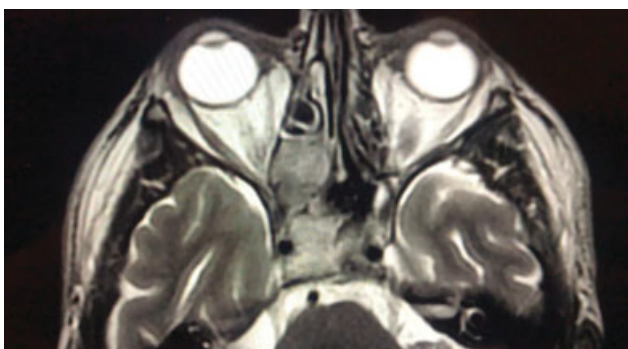

Fig. 1 T2-weighted MRI showing lesion in the right nasal cavity with infiltration of the medial orbital wall and ethmoid bone with evidence of a sellar lesion involving the right carotid artery.

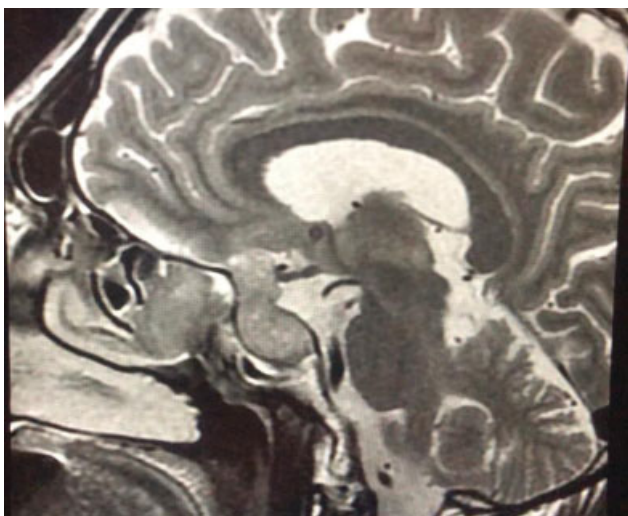


Fig. 2 T2-weighted sagittal MRI showing anterior lesion in the nasal cavity (carcinoma) and posterior lesion in the sellar / suprasellar region (adenoma).

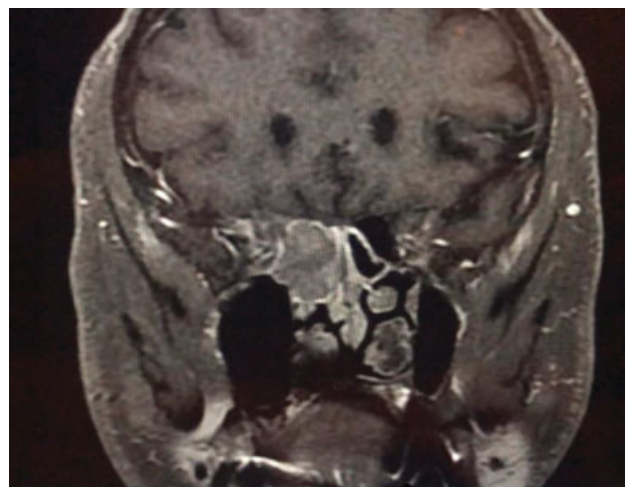


Fig. 3 T1-weighted MRI in the coronal section with gadolinium showing lesion in the nasal cavity.

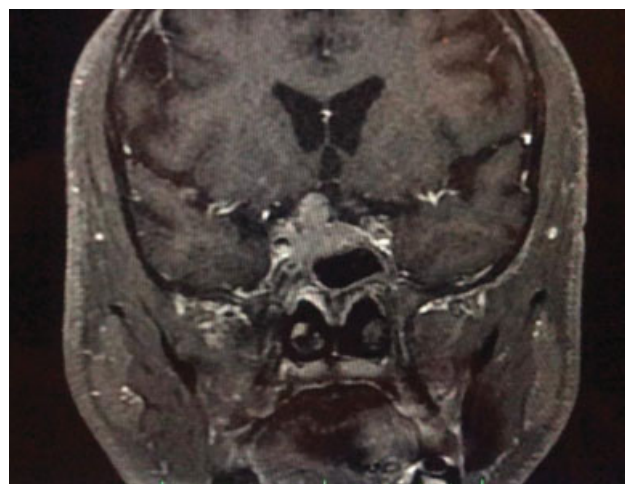


Fig. 4 T1-weighted MRI with contrast of the lesion in the sellar region with parasellar and suprasellar extension.

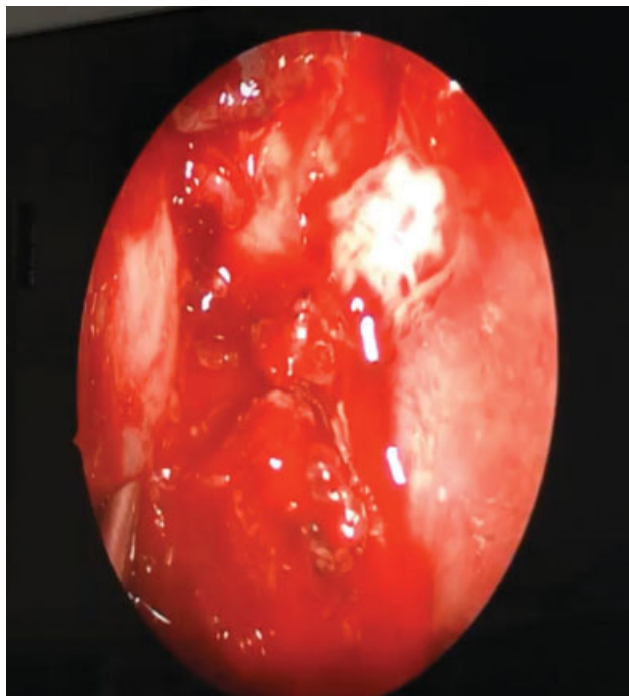

Fig. 5 Endoscopy showing lesion in the nasal cavity at the center with extension up to 6 hours. At 12 o'clock and at 2 o'clock, whitish, dura mater of the frontal lobe. At 9 AM, medial orbital wall. At 3 PM, nasal septum, posteriorly.

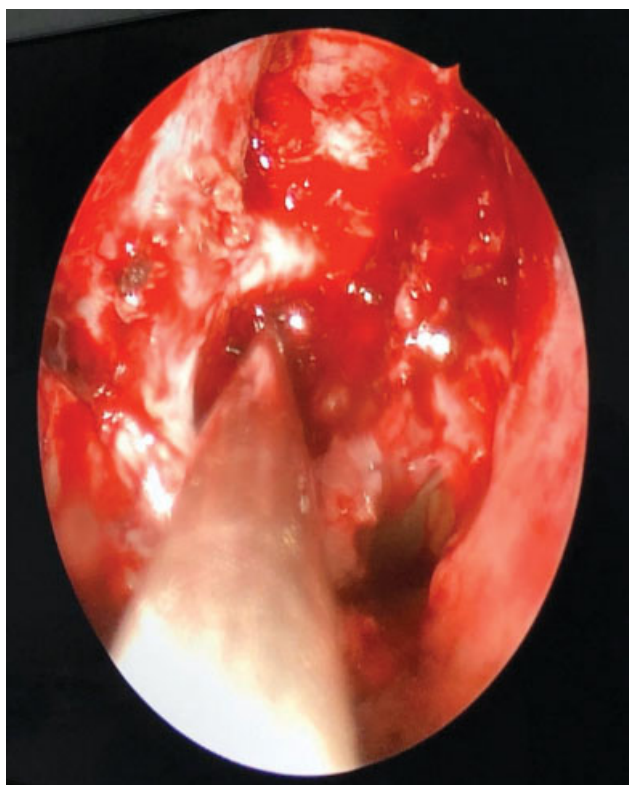

Fig. 6 Image after total resection of a lesion in the nasal cavity. Aspirator located in the optocarotid recess on the right.

The anatomopathological study of the nasal cavity lesion showed nasal MEC (►Fig. 7). After a day of hospitalization,

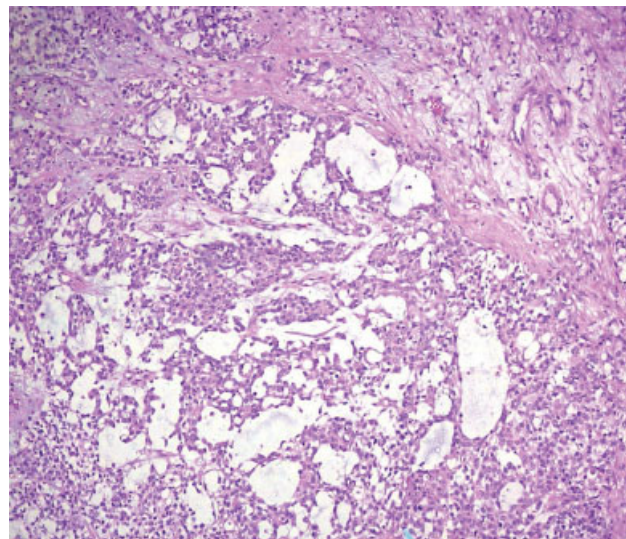


Fig. 7 Epithelial cells with atypia and mucoproducing areas. Hematoxylin and Eosin (H & E) $\times 100$.

the patient was discharged without any associated motor or sensory deficits and without evidence of nasal bleeding. He was referred to an oncology service for follow-up adjuvant therapy (radio and chemotherapy).

Discussion

Sinonasal neoplasms represent a small portion of all malignancies of the upper aerodigestive tract, accounting for < 5% of all these neoplasms.^{8,9} Mucoepidermoid carcinoma is the most common malignant tumor of the major and minor salivary glands, and it also has a broad spectrum of occurrence, which can be developed from the mucosa of the nasal cavity and sinuses to the trachea and lung.³ However, the vast majority of primary sinonasal malignancies are squamous cell carcinomas, while MEC represents < 0.1% of primary sinonasal neoplasms.¹⁰

Given the rarity of these tumors, when studying the existing literature in search of a correlation between MEC and pituitary adenomas, a scarcity of similar reports was observed and, when interpreting population database studies, there were limitations. The studies that include sinonasal tract MEC are grouped with data on sinonasal carcinomas or head and neck MEC,^{8,11} making it difficult to conclude about adjacent tumors and their treatment.

The development of MEC, based on reports on this topic, involves risk factors such as occupational issues,^{1,4} history of trauma and surgeries⁵ in the nasal area, and radioactive exposure, as in previous radiotherapies.^{1,4} Labor hazards include interactions with components that are harmful to the respiratory tract – such as sawdust, industrial toxins, chromium, nickel, formaldehyde, and pollutants, as well as substances related to the handling of leather, textiles, and clothing. In these questions related to work routines, there was no correlation with the history of this clinical case.

Regarding the other predisposing factors, the patient had a history of surgery by the sublabial transsphenoidal

approach on two occasions, as well as of RT treatment after his second operation. In this sense, the issue of the previous RT is highlighted in the literature. There even are links between the use of conservative RT fields in the treatment of neoplasms of the skull base and the development of new tumors, due to contiguity dissemination⁶ and, possibly, to the damage to healthy adjacent tissues. Thus, it is believed, based on the history of treatment of the sellar lesion by RT, that this conduct may have a relevant influence on the origin of MEC in the nasal septum of the patient.

Regarding therapeutic intervention in pituitary adenomas, except for prolactinomas, surgical resection is the recommended initial treatment, using the transsphenoidal approach.^{12,13} In these circumstances, in face of operations performed by excellent pituitary surgeons, reports indicate that the achieved remission in microadenomas had an index of 80 to 90%, while in macroadenomas the index was from 40 to 70%, with a 10 to 20% recurrence rate due to remaining tumors over the years.¹³

Concerning the possibility of RT, studies point to it as a treatment recommended in very specific situations; for example, when tumors cannot be safely dried out or hormonal levels are not controlled even after neurosurgical interventions and previous drug treatment.¹⁴

Another situation in which RT is shown in articles to be effective is in the case of adjuvant treatment of clinically nonfunctioning adenomas when tumor residues are identified on MRI.¹⁵

Conclusion

Mucoepidermoid carcinoma is an uncommon neoplasia and can be associated with RT treatment, as used in cases of patients with a recurrent pituitary macroadenoma.

It presents itself as a rare complication, which is evident from the lack of reports in the literature. The elements discussed allow to emphasize the need for attention to the specific circumstances in which RT is indicated as a therapeutic measure, considering the accuracy of the available technologies for irradiation, the viability of precise incidence at the tumor site, and the intrinsic aspects of the clinical history of the patient. In general, the conduct of surgical resection by a professional of excellence in surgery with the attainment of free margins of neoplastic tissue is the aimed treatment, in favor of better prognosis.

Conflict of Interests

The authors have no conflict of interests to declare.

References

- 1 Thomas GR, Regalado JJ, McClinton M. A rare case of mucoepidermoid carcinoma of the nasal cavity. *Ear Nose Throat J* 2002;81(08):519–522
- 2 Luís CM, Israel MS. Carcinoma Mucoepidermóide: Revisão de Literatura. *Rev Ciênc Méd Biol* 2007;6:219–222
- 3 Pires FR, Alves FA, Almeida OP, Kowalski LP. Carcinoma mucoepidermóide de cabeça e pescoço: estudo clínico patológico de 173 casos. *Rev Bras Otorrinolaringol* 2002;68(05):679–684
- 4 Calderón-Garcidueñas L, Delgado R, Calderón-Garcidueñas A, et al. Malignant neoplasms of the nasal cavity and paranasal sinuses: a series of 256 patients in Mexico City and Monterrey. Is air pollution the missing link? *Otolaryngol Head Neck Surg* 2000;122(04):499–508
- 5 Rosdeutscher JD, Burnette R. Nasal mucoepidermoid carcinoma. *Otolaryngol Head Neck Surg* 2003;129(03):291–292
- 6 Paulino AC, Marks JE, Leonetti JP. Postoperative irradiation of patients with malignant tumors of skull base. *Laryngoscope* 1996;106(07):880–883
- 7 Ghosh-Laskar S, Murthy V, Wadasadawala T, et al. Mucoepidermoid carcinoma of the parotid gland: factors affecting outcome. *Head Neck* 2011;33(04):497–503
- 8 Turner JH, Reh DD. Incidence and survival in patients with sinonasal cancer: a historical analysis of population-based data. *Head Neck* 2012;34(06):877–885
- 9 Dulguerov P, Jacobsen MS, Allal AS, Lehmann W, Calcaterra T. Nasal and paranasal sinus carcinoma: are we making progress? A series of 220 patients and a systematic review. *Cancer* 2001;92(12):3012–3029
- 10 Wolfish EB, Nelson BL, Thompson LD. Sinonasal tract mucoepidermoid carcinoma: a clinicopathologic and immunophenotypic study of 19 cases combined with a comprehensive review of the literature. *Head Neck Pathol* 2012;6(02):191–207
- 11 Thorup C, Sebbesen L, Danø H, et al. Carcinoma of the nasal cavity and paranasal sinuses in Denmark 1995–2004. *Acta Oncol* 2010;49(03):389–394
- 12 Swearingen B. Update on pituitary surgery. *J Clin Endocrinol Metab* 2012;97(04):1073–1081
- 13 Ammirati M, Wei L, Ciric I. Short-term outcome of endoscopic versus microscopic pituitary adenoma surgery: a systematic review and meta-analysis. *J Neurol Neurosurg Psychiatry* 2013;84(08):843–849
- 14 Chanson P, Raverot G, Castinetti F, Cortet-Rudelli C, Galland F, Salenave S French Endocrinology Society non-functioning pituitary adenoma work-group. Management of clinically non-functioning pituitary adenoma. *Ann Endocrinol (Paris)* 2015;76(03):239–247
- 15 Molitch ME. Diagnosis and Treatment of Pituitary Adenomas: A Review. *JAMA* 2017;317(05):516–524