




# Isolated Intramedullary Lumbar Spine Neurocysticercosis: A Rare Occurrence and Review of Literature

Anil Dhar, MCh<sup>1</sup> Sanjeev Dua, MCh<sup>1</sup> Hershdeep Singh, MCh<sup>1</sup> 

<sup>1</sup>Department of Neurosurgery, Max Super Speciality Hospital, New Delhi, India

Address for correspondence Hershdeep Singh, MCh, Department of Neurosurgery, Max Super Speciality Hospital, Max Patparganj, New Delhi, India (e-mail: Singh.hershey@gmail.com).

Surg J (NY) 2021;7:e327–e336.

## Abstract

### Keywords

- ▶ neurocysticercosis
- ▶ lumbar
- ▶ spine
- ▶ intramedullary
- ▶ rare

Neurocysticercosis (NCC) is the most common parasitic infection of the central nervous system. Spinal cysticercosis is a rather rare clinical occurrence. Intramedullary (IM) spinal NCC is rarer still. Furthermore, cases of IM-NCC at lumbar levels are few and far between. We present a case of a 35-year-old male patient who was diagnosed to have IM-NCC at L2-3 level and was managed surgically with no recurrence at 2 years of follow-up. A systematic literature review (1992–2020) highlights it to be only the third case reported with exclusive lumbar involvement

## Introduction

Neurocysticercosis (NCC) is the most common parasitic infection of the central nervous system (CNS), caused by the larval form of *Taenia solium*.<sup>1</sup> Pigs are the intermediate hosts, and humans are the definitive/intermediate hosts. Common risk factors are poor personal hygiene and unsanitary pig raising practices. Spinal cysticercosis is a rather rare clinical occurrence to come across with, as per current literature.<sup>2</sup> With an incidence of 0.7 to 3%,<sup>3</sup> it is common to find it in the combination of intracranial cysticercosis. Spinal NCC can be divided in extradural, intradural subarachnoid (leptomeningeal), and intramedullary (IM) (parenchymal) forms. More common are cases with the dorsal spine involvement than the other parts of the spinal cord.<sup>4</sup> IM presentation is usually the rarest. Here, we present a case of 35-year-old male patient who was diagnosed to have L2-L3 spinal IM-NCC and managed surgically without recurrence at 2 years of follow-up.

## Case Report

A 35-year-old man presented with the complaints of low back ache for 12 years, radiating to right leg for 4 months and

numbness extending to lateral side of the sole of right foot. On examination, there was a 30% sensory loss in right S1 dermatome as compared with contralateral limb, with no bladder bowel involvement. Patient had no motor deficit. Magnetic resonance imaging (MRI) of the lumbosacral spine was suggestive of IM cystic lesion at L2-3 hypointense on T1-weighted images and hyperintense on T2-weighted images. MRI brain did not reveal any abnormality. Lumbar puncture and serologic studies were not performed.

With the differential diagnosis of neoplastic lesion, the patient was taken up for posterior laminectomy. L2-3 laminectomy was done. A dural bulge was identified. On durotomy, the cord was found to be enlarged. Under microscopic guidance, posterior longitudinal myelotomy was done, the cysts were approached, and subtotal resection of cysts was done. Intraoperatively, three grayish white cysts were identified. Cysts were found to be adherent to the nerve roots causing their inflammation. As a result, one of the cysts could not be excised and was only decompressed. The remaining two cysts were completely excised. Histopathology revealed it to be NCC.

The patient improved postoperatively. Back pain was relieved, and there was significant reduction in radiating pain. He was started on albendazole (15 mg/kg body weight)

received  
June 7, 2021  
accepted after revision  
September 23, 2021

DOI <https://doi.org/10.1055/s-0041-1739118>.  
ISSN 2378-5128.

© 2021. The Author(s).

This is an open access article published by Thieme under the terms of the Creative Commons Attribution License, permitting unrestricted use, distribution, and reproduction so long as the original work is properly cited. (<https://creativecommons.org/licenses/by/4.0/>)  
Thieme Medical Publishers, Inc., 333 Seventh Avenue, 18th Floor, New York, NY 10001, USA

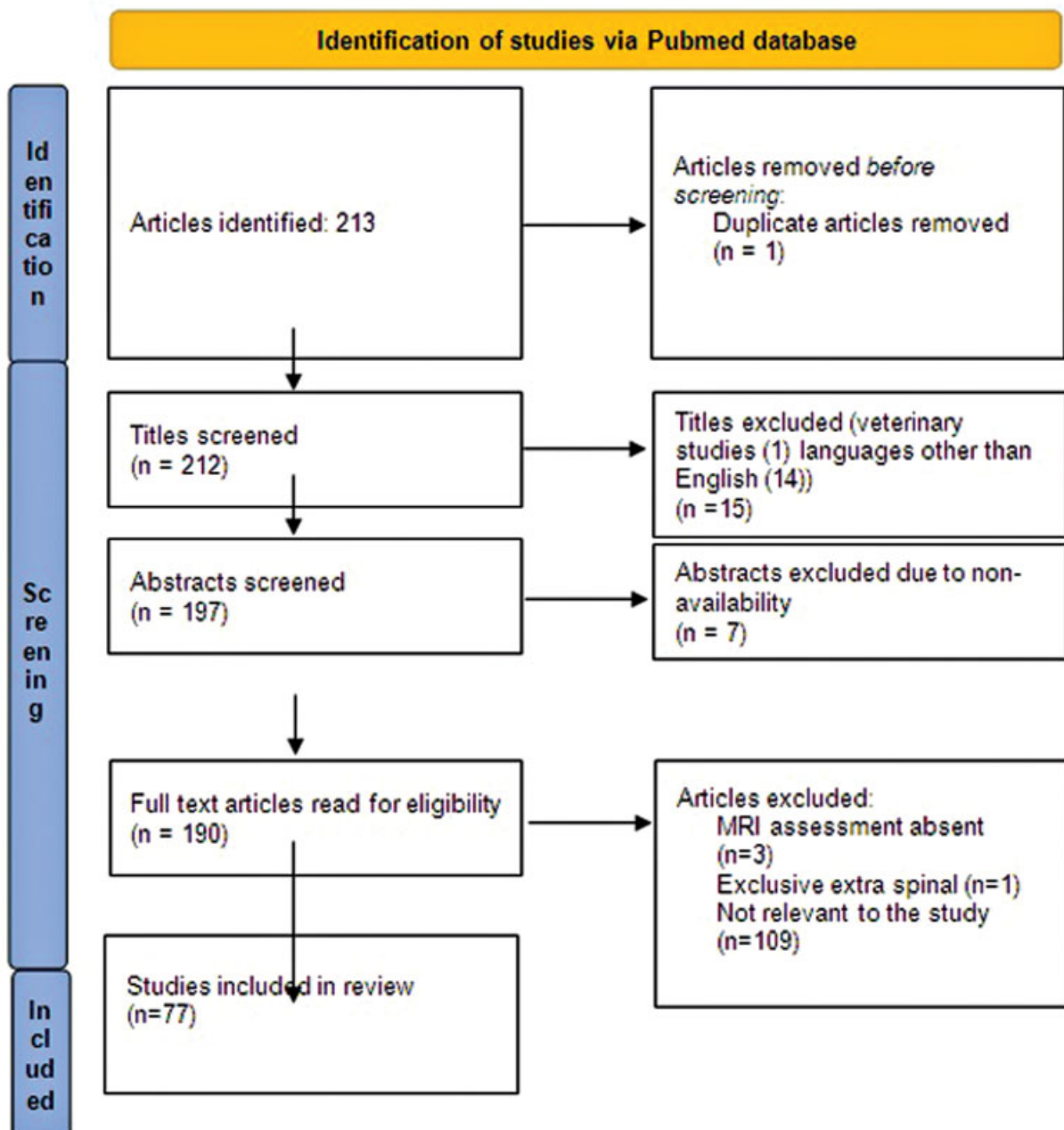
for 4 weeks and steroids for 2 weeks. The patient was discharged on the 4th post-operative day. He was followed-up biweekly for the first month. Thereafter, monthly follow-up was done for the next 2 months. MRI done at 6 months confirmed resolution of the cystic lesion. Thereafter, 6 monthly follow-up was done. Patient is symptom free and not on any medication at 2 years of follow-up.

## Discussion

Spinal NCC was originally reported by Rockitansky.<sup>4</sup> Its infrequent incidence (0.7–5.85%),<sup>5</sup> is attributed to the sieve effect provided by subarachnoid layer which filters cysticer-

ci, thus preventing them to pass. IM involvement occurs in less than one-fifth of the cases with intradural pathology.<sup>6</sup> The cysticerci migrate via hematogenous and ventriculoependymal pathways, thus afflicting mainly the dorsal segment of spinal cord primarily as a consequence of high-blood flow.<sup>5</sup>

In 2017, the Infectious Diseases Society of America (IDSA) and American Society of Tropical Medicine and Hygiene (ASTMH)<sup>7</sup> recommended clinical practice guidelines for the diagnosis and treatment of NCC. The said guidelines strongly advice prescription of corticosteroids in cases of spinal NCC with spinal cord dysfunction and also as an adjunct to antiparasitic treatment. As evidence to recommend one modality of



**Fig. 1** Preferred Reporting Items for Systematic Reviews and Meta-Analyses (PRISMA) flowchart for article selection process.

treatment (medical or surgical) over the other is lacking, authors suggested treatment be planned on case basis and surgical expertise available.

### Review of Literature and Results

The authors searched the PubMed database using keywords “Spinal neurocysticercosis” and “spinal cord neurocysticercosis.” A total of 213 results were obtained which included articles pertaining to both IM and extramedullary (EM) spinal cord NCC lesions.

Research papers reporting exclusive extra spinal involvement, no MRI assessment, published in non-English vernacular, and conducted in nonhuman subjects were excluded from this review (►Fig. 1). In the final analysis, 77 articles were shortlisted, encompassing both EM and IM involvement of spinal cord NCC (►Table 1). The cumulative number of cases was 147. These include 100 (EM), 46 (IM), and 1 (EM + IM).<sup>8</sup>

The literature review done by authors revealed only 33 articles (case reports and series) pertaining to the IM-NCC, the earliest being published in 1996. It translates to three articles being published from 1996–2000, followed by nine articles being in print from 2001–2010, and finally 21 articles from 2011–2020. Evidently, there has been increased scientific interest in spinal NCC. Increase in data availability will help to make more evidence-based treatment guidelines possible.

The review brings forth the fact that such cases were found not only in countries of Asia, Mexico but also in countries of the developed world. Eighteen such publications originate from India, followed by eight in the United States, three in Brazil, and one each in China, Guatemala and Spain. A 30-year long (1980–2010) combined research study was undertaken by clinicians from Mexico and India<sup>9</sup>. In most instances, the patients in the developed nations have a history of travel to the endemic region or a history of immigration.<sup>10–12</sup> It not only highlights the significance of cultural and environmental impact in this parasitic disease but also the need to consider this rare entity as a differential in such patients by clinicians in the developed world.

The patients with IM-NCC ranged in age from 5 to 70 years with an average of 31.06 years. Among the 46 patients of IM-NCC, 30 were male and 15 were female. In one of the study, this information was not provided.<sup>9</sup>

Spinal NCC has been reported to occur most commonly in the dorsal spine. The authors found majority ( $n = 32$ ) of the IM-NCC has been reported to be located in dorsal or dorso-lumbar levels, including two cases occurring at D11-L1 and D12-L1.<sup>13,14</sup> It is followed by cervical and cervicodorsal region ( $n = 12$ ). Highly sporadic occurrence has been reported in the lumbar region. Two of 46 cases of IM-NCC occur purely in the lumbar region.<sup>9,15</sup> Our patient is only the third reported case with pure lumbar involvement. With such an unusual occurrence, the diagnosis of the NCC was overlooked, and intraoperative findings were contrasting to our preoperative assessment, compelling us to share our experience.

**Table 1** Review of current literature

S.no	Authors	Country	Year	Age (yr)	Gender	Compartment	S.C level	Symptoms	Investigations	Mx	Remarks
1	Barrie et al <sup>27</sup>	USA	2020	44	F	IM	C5-6	M	M	S	Postop albendazole, steroid
2	Jobanputra et al <sup>28</sup>	USA	2020	44	F	IM	C5-C7	P, S	M	S	
3	Garg et al <sup>19</sup>	India	2020	51	F	EM	L3-5	P, S	M	C	Malignant (progresses from spine to cranium)
4	Torres-Corzo et al <sup>29</sup>	Mexico	2019	39	M	EM	L4-S1	P, M	M	S	P.O albendazole, Cranial +
				32	F	EM	L5-S1	P, S	M	S	P.O albendazole, Cranial +
				22	F	EM	L1-4	P, M	M	S	P.O albendazole, Cranial +
5	Lopez et al <sup>30</sup>	Ecuador	2019	58	M	EM	D4-6, D9-11	M, S, B	M	S	Multiple lesions
6	Li et al <sup>31</sup>	China	2019		F	EM	CMJ	H	M, IgG antibodies	S	HCP+
7	Shashidha <sup>32</sup>	India	2018	55	F	EM	L2-3	H, P	M, E, Eo	C	
8	Almeid <sup>33</sup>	Brazil	2018	10	M	IM	D 3-4	M	M	S	P.O albendazole
9	Mast <sup>2</sup>	India	2018	30	M	IM	D11	P, M	M, E, CSF antibody+	M	
10	Zhang et al <sup>34</sup>	China	2017	59	F	EM	L1-S1	P, B	M, E	S	Postop albendazole given
11	Datta et al <sup>26</sup>	India	2017	70	M	IM	D9-10	P, M, B	M	M	P.O albendazole, Operated twice

(Continued)

**Table 1 (Continued)**

S.no	Authors	Country	Year	Age (yr)	Gender	Compartment	S.C level	Symptoms	Investigations	Mx	Remarks
				23	M	IM	D10-11	P, M, B	M	S	
				24	M	IM	D5-6	P, S	M	O	Refused Rx
12	Yacoub et al <sup>8</sup>	USA	2017	49	M	EM	C4-D4, D6-D9	M, S	M	S	Cranial + P. O Albendazole
13	Muralidharan et al <sup>3</sup>	India	2017	56	M	EM	CMJ-C4	M, S, B	M, EITB	S	P.O albendazole
14	Pal et al <sup>35</sup>	India	2017	44	M	EM	D12-L3, D1-D9	P, M, S	M	S	Operated twice, P.O Albendazole given, mimics arachnoid cyst
15	Yadav et al <sup>36</sup>	India	2017	8	M	IM	C5-6	P, M	M	M	
16	Sharma <sup>37</sup>	India	2017	48	F	EM	L2-S2	P	M, Eo	S	P.O albendazole
17	Bansal et al <sup>6</sup>	India	2017	40	M	EM	L5-S1	P	M	S	P.O albendazole
18	Ranjan <sup>25</sup>	India	2017	6	M	IM	C4-6	P	M, S, ELISA +	M	
19	Hansberry et al <sup>38</sup>	USA	2016	49	M	EM	Post fossa to C2	M, S	M, WBA	S	Cranial +
20	Pant et al <sup>39</sup>	India	2016	60	M	IM	D11	M, R, B	M	S	P.O albendazole
				25	F	EM	D12-L2	P, M	M	S	P.O albendazole
21	Torous et al <sup>40</sup>	USA	2016	40	M	EM	L4-S1	P, M, S, B	M	S	
22	Valsangkar <sup>41</sup>	India	2015	40	M	IM	D10-12	P, M, B	M	S	P.O albendazole
23	Salazar Noguera <sup>42</sup>	Guatemala	2015	43	M	IM	C7-D1	M, S	M	S	
24	Hackius <sup>43</sup>	Switzerland	2015	46	F	EM	C1-C2, L4-5	H, N, D	M, Eo, E	M	
25	Cárdenas <sup>9</sup>	Mexico, India	2015	64	M	EM	CMJ	M		S	30 year study, 19 Mexican, 8 Indian
				57	M	EM	CMJ	M		C	
				60	F	EM	D1-D7	M, B		C	
				68	M	EM	D12-L3	M, B, R		S	
				55	F	EM	C3-4	M, B		O	
				26	F	EM	C7-D2	M, B, R		C	
				57	F	EM	D5-7	S		C	
				21	M	EM	D5-7	S		C	
				50	M	EM	L4-5	M, B, R		C	
				48	M	EM	L3-4	M		C	VP diversion
				29	F	EM	D4-8	M, B, R		S	
				52	M	EM	L3-5	S, B		S	
				45	F	EM	C1-5, C5-D8	M, B, R		C	
				64	F	EM	D1-2	S		S	
				32	M	EM	C2-3	S, Z		M	
				38	F	EM	L2-4	M		M	
				49	F	EM	CMC-C2	M		C	
				33	F	EM	C3-4, L2-4	S		S	

Table 1 (Continued)

S.no	Authors	Country	Year	Age (yr)	Gender	Compartment	S.C level	Symptoms	Investigations	Mx	Remarks
				62	F	EM	D5-8	M		M	
				50	F	EM	L4	M		C	
				16	F	IM	D11	M		S	
				35	F	EM	D12-L1	M		C	
				45	M	IM	CMJ	M		S	
				NA	NA	IM	D2	M		S	
				16	M	IM	L1	M, B		S	
				39	M	IM	D12	M		S	
				28	M	IM	D1-2	M		S	
26	Chaurasia et al <sup>21</sup>	India	2015		M	IM	D11	M, B, P	M, E (CSF, serum)	M	Brown-Sequard Syndrome
27	Wang et al <sup>44</sup>	USA	2015	45	M	EM	CMJ	H, P	M, serum antibody +	S	P.O albendazole
28	Ganesan <sup>45</sup>	India	2015	32	M	EM	L2-S1	P, B, S	M	S	
29	Han et al <sup>46</sup>	South Korea	2014	59	M	EM	L1-5	P, S, M	M	S	Multiple, P.O Albendazole
30	Vecchio et al <sup>47</sup>	Italy	2014	23	M	EM	L3-4	H, D	M, E	M	Cranial +
31	Amelot et al <sup>48</sup>	France	2014	48	M	EM	CVJ	M, H, PS	M	C (VP shunt)	Case series of 3 cases, 2 had spinal involvement
				25	F	EM	L4-S2	H, P, AMS	M	EVD, S	
32	Kim et al <sup>49</sup>	South Korea	2014	64	M	EM	D12-L1, L3-4	H, M, B	M	S (VP shunt+ laminectomy)	Hydrocephalus +, P.O albendazole
33	Qazi <sup>14</sup>	India	2014	19	M	IM	D11-L1	M, B	M	S	
34	Yoo et al <sup>50</sup>	South Korea	2014	42	M	EM	D11-S1	P	M, S.E	S	P.O albendazole
35	Lacoangeli <sup>51</sup>	Italy	2013	44	F	EM	L4-5	P, M, S, B	M	S	P.O albendazole
36	Chandramohan <sup>15</sup>	India	2013	15	M	IM	L1	M, B, R	M, Western blot	M	
37	Rice et al <sup>22</sup>	USA	2012	42	M	IM	D10-D11	M, S	M	S	Brown-Sequard Syndrome
38	De Deo et al <sup>52</sup>	Italy	2012	49	M	EM	D6-8, D10-11	H, M	M	S	Cranial +, P.O Albendazole
39	Callacondo et al <sup>53</sup>	Peru	2012	NA	NA	All 18 EM	LS M.C				Out of 55 patients with cranial NCC (intraparenchymal + basal cisterns) 18 pt had spinal involvement all EM
40	Jain et al <sup>16</sup>	India	2012	20	M	IM	C2	Z, M, B	M, IgG	M	Lost to follow up, Cranial+
41	Shin et al <sup>54</sup>	South Korea	2012	48	M	EM	D12-S1	M, B	M	S	P.O albendazole
42	Agale <sup>10</sup>	India	2012	38	M	IM	D10-11	M	M	S	P.O albendazole
43	Kapu et al <sup>55</sup>	India	2012	38	F	EM	D12-L1	P, M, S	M	S	P.O albendazole, Cysticercal abscess

(Continued)

**Table 1** (Continued)

S.no	Authors	Country	Year	Age (yr)	Gender	Compartment	S.C level	Symptoms	Investigations	Mx	Remarks
44	Bin Qi et al <sup>56</sup>	China	2011	40	F	IM	D4-5	M, B, R		S	P.O. anticysticercal agents
45	Seo et al <sup>57</sup>	South Korea	2011	59	M	EM	D12-L1, L4-5	H, V	M, Eo	S	P.O. albendazole, ocular symptoms, Visual defects persisted
46	Jongwutives <sup>58</sup>	USA	2011	59	F	EM	L1-4	M, S, B	M, S.E	S	
47	Park <sup>59</sup>	South Korea	2011	72	M	EM	L5-S1	P, M	M	S	Cranial + HCP+
48	Lambertucci <sup>60</sup>	Brazil	2011	23	M	IM	C3-5	P, M	M	S	P.O. albendazole
49	Azfar <sup>61</sup>	India	2011	10	F	IM	D2	M, S, B, R	CSF E	M	
50	Vij et al <sup>23</sup>	India	2011	20	M	IM	D10-11	P, M, S, B	M	S	Coexisting IM Schwannoma
51	Jang et al <sup>62</sup>	South Korea	2010	50	F	EM	L5-S1	P	M	S	Reoperated, P.O. Albendazole
52	Boulos et al <sup>63</sup>	Canada	2010	35	F	EM	CMJ	H, S	M	S	P.O. albendazole, Cranial leptomeningeal enhancement +
53	Lim et al <sup>64</sup>	South Korea	2010	42	M	EM	C2-L2	M	M	S (D3-5, L1-3)	H/O HCP +, P.O. Albendazole
54	Choi et al <sup>65</sup>	South Korea	2010	43	F	EM	L5-S1	P, M, S	M	S	P.O. Albendazole
55	Gonçalves et al <sup>66</sup>	USA	2010	62	M	IM	D11	P, M, S, B	M	S	
56	Chibber et al <sup>67</sup>	India	2009	38	F	IM	D5-6	P, M, B	M, E	M	
57	Shin <sup>68</sup>	South Korea	2009	45	M	EM	C1-L1	M, B	M, CSF ELISA	S	Cranial + HCP +, P.O. albendazole
58	Kasiwal et al <sup>69</sup>	India	2008	34	M	EM	C1-C2	P, M, H	M	S	P.O. albendazole
59	Izci et al <sup>12</sup>	USA	2008	70	M	IM	D11-L1	M, B, R	M	S	P.O. albendazole
60	Paterakis <sup>70</sup>	Greece	2007	60	M	EM	L3, L5-S1	P, M, B	M	S	P.O. Albendazole
61	Ahmad <sup>11</sup>	India	2007	8	F	IM	D8	P, M, B	M	S	P.O. albendazole
				35	F	IM	D1-2	P, M, S, B	M	S	P.O. albendazole
62	Guedes-Corrêa <sup>13</sup>	Brazil	2006	53	F	IM	D12-L1	P	M	S	
63	Delobel <sup>71</sup>	France	2004	45	M	EM	L3-4	P, M, B	M, E (CSF, serum)	S	HIV + cranial +, Brown Sequard syndrome, P.O. Albendazole
64	Torabi et al <sup>17</sup>	USA	2004	35	M	IM	C4, D4-9	H, P, M, B	M	M	Cranial + HCP +, Multilevel
65	Alsina et al <sup>18</sup>	USA	2002	38	M	EM	L2-3	M, B	M	C	Cranial +
				14	F	EM	C5-D1	M	M	S	
				36	M	EM	C5	M	M	S	Cranial +
				40	M	EM	FM	H	M	C	
				28	F	IM	C1	M	M	M	Cranial +
				80	M	EM	D4-5, D7-9	P	M	S	
66	Colli <sup>72</sup>	Brazil	2002	15	F	EM	D9	M	M	S	HCP+
				23	F	EM	D2-L1	P, M	M	S	HCP+
				24	F	EM	L2-5	P, S	M	S	
				36	F	EM	D11-L5	M, B, R	M	O	HCP+
				40	F	EM	C5-6	M, B	M	S	HCP+

Table 1 (Continued)

S.no	Authors	Country	Year	Age (yr)	Gender	Compartment	S.C level	Symptoms	Investigations	Mx	Remarks
				43	F	EM	L3-5	P, M	M	S	HCP+
				46	F	EM	D1-2	IM, S	M	S	HCP+
				46	F	EM	D9-L1	P, M, B, R	M	S	HCP+
				22	M	EM	D1	P	M	O	HCP+
				24	M	EM	D8-L2	P	M	S	
				24	M	EM	L3-4-S1	P, S, M	M	S	HCP+
				51	M	EM	C3-7		M	S	
67	Sheehan <sup>73</sup>	USA	2002	16	F	IM	C1-2	S	M	S	P.O praziquantel
68	Homans <sup>4</sup>	USA	2001	5	F	IM	D11-12	P, B	M, EITB	S	Cranial + operated twice
69	Mathuriya et al <sup>74</sup>	India	2001	28	M	IM	D1	P, M, S, B	M	S	
				55	M	IM	D1-2	P, M, S, B	M	S	
				50	M	IM	D11	P, M, S, B	M	S	
70	Gaur et al <sup>24</sup>	India	2000	22	F	IM	D8	M, S, B	CSF ELISA	M	
				27	F	IM	D5-6	M, S, B, R	CSF ELISA	M	
71	Ciftçi et al <sup>75</sup>	USA	1999	30	F	EM	C2-4	H, P	M	NA	HCP +
72	Garg et al <sup>76</sup>	India	1998	11	M	IM	D9	M, S, B	M, CSF, S, ELISA	M	Cranial+
				10	M	IM	D8	M, S, B	M	M	
73	Lau et al <sup>77</sup>	Hong Kong	1998	35	M	EM	D11-S1	M, S, HL	M	S	Cranial+
74	Davies <sup>78</sup>	Australia	1996	40	M	EM	C3-6	M, H, PS	M	S	Cranial + CSF diversion done multiple times, P.O Praziquantel
75	Corral <sup>20</sup>	Spain	1996	20	F	IM	C	Z, S, M	M, E	M	Cranial +
76	Isidoro-Lorens <sup>79</sup>	Spain	1993	30	F	EM + IM	C7-L2, IM at D	M	M	S	Operated twice, P.O Praziquantel
77	Bandres et al <sup>80</sup>	USA	1992	34	M	EM	C2, S1-L3	P	M	M	A case series of 5 patients, ventricular dilation +

Abbreviations: CSF, cerebrospinal fluid; CMJ, cervicomedullary junction; CVJ, craniovertebral junction; EM, extramedullary; EITB, enzyme-linked immunoelectrotransfer blot; ELISA, enzyme-linked immunosorbent assay; IgG, immunoglobulin G; IM, intramedullary; VP, ventriculoperitoneal.

Isolated spinal NCC is not a common occurrence. Concomitant cranial lesions are usually present. Of the 147 cases thus reported, 39 patients were known to have a concurrent or a history of cranial involvement. Six of the patients with IM-NCC had such a finding.<sup>4,16–20</sup>

Eighteen of patients with spinal NCC were reported to have hydrocephalus. Only one of these patients had IM-NCC,<sup>17</sup> who also had an evidence of cranial NCC.

The most common symptoms in patients with IM-NCC were those of motor involvement (40), followed by bladder involvement (26), back pain (21), sensory involvement (17), and bowel involvement (6). Two patients had complaints of seizures while headache was seen in one patient. These patients had cervical spine and brain lesions. Two patients (dorsal level IM-NCC) presented with Brown–Séguard syndrome (dorsal lesion).<sup>21,22</sup> One of the patients was found to have a coexisting schwannoma at D10–11 lesion.<sup>23</sup> Patients with pure lumbar involvement had motor symptoms and bladder bowel involvement.<sup>9,15</sup>

MRI is the investigation of choice for spinal NCC. Research papers with no MRI assessment were excluded from this review. MRI is the most essential to make diagnosis of spinal pathology, its level, and compartment involved. Other investigations may not always be helpful. In only 12 of the cases of IM-NCC, antibodies were detected by various techniques, including enzyme-linked immunosorbent assay (ELISA), Western blot, and enzyme-linked immunoelectrotransfer blot (EITB).<sup>24,25</sup>

In the review, it was concluded that surgery was the main modality of treatment ( $n=29$ ), while 16 patients were managed medically with anticysticercal agents (albendazole, praziquantel). One of the patients refused any treatment. Postop medical treatment was given to 12 patients. Redo surgery was required in two cases, both were in dorsal region.<sup>4,26</sup> There is no conclusive evidence pointing to advantage of one modality over the other. Case-based decisions are made, and patients are treated, according to clinical expertise available

## Conclusion

IM spinal NCC is a rare occurrence, even scarcer in the lumbar regions. To the author's knowledge, this case study is only the third to be reported in global data, thus adding up to the current literature.

Given its rarity, it is highly likely that such a diagnosis be ignored at the outset. It is prudent to consider this differential, especially in relation to patient history, travel history, personal history, and cultural background, to avoid any surprise. Advocated by clinical judgement, although medical treatment has been followed by similar results, surgical intervention remains the mainstay of treatment of spinal NCC. Although clinicians do prescribe steroids and antiparasitic agents in postop period, strong evidence-based guidelines are needed, necessitating more high-quality research. Steady follow-up is crucial to detect recurrence.

## Sources of Support

Nil.

## Note

The authors declare in consensus that the information provided is true to the best of their knowledge and currently this manuscript is not under submission in any other journal.

## Conflict of Interest

None declared.

## References

- Flisser A, Sarti E, Lightowers M, Schantz P. Neurocysticercosis: regional status, epidemiology, impact and control measures in the Americas. *Acta Trop* 2003;87(01):43–51
- Maste PS, Lokanath YK, Mahantshetti SS, Soumya S. Isolated intramedullary spinal cysticercosis: a case report with review of literature of a rare presentation. *Asian J Neurosurg* 2018;13(01):154–156
- Muralidharan V, Nair BR, Patel B, Rajshekhar V. Primary intradural extramedullary cervical spinal cysticercosis. *World Neurosurg* 2017;106:1052.e5–1052.e11
- Homans J, Khoo L, Chen T, Commins DL, Ahmed J, Kovacs A. Spinal intramedullary cysticercosis in a five-year-old child: case report and review of the literature. *Pediatr Infect Dis J* 2001;20(09):904–908
- Mohanty A, Das S, Kolluri VR, Das BS. Spinal extradural cysticercosis: a case report. *Spinal Cord* 1998;36(04):285–287
- Bansal S, Suri A, Sharma MC, Kakkar A. Isolated lumbar intradural extra medullary spinal cysticercosis simulating tarlov cyst. *Asian J Neurosurg* 2017;12(02):279–282
- White C, et al. Diagnosis and Treatment of Neurocysticercosis: 2017 Clinical Practice Guidelines by the Infectious Diseases Society of America (IDSA) and the American Society of Tropical Medicine and Hygiene (ASTMH). *Clin Infect Dis* 2018;66(08):49–75
- Yacoub HA, Goldstein I, El-Ghanem M, Sharer L, Souayah N. Spinal racemose cysticercosis: case report and review. *Hosp Pract (1995)* 2017;45(03):99–103
- Cárdenas G, Guevara-Silva E, Romero F, et al. Spinal *Taenia solium* cysticercosis in Mexican and Indian patients: a comparison of 30-year experience in two neurological referral centers and review of literature. *Eur Spine J* 2016;25(04):1073–1081
- Agale SV, Bhavsar S, Choudhury B, Manohar V. Isolated intramedullary spinal cord cysticercosis. *Asian J Neurosurg* 2012;7(02):90–92
- Ahmad FU, Sharma BS. Treatment of intramedullary spinal cysticercosis: report of 2 cases and review of literature. *Surg Neurol* 2007;67(01):74–77, discussion 77
- Izci Y, Moftakhar R, Salamat MS, Baskaya MK. Spinal intramedullary cysticercosis of the conus medullaris. *WMJ* 2008;107(01):37–39
- Guedes-Corrêa JF, Macedo RC, Vaitsman RP, Mattos JG, Agra JM. Intramedullary spinal cysticercosis simulating a conus medullaris tumor: case report. *Arq Neuropsiquiatr* 2006;64(01):149–152
- Qazi Z, Ojha BK, Chandra A, Singh SK, Srivastava C, Patil TB. Isolated intramedullary spinal cord cysticercosis. *J Neurosci Rural Pract* 2014;5(1, Suppl 1):S66–S68
- Chandramohan R, Kadiravan T, Swaminathan RP. Cysticercosis of the spinal cord. *QJM* 2013;106(03):279–280
- Jain N, Gutch M, Agrawal A, Khanna A. Quadriparalytic disseminated neurocysticercosis. *BMJ Case Rep* 2012;2012:bcr0820114613
- Torabi AM, Quiceno M, Mendelsohn DB, Powell CM. Multilevel intramedullary spinal neurocysticercosis with eosinophilic meningitis. *Arch Neurol* 2004;61(05):770–772



- 18 Alsina GA, Johnson JP, McBride DQ, Rhoten PR, Mehringer CM, Stokes JK. Spinal neurocysticercosis. *Neurosurg Focus* 2002;12(06):e8
- 19 Garg K, Vij V, Garg A, Singh M, Chandra PS. "Malignant" cranio-spinal neurocysticercosis: a rare case. *World Neurosurg* 2021; 146:95–102
- 20 Corral I, Quereda C, Moreno A, et al. Intramedullary cysticercosis cured with drug treatment. A case report. *Spine* 1996;21(19): 2284–2287
- 21 Chaurasia RN, Mishra VN, Jaiswal S. Spinal cysticercosis: an unusual presentation. *BMJ Case Rep* 2015;2015:bcr2014207966
- 22 Rice B, Perera P. Intramedullary spinal neurocysticercosis presenting as brown-sequard syndrome. *West J Emerg Med* 2012;13(05):434–436
- 23 Vij M, Jaiswal S, Jaiswal AK, Behari S. Coexisting intramedullary schwannoma with intramedullary cysticercosis: report of an unusual collision. *Indian J Pathol Microbiol* 2011;54(04):866–867
- 24 Gaur V, Gupta RK, Dev R, Kathuria MK, Husain M. MR imaging of intramedullary spinal cysticercosis: A report of two cases. *Clin Radiol* 2000;55(04):311–314
- 25 Ranjan R, Tulika, Chand S, Agnihotri A. Solitary intramedullary cervical cysticercosis without neurological deficit: a rare case report. *J Pediatr Neurosci* 2017;12(01):99–101
- 26 Datta SGS, Mehta R, Macha S, Tripathi S. Primary spinal intramedullary neurocysticercosis: a report of 3 cases. *World Neurosurg* 2017;105:1037.e1–1037.e7
- 27 Barrie U, Badejo O, Aoun SG, et al. Systematic review and meta-analysis of management strategies and outcomes in adult spinal neurocysticercosis. *World Neurosurg* 2020;138:504–511.e8
- 28 Jobanputra K, Raj K, Yu F, Agarwal A. Intramedullary neurocysticercosis mimicking cord tumor. *J Clin Imaging Sci* 2020;10:7
- 29 Torres-Corzo JG, Islas-Aguilar MA, Cervantes DS, Chalita-Williams JC. The role of flexible neuroendoscopy in spinal neurocysticercosis: technical note and report of 3 cases. *World Neurosurg* 2019; 130:77–83
- 30 Lopez S, Santillan F, Diaz JJ, Mogrovejo P. Spinal cord compression by multiple cysticercosis. *Surg Neurol Int* 2019;10:94
- 31 Li H, Sun J, Nan G. Nonspecific dizziness as an unusual presentation of neurocysticercosis: A case report. *Medicine (Baltimore)* 2019;98(30):e16647
- 32 Shashidhar A, Savardekar AR, Mundlamuri RC, et al. Chronic eosinophilic meningitis as a manifestation of isolated spinal neurocysticercosis: a rare case and a review of literature. *Neurol India* 2018;66(02):561–564
- 33 Almeida C Jr, de Almeida GC, Pentiado JAM Jr, Konichi Dias R. Teaching NeuroImages: Spinal intramedullary cysticercosis: The pseudotumoral form. *Neurology* 2018;91(12):e1202–e1203
- 34 Zhang S, Hu Y, Li Z, Zhao L, Wang Z. Lumbar spinal intradural neurocysticercosis: A case report. *Exp Ther Med* 2017;13(06): 3591–3593
- 35 Pal A, Biswas C, Ghosh TR, Deb P. A rare case of recurrence of primary spinal neurocysticercosis mimicking an arachnoid cyst. *Asian J Neurosurg* 2017;12(02):250–252
- 36 Yadav K, Garg D, Kaushik JS, Vaswani ND, Dubey R, Agarwal S. Intramedullary neurocysticercosis successfully treated with medical therapy. *Indian J Pediatr* 2017;84(09):725–726
- 37 Sharma R, Garg K, Agarwal D, et al. Isolated primary intradural extramedullary spinal cysticercosis. *Neurol India* 2017;65(04): 882–884
- 38 Hansberry DR, Agarwal N, Sharer LR, Goldstein IM. Minimally manipulative extraction of polycystic cervical neurocysticercosis. *Eur Spine J* 2017;26(Suppl 1):63–68
- 39 Pant I, Chaturvedi S, Singh G, Gupta S, Kumari R. Spinal cysticercosis: a report of two cases with review of literature. *J Craniovertebr Junction Spine* 2016;7(04):285–288
- 40 Torous VF, Darras N. A lumbar canal cystic mass lesion in a man with a history of chronic lower back pain. *Neuropathology* 2016; 36(01):103–106
- 41 Valsangkar SA, Kharosekar HU, Palande DA, Velho V. Isolated conus-epiconus neurocysticercosis. *Neurol India* 2015;63(01): 119–120
- 42 Salazar Noguera EM, Pineda Sic R, Escoto Solis F. Intramedullary spinal cord neurocysticercosis presenting as Brown-Séquard syndrome. *BMC Neurol* 2015;15:1
- 43 Hackius M, Pangalu A, Semmler A. Neurological picture. Isolated spinal neurocysticercosis. *J Neurol Neurosurg Psychiatry* 2015;86(02):234–235
- 44 Wang DD, Huang MC. Cervicomedullary neurocysticercosis causing obstructive hydrocephalus. *J Clin Neurosci* 2015;22(09): 1525–1528
- 45 Ganesan S, Acharya S, Kalra KL, Chahal R. Intradural Neurocysticercosis of Lumbar Spine: A Case Report. *Global Spine J* 2015;5(04):e1–e4
- 46 Han SB, Kwon HJ, Choi SW, et al. Lumbar intradural neurocysticercosis: a case report. *Korean J Spine* 2014;11(03):205–208
- 47 Vecchio RF, Pinzone MR, Nunnari G, Cacopardo B. Neurocysticercosis in a 23-year-old Chinese man. *Am J Case Rep* 2014;15:31–34
- 48 Amelot A, Faillot T. Hydrocephalus and neurocysticercosis: cases illustrative of three distinct mechanisms. *J Clin Neurol* 2014;10(04):363–366
- 49 Kim SW, Wang HS, Ju CI, Kim DM. Acute hydrocephalus caused by intraspinal neurocysticercosis: case report. *BMC Res Notes* 2014; 7:2
- 50 Yoo M, Lee CH, Kim KJ, Kim HJ. A case of intradural-extramedullary form of primary spinal cysticercosis misdiagnosed as an arachnoid cyst. *J Korean Neurosurg Soc* 2014;55(04):226–229
- 51 Jongwutiwes U, Yanagida T, Ito A, Kline SE. Isolated intradural-extramedullary spinal cysticercosis: a case report. *J Travel Med* 2011;18(04):284–287
- 52 De Feo D, Colombo B, Dalla Libera D, Martinelli V, Comi G. Subarachnoid neurocysticercosis with spinal involvement presented with headache. *Neurol Sci* 2013;34(08):1467–1469
- 53 Callacondo D, Garcia HH, Gonzales I, Escalante D, Nash TECysticercosis Working Group in Peru. High frequency of spinal involvement in patients with basal subarachnoid neurocysticercosis. *Neurology* 2012;78(18):1394–1400
- 54 Shin DA, Shin HC. A case of extensive spinal cysticercosis involving the whole spinal canal in a patient with a history of cerebral cysticercosis. *Yonsei Med J* 2009;50(04):582–584
- 55 Kapu R, Singh MK, Pande A, Vasudevan MC, Ramamurthi R. Intradural extramedullary cysticercal abscess of spine. *Trop Parasitol* 2012;2(02):131–134
- 56 Qi B, Ge P, Yang H, Bi C, Li Y. Spinal intramedullary cysticercosis: a case report and literature review. *Int J Med Sci* 2011;8(05): 420–423
- 57 Seo JH, Seo HJ, Kim SW, Shin H. Isolated spinal neurocysticercosis: unusual ocular presentation mimicking pseudotumor cerebri. *J Korean Neurosurg Soc* 2011;49(05):296–298
- 58 Iacoangeli M, Moriconi E, Gladi M, Scerrati M. Isolated cysticercosis of the cauda equina. *J Neurosci Rural Pract* 2013;4(1, Suppl 1):S117–S119
- 59 Lambertucci JR, Vale TC, Pereira ACG, et al. Teaching NeuroImages: isolated cervical spinal cord cysticercosis. *Neurology* 2011;77(23):e138
- 60 Park YS, Lee JK, Kim JH, Park KC. Cysticercosis of lumbar spine, mimicking spinal subarachnoid tumor. *Spine J* 2011;11(04):e1–e5
- 61 Azfar SF, Kirmani S, Badar F, Ahmad I. Isolated intramedullary spinal cysticercosis in a 10-year-old female showing dramatic response with albendazole. *J Pediatr Neurosci* 2011;6(01):52–54
- 62 Jang JW, Lee JK, Lee JH, Seo BR, Kim SH. Recurrent primary spinal subarachnoid neurocysticercosis. *Spine* 2010;35(05):E172–E175
- 63 Boulos MI, Aviv RI, Lee L. Spinal neurocysticercosis manifesting as recurrent aseptic meningitis. *Can J Neurol Sci* 2010;37(06): 878–880
- 64 Lim BC, Lee RS, Lim JS, Cho KY. A case of neurocysticercosis in entire spinal level. *J Korean Neurosurg Soc* 2010;48(04):371–374

- 65 Choi KB, Hwang BW, Choi WG, Lee SH. Herniated lumbar disc combined with spinal intradural extramedullary cysticercosis. *J Korean Neurosurg Soc* 2010;48(06):547–550
- 66 Gonçalves FG, Neves PO, Jovem CL, Caetano C, Maia LB. Chronic myelopathy associated to intramedullary cysticercosis. *Spine (Phila Pa 1976)* 2010;35:E159–62
- 67 Chhiber SS, Singh B, Bansal P, Pandita KK, Razdan S, Singh J. Intramedullary spinal cysticercosis cured with medical therapy: case report and review of literature. *Surg Neurol* 2009;72(06):765–768, discussion 768–769
- 68 Shin SH, Hwang BW, Lee SJ, Lee SH. Primary extensive spinal subarachnoid cysticercosis. *Spine* 2012;37(19):E1221–E1224
- 69 Kasliwal MK, Gupta DK, Suri V, Sharma BS, Garg A. Isolated spinal neurocysticercosis with clinical pleomorphism. *Turk Neurosurg* 2008;18(03):294–297
- 70 Paterakis KN, Kapsalaki E, Hadjigeorgiou GM, Barbanis S, Fezoulidis I, Kourtopoulos H. Primary spinal intradural extramedullary cysticercosis. *Surg Neurol* 2007;68(03):309–311, discussion 312
- 71 Delobel P, Signate A, El Guedj M, et al. Unusual form of neurocysticercosis associated with HIV infection. *Eur J Neurol* 2004;11(01):55–58
- 72 Colli BO, Valenca MM, Carlotti CG Jr, Machado HR, Assirati JA Jr. Spinal cord cysticercosis: Neurological aspects. *Neurosurg Focus* 2002;12:9
- 73 Sheehan JP, Sheehan JM, Lopes MB, Jane JA. Intramedullary cervical spine cysticercosis. *Acta Neurochir (Wien)* 2002;144(10):1061–1063
- 74 Mathuriya SN, Khosla VK, Vasishta RK, Tewari MK, Pathak A, Prabhakar S. Intramedullary cysticercosis: MRI diagnosis. *Neurol India* 2001;49(01):71–74
- 75 Ciftçi E, Diaz-Marchan PJ, Hayman LA. Intradural-extramedullary spinal cysticercosis: MR imaging findings. *Comput Med Imaging Graph* 1999;23(03):161–164
- 76 Garg RK, Nag D. Intramedullary spinal cysticercosis: response to albendazole: case reports and review of literature. *Spinal Cord* 1998;36(01):67–70
- 77 Lau KY, Roebuck DJ, Mok V, et al. MRI demonstration of subarachnoid neurocysticercosis simulating metastatic disease. *Neuroradiology* 1998;40(11):724–726
- 78 Davies MA, Turner J, Bentivoglio P. Spinal and basilar extraparenchymal neurocysticercosis. *J Clin Neurosci* 1996;3(02):174–177
- 79 Isidro-Llorens A, Dachs F, Vidal J, Sarrias M. Spinal cysticercosis. Case report and review. *Paraplegia* 1993;31(02):128–130
- 80 Bandres JC, White AC Jr, Samo T, Murphy EC, Harris RL. Extraparenchymal neurocysticercosis: report of five cases and review of management. *Clin Infect Dis* 1992;15(05):799–811