



# Management of Bleed from Percutaneous Portal Puncture Site (post-BRTO) by Trans-jugular-Trans-Hepatic Embolization

Raghav Seth<sup>1</sup> Arun Gupta<sup>1</sup> Ajit Yadav<sup>1</sup>

<sup>1</sup>Department of Interventional Radiology, Sir Ganga Ram Hospital, New Delhi, India

Address for correspondence Arun Gupta, Department of Interventional Radiology, Sir Ganga Ram Hospital, Old Rajinder Nagar, New Delhi 110060, India (e-mail: [irdrarungupta@gmail.com](mailto:irdrarungupta@gmail.com)).

J Clin Interv Radiol ISVIR 2022;6:220–222.

## Abstract

We report the case of an elderly male, who was a known case of chronic liver parenchymal disease. He presented with a history of melena for 2 weeks and upper-GI endoscopy revealed fundal varices. He was planned for BRTO. Along with BRTO, a percutaneous trans-hepatic puncture of a branch of the right portal vein was also performed for proper embolization of the varices. The trans-hepatic puncture-tract was embolized after the procedure. However, after 24 hours of the procedure, the patient developed hypotension and abdominal distension due to hemorrhage from the portal puncture site. Portal-venography was performed via the trans-jugular-trans-hepatic route to confirm the source of hemorrhage and embolization of the culprit portal venous branch was performed via the same route. The patient was stable after the procedure.

Various interventional procedures via the trans-jugular route have been routinely described in the literature, including trans-jugular liver biopsies, placement of TIPSS shunts and endovascular interventions for haemodialysis. However, the literature on trans-jugular embolization of portal vein is scarce. This case describes the unexpected clinical situation, in the form of bleeding from the portal puncture site, despite embolization of the trans-hepatic tract after BRTO. Finally, a creative solution was thought of and trans-jugular embolization of the portal vein was performed, which succeeded in terminating the ongoing bleeding from the portal vein.

## Keywords

- BRTO
- portal vein embolization

## Case History

A 55 year old male (known case of alcoholic chronic liver parenchymal disease) presented to the gastroenterology outpatient department with a history of melena for 14 days. Hemogram showed a hemoglobin level of 8.3 g/dL. The platelet count and other coagulation parameters including INR were in the normal range. Ultrasound abdo-

men did not reveal any ascites. Upper GI endoscopy was performed which revealed fundal varices (GOV type 2). On contrast-enhanced abdominal CT, the gastric varices showed three afferent veins with lieno-renal shunt as the only drainage pathway (Kiyosue inflow-type-2 and outflow-type-A). He was planned for trans-jugular BRTO as the varices were not suitable for endoscopic glue/coil embolization.

article published online  
November 12, 2021

DOI <https://doi.org/10.1055/s-0041-1739044>.  
ISSN 2457-0214.

© 2021. Indian Society of Vascular and Interventional Radiology. All rights reserved.

This is an open access article published by Thieme under the terms of the Creative Commons Attribution-NonDerivative-NonCommercial-License, permitting copying and reproduction so long as the original work is given appropriate credit. Contents may not be used for commercial purposes, or adapted, remixed, transformed or built upon. (<https://creativecommons.org/licenses/by-nc-nd/4.0/>)

Thieme Medical and Scientific Publishers Pvt. Ltd., A-12, 2nd Floor, Sector 2, Noida-201301 UP, India

## Procedure

After balloon occlusion of the lieno-renal shunt, a diagnostic venogram was performed. However, the gastric varices were not opacified with contrast. This was because the low-pressure afferent veins started functioning as the draining veins, resulting in the efflux of the contrast into the portal circulation. Hence, percutaneous trans-hepatic puncture of a branch of the right portal vein (BATO/antegrade access) had to be performed for coil-embolization of two of the three afferent veins. After the percutaneous trans-hepatic puncture was performed, pressure in the portal vein was measured (10–12 mm Hg). After the two afferent veins were embolized, balloon occlusion of the lieno-renal shunt was again performed and this time, the venogram showed opacification of the gastric varices. Subsequently, STS (sodium-tetradecyl-sulfate) foam (3:2:1 ratio of air: 3% STS: Lipiodol) was used for gastric variceal embolization via the trans-jugular route (BRTO). Finally, the percutaneous trans-hepatic puncture-tract was embolized using a coil (Nester Embolization coil 18–14–3, Cook Medical LLC, Bloomington, USA) and 50% glue mixed with lipiodol (–Fig. 1). After embolization, portal pressure was again measured, which was slightly higher (12–14 mm Hg) than the pre-embolization portal pressure, indicating that the embolization of the gastric varices was successful.

## Post-procedural Complication and Management

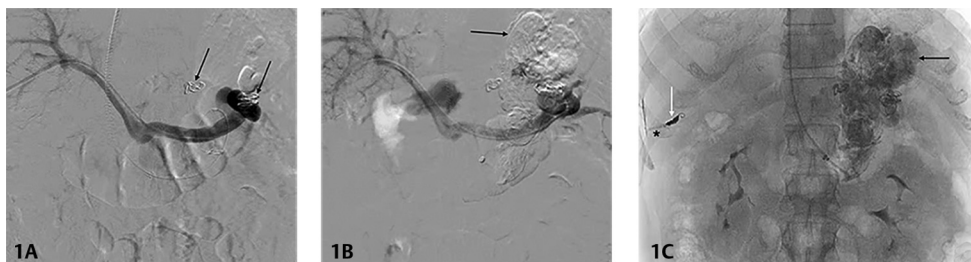
After 24 hours, the patient developed hypotension and abdominal distension with a hemoglobin level of 5.9 g/dl. Diagnostic aspiration confirmed hemoperitoneum. Bleeding from the portal-puncture site was considered as the most likely cause. CT scan of abdomen (NCCT, arterial and venous phase) was performed, which revealed complete obliteration of the gastric varices along with an ill-defined hyper-density around the liver (portal puncture site) on all phases, suggestive of hematoma. However, no progressive increase in attenuation could be observed in the hematoma to suggest active bleed from the suspected site on arterial as well as venous phases (due to coil artifacts). Hence, portal venography was performed via trans-jugular-trans-hepatic route, which revealed active contrast-extravasation from the portal venous branch

punctured during BRTO. Subsequently, embolization of that portal venous branch was performed using 50% glue mixed with lipiodol, via the same trans-jugular-trans-hepatic route (–Fig. 2). 5 units of packed red blood cells were transfused during and after the procedure. The patient was stable after the procedure and was discharged after 3 days with a hemoglobin level of 9.5 g/dl. There has been no recurrence of bleeding till date (24 months' post-procedure).

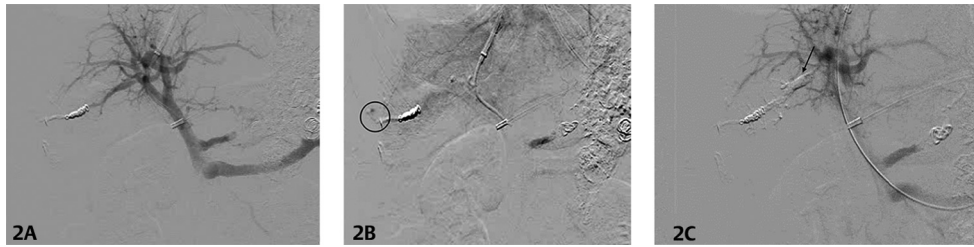## Discussion

In patients suffering from liver parenchymal disease, gastric varices account for ~10–30% of all the variceal hemorrhages.<sup>1</sup> Upper gastrointestinal endoscopy is the first-line diagnostic as well as therapeutic modality for variceal bleeding. However, when endoscopy fails to control the bleeding, BRTO (balloon-occluded retrograde trans-venous obliteration) can be performed. BRTO has been shown to be effective in controlling gastric variceal bleeding with low rebleed rates.<sup>2</sup> Conventional BRTO procedure is performed via the endovascular route (trans-femoral or trans-jugular) to occlude the outflow porto-systemic shunt, like a gastro-renal or a lieno-renal shunt. Percutaneous transhepatic obliteration or BATO (balloon-occluded anterograde trans-venous obliteration) is a technique which is used as an adjunct to the traditional BRTO, to gain access into the afferent veins supplying the gastric varices. Whenever percutaneous transhepatic route is used for BATO, it must be kept in mind that the percutaneous tract must be adequately embolized. However, if the tract is inadequately embolized (as in our case), it can result in bleeding from the puncture site. In addition, it must also be kept in mind that in cirrhotic patients with portal hypertension, the chances of bleeding from the puncture site are even more, due to the presence of ascitic fluid and deranged coagulation profile. Further, the risk of bleeding is also higher after BRTO, due to the increased portal pressure.

Bleeding from the percutaneous trans-hepatic portal venous puncture site has been described after various types of procedures including percutaneous transhepatic portal vein stenting, percutaneous transhepatic portal vein embolization, during BATO and after PTBD (percutaneous transhepatic biliary drainage).<sup>3–5</sup> In general, CTA is not sensitive in identifying the site of the portal venous bleeding, as the artifacts due to the implanted devices like a stent (in case of portal vein stenting)



**Fig. 1** (A). DSA image showing portal venogram after trans-hepatic coil-embolization of the two afferent veins (arrows) supplying the gastric varices. (B) DSA image showing sclerosant (STS foam) in the gastric varices (arrow) injected after balloon occlusion of the lieno-renal shunt via the trans-jugular route. (C). Post-procedure fluoroscopic image showing sclerosant cast in the gastric varices (black arrow) along with coil (white arrow) and glue cast (\*) in the portal vein puncture tract that was used for antegrade access.



**Fig. 2** (A) DSA image showing portal venogram (early phase) performed via the trans-jugular route. No contrast extravasation seen. (B). DSA image showing portal venogram (delayed phase) performed via the trans-jugular route. Active contrast extravasation (encircled) from the portal vein branch that was punctured for antegrade access. (C) DSA image taken post-procedure showing the glue cast (arrow) in the portal vein branch. No residual contrast leak seen.

will obscure the site of rebleed. Diagnostic angiography has to be ultimately performed to confirm the exact site of bleed. Once the culprit portal venous branch is identified, it must be embolized to stop the ongoing bleeding.

The possible solution to this peculiar complication depends on the site of injury. The management by coil embolization, glue embolization or using stent grafts are the definitive management strategies. Stent grafting is usually preferred if a large portal venous branch is involved. A critical point here is deciding the access route for management of the portal venous bleed. All the above mentioned procedures can be performed either via the percutaneous trans-hepatic route or via the trans-jugular-trans-hepatic route. Percutaneous trans-hepatic route can be used to puncture a branch of the portal vein (separate from the branch that has caused bleeding) and selectively cannulate the culprit vessel for its embolization. The literature on the use of the trans-jugular-trans-hepatic route for management of portal venous bleed is scarce. We suggest that this route should be considered for embolization of the involved portal venous branch as it is expected to be safer than the percutaneous route, especially in the presence of ascites and when the coagulation parameters are deranged. Further, the risk of bleeding from the trans-hepatic portal vein puncture site is especially higher after BRTO, due to the increased portal pressure, as a result of occlusion of one of the porto-systemic pathways (lieno-renal/gastro-renal shunt).

## Conclusion

This case describes the unexpected complication of bleeding from the percutaneous portal puncture site after BRTO,

despite embolization of the percutaneous tract. A solution in the form of trans-jugular-trans-hepatic embolization of the portal vein was considered, which succeeded in terminating the ongoing bleeding from the portal vein. This access route can be considered for embolization of portal venous bleed due to any cause. It is expected to be a safer alternative to the percutaneous route, especially in a few scenarios like post-BRTO, in the presence of ascites and deranged coagulation profile.

## Conflict of Interest

None declared.

## Acknowledgments

No acknowledgments.

## References

- 1 Wani ZA, Bhat RA, Bhadoria AS, Maiwall R, Choudhury A. Gastric varices: Classification, endoscopic and ultrasonographic management. *J Res Med Sci* 2015;20(12):1200–1207
- 2 Saad WEA. Balloon-occluded retrograde transvenous obliteration of gastric varices: concept, basic techniques, and outcomes. *Semin Intervent Radiol* 2012;29(02):118–128
- 3 Broutzos EN, Alexopoulou E, Koskinas I, Thanos L, Papatheasios MA, Kelekis DA. Intrahepatic portal vein bleeding during transjugular intrahepatic portosystemic shunt: treatment with stent-graft placement. *AJR Am J Roentgenol* 2000;174(01):132–134
- 4 Kodama Y, Shimizu T, Endo H, Miyamoto N, Miyasaka K. Complications of percutaneous transhepatic portal vein embolization. *J Vasc Interv Radiol* 2002;13(12):1233–1237
- 5 Quencer KB, Tadros AS, Marashi KB, et al. Bleeding after Percutaneous Transhepatic Biliary Drainage: Incidence, Causes and Treatments. *J Clin Med* 2018;7(05):94