



Induction Chemotherapy for Orbit Preservation in Sinonasal Squamous Cell Carcinoma

Gabriela Lilly¹ Mathew Geltzeiler¹

¹Department of Otolaryngology-Head and Neck Surgery, Oregon Health & Science University, Portland, Oregon, United States

J Neurol Surg Rep 2021;82:e36–e37.

Address for correspondence Gabriela Lilly, MD, Department of Otolaryngology-Head and Neck Surgery, Oregon Health & Science University, Portland 97239, Oregon, United States (e-mail: Bobarnac@ohsu.edu).

Abstract

Keywords

- ▶ sinonasal squamous cell carcinoma
- ▶ orbit preservation
- ▶ orbital exenteration
- ▶ induction chemotherapy

Sinonasal squamous cell carcinoma (SNSCC) is a rare and aggressive malignancy which often presents at an advanced stage. The gold-standard treatment includes negative-margin surgical resection plus adjuvant therapy. In cases of orbital invasion, surgery requires orbital exenteration which can carry significant morbidity and result in decreased quality of life. In selected patients, induction chemotherapy (IC) can allow for orbit preservation without compromising oncologic outcomes. The available literature will be briefly discussed.

Introduction

Sinonasal squamous cell carcinoma (SNSCC) is a rare and aggressive malignancy which often presents at an advanced stage. The gold-standard treatment includes negative-margin surgical resection plus adjuvant therapy.^{1,2} Due to the proximity to the orbit, surgery can carry significant morbidity and result in decreased quality of life.³ In selected patients, induction chemotherapy (IC) can allow for orbit preservation without compromising oncologic outcomes.^{1,2,4,5}

Case Report

A 72-year-old female presented with epiphora, diplopia, and a left ethmoid mass. Computed tomography (CT) and magnetic resonance imaging (MRI) noted erosion into the left orbit, with tumor immediately adjacent to the medial rectus, potentially violating the periorbita (▶ **Fig. 1A**, and **B**). Biopsy revealed poorly differentiated SCC, staged T4aNOMO. The patient underwent IC with two cycles of cisplatin and docetaxel. Interval imaging revealed significant tumor reduction with potential residual within the frontal bone (▶ **Fig. 1C** and **D**). Given concern for persistent disease, she

underwent orbit-sparing surgical resection followed by adjuvant intensity-modulated radiation therapy (IMRT) radiotherapy (60 Gy). She is doing well at 24-months post-treatment with preservation of orbital function and no evidence of recurrence.

Literature Review

SNSCC portends a poor prognosis which is further decreased by orbital invasion.^{1,4} Multimodality therapy has been associated with improved overall survival (OS).^{1,5} Superior outcomes have been found with resection with negative margins followed by adjuvant therapy as compared with primary chemoradiation (CRT).^{4,6–8}

The ability to achieve negative margins decreases with increasing tumor stage.¹ In the case of orbital invasion, when the periorbita is violated, negative margins cannot be confidently achieved without orbital exenteration. Exenteration is a disfiguring operation which can yield significant body image concerns and decreased psychosocial outcomes.³ Thus, treatment paradigms have evolved to attempt organ preservation.

received

April 26, 2021

accepted after revision

July 13, 2021

DOI <https://doi.org/>

10.1055/s-0041-1736160.

ISSN 2193-6358.

© 2021. The Author(s).

This is an open access article published by Thieme under the terms of the Creative Commons Attribution-NonDerivative-NonCommercial-License, permitting copying and reproduction so long as the original work is given appropriate credit. Contents may not be used for commercial purposes, or adapted, remixed, transformed or built upon. (<https://creativecommons.org/licenses/by-nc-nd/4.0/>)

Georg Thieme Verlag KG, Rüdigerstraße 14, 70469 Stuttgart, Germany

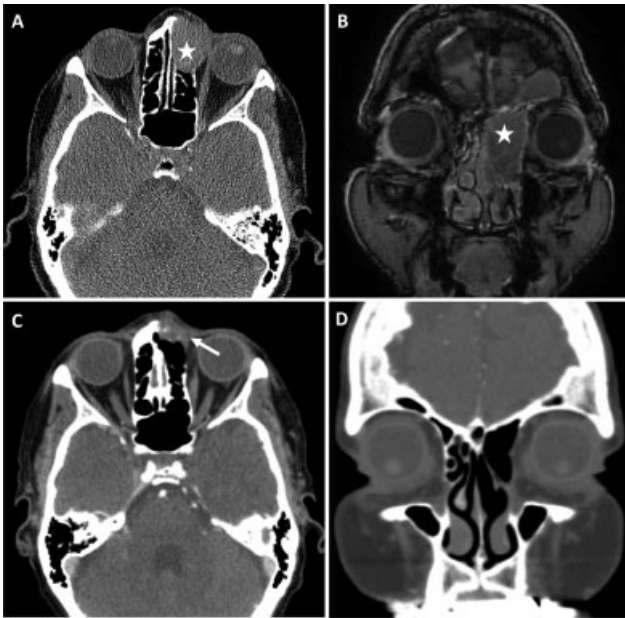


Fig. 1 Pre-induction chemotherapy CT (A) and MRI (B) images of a left ethmoid SNSCC (star) which is seen in close proximity to the medial rectus muscle with no clear plane between tumor and periorbita. This would historically require an orbital exenteration to ensure negative margins. Post-induction chemotherapy CT images (C, D) in the same patient show a significant reduction in tumor volume, with no evidence of persistent tumor near the lamina papyracea (D). There is apparent persistent disease within the frontal sinus (C, arrow), for which orbit-sparing surgical resection was undertaken.

IC has shown significant promise. In a study of the National Cancer Database, Farrell et al found similar 60-month OS in patients treated with IC followed by surgery or CRT as compared with primary surgery and adjuvant therapy.¹ Khoury et al, in a meta-analysis, reported an 83.3% rate of orbital preservation following IC. There was no change in OS, and orbit function was largely preserved.⁵

IC may also have a prognostic role. Hanna et al found that tumor response to IC was predictive of OS. In particular, the 2-year survival for patients with at least a partial response was significantly higher than that of patients whose disease progressed (77 vs. 36%).² Similarly Turri-Zanoni et al found a 5-year OS of 93.8% in IC responders versus 17.8% in non-responders.⁴ Treatment response was used to direct additional therapy in both series, with definitive CRT used

successfully in complete responders and orbit-sparing surgery used successfully in partial responders.^{2,4}

Conclusion

Surgical excision plus adjuvant therapy is the gold-standard treatment of SNSCC. IC may allow for organ preservation when achieving negative margins would require orbital exenteration. Response to IC can be prognostic and guide additional therapy. Specifically, orbit-sparing surgery can be considered in patients who partially respond, without compromising risk of disease-specific mortality. When a complete response is achieved, consolidation CRT is also a viable option.

Conflict of Interest

None declared.

References

- Farrell NF, Mace JC, Detwiller KY, et al. Predictors of survival outcomes in sinonasal squamous cell carcinoma: an analysis of the National Cancer Database. *Int Forum Allergy Rhinol* 2021;11(06):1001–1011
- Hanna EY, Cardenas AD, DeMonte F, et al. Induction chemotherapy for advanced squamous cell carcinoma of the paranasal sinuses. *Arch Otolaryngol Head Neck Surg* 2011;137(01):78–81
- Fingeret MC, Yuan Y, Urbauer D, Weston J, Nipomnick S, Weber R. The nature and extent of body image concerns among surgically treated patients with head and neck cancer. *Psychooncology* 2012;21(08):836–844
- Turri-Zanoni M, Lambertoni A, Margherini S, et al. Multidisciplinary treatment algorithm for the management of sinonasal cancers with orbital invasion: A retrospective study. *Head Neck* 2019;41(08):2777–2788
- Khoury T, Jang D, Carrau R, Ready N, Barak I, Hachem RA. Role of induction chemotherapy in sinonasal malignancies: a systematic review. *Int Forum Allergy Rhinol* 2019;9(02):212–219
- Choi JJ, Kim DW, Kim DY, Lee CH, Rhee CS. Predictive markers for neoadjuvant chemotherapy in advanced squamous cell carcinoma of maxillary sinus: preliminary report. *Acta Otolaryngol* 2013;133(03):291–296
- Lisan Q, Kolb F, Temam S, Tao Y, Janot F, Moya-Plana A. Management of orbital invasion in sinonasal malignancies. *Head Neck* 2016;38(11):1650–1656
- Cracchiolo JR, Patel K, Migliacci JC, et al. Factors associated with a primary surgical approach for sinonasal squamous cell carcinoma. *J Surg Oncol* 2018;117(04):756–764