



# Sinus of Valsalva Rupture or VSD Shunt: Mystery Solved by Cardiac CT

Keyur Vora<sup>1</sup>  Uday Surana<sup>2</sup> Alok Ranjan<sup>3</sup>

<sup>1</sup>Department of Cardiac Imaging, Kiran Multispecialty Hospital & Research Center, Surat, Gujarat, India

<sup>2</sup>Department of Radiology, Kiran Multispecialty Hospital & Research Center, Surat, Gujarat, India

<sup>3</sup>Department of Cardiology, Kiran Multispecialty Hospital & Research Center, Surat, Gujarat, India

Address for correspondence Keyur Vora, MD, FACC, FSCCT, Department of Cardiac Imaging, Kiran Multispecialty Hospital & Research Center, Surat, Gujarat 395009, India (e-mail: drkeyurvora@gmail.com).

Indian J Radiol Imaging 2021;31:748–750.

## Abstract

### Keywords

- ▶ cardiac CT
- ▶ sinus of Valsalva aneurysm
- ▶ surgical plan
- ▶ ventricular septal defect

Unruptured aneurysm of sinus of Valsalva is an asymptomatic pathology and diagnosed incidentally. This extremely rare anomaly can be associated with other congenital cardiac anomalies which can make the diagnosis and prognosis even more complex. We are reporting a case of a 12-year-old boy with progressive dyspnea and episodes of syncope. Multimodality imaging confirmed the diagnosis and paved the way for appropriate surgical treatment options.

## Introduction

Sinus of Valsalva (SoV) aneurysms are extremely rare cardiac anomalies that may be acquired or congenital. The congenital aneurysm is more common and is most often caused by weakness at the juncture of the aortic media and the annulus fibrosus.<sup>1</sup> Aneurysms may originate in the right coronary sinus (65–85%), the noncoronary sinus (10–30%), and rarely the left coronary sinus (1–5%).<sup>2</sup> Although aneurysms usually remain asymptomatic, rupture can complicate the pathophysiology very rapidly. Ruptured SoV aneurysms are frequently associated with perimembranous ventricular septal defects (VSDs).<sup>3</sup> We report herein a patient with an unruptured right SoV with subpulmonic location of small VSD with curved jet around aneurysm.

## Case Report

A 12-year-old boy with body mass index 20.6 kg/m<sup>2</sup> was presented to the outpatient department with symptoms of

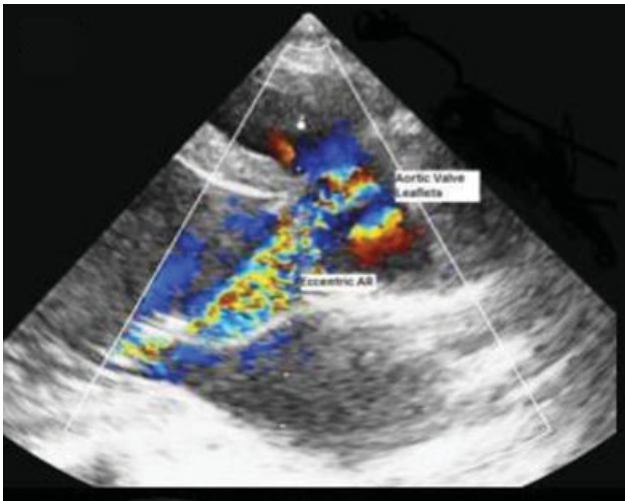
fatigue, substernal chest pressure, palpitations, and near syncope episodes three times on different days for the past 2 months. He had a history of cardiac murmur since birth and was diagnosed at that time with a small VSD by transthoracic echocardiography (TTE) with no further clinical follow-up.

An electrocardiogram showed sinus tachycardia at a rate of 110 bpm and met the voltage criteria for incomplete right bundle branch block. Chest radiography revealed a normal cardiac silhouette with mild congestion of the pulmonary vasculature.

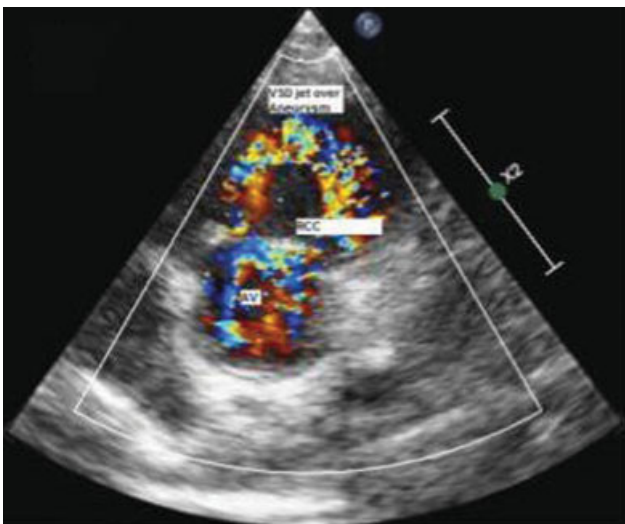
TTE showed normal left and right ventricular dimensions; left ventricular systolic function was hyperdynamic. Color-flow Doppler echocardiography displayed severe aortic regurgitation (AR) with normal biventricular systolic function (▶ Fig. 1). Additionally, an abnormal flow curving around the right SoV aneurysm into the right ventricular outflow tract was found (▶ Fig. 2). Interestingly, due to unusually curvilinear thick jet, precise determination of SoV rupture or VSD

DOI <https://doi.org/10.1055/s-0041-1735924>.  
ISSN 0971-3026.

© 2021. Indian Radiological Association. All rights reserved.  
This is an open access article published by Thieme under the terms of the Creative Commons Attribution-NonDerivative-NonCommercial-License, permitting copying and reproduction so long as the original work is given appropriate credit. Contents may not be used for commercial purposes, or adapted, remixed, transformed or built upon. (<https://creativecommons.org/licenses/by-nc-nd/4.0/>)  
Thieme Medical and Scientific Publishers Pvt. Ltd., A-12, 2nd Floor, Sector 2, Noida-201301 UP, India



**Fig. 1** Parasternal long axis view shows eccentric severe aortic regurgitation jet with dilated aortic root.

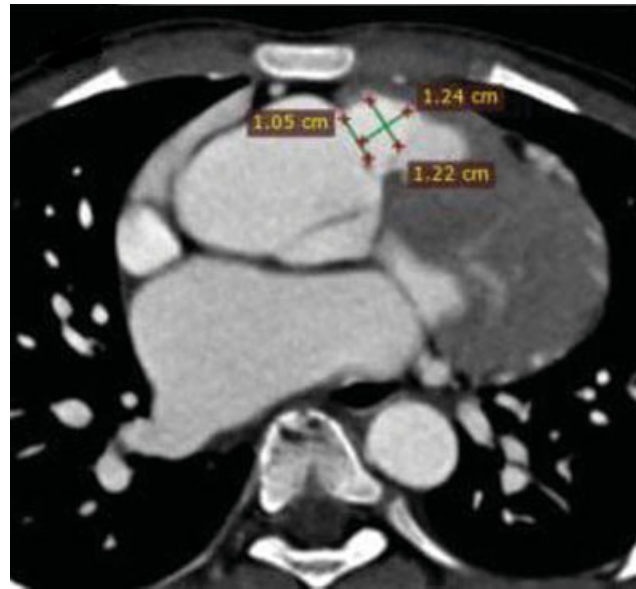


**Fig. 2** Left ventricle to right ventricular shunt with curved path over aneurysm.

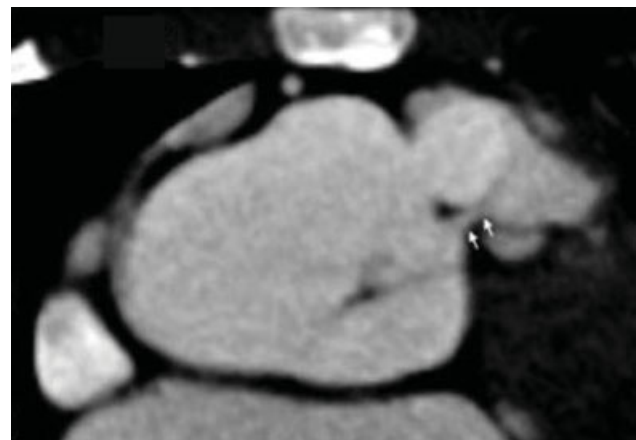
shunt was not possible on TTE. To determine this complex anatomy, a contrast cardiac computed tomography (CT) scan was performed. On cardiac CT, evidence of contrast filled outpouching seen arising from right aortic SoV of  $\sim 16 \times 16$  mm width and 12 mm wide neck suggestive of aneurysm (**Fig. 3**). The right SoV aneurysm extends to the right ventricle (RV) with reflux of contrast into the RV. Additionally, there was evidence of thin track-like communication filled with contrast in the subpulmonic region, confirming the underlying subpulmonic location of VSD (**Fig. 4**).

## Discussion

SoV aneurysms are very rare, with incidence rate ranging from 0.1 to 3.5% of all congenital heart diseases.<sup>4</sup> SoV aneurysms occur three times more often in males, with the highest incidence in Asian populations.<sup>5</sup> Most SoV aneurysms arise from the right or the noncoronary sinuses. They commonly



**Fig. 3** Cardiac computed tomography showing the right coronary cusp aneurysm with contrast reflux extending into right ventricle.



**Fig. 4** Left ventricular outflow tract to right ventricular outflow tract contrast flow at subpulmonic location suggestive of ventricular septal defect shunt.

rupture into the RV or right atrium. Anatomically, most SoV aneurysms are congenital in origin, caused by the lack of fusion between the media of the aorta and the annulus fibrosus of the aortic valve.<sup>6</sup> Hemodynamically, the flow through VSD produces Venturi effect, a tendency for the related aortic sinus and cusp to pull away from closure. These two mechanisms induce AR and AR begets AR. Our case confirms the mechanism of this classic effect. Although the first line of investigation in such cases is TTE, accuracy is reported  $\sim 75\%$  in the literature.<sup>7</sup> In our case, TTE confirms the site and size of aneurysm but fails to determine abnormal jet as rupture versus shunt. It was suspected that two different pathologies are difficult to differentiate because of anatomically adjacent locations at the level of aortic annulus. Cardiac CT identified the exact localization of the VSD which was subpulmonic and the right coronary cusp aneurysm was intact with no evidence of contrast spill into the RV.

### Surgical Plan

The three-dimensional (3D) outline of the complex defect enables proactive surgical plan and appropriate choice of the surgical method. The importance of advanced imaging in surgical planning is the most critical step in such cases. Especially, 3D CT gives an accurate anatomy of the region of aortic root and location of coronary ostia. In our case, the surgical option includes simple patch closure of VSD with or without aortic valve repair. Another approach is the “Ross” procedure where diseased aortic valve is replaced by the patient’s pulmonary valve and pulmonary valve is replaced by homograft. Another surgical approach is the “Bentall” procedure where composite graft replacement of aortic root, aortic valve, and ascending aorta is performed with reimplantation of coronary ostia. The choice of surgical approach is determined by the cardiovascular surgical team combining the overall clinical parameters with anatomy of the aortic root.

### Conclusion

Cardiac CT with 3D anatomical outline is the most advanced and preferred imaging method for appropriate choice of surgical method and risk stratification of surgical outcome. Our case report highlights the importance of comprehensive evaluation of complex congenital heart diseases by clinical parameters and advanced cardiac CT imaging for accurate diagnosis and treatment plans.

### Financial Support and Sponsorship

Nil.

### Conflict of Interest

None declared.

### References

- 1 Edwards JE, Burchell HB. Specimen exhibiting the essential lesion in aneurysm of the aortic sinus. *Proc Staff Meet Mayo Clin* 1956; 31(14):407–412
- 2 Fishbein MC, Obma R, Roberts WC. Unruptured sinus of Valsalva aneurysm. *Am J Cardiol* 1975;35(06):918–922
- 3 Sakakibara S, Konno S. Congenital aneurysm of the sinus of Valsalva associated with ventricular septal defect. *Anatomical aspects. Am Heart J* 1968;75(05):595–603
- 4 Takach TJ, Reul GJ, Duncan JM, et al. Sinus of Valsalva aneurysm or fistula: management and outcome. *Ann Thorac Surg* 1999;68(05): 1573–1577
- 5 Chu SH, Hung CR, How SS, et al. Ruptured aneurysms of the sinus of Valsalva in Oriental patients. *J Thorac Cardiovasc Surg* 1990;99 (02):288–298
- 6 Edwards JE, Burchell HB. The pathological anatomy of deficiencies between the aortic root and the heart, including aortic sinus aneurysms. *Thorax* 1957;12(02):125–139
- 7 Dev V, Goswami KC, Shrivastava S, Bahl VK, Saxena A. Echocardiographic diagnosis of aneurysm of the sinus of Valsalva. *Am Heart J* 1993;126(04):930–936