



Treatment of Brachymetatarsia by Distraction Osteogenesis Using Monolateral External Fixator

Tratamento da braquimetatarsia por distração osteogênica com fixador externo monolateral

Adriano Machado Filho¹ Gabriel Fonseca de Oliveira Costa¹ Aryell Assis dos Santos Faria¹
Gustavo Teixeira Leão¹ Jefferson Soares Martins¹

¹Department of Foot and Ankle, Hospital de Urgências de Goiânia – State Department of Health, Goiânia, GO, Brazil

Address for correspondence Adriano Machado, B.Sc., Resident Physician in Orthopedics and Traumatology, Hospital de Urgências de Goiânia - State Department of Health, Rua T-37, n. 3000, Ônix Bueno, Setor Bueno, Goiânia, GO, 74230-025, Brazil (e-mail: adrianomf_5@hotmail.com).

Rev Bras Ortop 2022;57(1):75–81.

Abstract

Objective To describe the profile of the patients and the results obtained with the use of an external fixator for metatarsal lengthening in brachymetatarsia.

Methods A retrospective analysis of the medical records of patients with brachymetatarsia treated between January 2018 and April 2020 was performed. During this period, eight feet of six patients were operated on. Frequencies were estimated according to demographic and surgical aspects.

Results All patients (100%; $n = 6$) were female, with a mean age of 28 years old, ranging from 15 to 48 years old, and were motivated to seek the orthopedic service due to aesthetic deformity. The deformity was bilateral in two patients and unilateral in four patients. The average lengthening time was 22 days (± 7.15 , 95% confidence interval [CI]: 19.04–26.81). The lengthening speed was 0.5 mm/day, and the average total length of the lengthening was 11.46 mm (± 3.57 ; 95%CI: 9.52–13.40). Half of the patients (50%; $n = 3$) had local infection of the pins and were treated with antibiotics, and the others did not report any postsurgical complications. All patients denied pain or calluses after the surgical procedure and reported satisfaction with the results.

Conclusion All patients were female and sought surgery for brachymetatarsia for aesthetic reasons. Osteogenic distraction at a rate of 0.5 mm/day resulted in successful lengthening of the metatarsal, with a low frequency of complications, good clinical outcomes, and high patient satisfaction.

Keywords

- ▶ foot deformities
- ▶ orthopedic procedures
- ▶ osteogenesis, distraction
- ▶ metatarsal bones

The present work was developed at the Hospital de Urgências de Goiânia - State Department of Health, Goiânia, GO, Brazil.

received
January 7, 2021
accepted
June 2, 2021
published online
October 1, 2021

DOI <https://doi.org/10.1055/s-0041-1735828>.
ISSN 0102-3616.

© 2021. Sociedade Brasileira de Ortopedia e Traumatologia. All rights reserved.

This is an open access article published by Thieme under the terms of the Creative Commons Attribution-NonDerivative-NonCommercial-License, permitting copying and reproduction so long as the original work is given appropriate credit. Contents may not be used for commercial purposes, or adapted, remixed, transformed or built upon. (<https://creativecommons.org/licenses/by-nc-nd/4.0/>)

Thieme Revinter Publicações Ltda., Rua do Matoso 170, Rio de Janeiro, RJ, CEP 20270-135, Brazil

Resumo

Objetivo Descrever o perfil dos pacientes e os resultados obtidos com o uso de fixador externo para alongamento de metatarso em braquimetatarsia.

Métodos Foi realizada uma análise retrospectiva dos prontuários de pacientes com braquimetatarsia tratados entre janeiro de 2018 e abril de 2020. Durante este período, foram operados oito pés de seis pacientes. Foram coletadas e estimadas as frequências em relação a aspectos demográficos e cirúrgicos.

Resultados Todas as pacientes (100%; $n = 6$) eram do sexo feminino, com média de idade de 28 anos, variando de 15 a 48 anos, e motivadas a buscar o serviço de ortopedia em função da deformidade estética. O acometimento era bilateral em duas pacientes e unilateral em quatro pacientes. O tempo médio de alongamento foi de 22 dias ($\pm 7,15$; intervalo de confiança [IC] 95%: 19,04–26,81). A velocidade de alongamento foi de 0,5 mm/dia e o comprimento médio total do alongamento foi de 11,46 mm ($\pm 3,57$; IC95%: 9,52–13,40). Metade das pacientes (50%; $n = 3$) teve infecção local dos pinos e foi tratada com antibióticos; as demais não relataram nenhuma complicação pós-cirúrgica. As pacientes negaram dor ou calosidade após o procedimento cirúrgico e relataram satisfação com os resultados.

Conclusão Todas as pacientes eram do sexo feminino e buscaram a cirurgia para braquimetatarsia por motivos estéticos. A distração osteogênica a uma taxa de 0,5 mm/dia resultou em alongamento bem-sucedido do metatarso, com uma baixa frequência de complicações, bons resultados clínicos e alta satisfação das pacientes.

Palavras-chave

- ▶ deformidades do pé
- ▶ procedimentos ortopédicos
- ▶ osteogênese por distração
- ▶ ossos do metatarso

Introduction

Brachymetatarsia is a rare congenital deformity, predominant in females (92.5%),¹ in which the metatarsus of the foot is shortened by ≥ 5 mm in relation to the transverse arch of the foot.² It mainly affects the fourth metatarsal, but the pathology can occur in any metatarsal bone. In addition to aesthetic insecurity, the deformity can impair the support mechanism of the foot, causing pain to walk. Surgical treatment is an alternative in the search for a satisfactory aesthetic and functional result.^{3,4}

The etiology of the pathology is not yet fully understood. The main cause is premature closure of the metatarsal growth plate, resulting from hereditary, post-traumatic or postsurgical factors.⁵ It may be associated with diseases such as Down syndrome, Apert syndrome, Albright osteoarthritis, sickle cell anemia, diastrophic anomaly, poliomyelitis, endocrinopathies, and Turner syndrome.¹ Other secondary causes described in the literature include infections, tumors, and radiation exposure.⁶

Brachymetatarsia is typically detected between 1 and 5 years of age, may affect ≥ 1 metatarsi, and may be unilateral or bilateral. The incidence of bilateralism occurs in $>50\%$ of the cases described in the literature.⁷ The complaints of the patients include metatarsalgia, calluses, irritation in the use of footwear, and soft tissue contractures. However, aesthetic appearance is the main complaint in young women, resulting from the shortening of the affected radius or associated deformities of the other toes, including the deviation of normal rays to fill the gap formed by the compromised metatarsus, generating varus

deformities in the medially located and varus fingers in the laterally located fingers.⁸

Surgical treatment of brachymetatarsia includes techniques that use acute stretching using interpositional bone graft or gradual stretching by osteogenic distraction (with or without graft), associated or not with a procedure in adjacent phalanges.^{5,9,10} Distraction osteogenesis using external fasteners is a widely used technique, especially when stretching > 1 cm is required.¹¹ Although the long duration of treatment and the understanding and cooperation of the patient may seem unfavorable in the choice of this technique,⁸ some important advantages of the use of gradual distraction include increased construction stability, possibilities of longer stretching, greater control of stretching, shorter surgical time, and absence of the need for bone graft (which can generate pain and discomfort in the donor area, in addition to the risk of graft absorption).¹

The aim of the present study was to describe the profile of the patients and the results obtained with the use of external fixator for metatarsal stretching in brachymetatarsia in an orthopedics and traumatology service.

Material and Methods

The present retrospective study with analysis of medical records was approved by the Research Ethics Committee of the proposing institution with the CAEE number 34810920.2.0000.0033. The collected data were evaluated in Microsoft Excel 2007 (Microsoft Corporation, Redmond, WA, USA) and in SPSS Statistics for Windows version 17.0 (SPSS Inc., Chicago, IL, USA). The present study included 6

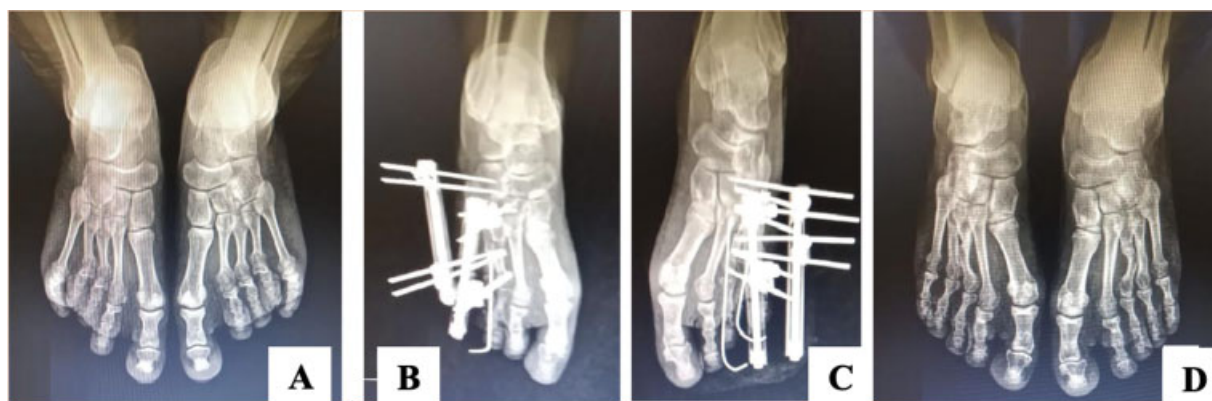

Fig. 1 Radiograph in anteroposterior incidence of the feet with load demonstrating the evolution of a patient with bilateral brachymetatarsia in the 3rd and 4th metatarsi submitted to osteogenic distraction. (A) preoperative radiography, (B) postoperative radiography of the right side, (C) postoperative radiography of the left side; and (D) result after 12 weeks of treatment.

patients diagnosed with brachymetatarsia treated between January 2018 and April 2020 and a total of 8 feet and 12 metatarsi.

The following epidemiological variables were evaluated: age, gender, reason for consultation (aesthetic deformity, metatarsalgia, difficulty to put on shoes), affected side, affected metatarsal, presence of pain or callosity (before and after surgery), time of distraction of the fixator, stretching obtained (in mm), time of use of fixator, complications, and postsurgical satisfaction.

Radiographs (→ **Figure 1**) were used in the anteroposterior and profile incidences for evaluation of the parameters of stretching (length gain) and of the callogenesis of bone regenerated. The desired clinical aspect in the correction of the deformity determined the stretching period to be performed by the patient via outpatient care.

The inclusion criteria were patients submitted to osteogenic distraction with external fixator for metatarsal elongation in brachymetatarsia. Participants who underwent any surgical procedure for metatarsal stretching other than osteogenic distraction with monolateral external fixator were excluded from the sample.

The surgical technique used followed the following standardization: patient in the supine position with a lateral inclination of 45° on the side to be operated, using a pneumatic garrote inflated at 300 mmHg. Under fluoroscopy guidance, two Schanz pins are inserted into the proximal mephemis and two in the distal mephemis. The pins are positioned in an inclination of 45° in relation to the axis of the metatarsus to be elongated, after skin incision with scalpel, blade number 15, dissection of soft parts with delicate hemostatic clam for the removal of tendons, and broaling with punch with rotational control. When the metatarsal to be lengthened is very shortened, the placement of a pin on the corresponding cuneiform bone is accepted. After installation and locking of the two heads of the mini-fixator, a skin incision is made with dissection by planes, diaphysis exposure, and multiple perforations with a delicate drill to aid in corticotomy. Corticotomy is performed with delicate osteotomy, direct subvisualized, and fluoroscopy

was conferenced intraoperatively. Next, the metatarsus-phalange joint is fixated with a Kirschner wire 1.5 (→ **Figure 2**) to avoid deformity in phalanx flexion during distraction stretching. After that, the skin incision is closed at the site of corticotomy with nylon 4.0 thread and bandages on the pins. When there it is necessary to place more than one external fixator, the procedure is performed in the same way by carefully observing the distance between the assemblies so as not to hinder distraction and stretching.

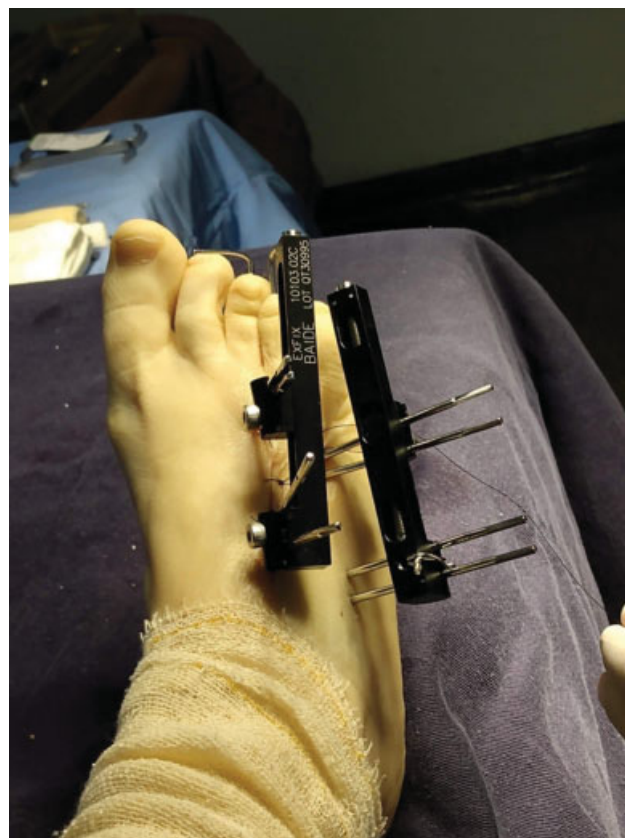

Fig. 2 Monolateral external fixator installed for bone distraction at 45° inclination and intramedullary Kirschner wires.

Table 1 Demographic data of patients (preoperative)

| Data | Values |
|---|--------------------------|
| Number of participants (n) | 6 |
| Number of metatarsi (n) | 13 |
| Number of feet (n) | 8 |
| Female (n) | 6 |
| Age (\pm standard deviation) | 28 \pm 14.62 years old |
| Laterality (n) | – |
| Bilateral | 2 patients |
| Right | 2 patients |
| Left | 2 patients |
| Patients with aesthetic dissatisfaction | 6 (100%) |

The patients in the present study were discharged from the hospital in 48 hours. They were instructed on when to start and on how to perform bone distraction, 0.25mm every 12 hours, with weekly radiographs and partial load with rigid sole. The removal of the external fixator was performed in all patients in the 12th postoperative week, under sedation.

Results

In the period from 2018 to 2020, 6 patients were surgically treated, totaling 8 feet and 13 metatarsi (\blacktriangleright **Table 1**) submitted to osteogenic distraction with external fixator. The mean age was 28 years old (\pm 14.62; 95% confidence interval [CI]: 16.31–39.69), ranging from 15 to 48 years old. All patients (100%; $n = 06$) were female, with congenital brachymetatarsia and motivated to seek orthopedic service due to aesthetic deformity. Only one patient complained of presurgical pain.

The involvement was bilateral in two patients and unilateral in four patients. The mean stretching time was 22 days (\pm 7.15; 95%CI: 19.04–26.81) and the total mean length of elongation was 11.46 mm (\pm 3.57; 95%CI: 9.52–13.40); the mean was higher in the right foot (25.43 ± 9.07 days) than in the left (20.00 ± 2.19 days; $p < 0.05$). Regardless of the affected side, the frequency of deformity is higher in the fourth metatarsus, in which all patients had deformity (\blacktriangleright **Figure 3**).

\blacktriangleright **Table 2** shows the individual data referring to the stretching time (in days), the length obtained (in mm), and the follow-up time (in months) of the patients treated using an external fixator separated according to the affected side and metatarsus. The metatarsi on the right side presented the highest means of stretching time and length obtained. For the fourth metatarsi on the right side, the elongation lasted on average 28.76 days, and the average length obtained was 14.33 mm. For the fourth metatarsus on the left side, the mean was 22 days, and the length was 11 mm. The third metatarsus followed the same trend, with a mean elongation time on the right side of 24.67 days and an average length of 12.33 mm, which were higher than those of the left side, of 18 days and 9 mm. The stretching speed was 0.5 mm/day and the patients were instructed to lengthen the fixator daily. The mean follow-up period was 18 months, ranging from 6 to 48 months.

According to the data from the medical records, 50% ($n = 03$) of the patients had local infection of the pins and were treated with antibiotics; the others did not report any postsurgical complications. All patients denied pain or callosity after the surgical procedure and reported being satisfied with the results obtained.

Discussion

The main complaint of patients seeking treatment for brachymetatarsia is associated with aesthetic deformity or

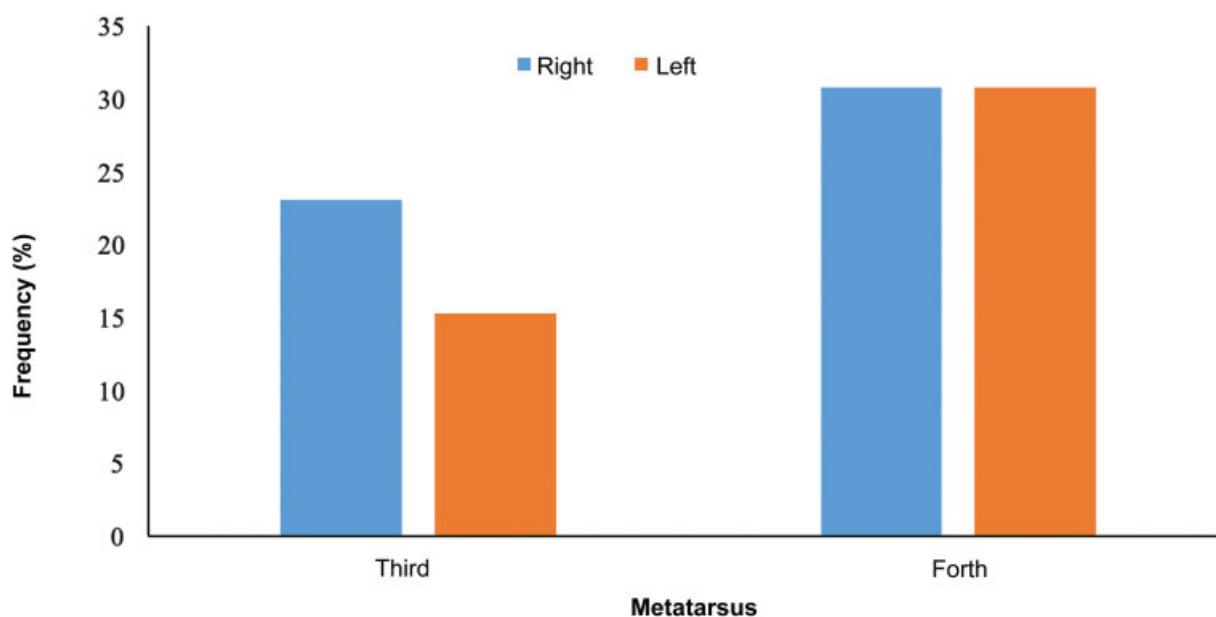


Fig. 3 Frequency of brachymetatarsia according to the side and metatarsus affected in patients using a monolateral external fixator for stretching.

Table 2 Data of patients with brachymetatarsia regarding elongation time (T), length obtained (L) and follow-up time (FT) submitted to treatment using external fixator

| Side | Right | | | | Left | | | | FT (months) |
|--------------|--------------|--------------|--------------|--------------|--------------|-------------|--------------|--------------|-------------|
| | Metatarsus* | | Room | | Third | | Room | | |
| Patient | T (days) | L (mm) | T (days) | L (mm) | T (days) | L (mm) | T (days) | L (mm) | |
| 1 | – | – | – | – | – | – | 20 | 10 | 24 |
| 2 | – | – | 18 | 9 | – | – | – | – | 48 |
| 3 | – | – | – | – | – | – | 20 | 10 | 12 |
| 4 | 18 | 9 | 20 | 10 | 18 | 9 | 20 | 10 | 8 |
| 5 | 20 | 10 | 26 | 13 | 18 | 9 | 24 | 12 | 12 |
| 6 | 36 | 18 | 40 | 20 | – | – | – | – | 6 |
| Average ± SD | 24.67 ± 9.87 | 12.33 ± 4.93 | 28.67 ± 9.93 | 14.33 ± 4.97 | 18.00 ± 0.00 | 9.00 ± 0.00 | 22.00 ± 2.00 | 11.00 ± 1.00 | 18.3 ± 15.8 |

Abbreviations: FT, follow-up time; L, length; SD, standard deviation; T, time.

functional difficulty.^{2,6} These patients are generally excluded from social and sports activities due to the appearance of the foot.¹² In the present study, aesthetic appearance was the main complaint reported by patients undergoing surgical treatment. About 25% of primary weight support stress is absorbed by the metatarsi. The shortening of any of them leads to overload and laxity of the transverse ligament, causing inadequate forefoot contact, excessive pressure, and impaired muscle function, resulting in pain and fatigue in the leg and the foot.¹³ Pain is considered the second most common indication for the surgical treatment of brachymetatarsia.¹⁴ None of the patients in the present study reported significant pain complaints.

Most of the cases described in the literature^{3,4,8,9} and all cases evaluated in the present study are female. Brachymetatarsia is a rare congenital deformity (its incidence in the population ranges from 0.02 to 0.05%), with a higher frequency in females, at the ratio of 25:1 when compared with males.¹²

The greatest demand for surgical treatment of brachymetatarsia occurs in the adolescence, due to aesthetic dissatisfaction.² However, in the present study, half of the sample was composed of adolescents and the other half was of young adults (50%; $n=3$). The mean age of the operated patients was 28 years old, close to that observed by Giannini et al.⁸ (mean of 27 years old, ranging from 12 to 42 years old) when evaluating 29 patients operated for correction of brachymetatarsia in an Italian hospital for 10 years. These same authors⁸ suggest that surgery be performed after 12 years

of age, as bone growth should be expected to be completed, in addition to the difficulty of management after surgery in younger children. Lee et al.¹⁵ report a lower rate of complications in operated adolescents when compared with adults in relation to bone regenerated consolidation.

Lamm¹¹ suggests that for a gain of 20 mm in metatarsal elongation, the time required would be ~ 45 days, with 5 days of latency and 40 days of distraction at a speed of 0.5 mm/day. In the present study, the distraction speed was 0.5 mm/day (0.25 mm every 12 hours) and the mean elongation time was 22 days. Stretching speeds > 1 mm/day may result in pain, in excessive soft tissue tension, and in joint dislocation.¹⁶ Gradual stretching in a single stage reduces the risk of neurovascular involvement, as it generates lower soft tissue tension. When the need for stretching is > 10 mm, the risk of neurovascular involvement is the main limitation of acute treatment with stretching, bone grafting, and internal fixation.¹¹

When evaluating 48 cases of brachymetatarsia, Peña-Martínez et al.¹⁶ observed that the fourth metatarsus was the most affected, representing 98% of the cases, with the third metatarsus representing the other 2%. In the present study, 61.5% ($n=8$) of the deformities were in the fourth metatarsus, and 38.5% ($n=5$) were in the third metatarsus (→ **Figure 3**). The chosen technique used a monolateral external fixator associated with the use of Kirschner wires (→ **Figures 2 and 4**), promoting stability in the metatarsophalangeal joint and avoiding deformity in metatarsus flexion during bone stretching.

**Fig. 4** Postoperative of a patient with a 3rd and 4th metatarsi deformity of the left foot submitted to bone stretching with monolateral external fixator.

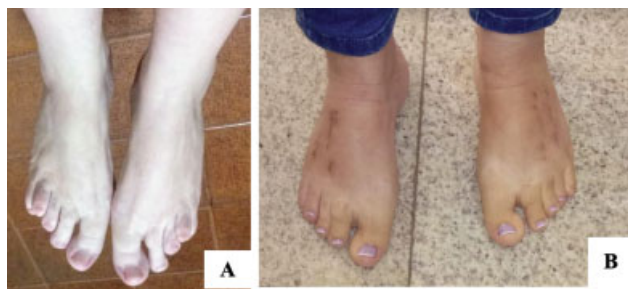

Fig. 5 Preoperative (A) and postoperative (B) clinical aspects of a patient with bilateral brachymetatarsia in the 3rd and 4th metatarsi submitted to osteogenic distraction using a monolateral fixator.

Osteogenic distraction is the most accepted and most successful treatment performed by foot and ankle surgeons for metatarsus stretching.¹⁷ The advantages of gradual stretching are the ability to obtain a longer length compared with that obtained by the use of an interim bone graft, allowing immediate weight support and preserving the movement of the metatarsal-phalangeic joint, and the fact that it does not present the need for bone graft, which can generate discomfort in the donor area.¹¹ These advantages make the technique of gradual distraction the most used method when seeking a stretching > 15 mm or > 25% of the initial size of the metatarsus.¹

Osteogenic distraction has as a disadvantage the need for regular adjustment of the external fixator for stretching, the possibility of insufficient bone formation, and the risk of local infection. To stimulate adequate bone formation, a careful osteotomy should be performed with minimal damage to soft tissue and vascular tissue.^{11,18}

In stretching by osteogenic distraction in 2 stages, distraction is performed more quickly (~ 2 mm per day), and after reaching the desired length, the placement of bone graft in the regenerated and the replacement of external fixation by the internal fixation, in the absence of infection of the pins, are performed to reduce the time of the external fixator and joint stiffness.¹⁴

Masada et al.¹⁹ report a higher number of postoperative complications when stretching is > 40% of the original length of the metatarsus, citing excessive stretching, joint stiffness, loss of alignment, delayed consolidation, and fracture of the regenerated.

In all analyzed patients, the elongation achieved was obtained without loosening the pins, with a good bone regenerated without the need for graft use in a second moment or for another surgical procedure in addition to the removal of the external fixator and of the Kirschner wire via outpatient care. Consolidation was obtained in 100% of the patients within the period of 8 to 12 weeks. At the end of the treatment, all patients presented good surgical correction, good aesthetic aspect (► **Figure 5**), high degree of satisfaction with the surgery, and no degree of stiffness or of mobility deficit in the joints of the third and fourth toes.

In the scientific literature, it is well-established that external fixation restores the length of the metatarsus, the position of the toes, the function of the foot and toes,

improves cosmesis, and reduces pain.²⁰ The results obtained in the present study were comparable to those of other studies in terms of demographic characteristics, amount of surgical correction, and clinical results.^{9,20,21} The present study also presents some limitations due to its retrospective nature, besides having a relatively small sample and a short follow-up time in the postoperative period.

Conclusion

All patients were female and sought surgery for brachymetatarsia for aesthetic reasons. Gradual osteogenic distraction at a rate of 0.5 mm/day using an external fixator and fixation of the metatarsophary joint with Kirschner wire resulted in successful stretching of the metatarsus, with good aesthetic and functional results. Despite the limitations of the present study, the good clinical results and the high satisfaction of the patients make the use of a monolateral external fixator for metatarsus elongation in brachymetatarsia a good option.

Financial Support

There was no financial support from public, commercial, or non-profit sources.

Conflict of Interests

The authors have no conflict of interests to declare.

References

- 1 Rocha FA, Mansur H, Meira RB, Gusmão L, Gonçalves CB, Castro Júnior IM. One-stage correction of multiple brachymetatarsia and hallux valgus with calcaneal autograft. *Sci J Foot Ankle* 2018;12 (04):342-346
- 2 Kim HT, Lee SH, Yoo CI, Kang JH, Suh JT. The management of brachymetatarsia. *J Bone Joint Surg Br* 2003;85(05):683-690
- 3 Smolle E, Scheipl S, Leithner A, Radl R. Management of congenital fourth brachymetatarsia by additive autologous lengthening osteotomy (AALO): a case series. *Foot Ankle Int* 2015;36(03):325-329
- 4 Desai A, Lidder S, Armitage AR, Rajaratnam SS, Skyrme ADS. Brachymetatarsia of the fourth metatarsal, lengthening scarf osteotomy with bone graft. *Ortop Rev (Pavia)* 2013;5(03):e21
- 5 Lara LCR, Franco Filho N, Marques AFS. Tratamento cirúrgico da braquimetatarsia. *Rev ABTPe* 2008;2(01):7-11
- 6 Lee WC, Suh JS, Moon JS, Kim JY. Treatment of brachymetatarsia of the first and fourth ray in adults. *Foot Ankle Int* 2009;30(10):981-985
- 7 Scher DM, Blyakher A, Krantzow M. A modified surgical technique for lengthening of a metatarsal using an external fixator. *HSS J* 2010;6(02):235-239
- 8 Giannini S, Faldini C, Pagkrati S, Miscione MT, Luciani D. One-stage metatarsal lengthening by allograft interposition: a novel approach for congenital brachymetatarsia. *Clin Orthop Relat Res* 2010;468(07):1933-1942
- 9 Lee KB, Yang HK, Chung JY, Moon ES, Jung ST. How to avoid complications of distraction osteogenesis for first brachymetatarsia. *Acta Orthop* 2009;80(02):220-225
- 10 Iida N, Watanabe A. A new surgical procedure for brachymetatarsia by a hydroxyapatite graft. *Eur J Plast Surg* 2013;36:41-44
- 11 Lamm BM. Percutaneous distraction osteogenesis for treatment of brachymetatarsia. *J Foot Ankle Surg* 2010;49(02):197-204
- 12 Shim JS, Park SJ. Treatment of brachymetatarsia by distraction osteogenesis. *J Pediatr Orthop* 2006;26(02):250-254

- 13 Barik S, Farr S. Brachymetacarpia and brachymetatarsia: do we need to operate? *EFORT Open Rev* 2021;6(01):15–23
- 14 Shecaira AP, Fernandes RMP. Brachymetatarsia: One-stage Versus Two-Stage Procedures. *Foot Ankle Clin* 2019;24(04):677–687
- 15 Lee KB, Park HW, Chung JY, Moon ES, Jung ST, Seon JK. Comparison of the outcomes of distraction osteogenesis for first and fourth brachymetatarsia. *J Bone Joint Surg Am* 2010;92(16):2709–2718
- 16 Peña-Martínez VM, Palacios-Barajas D, Blanco-Rivera JC, et al. Results of External Fixation and Metatarsophalangeal Joint Fixation With K-Wire in Brachymetatarsia. *Foot Ankle Int* 2018;39(08):942–948
- 17 Lamm BM, Gourdine-Shaw MC. Problems, obstacles, and complications of metatarsal lengthening for the treatment of brachymetatarsia. *Clin Podiatr Med Surg* 2010;27(04):561–582
- 18 Hurst JM, Nunley JA II. Distraction osteogenesis for the shortened metatarsal after hallux valgus surgery. *Foot Ankle Int* 2007;28(02):194–198
- 19 Masada K, Fujita S, Fuji T, Ohno H. Complications following metatarsal lengthening by callus distraction for brachymetatarsia. *J Pediatr Orthop* 1999;19(03):394–397
- 20 Lee WC, Yoo JH, Moon JS. Lengthening of fourth brachymetatarsia by three different surgical techniques. *J Bone Joint Surg Br* 2009;91(11):1472–1477
- 21 Fusini F, Langella F, Catani O, Sergio F, Zanchini F. Mini-invasive treatment for brachymetatarsia of the fourth ray in females: percutaneous osteotomy with mini-burr and external fixation—a case series. *J Foot Ankle Surg* 2017;56(02):390–394