



# Comparison between Digital Subtraction Angiography and Indocyanine Green Video Angiography in the Operative Management of Aneurysmal Subarachnoid Hemorrhage

Mohsin Fayaz<sup>1</sup> Kaiser Kareem<sup>1</sup> Abrar Ahad Wani<sup>1</sup> Altaf Umar Ramzan<sup>1</sup> Nayil khursheed Malik<sup>1</sup> Sabia Rashid<sup>1</sup>

<sup>1</sup> Department of Neurosurgery, Sher-i-Kashmir Institute of Medical Sciences, Soura, Srinagar, Jammu and Kashmir, India

Address for correspondence Mohsin Fayaz, MBBS, MS, MCh, Department of Neurosurgery, Sher-i-Kashmir Institute of Medical Sciences, Soura, Srinagar 190011, Jammu and Kashmir, India (e-mail: mohsin.fayaz.bhat@gmail.com).

Indian J Neurosurg 2024;13:103–106.

## Abstract

**Background** Digital subtraction angiography (DSA) is a fluoroscopy technique used in interventional radiology to clearly visualize blood vessels in a bony or dense soft tissue environment. Images are produced using contrast medium by subtracting a “pre-contrast image” or mask from subsequent images, once the contrast medium has been introduced into a structure, hence the term “Digital subtraction angiography.” Indocyanine green video angiography (ICG-VA) is a safe and practical method of real-time delineation of microvasculature used in the surgical management of intracranial aneurysms, arteriovenous malformations, and other vascular lesions. Intraoperative ICG-VA is used as an adjunct in addition to intraoperative or postoperative DSA, and in other cases, it is used as the sole method to confirm the complete obliteration of clipped intracranial aneurysm. The only limitation of ICG-VA is the nonvisibility of vessels that are not in the operative field. Intraoperative ICG is useful in the clipping of intracranial aneurysms to ensure a gross patency of branch vessels; however, the presence of residual aneurysms and subtle changes in flow in branch vessels is best seen by DSA.

**Methods** ICG angiography was done during the surgery and the findings of intraoperative ICG angiography were compared with postoperative DSA that was done between 6 and 12 weeks. DSA was done to see any compromise of lumen of parent vessel by clip, any residual aneurysm.

**Results** In our study, intraoperative ICG complete aneurysm obliteration was present in all 30 (100%) patients, while in postoperative DSA complete aneurysm obliteration was diagnosed in 27 (90.0%) patients. Parent vessel patency was present in all 30 (100.0%) patients in both intraoperative ICG-VA and postoperative DSA. In intraoperative ICG distal branch patency was present in 26 (86.7%) patients, while in postoperative DSA distal branch patency was diagnosed in 27 (90.0%) patients.

## Keywords

- aneurysm
- digital subtraction angiography
- indocyanine video angiography

article published online  
April 21, 2022

DOI <https://doi.org/10.1055/s-0041-1735378>.  
ISSN 2277-954X.

© 2022. The Author(s).

This is an open access article published by Thieme under the terms of the Creative Commons Attribution-NonDerivative-NonCommercial-License, permitting copying and reproduction so long as the original work is given appropriate credit. Contents may not be used for commercial purposes, or adapted, remixed, transformed or built upon. (<https://creativecommons.org/licenses/by-nc-nd/4.0/>)

Thieme Medical and Scientific Publishers Pvt. Ltd., A-12, 2nd Floor, Sector 2, Noida-201301 UP, India

**Conclusion** We compared the intraoperative ICG finding and postoperative DSA finding and found that DSA is more sensitive than ICG in depicting residual aneurysm neck, hence reducing the risk of rupture of the aneurysm in future. Intraoperative ICG has high special resolution reflex feedback, intraoperative repositioning time is less and thus critical ischemia time is reduced. In a developing country like ours where DSA facilities are limited, ICG can be optimal investigation to delineate the vascular anatomy and confirmation of clip position thus reducing mortality.

## Introduction

Digital subtraction angiography (DSA) remains the gold-standard study for the radiographic diagnosis and the overall treatment planning for patients with brain aneurysms.<sup>1</sup> Over the past two decades, DSA has become a well-established modality for the delineation of vasculature in the human body.<sup>2</sup> The technique usually involves injecting contrast medium into the veins and measuring over time the changing concentration of contrast medium passing through the vasculature of interest. With the advanced digital system, the images before the contrast injection are “subtracted” from those after injection to give a numerical representation of the arterial structure under study. This relatively noninvasive technique can be performed on an outpatient basis with very low risk of morbidity and has made invasive techniques trivial. Subtraction angiography was first described in 1935.<sup>3,4</sup> Intraoperative indocyanine green (ICG) angiography is a technique of intraoperative blood flow assessment and delineation of microvasculature introduced in 2003. ICG is an inert agent and it avoids contrast exposure.<sup>5</sup> ICG dye is a near infrared fluorescent dye that was originally used for the evaluation of vascular and hepatic function. After intravenous injection, ICG is bound almost immediately by globulins and remains intravascular until its excretion by liver. ICG is not reabsorbed into the intestine, neither does it enter the hepatic circulation. The surgical field is illuminated by a light source with the wavelength covering the ICG absorption band (700–850nm). After intravenous injection of ICG dye, its fluorescence is induced and recorded by video camera. As a result, real-time video images of arterial, capillary, and venous phases of angiography can be seen. This method gives excellent and quick assessment of microvasculature intraoperatively.<sup>6,7</sup> It confirms optimal clip positioning across the neck and patency of adjacent vasculature and minimizes the need for intraoperative DSA.<sup>5</sup> Indocyanine green video angiography (ICG-VA) is a safe method that can be used during microneurosurgical management of intracranial aneurysms, arteriovenous malformations, and other vascular lesions. The limitation of ICG-VA is the nonvisualization of vessels that are not in the operative field. Intraoperative ICG is useful in the clipping of intracranial aneurysms to ensure a gross patency of

branch vessels; however, lacks to show the presence of residual aneurysms, perforators and subtle changes in flow in branch vessels is best seen by DSA. This has important clinical implications about follow-up imaging and surgical/endovascular management.<sup>5</sup>

ICG angiography can be used as an adjunct to intraoperative DSA or used as the sole method to confirm the complete obliteration of clipped intracranial aneurysms. Therefore, we conducted a study to evaluate the correlation between ICG and DSA in clipped intracranial aneurysm in which both modalities were tested.

## Aims and Objectives

The aim of this study was to study and compare the efficacy of intraoperative ICG with postoperative DSA.

## Materials and Methods

The present study titled “Comparison between Digital Subtraction Angiography and Indocyanine Green Video-Angiography in the Operative Management of Aneurysmal Subarachnoid Hemorrhage” was prospective in design and was conducted in the Department of Neurosurgery SKIMS, Srinagar, from September 2017 to September 2020.

### Inclusion Criteria

Patients with aneurysmal Subarachnoid Hemorrhage who underwent clipping of intracranial aneurysm.

### Exclusion Criteria

1. Age less than 18 years.
2. Patients with contraindication to DSA.
3. Refusal to undergo procedure.

### Methodology

In our study, we did an intraoperative ICG to delineate the microvasculature and obliteration of aneurysm and see patency of main vessels and compared it with the postoperative DSA findings. DSA was done between 2 and 6 weeks postoperatively.

### Observation and Results

The following observations were made (→ **Table 1**).

**Table 1** Intraoperative ICG findings versus postoperative DSA findings

Findings	Intraoperative ICG findings		Postoperative DSA findings		p-Value
	No. of patients	%	No. of patients	%	
Complete aneurysm obliteration	30	100	27	90.0	0.237
Residual neck	0	0.0	3	10.0	0.237
Parent vessel patency	30	100	30	100	1.000
Distal branches patency	26	86.7	27	90.0	0.687

Abbreviations: DSA, digital subtraction angiography; ICG, indocyanine green.

Notes: In intraoperative ICG, complete aneurysm obliteration was present in all 30 (100%) patients, while in postoperative DSA, complete aneurysm obliteration was diagnosed in 27 (90.0%) patients. *p*-Value was 0.237.

Residual neck was present in none of patients in intraoperative ICG. Three (10.0%) patients had residual neck in postoperative DSA. *p*-Value was 0.237.

Parent vessel patency was present in all 30 (100.0%) patients in both intraoperative and postoperative DSA. *p*-Value was 1.000.

In intraoperative ICG, distal branches patency was present in 26 (86.7%) patients, while in postoperative DSA, distal branches patency was diagnosed in 27 (90.0%) patients. *p*-Value was 0.687.

## Discussion

In our study, evaluation of the intraoperative ICG findings of the patients verified complete aneurysm obliteration in 30 (100.0%) patients, parent vessel patency in 30 (100.0%) patients, distal vessel patency in 26 (86.7%) patients, and vasospasm in 2 (6.7%) patients. ►Fig. 1 is showing complete obliteration of distal anterior cerebral artery (DACA) aneurysm in the intraoperative ICG-VA and demonstration of pericallosal vessels. In the study conducted by Vitaz et al,<sup>8</sup> evaluation of the intraoperative angiographic sequence verified complete obliteration of the aneurysm with normal flow in the surrounding vessels in 75 cases (82%), whereas a persistent abnormality was documented in nine cases (19%). Intraoperative angiography in four of these patients revealed obliteration of a normal surrounding vessel. Good collateral flow was documented in two of these patients, and, in the other two, emergency extracranial–intracranial bypass was performed. The remaining five patients had evidence of a residual aneurysmal neck. Three of these five had undergone treatment of giant aneurysms (one anterior communicating, one ophthalmic, one basilar), whereas the other two had basilar artery aneurysms.

In our study, only 20% (6 out of 30) patients needed post-ICG repositioning of clip. Generally, highly variable clip adjustment rates of 2 to 38% following ICG have been

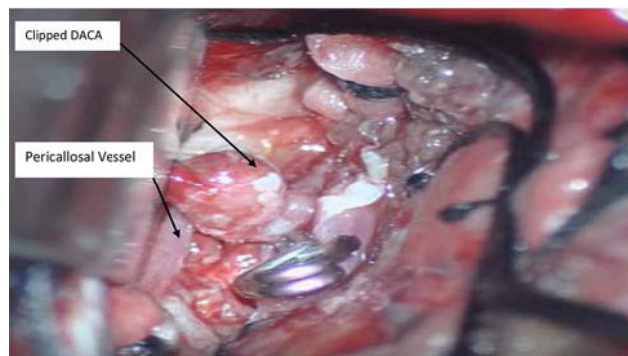
reported since the introduction of this imaging technique. ►Fig. 2 shows clipped DACA aneurysm with demonstration of pericallosal vessels. The larger report in literature until now revealed a rate of clip adjustment of 9.1% of 295 aneurysms treated in 232 patients. The variance may be attributable to a low number of patients, inhomogeneous patient groups, and the nonsystematic application of the technique in the previous studies.<sup>8</sup>

In our study, evaluation of the postoperative DSA findings of the patients verified complete aneurysm obliteration in 27 (90.0%) patients, residual neck in 3 (10.0%) patients, parent vessel patency in 30 (100.0%) patients, distal vessel patency in 27 (90.0%) patients, and vasospasm in 1 (3.3%) patient. ►Fig. 3 depicts clipped DSA showing complete obliteration of DACA aneurysm with patency of distal vasculature. In the study conducted by Doss et al,<sup>5</sup> postoperative DSA did not show any evidence of major branch occlusions or incomplete occlusions of the aneurysm domes.

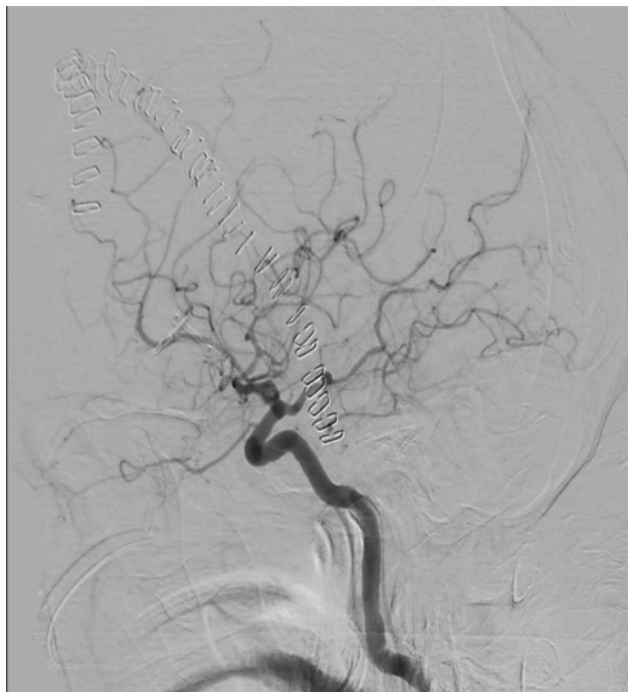
Compared with other studies, our study showed lower discrepancy between intraoperative ICG angiography and postoperative DSA results. Complete aneurysm obliteration was seen in 100.0% of patients in intraoperative ICG findings and 90.0% of patients in postoperative DSA. *p*-Value of 0.237 was found that was statistically nonsignificant. Residual neck was seen in 10.0% of patients in postoperative DSA findings and none in intraoperative ICG findings. Parent vessel



**Fig. 1** Indocyanine green video angiography depicting complete obliteration of distal anterior cerebral artery (DACA) aneurysm.



**Fig. 2** Clipped distal anterior cerebral artery (DACA) aneurysm.



**Fig. 3** Post clipped digital subtraction angiography showing complete obliteration of distal anterior cerebral artery aneurysm with patency of distal vasculature.

patency was seen in 100.0% patients in both intraoperative ICG and postoperative DSA findings. *p*-Value of 1.000 was obtained that was nonsignificant. Distal branches patency was seen in 86.7% patients in intraoperative ICG and 90.0% patients in postoperative DSA. *p*-Value of 0.687 was obtained that was statistically nonsignificant. Three out of seven were ruptured at presentation. Similarly, Fischer et al<sup>9</sup> showed inadequacies with ICG angiography in 10% of the clipped aneurysms.

## Conclusion

The sensitivity of DSA is more than ICG in showing residual aneurysm neck potentially reducing the risk of rupture of

the aneurysm. However, the high special resolution reflex feedback and less intraoperative clip repositioning time make ICG an attractive and safe modality effectively reducing critical ischemia time. In centers where DSA facilities are limited, ICG is a reasonable option to depict microvasculature, obliteration of aneurysm, and patency of main branches.

## Conflict of Interest

None declared.

## References

- 1 Simpson VM, Deshaies EMDiagnosis and Initial Management of Subarachnoid Haemorrhage. *OA Emergency Medicine* 2013;1-11
- 2 Hoh BL, Cheung AC, Rabinov JD, Pryor JC, Carter BS, Ogilvy CS. Results of a prospective protocol of computed tomographic angiography in place of catheter angiography as the only diagnostic and pretreatment planning study for cerebral aneurysms by a combined neurovascular team. *Neurosurgery* 2004;54(06):1329-1340, discussion 1340-1342
- 3 Meijering EH, Niesssen WJ, Viergever MA. Retrospective motion correction in digital subtraction angiography: a review. *IEEE Trans Med Imaging* 1999;18(01):2-21
- 4 Hanafee W, Stout P. Subtraction technic. *Radiology* 1962;79(04): 658-661
- 5 Doss VT, Goyal N, Humphries W, Hoit D, Arthur A, Elijovich L. Comparison of intraoperative indocyanine green angiography and digital subtraction angiography for clipping of intracranial aneurysms. *Intervent Neurol* 2015;3(03/04):129-134
- 6 Raabe A, Beck J, Gerlach R, Zimmermann M, Seifert V. Near-infrared indocyanine green video angiography: a new method for intraoperative assessment of vascular flow. *Neurosurgery* 2003;52(01):132-139discussion 139
- 7 Dashti R, Laakso A, Niemelä M, Porras M, Hernesniemi J. Microscope-integrated near-infrared indocyanine green video-angiography during surgery of intracranial aneurysms: the Helsinki experience. *Surg Neurol* 2009;71(05):543-550, discussion 550
- 8 Vitaz TW, Gaskill-Shipley M, Tomsick T, Tew JM Jr. Utility, safety, and accuracy of intraoperative angiography in the surgical treatment of aneurysms and arteriovenous malformations. *AJNR Am J Neuroradiol* 1999;20(08):1457-1461
- 9 Fischer G, Stadie A, Oertel JM. Near-infrared indocyanine green videoangiography versus microvascular Doppler sonography in aneurysm surgery. *Acta Neurochir (Wien)* 2010;152(09): 1519-1525