

# A Quick, Economical and Easy Method of Skin Graft Fixation

Dhruv Chavan<sup>1</sup> G. Vishwanath<sup>1,✉</sup> Bhushan Patil<sup>1</sup> Manashree Sankhe<sup>1</sup>

<sup>1</sup>Department of Plastic and Reconstructive Surgery, Dr. D. Y. Patil Medical College and Hospital, Pune, Maharashtra, India

**Address for correspondence** Dhruv Chavan, MBBS, MS, Department of Plastic and Reconstructive Surgery, Dr. D. Y. Patil Medical College and Hospital, Pimpri Pune 411018, Maharashtra, India (e-mail: dhruvchavan@gmail.com).

Indian J Plast Surg 2021;54:379–380.

The immobilization of a skin graft is a key factor in its take of a skin graft.

Traditionally, a bolster dressing is used to secure and keep the graft immobilized on its bed.<sup>1</sup> Its pressure obliterates dead space, and prevents hematoma and seroma formation.

This step usually falls toward the end of a long surgery, when anesthetic time may be at a premium and surgeon fatigue at its peak. Here, we describe a new method of graft immobilization which is effective, fast, and economical.

The method which uses a skin stapler and linen threads for bolster dressing is described here.

The skin graft is placed over the prepared recipient bed and fixed in the following manner. A free linen tie is placed over the margin of the wound, with one end long and the other end short but adequately long to hand tie a surgical knot, and the stapler is fired over the thread, fixing it to the graft and the bed (►Fig. 1).

A surgical knot is then tied over the staple (►Fig. 2).

The required number of such linen ties and staples are placed over the margin radially.

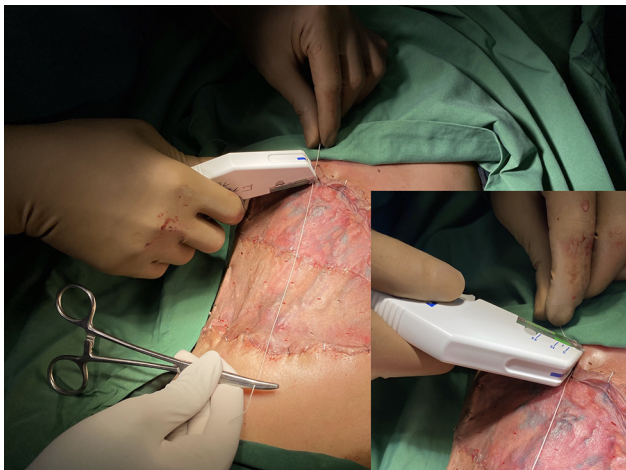
A bolster dressing is placed over the graft, and the linen ties are tied over it in the usual manner (►Fig. 3).

The traditional method of graft immobilization uses multiple sutures taken with a swaged needle and tied over a bolster dressing. This requires multiple foils of suture material, which is expensive and time-consuming.

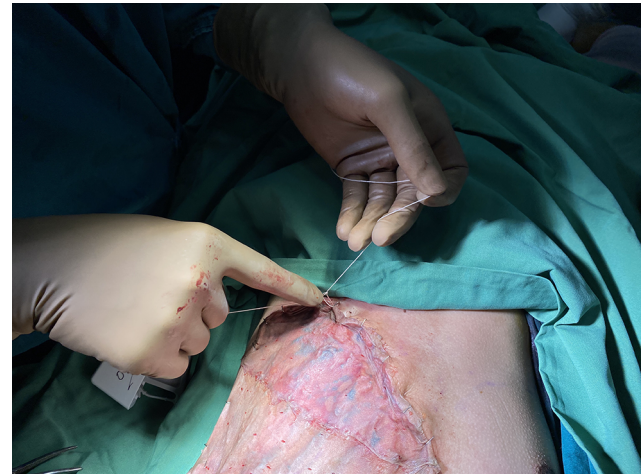A glove technique has also been described recently,<sup>2</sup> in which a sterile glove is cut open and is fixed with staples outside one margin of the grafted wound, stretched over a cotton bolster, and then fixed outside the opposite margin.

A modified bolster dressing with the use of continuous suction is also described in literature.<sup>3</sup>

We have found the described “stapler and linen” technique to be quick, economical, and simple, as linen ties are



**Fig. 1** Linen tie being placed across while the staple is being applied.



**Fig. 2** Surgical knot tied with the linen thread over the staple.

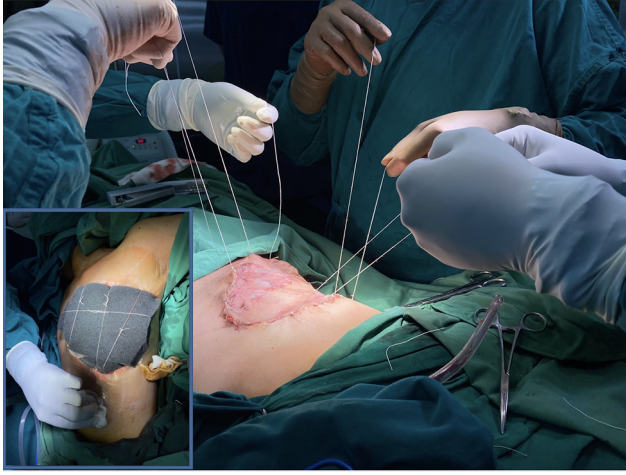
published online  
September 16, 2021

DOI <https://doi.org/10.1055/s-0041-1734581>  
ISSN 0970-0358

© 2021. Association of Plastic Surgeons of India.

This is an open access article published by Thieme under the terms of the Creative Commons Attribution-NonDerivative-NonCommercial-License, permitting copying and reproduction so long as the original work is given appropriate credit. Contents may not be used for commercial purposes, or adapted, remixed, transformed or built upon. (<https://creativecommons.org/licenses/by-nc-nd/4.0/>).

Thieme Medical and Scientific Publishers Pvt. Ltd. A-12, 2nd Floor, Sector 2, Noida-201301 UP, India



**Fig. 3** Multiple linen ties taken; inset shows the same tied over bolster dressing.

readily available in any OT, and the stapler is usually already in use in the procedure.

#### **Financial Support and Sponsorship**

Nil.

#### **Conflicts of Interest**

There are no conflicts of interest.

#### **References**

- 1 Hoffman HT, La Rouere M. A simple bolster technique for skin grafting. *Laryngoscope* 1989;99(5):558–559
- 2 Singh S, Bhatt YC, Doshi P, Vaghani SG. 'Glove technique' to secure skin grafts: A novel technique. *Indian J Plast Surg* 2016;49(1):127–128
- 3 Lee E, Park SI, Kim D, Jin H, Jeong HS. Modified bolster dressing with continuous suction improves skin graft survival for an oral cavity wound. *J Otolaryngol Head Neck Surg* 2018;47(1):68