



# Intracranial Textiloma: Imaging Features and Literature Review

Vivek Agarwal<sup>1</sup> Sameer Vyas<sup>1</sup> Chirag Kamal Ahuja<sup>1</sup> Vikas Bhatia<sup>1</sup> Manjul Tripathi<sup>2</sup>  
Pravin Salunke<sup>2</sup> Manoj Kumar Tewari<sup>2</sup>

<sup>1</sup>Department of Radiodiagnosis and imaging, Postgraduate Institute of Medical Education and Research (PGIMER), Chandigarh, India  
<sup>2</sup>Department of Neurosurgery, Postgraduate Institute of Medical Education and Research (PGIMER), Chandigarh, India

**Address for correspondence** Sameer Vyas, MD, DM, Department of Radiodiagnosis and Imaging, PGIMER, Chandigarh 160012, India (e-mail: sameer574@yahoo.co.in).

Indian J Radiol Imaging 2021;31:441–444.

## Abstract

**Background and Importance** Intracranial textilomas are retained surgical sponges presenting as pseudomass lesions in postoperative patients usually with surrounding inflammatory reaction. Though rare, these are commonly misdiagnosed as postoperative hemorrhagic collections, abscesses, radionecrosis, or residual/recurrent mass lesions. We describe the imaging findings of intracranial textilomas diagnosed in four patients on follow-up postoperative imaging along with their characteristic imaging findings to help radiologists/neurosurgeons make accurate diagnosis.

**Clinical Presentation** One patient had chronic headache without any focal neurological deficits. Rest of the patients were asymptomatic at the time of presentation

**Conclusion** In postoperative scans, possibility of textilomas should be considered apart from residual/recurrent lesions, postoperative abscesses, or radionecrosis. Correct and timely diagnosis is important for further treatment planning and patient care.

## Keywords

- ▶ textiloma
- ▶ surgical sponges
- ▶ pseudomass
- ▶ postoperative

## Background and Importance

Intracranial textilomas are retained surgical sponges, kept by the surgeon for filling the postoperative space and achieving hemostasis, presenting as pseudomass lesions in postoperative patients usually with surrounding inflammatory reaction. Though textiloma is often used interchangeably with gossypiboma, some case reports use the later term when there is foreign body reaction surrounding the retained sponges.<sup>1-3</sup> Intracranial textilomas are very rare with only few case reports available in literature.<sup>4</sup> Through this article we intend to describe the spectrum of imaging findings in intracranial textilomas through clinicroadiological discussion of four postoperative cases. We took our institutional ethical committee clearance for this study.

## Clinical Presentation

### Case 1

A 45-year-old female patient presented with complaints of headache and occasional vomiting. Magnetic resonance imaging (MRI) showed well-defined extra-axial enhancing mass lesion in right parafalcine region possibly representing large meningioma (▶ **Fig. 1A**). Patient underwent craniotomy with excision of the lesion. Bipolar cautery was used to achieve hemostasis and a single gelatin sponge was kept in the operative cavity. Patient had uneventful postoperative course. Follow-up imaging was done after 3 months of surgery. She was completely asymptomatic on follow-up. Follow-up computed tomography (CT) scan showed ill-defined hyperdense lesion in right frontal region at the site of surgery

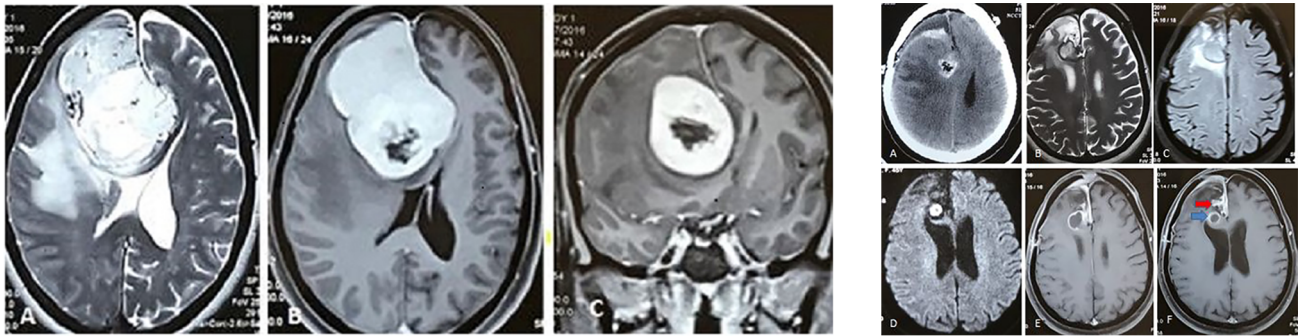
published online  
July 27, 2021

**DOI** <https://doi.org/10.1055/s-0041-1733815>  
**ISSN** 0971-3026

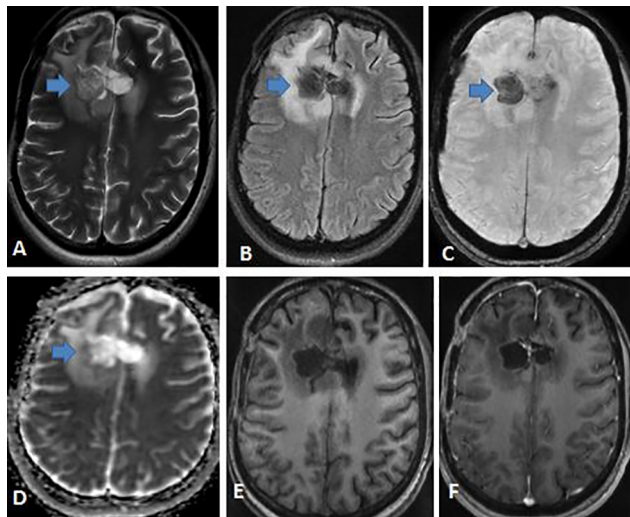
© 2021. Indian Radiological Association.

This is an open access article published by Thieme under the terms of the Creative Commons Attribution-NonDerivative-NonCommercial-License, permitting copying and reproduction so long as the original work is given appropriate credit. Contents may not be used for commercial purposes, or adapted, remixed, transformed or built upon. (<https://creativecommons.org/licenses/by-nc-nd/4.0/>).

Thieme Medical and Scientific Publishers Private Ltd, A-12, Second Floor, Sector -2, NOIDA -201301, India



**Fig. 1** (a) Pre-operative MRI Images. Axial T2-weighted image (A), axial (B) and Coronal (C) post-contrast T1-weighted images shows large well defined extra-axial hyperintense lesion in right para-falcine frontal region causing mass effect over brain parenchyma and surrounding vasogenic edema. The lesion shows intense enhancement with non-enhancing component on inferomedial aspect of lesion. (b) Pre-operative MRI Images. Axial NCCT image (A) at the level just above the ventricles shows post-operative changes as craniotomy and subdural hypodense collection in right frontal region. There is relatively well defined hyperdense lesion with interspersed air foci at the operative site. Axial T2W (B) and Axial FLAIR (C) images shows similar post-operative changes in right frontal region. The lesion appears well defined with central hyperintense signal intensity and peripheral hypointense capsule. Axial DWI (D) shows intense restriction in central part of the lesion which was hypointense on ADC images. Axial post contrast (E and F) T1-images shows thick smooth peripheral enhancement in the lesion (blue arrow). Also noted is thick anterior falcine and frontal convexity pachymeningeal enhancement with residual homogeneously enhancing lesion in right parafalcine region (red arrow).



**Fig. 2** Post-operative MRI images. Axial T2W (A) and axial FLAIR (B) images show post-operative gliotic changes in right frontal region. There is a well-defined centrally T2 hyperintense lesion with peripheral hypointense rim and internal hypointense T2 striations at the operative site in right frontal region. It is hypointense on FLAIR image (blue arrows). Axial SWI (C) image shows peripheral susceptibility changes within the lesion. Axial ADC image (D) shows mild diffusion restriction in the peripheral part of the lesion. Axial pre- (E) and post-contrast (F) images shows smooth peripheral enhancement of the lesion.

with few interspersed air foci and surrounding edema. MRIs revealed new lesion that was relatively well-defined T2/fluid-attenuated inversion recovery (FLAIR) isohyperintense with peripheral hypointensity in right frontal convexity with surrounding mild vasogenic edema. The lesion showed peripheral post-contrast enhancement (►Fig. 1B). The size of the lesion correlated with the size of the gelatin sponge kept as a homeostatic device in the operative cavity. Also noted was residual right parafalcine homogeneously enhancing lesion. Since the patient was asymptomatic, no

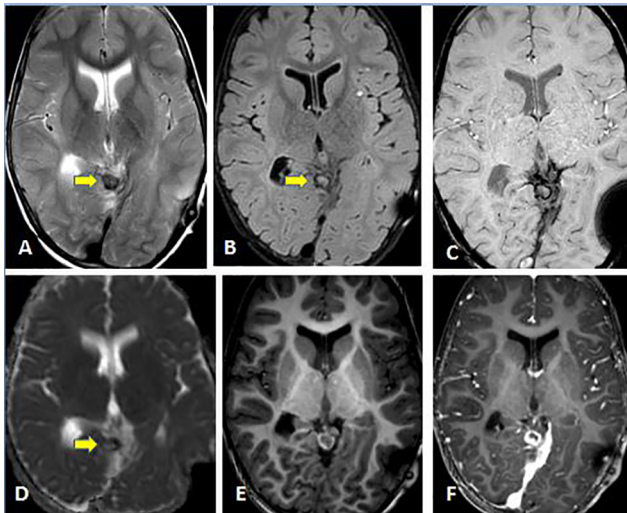
further management was advised and patient was called up for routine follow-up imaging after 6 months.

### Case 2

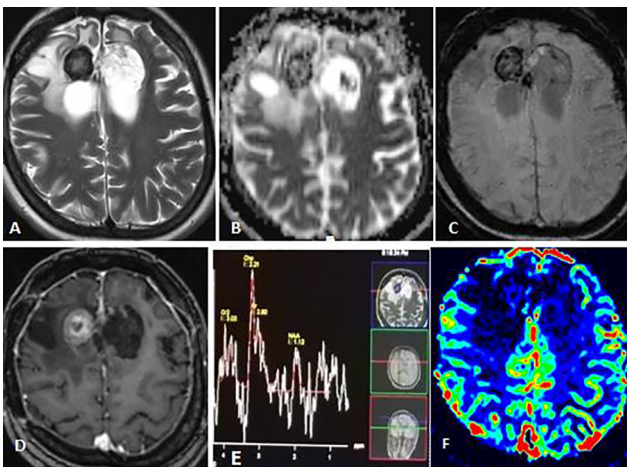
A 42-year-old female patient presented with chief complaints of chronic headache and a single episode of seizures. MRI revealed an ill-defined infiltrating mass lesion in right frontal region. Patient underwent craniotomy with partial excision of the mass lesion. Hemostasis in the post-operative cavity was achieved using Surgicel (oxidized cellulose) and fibrin sealant. Histopathology revealed anaplastic astrocytoma. Follow-up MRI after 3 months revealed postoperative substance defect in right frontal region with a relatively well-defined intra-axial T2/FLAIR hyperintensity and T1 hypointensity at the operative site. The lesion showed internal T2 hypointense striations, mild susceptibility changes, and peripheral diffusion restriction. There was smooth peripheral contrast enhancement. CT images showed hyperdense lesion with interspersed air foci (►Fig. 2). The size of the lesion was smaller than the size of the Surgicel kept in the operative cavity.

### Case 3

A 3-year-old female child was operated for superior cerebellar pilocytic astrocytoma. No operative details were available. She was asymptomatic after 1 year of surgery. Follow-up MRI after 3 months revealed relatively well-defined intra-axial T2/FLAIR peripherally hypointense and T1 mildly hyperintense lesion at the operative site. The lesion showed peripheral susceptibility changes and mild diffusion restriction. There was thick smooth peripheral post-contrast enhancement (►Fig. 3). No perfusion was noted within the lesion and MR spectroscopy showed decreased N-acetylaspartate (NAA) level. Since the lesion was present at the operative site with MRI signal characteristics typical of homeostatic devices and different from the original lesion, possibility of the textiloma was kept. Patient remained asymptomatic with no increase



**Fig. 3** Post-operative MRI Images. Axial T2W (A) and axial FLAIR (B) images shows well defined hypointense lesion with peripheral hypointense capsule in superior cerebellar vermis at the operative site (yellow arrow). Axial SWI image (C) shows peripheral susceptibility changes within the lesion. Axial ADC image (D) shows diffusion restriction in central part of the lesion (arrow). Axial pre- (E) and post-contrast (F) T1-images shows thick smooth peripheral enhancement of the lesion. Also noted is thick enhancement of left sided tentorium.



**Fig. 4** Post-operative MRI Images. Axial T2WI (A) shows well defined peripherally hypointense lesion at the operative site in right frontal region. Axial ADC image (B) shows diffusion restriction in central part of the lesion. Axial SWI image (C) shows peripheral susceptibility changes within the lesion. Axial post-contrast T1-image (D) shows well defined hyperintense lesion with thick smooth peripheral enhancement. Single voxel MR Spectroscopy (E, TE-135) shows raised Cho/Cr and decreased NAA/Cr ratios. F) Axial perfusion image (F, relative cerebral blood volume map) shows reduced perfusion in the lesion.

in the size of the lesion/hemostatic device on follow-up MRI after 6 months.

#### Case 4

A 46-year-old female patient presented with chief complaints of headache, vomiting, and seizures. MRI showed intra-axial infiltrating T2/FLAIR hyperintense mass lesion with patchy

areas of enhancement involving bilateral superior frontal lobes. Frontal craniotomy and excision of mass were done. As in previous case, postoperative cavity was filled with Surgical (oxidized cellulose) and fibrin sealant to achieve hemostasis. Histopathology revealed infiltrating astrocytoma. Patient presented with mild headache. Follow-up MRI after 3 months revealed new lesion that was relatively well-defined intra-axial T2/FLAIR isohyperintense lesion with peripheral hypointensity in right frontal lobe with surrounding mild vasogenic edema. The lesion that appeared T1 hyperintense showed central diffusion-weighted imaging (DWI) restriction, peripheral susceptibility changes, and thick peripheral post-contrast enhancement. The lesion showed no perfusion. MR spectroscopy showed decreased NAA levels with elevated Cho/Cr ratios (→ Fig. 4). After consultation with the neurosurgeon, it was apparent that the size of the lesion matched the size of the Surgical kept in the operative cavity. Based on the appearances, possibility of textiloma was kept and follow-up MRI after 6 months was advised.

#### Discussion

Assessment of postoperative follow-up MRI scans in patients operated for intracranial mass lesions requires thorough knowledge of the hemostatic agents used to prevent repetitive hemorrhages. Different agents used such as simple cotton gauze, cellulose, gelatin sponges, oxidized cellulose (Surgicel), Gelfoam wafers, or collagen tissue have different MRI appearances that can be easily confused with residual or recurrent mass lesion especially to inexperienced eye. Most of the cases of textilomas reported in literature were mostly seen after abdominopelvic surgery with only limited literature available for intracranial textilomas.<sup>5</sup> Surgicel is a hemostatic agent (blood-clot-inducing material) made of an oxidized cellulose polymer (the unit is polyanhydroglucuronic acid).

Although mostly used as hemostatic agents to prevent recurrent bleeds at the operative site, these agents are notorious for eliciting acute foreign body inflammatory changes around them. These acute changes gradually turn into subacute to chronic type noncaseating granulomatous inflammatory reaction.<sup>6,7</sup> This results in a demarcated inflammatory pseudomass that is easily confused with post-chemoradiotherapy changes on postoperative MRI scans. The lesions in fibrotic stages are asymptomatic and are detected incidentally on follow-up scans, while lesions in exudative phase might become symptomatic in early postoperative period or later depending on their location and size.<sup>8</sup> Here, we describe radiological appearances of these hemostatic agents to help our radiology colleagues differentiate them from other lesions. Since these were left purposely for hemostasis, no further management was needed in any case. No follow-up scan was done in any case.

MRI appearances might vary depending on the type of material left, timing of MRI scan, and the location of the hemostatic agent.<sup>4</sup> On conventional sequences, most of these agents appear as well demarcated focal lesions mostly hypointense on T1-weighted (T1W) sequence. Signal changes

on T2W images could be hyperintense–hypointense depending on the fluid and protein contents. According to literature, there is usually a peripheral T1 and T2 hypointense fibrotic capsule that shows enhancement on post-contrast images.<sup>7,9</sup> Sometimes, internal linear T2W hypointense signal can be seen in hyperintense lesion representing fibers of gauze material.<sup>10</sup> Some case reports are available where the patients were operated again and histopathology showed granulomatous inflammatory reaction.<sup>7,11</sup> Differentiating textilomas from recurrent/residual lesions or post-radiochemotherapy changes requires comparison of the imaging characteristics with preoperative imaging and use of advanced MRI modalities like MR perfusion imaging and MR spectroscopy. Though MRI is very helpful in diagnosing textilomas, histopathology correlation may be needed in equivocal or questionable cases.<sup>12</sup> CT scan may also add up to the diagnosis of textilomas.<sup>13</sup>

Similar findings were noted in all our cases. The lesions, in our cases, were, however, more hyperintense on T1-weighted imaging and showed DWI restriction representing proteinaceous internal contents. Also, there was surrounding vasogenic edema with mild mass effect. Thick peripheral T2 hypointensity representing fibrotic capsule was seen in our cases. Dynamic susceptibility contrast perfusion done in our cases revealed perfusion defects without raised cerebral blood volume and cerebral blood flow parameters. MR spectroscopy findings were not specific. MR spectroscopy done in three cases showed decreased NAA levels with increased Cho/Cr ratios. After consultation with the operating neurosurgeon, it was apparent that the size of the lesions approximately matched the size of the hemostatic agents kept in the operative cavity. CT scan done in two of our patients revealed well-defined hyperdense masses with interspersed air foci as has been described in literature.<sup>13,14</sup>

The final diagnosis of the intracranial textiloma should be made after consultation with the operating neurosurgeon, comparison with the preoperative imaging, looking at post-operative CT scans, use of advanced MRI sequences like perfusion, diffusion, and MR spectroscopy and histopathology in questionable cases to reach the final diagnosis especially if it has a medico-legal relevance.

## Conclusion

Postoperative brain imaging is challenging. Intracranial hemostatic sponges are commonly used nowadays and seen on the scan as “textilomas”; these can mimic residual/recurrent lesions, postoperative abscesses, or radionecrosis. Careful clinical history and discussion with surgeon before the evaluation of preoperative imaging and use of different modalities can help reach the diagnosis and avoid pitfalls. Correct and timely diagnosis is important for further treatment planning and patient care.

## Disclaimer

The authors do not have any personal or institutional financial interest in drugs, materials, or devices described in their submissions.

The authors certify that this manuscript is a unique submission, has not been submitted and is not being considered for publication by any other source in any medium, and has not been published, in part or in full, in any form.

## Conflicts of Interest

No conflicts of interest financial or personal.

## References

- 1 Tringali G, Broggi M, Didato G, et al. Textiloma mimicking an intracranial postoperative abscess. *J Neurol Disord* 2015;3:213
- 2 Kucukyuruk B, Biceroglu H, Abuzayed B, Ulu MO, Kafadar AM. Paraspinal gossypiboma: a case report and review of the literature. *J Neurosci Rural Pract* 2010;1(2):102–104
- 3 Williams RG, Bragg DG, Nelson JA. Gossypiboma—the problem of the retained surgical sponge. *Radiology* 1978;129(2):323–326
- 4 Akpınar A, Ucler N, Ozdemir CO. Textiloma (gossypiboma) mimicking recurrent intracranial abscess. *BMC Res Notes* 2015;8:390
- 5 O'Connor AR, Coakley FV, Meng MV, Eberhardt SC. Imaging of retained surgical sponges in the abdomen and pelvis. *AJR Am J Roentgenol* 2003;180(2):481–489
- 6 Guerin C, Heffez DS. Inflammatory intracranial mass lesion: an unusual complication resulting from the use of Gelfoam. *Neurosurgery* 1990;26(5):856–859
- 7 Apel-Sarid L, Cochrane DD, Steinbok P, Byrne AT, Dunham C. Microfibrillar collagen hemostat-induced necrotizing granulomatous inflammation developing after craniotomy: a pediatric case series. *J Neurosurg Pediatr* 2010;6(4):385–392
- 8 Apter S, Hertz M, Rubinstein ZJ, Zissin R. Gossypiboma in the early post-operative period: a diagnostic problem. *Clin Radiol* 1990;42(2):128–129
- 9 Atabey C, Turgut M, Ilica AT. Retained surgical sponge in differential diagnosis of paraspinal soft-tissue mass after posterior spinal surgery: report of eight cases. *Neurol India* 2009;57(3):320–323
- 10 Nassar I, Mahi M, Semlali S, et al. Textilome intracrânien. *J Neuroradiol* 2004;31(2):148–149
- 11 O'Shaughnessy BA, Schafernak KT, DiPatri AJ Jr, Goldman S, Tomita T. A granulomatous reaction to Avitene mimicking recurrence of a medulloblastoma. Case report. *J Neurosurg* 2006;104(1(Suppl)):33–36
- 12 Renati S, Kaur S, Kresak JL, Wicklund M, Malaty I. Granulomatous meningitis secondary to Avitene (microfibrillar collagen). *Neurol Clin Pract* 2017;7(5):384–386
- 13 Coche G, Pardonnet MH, Chanois AM, et al. [Ultrasonography and x-ray computed tomography in the diagnosis of intra-abdominal textiloma. Apropos of 12 cases]. *J Radiol* 1988;69(4):243–251
- 14 Marquardt G, Rettig J, Lang J, Seifert V. Retained surgical sponges, a denied neurosurgical reality? Cautionary note. *Neurosurg Rev* 2001;24(1):41–43