



# The “Shirt Pocket” Technique—An Alternative for Augmentation-Mastopexy

Marcus Vinícius Jardini Barbosa<sup>1</sup> Paulo Henrique Costa de Souza<sup>2</sup> Fábio Xerfan Nahas<sup>3</sup>  
Lydia Masako Ferreira<sup>3</sup>

<sup>1</sup>The Morphofunctional Laboratory of the Scholl of Medicine of the University of Franca, São Paulo, Brazil

<sup>2</sup>Department of Plastic Surgery, Franca, São Paulo, Brazil

<sup>3</sup>Division of Plastic Surgery of the Federal University of São Paulo, São Paulo, Brazil

**Address for correspondence** Marcus Vinícius Jardini Barbosa, MD, PhD, Alameda dos Flamboyants, 700 – Morada do Verde, Zip code, 14404-409, Franca – SP, Brazil (e-mail: drmbarbosa@gmail.com.br).

Indian J Plast Surg 2021;54:362–366.

## Abstract

Augmentation-mastopexy is a frequent procedure with high rates of early recurrence of breast ptosis, mainly after subglandular approach. The dual-plane techniques, based on the cranial dissection of the pectoralis, is the most used, but this plane does not cover the inferior pole of the breast. Then, the possibility of a downward dissection of the muscle seems to be more reasonable to retain the implant and improve postoperative results. This study aimed to review the anatomy of the pectoralis in cadavers and the use of its downward dissection to create a pocket for breast implant as a “shirt pocket.” This maneuver was associated with a superior-based dermoglandular flap to overprotect the inferior pole. No complications were related in the postoperative period. The anatomic review showed that the “shirt pocket” is a safe option if done carefully. The technique demonstrated to be feasible and seemed to be effective, being another alternative to prevent early recurrence of breast ptosis in these procedures.

## Keywords

- ▶ breast
- ▶ breast implants
- ▶ plastic surgery
- ▶ mammoplasty
- ▶ pectoralis muscle

## Introduction

Augmentation-mastopexy is one of the most frequent surgical procedures in plastic surgery practice.<sup>1</sup> Despite the several described surgical techniques to achieve the best pocket plane in these kind of procedures, early postoperative glandular ptosis is a very common and undesirable event, which promotes frustration for both patients and plastic surgeons.<sup>2</sup> It is also known that the subglandular technique is more likely to have this type of complication.<sup>1</sup> Thus, several surgical tactics have been described to achieve a long-lasting result, with better maintenance of the breast shape.<sup>3,4</sup> Among these procedures, the most used are the dual-plane techniques which are based on the cranial dissection of the pectoralis major muscle to create the implant pocket.<sup>1-3,5</sup> To improve their results, Graf et al described

the use of the deep fascia of the pectoralis to cover breast implants.<sup>6</sup> They highlighted that the subfascial approach allowed soft-tissue coverage of the superior pole without the downside of raising the muscle. Despite the improvement in results, the fact is that the lower pole of the breast does not remain protected by the fascia or musculature, as the anatomy of the pectoralis major muscle does not allow full coverage of the implant.<sup>5</sup> This characteristic keeps the inferior pole of the breast (now with an implant) more vulnerable to an early recurrence of ptosis of the set gland and implant, in addition to other complications such as dehiscence and exposure of the implant. The idea of the proposed technical variation occurred, as some patients presented recurrence of breast ptosis after subglandular augmentation-mastopexy in a relatively early postoperative period (around 3–6 months).

**published online**  
September 17, 2021

**DOI** <https://doi.org/10.1055/s-0041-1733807>  
**ISSN** 0970-0358

© 2021. Association of Plastic Surgeons of India.

This is an open access article published by Thieme under the terms of the Creative Commons Attribution-NonDerivative-NonCommercial-License, permitting copying and reproduction so long as the original work is given appropriate credit. Contents may not be used for commercial purposes, or adapted, remixed, transformed or built upon. (<https://creativecommons.org/licenses/by-nc-nd/4.0/>).

Thieme Medical and Scientific Publishers Pvt. Ltd. A-12, 2nd Floor, Sector 2, Noida-201301 UP, India

Considering the anatomy of the pectoralis and its intersection with other muscles of the anterior chest wall, the dissection of the lower third of the muscle, as a “shirt pocket” associated with a thin superior-based dermoglandular flap, seems to be reasonable to prevent these complications by protecting the inferior pole when breast augmentation-mastopexy is performed.<sup>5-8</sup> Then, the purpose of this study was to review the anatomy of the pectoralis major and the application of the inferior dissection of the lower third of the muscle to create a pocket for breast implant as a “shirt pocket.”

## IDEA

### Anatomy Review

A cadaver dissection was performed to revise the local anatomy and the viability of this kind of dissection. With the cadaver in supine position, the anterior axillary line, the medial aspect of the sternal and the inframammary fold was marked as a reference point. A parasternal incision was made and carried parallel to the anterior axillary line from the superior pole of the breast until the inframammary fold level. Skin was dissected from the pectoralis fascia by sharp dissection. The subglandular dissection was performed superiorly until the superior pole, laterally until the anterior axillary line and inferiorly until the inframammary fold. The muscle split dissection begins in the inferior third of the pectoralis, considering its total length until the projection of the inframammary fold, medially to the lateral edge of the sternum, where the muscle fibers were split with blunt dissection. All of the vessels and nerves were observed to determine the limitations of the dissections as well as the areas that surgeons must take care. The inferior submuscular pocket was created by lifting the split muscle to accommodate the implant (→ Fig. 1). Meticulous care was required medially to avoid damage of the internal mammary perforators.

### Preoperative Marking

With the patient in the sitting position, the standard landmarks were marked (midline, midclavicular point, inframammary fold, and the breast meridian). The point “A” was marked on the breast meridian, using the anterior projection of the inframammary fold as a reference to position of a Strömbeck’s pattern to finish the breast marking as described by Barbosa et al.<sup>9</sup>

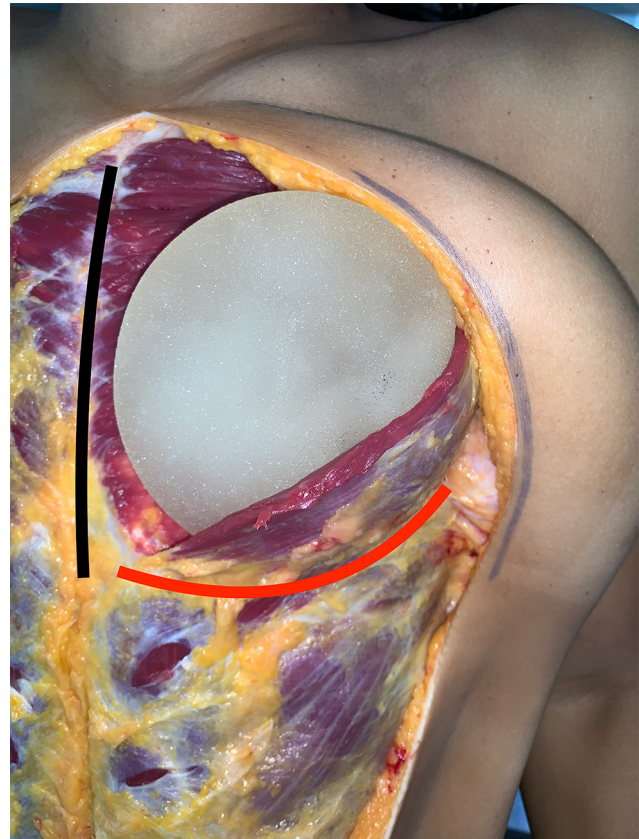
### Surgical Technique

#### Position and Anesthesia

With the patient in a 30° supine position and after sedation with intramuscular (IM) midazolam and intravenous (IV) fentanyl, a local injection of 2% lidocaine with 1:100,000 epinephrine (40 mL), diluted in 1000 mL of saline solution, was administered. The surgery was conducted as follows:

#### Step 1

The nipple-areola complex (NAC) was marked with a circular pattern (5 cm in diameter) and the Schwartzman maneuver



**Fig. 1** Cadaver dissection. A female cadaver had the left pectoralis dissected as a “shirt pocket,” and a 280 mL breast implant was included (black line = midline/red line = left inframammary fold level).

was done. Deepithelialization of the skin between the previously marked areas was done, and the breast tissue was incised medially and laterally at the pattern’s limbs level until the pectoralis fascia.

#### Step 2

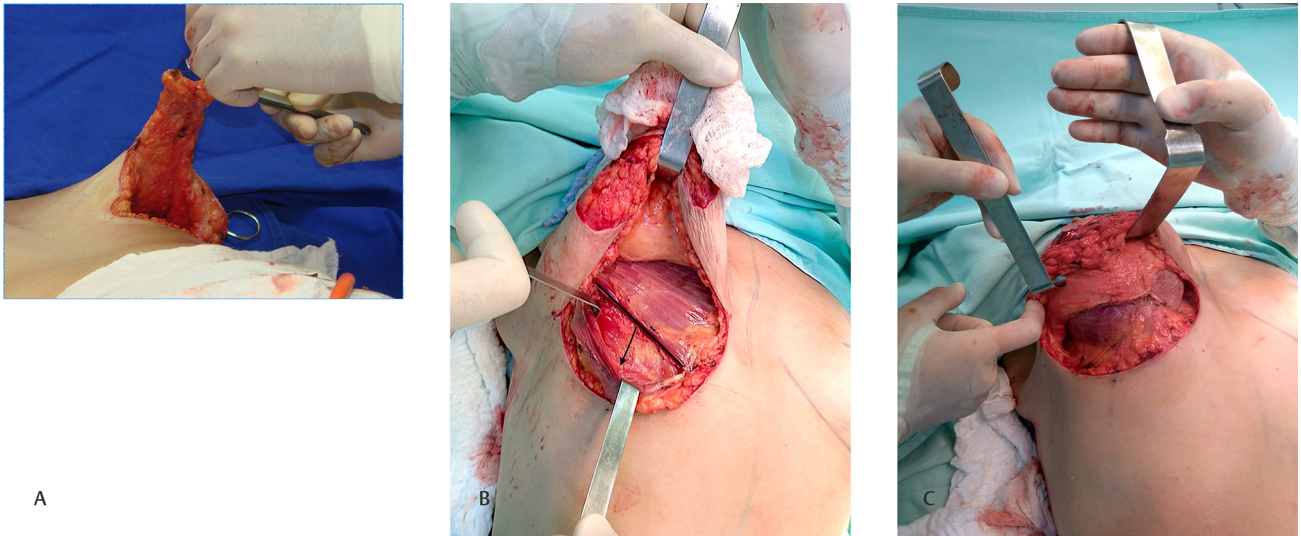
Breast tissue was incised, beginning 4 to 5 centimeters below the inferior part of the NAC to create the superior pedicle. Then, a glandular resection is done centrally in an amount sufficient to make the NAC free to ascend and for an adequate implant accommodation, leaving a thin (~1-cm thick) superior-based dermoglandular flap (→ Fig. 2 A).

#### Step 3


The pectoralis muscle was dissected inferiorly, until the inframammary fold, as a “shirt pocket” to accommodate a high-profile implant (→ Fig. 2 B). The superior margin of the pocket was sutured to the breast tissue at the level of the inferior projection of the NAC (→ Fig. 2 C).

#### Step 4

The NAC was placed on its new position by a 4-0 nylon suture. The extremities of the superiorly based dermoglandular flap were inferiorly and deeply sutured to the pectoralis fascia, at the level of the inframammary fold, with a 2-0 nylon suture as an additional cover of the set implant muscle (→ Fig. 3 A). Step 5



**Fig. 2** Steps of the “shirt pocket” technique. Intraoperative aspect of the “shirt pocket” (A) The superior-based pedicle flap to be sutured at the deeply aspect of the inframammary fold. (B) Dissection of the pectoralis—arrow indicates the inferiorly direction of the muscle pocket. (C) Implant inside the pocket and sutured at the level of the inferior projection of the nipple-areola complex (NAC) of the breast.



**Fig. 3** Schematic drawing of the operative technique. (A) Fixation of the superiorly based dermoglandular flap to the pectoralis fascia at the level of the inframammary fold. (B) Suture of the medial and lateral pillars, with the fixation of their lower pole to the inframammary area, overlapping the dermoglandular flap (B).

A U-shaped 4-0 nylon suture was done to close the superior corners of the medial and lateral skin flaps. The medial and lateral pillars were brought together, and then the lower pole of them were sutured to the inframammary area by a 3-0 nylon suture, overlapping the dermoglandular flap (→Fig. 3 B). Sutures were finished by planes, resulting in an inverted “T-” scar.

### Clinical Application

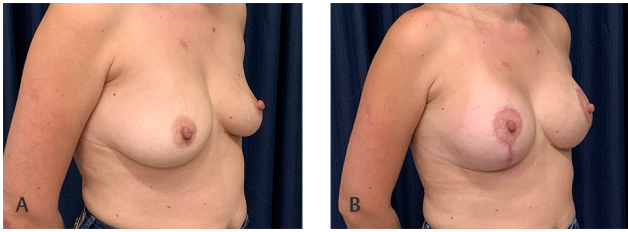
The “shirt pocket” technique was performed on four patients ( $n = 4$ ) as described above. Two of them ( $n = 2$ ) were secondary to a previous mastopexy, with implants due to early postoperative ptosis, and two ( $n = 2$ ) was primary mastopexy with implant. The average implant size ranged from 280 mL

to 375 mL. The mean follow-up period was 15 months (range, 12–20 months). The length of the vertical scar ranged from 4.0 cm to 5.5 cm (average length of 4.7 cm). There were no complications related to the anesthetic or surgical procedure during the postoperative period.

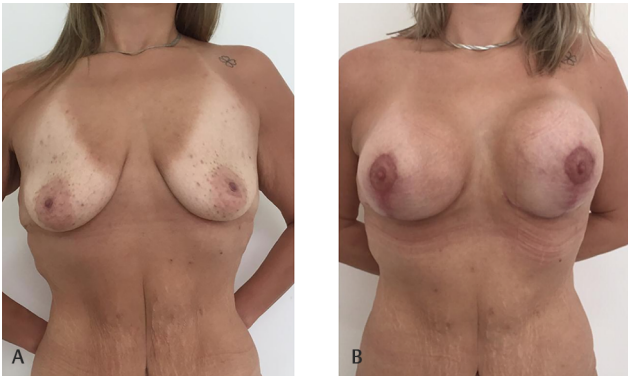
The outcome of the technique is illustrated in ►Figs. 4 and 5.

### Discussion

Augmentation-mastopexy is one of the most challenging breast surgery procedures.<sup>3</sup> The main goal of the procedure is to restore the normal anatomic parameters, enhance breast size, reduce skin envelope, and maintain the physiological function.<sup>10</sup> However, this procedure frequently



**Fig. 4** A 38-year-old patient who presents breast hypomastia and ptosis grade II. (A) Preoperative right oblique view. (B) 12-months postoperative right oblique view.



**Fig. 5** A 48-year-old white female who presents breast ptosis 7 months after mastopexy with implant. (A) Preoperative frontal view. (B) 20-month postoperative frontal view.

requires retouch or reoperation (~8–28%), mainly because of early postoperative recurrence of the glandular ptosis.<sup>2,7,11</sup> Early recurrence may occur due to the submuscular approach, creating the double-bubble deformity, or after the pure subglandular approach, which was increased after the recommendation for using smooth implants to avoid the breast implant-associated anaplastic large cell lymphoma (BIA-ALCL).<sup>12</sup>

According to the literature, many techniques and surgical maneuvers have been described in an attempt to avoid or slow up complications.<sup>1–3,5,7,10,11</sup> Graf et al highlighted that the use of the pectoralis fascia is more effective to cover breast implants by giving an additional soft-tissue coverage of the superior pole of the breast.<sup>6</sup> Considering the subglandular approach, Mansur and Bozola described the use of an inferior pedicle flap to protect and provide support of the inferior aspect of the breast when augmentation-mastopexy is performed.<sup>4</sup> However, the subfascial or submuscular approach, called dual-plane technique, seems to be more effective.<sup>5,6,10,11</sup>

Since its initial description, the dual-plane technique has been modified to improve postoperative results and minimize common complications after the subglandular approach. Khan reached the superior aspect of the pectoralis muscle without its release from the costal margin. He concluded that for adequate cover of the implant, only the upper part of the pectoralis major muscle is required.<sup>13</sup> Ono and Karner performed a submuscular pocket with a lateral muscle sling to receive the implant before resection and lift the breast with good results.<sup>2</sup> Borestein and Abrahami proposed

a median myotomy at the most tensioned part of the pectoralis major muscle to avoid postoperative double-bubble complications or waterfall deformity. They also stated that the dual-plane approach is a better way to perform breast augmentation than subglandular procedures, and it should be the default approach for mastopexy with implants.<sup>14</sup> Siclovian and Nistor modified the dual-plane technique by performing and internal mastopexy in patients with grade I ptosis.<sup>15</sup> The main point to be highlighted is that all of these techniques are correctly based on an adequate coverage of the implant. However, most patients who present for this type of procedure do not have good quality skin of the breast. This is an important feature for maintaining the postoperative result over time. When this aspect is considered, we will realize that the lower pole of the breast is the main point of weakness. Therefore, if we have a surgical technique that allows better protection of the lower pole with autologous tissue, this certainly will promote a better retention of the implant, reducing the possibility of an early recurrence of ptosis. This aspect motivated the development of the presented technique.

There is only one study that described the use of the inferior aspect of the pectoralis muscle to protect and retain the implant, in order to minimize early postoperative breast ptosis.<sup>7</sup> Although this technique has been described almost simultaneously with the present proposal, there is a difference between them, which is represented by the additional dermoglandular flap over the muscle-implant complex, ensuring greater protection of the lower pole. The flap is thin, based superiorly and its length is approximately 5 cm from the lower end of the NAC to avoid restriction to its ascension.

In the present study, the anatomic review was done to verify the real possibility of the described maneuver and evaluate risks and limitations. Saleh, Callear and Riaz, in an anatomic study, highlighted that major nerve injury and poor implant coverage would be likely if the initial muscle split is made cranial to the junction of the middle and lower thirds of the sternal origin of the pectoralis major, indicating that a more cranial muscle split would likely encounter major nerves.<sup>5</sup> The medial pectoral nerve is located medially to the axillary artery and in 88% takes its origin from the medial cord of the brachial plexus. The medial pectoral nerve mostly innervates caudal segments of the muscle and care must be taken with the vascularization because, in most cases, the lateral thoracic artery goes with the medial pectoral nerve and should be regarded as a factor of a potential risk of injury during surgical separation of the pectoralis major.<sup>8</sup> So, the “shirt pocket” seems to be a safe option if done carefully, mainly, at the medial portion.

Although all of the subfascial and submuscular approaches improved the implant stabilization and minimized the risk of capsular contracture, deformities of the contour are still possible because of the muscular contraction, and it should be considered as a limitation of the technique.<sup>7</sup>

In this study, the use of an additional superior-based dermoglandular flap to overprotect the inferior pole of the breast was based in two possible complications: displacement/rotation of the implant by muscle dynamics and wound dehiscence of the inverted T-scar with muscle exposure. It also

important to stress that the flap is approximately 4 to 5 cm in length exactly to allow both the superior translocation of the NAC and the glandular lifting. Then, it aimed to overprotect the inferior pole of the breast by overlapping the set implant pectoralis. Another resource to protect the inferior pole of the breast is the acellular dermal matrix (ADM). It has been used in reconstruction and aesthetic purposes to correct implant rippling, symmastia, and soft-tissue deficits.<sup>16</sup> However, if it is possible, the use of autologous soft tissue, such as the described dermoglandular flap, should be preferred because of the lower risk of complications.

The paper showed the experience of our group, using an inverted T-scar technique; however, this surgical approach can be used in the round-block, L-scar, and vertical scar techniques, according to the personal preference and experience, because the inferior dissection of the pectoralis major presents the same “difficulties” that surgeons may have when they do the superior undermining.

The study has some limitations like the low number of patients and the short postoperative period. In the next stage, we aim to improve the number of our series and apply a visual analogue scale to determine patient’s satisfaction.

In conclusion, the technique described demonstrated to be feasible and seemed to be effective, being another alternative to perform mastopexy with implants with less possibility of early recurrence breast ptosis or implant exposure due to dehiscence of the lower pole of the breast.

#### Conflict of Interest

The authors declare that they do not have any commercial interest in the subject of study or in the source of any financial or material support.

#### References

- 1 Khan UD. Augmentation mastopexy in muscle-splitting biplane: outcome of first 44 consecutive cases of mastopexies in a new pocket. *Aesthetic Plast Surg* 2010;34(3):313–321
- 2 Ono MT, Karner BM. Four-step augmentation mastopexy: lift and augmentation at single time (LAST). *Plast Reconstr Surg Glob Open* 2019;7(11):e2523
- 3 Khan UD. One-stage mastopexy and augmentation mammoplasty in layers: outcome analysis of first 50 consecutive cases. *Plast Aesth Res* 2018;5(45):1–14
- 4 Mansur JRB, Bozola AR. Mastopexia e aumento das mamas com proteção e suporte inferior da prótese com retalho de pedículo inferior. *Rev Bras Cir Plást* 2009;24(3):304–309
- 5 Saleh DB, Callear J, Riaz M. An anatomical appraisal of biplanar muscle-splitting breast augmentation. *Aesthet Surg J* 2016;36(9):1019–1025
- 6 Graf RM, Bernardes A, Rippel R, Araujo LR, Damasio RCC, Auersvald A. Subfascial breast implant: a new procedure. *Plast Reconstr Surg* 2003;111(2):904–908
- 7 Munhoz AM, Neto AM, Ferrari O. Single-stage augmentation mastopexy with composite reverse inferior muscle sling technique for autologous reinforcement of the inferior pole: technical refinements and outcomes. *Aesthet Surg J* 2020;40(6):NP356–NP373
- 8 Larionov A, Yotovskii P, Filgueira L. A detailed review on the clinical anatomy of the pectoralis major muscle. *SM J Clin Anat* 2018;2(3):1015
- 9 Barbosa MVJ, Nahas FX, Neto MA, Ferreira LM. Keyhole pattern for preoperative marking for reduction mammoplasty. *Can J Plast Surg* 2010;18(4):130–134
- 10 Ismail KT, Ismail MT, Ismail TA, Ismail AT, Toth BA. Triple-plane augmentation mastopexy. *Plast Reconstr Surg Glob Open* 2019;7(8):e2344
- 11 Sarosiek K, Maxwell GP, Unger JG. Getting the most out augmentation-mastopexy. *Plast Reconstr Surg* 2018;142(5):742e–759e
- 12 Barbosa MVJ. Is the use of the breast implant capsule for reconstruction safe? *Plast Reconstr Surg Glob Open* 2020;8(6):e2877
- 13 Khan UD. Muscle-splitting breast augmentation: a new pocket in a different plane. *Aesthetic Plast Surg* 2007;31(5):553–558
- 14 Borenstein A, Abrahami Y. Pectoralis major median myotomy: the median cut. *Plast Reconstr Surg* 2020;145(2):330–332
- 15 Şiclovan HR, Nistor P. Modified internal mastopexy technique in muscle splitting biplane breast augmentation. *Aesthetic Plast Surg* 2020;44(3):716–725
- 16 Macadam SA, Lennox PA. Acellular dermal matrices: Use in reconstructive and aesthetic breast surgery. *Can J Plast Surg* 2012;20(2):75–89