

## Case Report-I

# Primary Cardiac Sarcoma

SK BISHNOI, A BARDIA, V YADAV GL MEENA, S JAKHAR, S JAIN

### ABSTRACT

**Primary malignant tumours of the heart are very rare. Majority of them are highly aggressive sarcoma. Due to their rarity, evidence-based recommendations for management are lacking, therefore, treatment must be individualized. A multi-disciplinary approach is preferred in most cases.**

### INTRODUCTION

The most common types of primary cardiac tumour are- myxoma (benign) and sarcoma (malignant). Cardiac myxoma is eight times more common than cardiac sarcoma. The initial clinical presentation of both types of tumour are identical, therefore sarcoma is often misdiagnosed as myxoma. The clinical behavior of both tumours is distinct. Cardiac myxoma is benign, often completely resectable and have excellent prognosis while cardiac sarcoma is highly aggressive, often metastasize despite complete surgical excision and the overall outcome is poor. Therefore, accurate diagnosis is of vital importance.

There are only few reports of primary cardiac sarcoma from India<sup>1</sup>. It is estimated that, in a lifetime of 500 cardiac surgeons, chances are

only one would come across such a case. We report a case of primary cardiac sarcoma; the initial radiological impression was of right atrial myxoma, its malignant potential was appreciated only after patient developed pulmonary metastasis.

CASE: Mrs. KLS, age 58 years presented with complaints of dyspnoea on exertion (class II, NYHA) for last 4 months. Her routine check up done by a cardiologist 3 month back in another hospital showed pericardial effusion. Pericardial fluid analysis revealed hemorrhagic fluid which was negative for malignant cells. She was put on anti tubercular therapy (ATT) though her 2D-ECHO findings were consistent with right atrial myxoma. Since there was no improvement in pericardial effusion ATT was stopped and patient was referred to another hospital.

Patient presented with severe dyspnoea and right sided heart failure. Her physical examination revealed pulse 125/min, BP 190/100 mmHg with raised JVP, pedal edema. Systemic examination revealed loud S1 sound, hepatomegaly and left sided basal creptations. She was managed conservatively with decongestive therapy and after stabilization further investigated.

Electrocardiogram was showing 'inverted P wave' in II, III, AVF & V1-V6 leads. 3D- ECHO color Doppler studies revealed right atrial mass (unusual site for a myxoma), pericardial effusion with early feature of tamponade and pleural effusion. CT scan of chest demonstrated a large heterogeneous mass measuring 10.5x7.6x6.0 cms seen in right atrium

Acharya Tulsi Cancer Treatment and Research institute, Bikaner (Rajasthan)

Correspondence to : **S K BISHNOI**  
E-mail: drskbishnoi@rediffmail.com

completely occupying it and extending into the right ventricle and infiltrating into superior vena cava. (Fig.1A) Multiple nodular lesions seen in both lung fields suggesting metastases. FNAC smear from mass was a hyper cellular mixture of spindle shaped cells and mononucleated round to polyhedral shaped cells forming small to large tissue bits. These

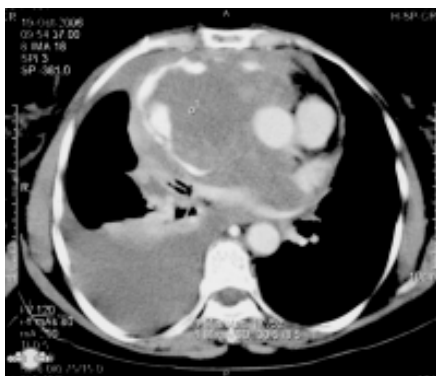


Fig-1A. Pre chemotherapy, CECT of thorax shows irregularly marginated mildly enhancing lesion in right atrium with right pleural effusion and pulmonary metastasis.

cells are seen against a toluidine blue metachromatic and PAS positive myxoid stroma. The nuclei of tumour cells are hyperchromatic irregular coarse nuclear chromatin and prominent nucleoli (Fig.2). In some of the cells it shows eccentrically placed nuclei at one end with long tapering cytoplasmic tail at the other end (comet configuration) (Fig.3). These cytological

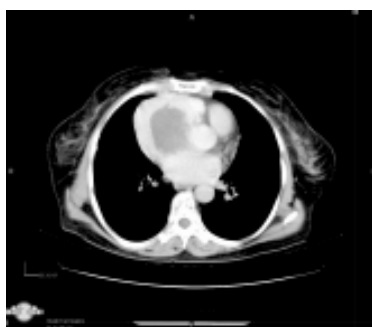


Fig-1B. Post chemotherapy CT scan of thorax shows significant reduction in size of cardiac lesion, near complete resolution of pleural effusion and pulmonary metastasis.

features are suggestive of a myxoid malignant fibrous histiocytoma.

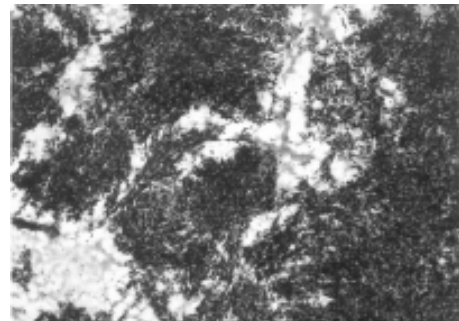


Fig-2 hyper cellular smear showing admixture of spindle shaped cells and mononucleated round to polyhedral shaped cells (H&E X 10)

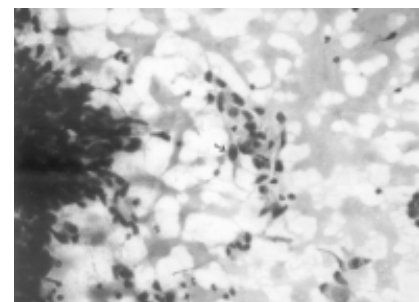


Fig-3 high power view shows cluster of cells having elongated hyperchromatic nuclei with irregular coarse nuclear chromatin and prominent nucleoli in some of the cells( marked with arrow) the nuclei are eccentrically placed at one end with long tapering cytoplasmic tail at the other end 'comet configuration' ( H&E X 45)

With diagnosis of primary cardiac sarcoma (most likely malignant fibrous histiocytoma) with pulmonary metastasis. She was put on palliative chemotherapy consisting of cyclophosphamide, vincristine, Epirubicin, and Dacarbazine. She had good symptomatic improvement. After 3 cycle of chemotherapy CT scan of chest demonstrated nearly 70% regression of primary tumour and complete resolution of pericardial and pleural effusion. (Fig 1B)

## DISCUSSION

The most common malignancy affecting the heart is secondaries from other organs mainly leukemias, melanoma, lung, breast, sarcoma and thyroid. Primary cardiac tumours are rare. Its incidence varies from 0.001% to 0.28% in various reports.<sup>2</sup> In India, exact incidence of cardiac neoplasm is unknown. Bhan et.al<sup>3</sup> reported incidence of 0.24% of all cardiac operations performed at their institution. Majority of primary cardiac tumours are benign. Myxoma (77%) is most common benign tumour while, sarcoma (10%) is most common primary malignant tumour of heart.

Radiological studies such as echocardiography, CT scan and MRI provide useful clues regarding the nature of intra cardiac mass. The features that favour malignant nature of cardiac mass are (i) right side cardiac mass is more likely to be malignant than left sided; (ii) Origin of mass from free wall of cardiac chamber rather than septum; (iii) Invasion of pericardium great vessels and mediastinum; (iv) Presence of distant metastases; (v) extension of mass into more than one cardiac chamber (vi) concomitant pericardial and / or pleural effusion;<sup>7</sup> (vii) diameter of mass more than 5 cm. (viii) tissue inhomogeneity<sup>9</sup> and Contrast enhancement. All these features were present in our case.

Malignant nature of cardiac mass can be confirmed only by histological examination of surgically obtained tissue or autopsy. Whether precise histological typing is mandatory in cardiac tumour before starting cancer directed definitive therapy, particularly in hemodynamically unstable patient, is a matter of controversy. One should attempt to get tissue diagnosis before planning definitive treatment because<sup>1</sup> it will rule out benign cardiac lesion, that are potentially curable with surgery.<sup>2</sup> It will confirm the metastatic lesions of potentially treatable malignancies like Non-Hodgkin's lymphoma, germ cell tumour, breast cancer etc.<sup>3</sup> It helps in selecting primary treatment modality.

However, tissue diagnosis can be omitted in few circumstances like when patient is hemodynamically compromised, tumour is metastasized to distant organs in the absence of primary outside the heart and treatment is of palliative nature only.

The histological types of cardiac sarcoma are virtually identical to those found in extra cardiac soft tissues. The most common histological types of primary cardiac sarcoma are angiosarcoma, malignant fibrous histiocytoma and undifferentiated sarcoma. The histological classification of cardiac sarcomas is currently of little clinical use<sup>4</sup>. The sub type of sarcoma does not apparently affect the treatment and survival.

Fine needle aspiration cytology have limited diagnostic utility in cases of cardiac masses and it is done rarely,<sup>5,6</sup> although it is helpful to confirm the diagnosis when there is pericardial effusion and extension of tumour into pericardium or mediastinum. We did ultrasound guided FNAC from right cardiac mass because mass had pericardial extension. Although, patient was hemodynamically unsuitable for cardiac catheterization or open-heart surgery, patient withstood the FNAC procedure rather well and good tissue yield was obtained.

Most common right side malignant tumours in heart are usually angiosarcoma, but in our case, cytological picture was typical of malignant fibrous histiocytoma. The FNA smear in MFH is hypercellular against myxoid background consist of pleomorphic spindle shaped cells admixed with bizarre multinucleated giant cells<sup>7</sup>, in contrast angiosarcoma are relatively hypocellular with low yield of cells against hemorrhagic background. The individual cells are oval, spindle to polygonal shape lying singly or in small clusters, often with stripped cytoplasm as naked nuclei. The nuclei are hyperchromatic pleomorphic and may show nuclear grooves, intracytoplasmic vacuoles or lumina formation.<sup>8</sup>

Although, immunohistochemistry is helpful in identifying the tissue of origin in undifferentiated sarcoma, most pathologists give preference to cytopathological diagnosis in case of typical or well differentiated sarcoma. Immunohisto-chemistry is confirmatory of a single diagnosis in 30-40% of cases. It is helpful in guiding the differential diagnosis in 50-60% of cases & it is contributory in 1-2% of cases.

Treatment is often multidisciplinary, but due to rarity of these tumours exact role of surgery, chemotherapy and radiotherapy is not defined.

Debulking surgery remains the mainstay of treatment. However, patients go untreated due to advanced/ metastatic disease. Reshma et al.<sup>10</sup> reported 4 cases of malignant cardiac tumours out of approximately 12,000 open-heart operations. Three of these tumours were angiosarcoma and one was a high-grade spindle-cell sarcoma. The prognosis for all 4 patients was poor in spite of maximal tumour debulking and postoperative chemotherapy.

Chemotherapy is generally accepted to be the most successful treatment for advanced soft tissue sarcomas. Of the different regimens, the combined CYVADIC regimen (cyclophosphamide, vincristine, doxorubicin and Dacarbazine) is superior, in terms of both response and survival. Eckstein et al.<sup>11</sup> recommended that every surgical excision of cardiac soft-tissue sarcomas be followed immediately by adjuvant chemotherapy. Liposomal doxorubicin, gemcitabine and paclitaxel also appear to be active.

Neo-adjuvant chemotherapy or chemoradiation may be proposed in patients with unresectable disease. Recently, there are few reports of successful loco-regional control as well as the feasibility of radiation with radiosensitizers.<sup>12, 13</sup> The response of soft-tissue sarcomas to radiation is variable, and radiation treatment is therefore not always successful.

Success of molecular targeted therapy, imatinib in gastrointestinal stromal tumour and vascular endothelial growth factor (VEGF) inhibitor bevacizumab (antiangiogenesis agent) in Kaposi's sarcoma and angiosarcoma, has given an exciting new prospect for treatment of cardiac sarcoma.

#### REFERENCES:

1. Agarwal V, Agarwal S K, Srivastav K, Kapoor S. Primary cardiac tumours. *Indian Heart J.* 2003;55(6):632-6
2. Burke A, Virmani R. Tumours of the heart and great vessels In: *Atlas of tumour pathology. 3<sup>rd</sup> Series, Fasc 16, Washington DC: Armed Forces Institute of Pathology.1996*
3. Bhan A, Mehrotra R, Chaudhary SK, Sharma R et al. Surgical experience with intracardiac myxomas: Long term follow up. *Ann. Thorac Surg.* 1998;66:810-813.
4. Burke A P, Gowan D, Virmani R. Cardiac Sarcoma. *Cancer.* 1992;69:387-395.
5. Kumar R.V, Devi M.G., Biswas S. Cytology of cardiac angiosarcoma in Fine Needle Aspiration. *Acta Cytologica* 2001;45:891.
6. Bhalla R, Nasir A. Cardiac Angiosarcoma Report of a case diagnosed by an echo guided FNAC. *Diagno. Cytopathol.* 2007;35:164-166.
7. *Principles and practice of surgical pathology and cytopathology 4<sup>th</sup> Edition, 2006. Silverberg Steven G. Delellis Ronald A, Frable William J Livolsi Virginia A and Wick Mark R. pub: churchil Livingstone.*
8. *Principles and practice of surgical pathology and cytopathology 4<sup>th</sup> Edition, 2006. Silverberg Steven G. Delellis Ronald A, Frable William J Livolsi Virginia A and Wick Mark R. pub: churchil Livingstone.*
9. Brooks JS. Immunohistochemistry in the differential diagnosis of soft tissue tumours. *Monogr Pathol.* 1996;38:65-128.
10. Reshma M B, Hemant PP, Nandkishor A et al. Cardiac Sarcoma: Is tumour debulking justifiable therapy? *Asian Cardiovasc. Thorac Ann* 1999;7:52-55.
11. Eckstein R, Gosner W, Rienmuller R, Primary malignant fibrous histiocytoma of left atrium: Surgical and chemotherapeutic management. *Br Heart J* 1984;52:354-357.
12. Romberg W, Grass M. Angiosarcoma of right atrium: local control via low radiation doses and razoxane: A Case report. *Strahlenther Onkol* 1999;175(3):2-4.
13. Benjamin M, Julie TF et al. Primary cardiac sarcoma: A Novel treatment approach, *CHEST* 1998;114:648-652.

