

Case Report-1

Therapy related acute promyelocytic leukemia

VENKATA SURESH SATYA ATTILI, HEMANT K DADHICH, TS SUNDERESHAN, PP BAPSY, TP SAHOO, G ANUPAMA

ABSTRACT

Therapy related acute myeloid leukemias (t - AML) contributes 10 - 30 % of all AML s. Promyelocytic sub type is rare and contributes to 12-15% of all t-AML. Radiation as a cause of secondary leukemia is even further rare. Here we report a case of t-APL developing in a patient who received radiotherapy for glioblastoma. He had classical t (15; 17) translocation.

INTRODUCTION

Therapy related acute myeloid leukemias (t - AML) contributes 10 - 30 % of all AML s.¹ It has two broad etiological categories. The first one, caused by alkylating agents /radiotherapy, typically having complex chromosomal rearrangements of 5 and 7, having a distinct pre-leukemic phase and carries poor prognosis. The second one, caused by other etiological agents including, topoisomerase II inhibitors, eg. Etoposide and are associated with classical AML translocation such as t (8; 21), t (15;17), 11q23 and inv16 etc. without pre-leukemic phase and carries a better prognosis.^{2,3} Therapy related acute promyelocytic leukemia (t-APL) is uncommon and contributes 12-15% of all t-AML.^{1,3-5} About 229 cases have been reported till January 2006 in English literature. In a review of 106 t-APL patients, Beaumont et

al found 27 patients with radiotherapy as the sole etiological agent.⁵ Of these 3 cases of t-APL developed after chemotherapy/radiotherapy for brain tumours. We here report a case of t-APL developing in a patient who received radiotherapy for glioblastoma. He had classical t (15; 17) translocation.

CASE: A 20-year-old man came to emergency department with complaints of headache and altered sensorium in February 2005. In past he was diagnosed as a case of glioblastoma (WHO grade 3) of right frontal lobe and was operated (complete excision of tumour with negative surgical margins) in July 2002. Post operatively he had received cranial irradiation-40 Gy. He remained asymptomatic for past two years. The patient was initially thought to have recurrence of glioblastoma and emergency CAT scan of head was done. The CAT scan revealed huge haematoma involving the bilateral temporo-parietal regions, with intra ventricular leak. The complete blood picture showed. Hb 6.6 gm/dl, WBC 30,000/mm³ with differential counts showing 60% promyelocytes. Coagulation profile prothrombin time 80 / 12 sec and APTT was 100/ 23 sec. The bone marrow examination showed richly cellular marrow with 85% promyelocytes, and all other elements were suppressed (fig-1). A cytogenetic analysis was suggestive of acute promyelocytic leukemia with t (15; 17) translocation. The patient was managed conservatively with fresh frozen plasma and platelet concentrates. However patient died within eight hours of admission.

Departments of Medical Oncology and Cytogenetics (TS Sundereshan) Kidwai Memorial Institute of Oncology, Hemato-Pathology³ St. Jhon's hospital Bangalore-560 029
correspondence to: AVS SURESH
E-mail: sureshattili@yahoo.com

DISCUSSION

A growing number of patient with t-APL have been reported in last few years. Earlier the frequency of t -APL ranged from 1.7 % to 5.8%.^{5,6} Presently, it contributes 12 to 15% of all t AML s^{1, 4} This increased frequency might be due to better recognition of the disease.

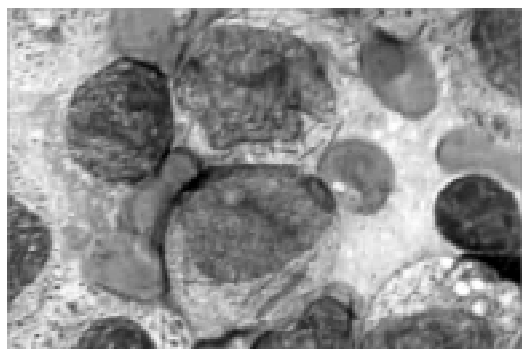


Figure 1: bone marrow showing promyelocytes (100x10)

Though the exact cytogenetic profile, pathophysiology, and clinical details of this observations entity have not been studied in detail, few common findings can be made after reviewing literature.

(a) Preleukaemic phase was not observed in t-APL⁵ (b) The incidence of secondary rearrangements was similar to that observed in de novo APL (24% versus 26%), but type of secondary rearrangements was somewhat different: 85% of the patients with t-APL with additional rearrangement had involvement of chromosomes 5, 7, or 17, as compared with 12% of de novo patients.⁷ (c) In the rare t-APL patients in whom the precise breakpoints on chromosome 15 and 17 were studied at the DNA level, some difference were observed compared with de novo APL, possibly also indicating somewhat different pathogenic mechanisms.^{8,9,10} (d) A significantly higher proportion of females (F: M=2.5:1), a higher median age 45 years and a poor performance status were observed among patients with t- APL.¹¹ (e) Morphologic subsets, white cell and platelet counts, or type of PML / RAR a fusion were not different from the classical APML.¹¹ (f) The median interval from

treatment of primary disease to diagnosis of t-APL was from 25 to 41 months reported by various authors. It can range from as short as 4 months to as long as 276 months.^{5,12}(g) There is no significant differences of time interval from primary disease to diagnosis of t -APL based on the primary malignancy or the therapy received.⁵ (h) Isolated radiotherapy leading to secondary APL depends on cumulative radiotherapy received to bone marrow. It ranges up to 0.3% in patients who received a mean bone marrow dose greater than 3.5 Gy.¹³ However the exact latency, pathophysiology of radiotherapy in development of t-APL is not studied in any of the series. (i) The treatment and outcome of t-APL might not be different from the de novo APL if ATRA is used.^{5,11} (j) The mechanism by which anthracyclins and radiation predispose patients to leukemia remains in dispute. Some evidence supports a direct role for topoisomerase II/ radiation in causing the DNA damage that leads to chromosomal rearrangements. Recent reports of treatment-related APL indicate that epirubicin and mitoxantrone are the most common antecedent drugs and that a substantial proportion of the patients had breast cancer.¹⁹

The commonest primary malignancy is breast carcinoma in various series (17 - 57%), followed by solid malignancies (24 - 35%) and hematological malignancies (18 - 27%). Patients who received radiotherapy / alkylating agents for nonmalignant disorders can also develop secondary APL, but the number of patients is extremely low (0-16%). There are many case reports of secondary acute myeloid leukemia developing following chemo/radiotherapy to the primary brain tumours.^{14, 15, 16, 17} But brain tumours, as primary malignancy accounted for less than one per cent of all t-APL. Only one child with CNS malignancy and t- APL has been observed by Beaumont et al in their review of 106 patients, patient received radiotherapy alone for the primary tumour as in our case. This child had 46 XX t (15;17).¹² However in the review, the exact translocation pattern in other two patients was not mentioned.¹⁸

This is the fourth case of t-APL developing in a patient with CNS tumour who received radiotherapy for the primary tumour. One rarer feature in the present case is the occurrence of the glioblastoma in the 2nd decade which is further rare. However as no genetic testing was done earlier, we could not explain or correlate with the present disease. In the present case t-APL developed 2.5 years after primary malignancy which is not different from the duration reported in literature⁵. Admittedly he received less dose of total radiation (reasons not known), we did not feel that it is having any impact on the occurrence of the APML as the dose requirement to cause secondary APML is just 3.5 Gy. As the patient already had intracranial bleed and features of brain herniation at presentation, he could not be saved. The present case suggest that secondary leukemia can be kept as a possibility in patients who present with features suggest of raised intracranial tension and bleeding manifestations after a gap of more than two years following treatment of previous CNS malignancy.

REFERENCES :

1. Giuseppe Leone, Luca Mele, Alessandro Pulsoni, Francesco Equitani, Livio Pagano. The incidence of secondary leukemias, *Haematologica* 1999; 84:937-945
2. Harris NL, Jaffe ES, Diebold J, et al. The World Health Organization classification of hematological malignancies Report of the Clinical Advisory Committee Meeting, Airlie House, Virginia, November 1997. *Mod Pathol.* 2000;13(2):193-207.
3. Fenaux P, Detourmignies I: Therapy-related acute promyelocytic leukaemia. *Br J Haematol* 1994;87:445-446,
4. Pollicardo N, O'Brien S, Estey EH, et al: Secondary acute promyelocytic leukemia: Characteristics and prognosis of 14 patients from a single institution. *Leukemia* 1996;10:27-31,
5. Beaumont M., Sanz M., Carli P.M., Maloisel F, Therapy-Related Acute Promyelocytic Leukemia. *J Clin Oncol* 2003;21:2123-2137.
6. Detourmignies L, Castaigne S, Stoppa AM, et al: Therapy-related acute promyelocytic leukemia: A report on 16 cases. *J Clin Oncol* 1992;10:1430-1435,
7. Xue Y, Lu D, Guo Y, et al: Specific chromosomal translocations and therapy-related leukemia induced by bimolane therapy for psoriasis. *Leuk Res* 1992;16:1113-1123,
8. De Botton S, Chevret S, Sanz M, et al: Additional chromosomal abnormalities in patients with acute promyelocytic leukaemia (APL) do not confer poor prognosis: results of APL 93 trial. *Br J Haematol* 2000;111:801-806,
9. Naoe T, Kudo K, Yoshida H, et al: Molecular analysis of the t(15;17) translocation in de novo and secondary acute promyelocytic leukemia. *Leukemia* 1997;11:287-288
10. Pedersen-Bjergaard J, Andersen MK, Christiansen DH, et al: Genetic pathways in therapy-related myelodysplasia and acute myeloid leukemia. *Blood* 1997;99:1909-1912,
11. Pulsoni A, Livio Pagano F, Lo Coco et al: Clinicobiological features and outcome of acute promyelocytic leukemia occurring as a second tumour. *Blood*, 2002;100:6,1972-1976
12. Andersen MK, Larson RA, Mauritzson N, et al: Balanced chromosome abnormalities inv (16) and t (15; 17) in therapy-related myelodysplastic syndromes and acute leukemia: report from an International workshop. *Genes Chromosomes Cancer* 2002;33:395-400.
13. Molero T, Lemes A, de la Iglesia S, Gomez Casares MT, del Mar Perera M, Jimenez S. Acute promyelocytic leukemia developing after radiotherapy for prostate cancer in a patient with chronic lymphocytic leukemia. *Cancer Genet Cytogenet.* 2001;131(2):141-3.
14. Perry JR, Brown MT, Gockerman JP. Acute leukemia following treatment of malignant glioma. *J Neurooncol.* 1998;40(1):39-46.
15. Genot JY, Krulik M, Poisson M, et al. Two cases of acute leukemia following treatment of malignant glioma. *Cancer.* 1983;15:52(2):222-6.
16. Vogl SE. Acute leukemia complicating treatment of glioblastoma multiforme. *Cancer.* 1978;41(1):333-6.
17. Kempin S, Sundaresan N, Shapiro WB, Arlin Z. Acute nonlymphocytic leukemia following treatment of malignant glioma. Report of two cases. *J Neurosurg.* 1984;(6):1287-90.
18. Wiernik PH, Muse IM. Acute promyelocytic leukemia after treatment of malignant glioma in a patient with von recklinghausen's disease: case report and review of the literature. *Leukemia.* 1996;10:178-191
19. Mistry AR, Felix CA, Whitmarsh RJ, et al, DNA topoisomerase II in therapy-related acute promyelocytic leukemia. *N Eng J Med.* 2005;14;352(15):1529-38.

