

## Images in Clinical Oncology

---

### Primary Squamous Cell Carcinoma of Breast

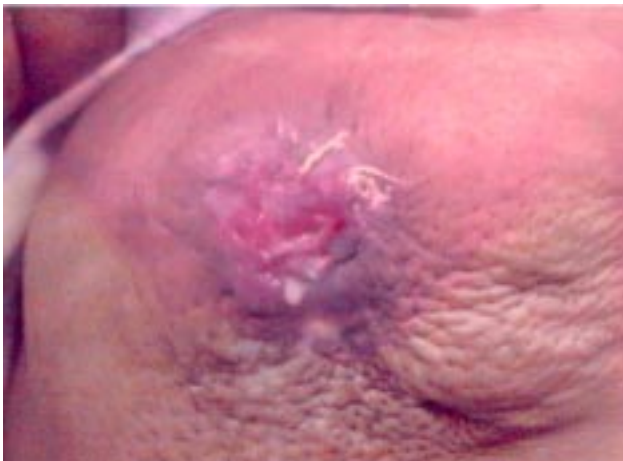

Fig 1

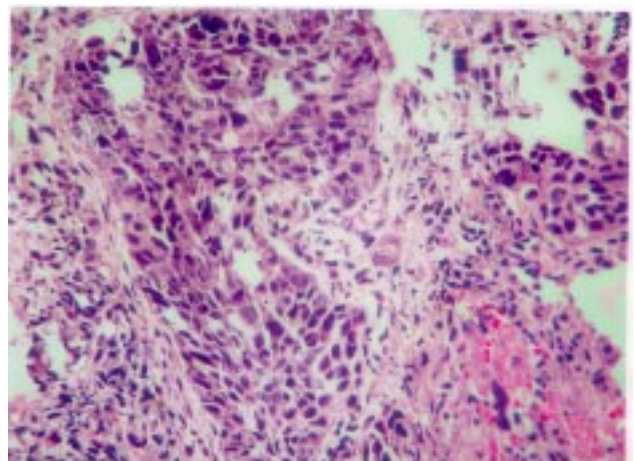


Fig 2

A 42 years old premenopausal female presented with a fungating mass 4x3cm in upper outer quadrant of right breast (fig 1). The axillary lymph nodes were not palpable. Systemic examination was normal. She underwent simple mastectomy. Histopathology revealed squamous cell carcinoma (fig 2). She received 4 cycles of chemotherapy using cisplatin, doxorubicin & 5 Fluorouracil followed by radiotherapy. She is on regular follow up and is disease free for 6 months at the time of reporting.

Primary squamous cell carcinoma of breast is a rare entity. Surgery followed by chemotherapy appears to be the best method of treatment. The role of adjuvant radiotherapy is not well established.

**N Sharma, B Sharma, V Yadav, A Kalwar, V Kumar, S Sharma\***

Acharya Tulsi Regional Cancer Treatment & Research Institute,  
S.P. Medical College Bikaner;

\*Bhagwan Mahaveer Cancer Hospital, Jaipur