



# Cemented Calcar Replacement versus Long Stem Cemented Hemiarthroplasty in Unstable Intertrochanteric Fractures in Octogenarians

## *Substituição do calcar cimentado versus hemiartroplastia de haste longa cimentada em fraturas intertrocantericas instáveis em octogenários*

Kavin Khatri<sup>1</sup>  Ravinder Kumar Banga<sup>2</sup>  Neeraj Malhotra<sup>3</sup>  Deepak Bansal<sup>4</sup> 

<sup>1</sup> Department of Orthopedics, All India Institute of Medical Sciences, Bathinda, Punjab, India

<sup>2</sup> Department of Orthopedics, Government Medical College, Patiala, Punjab, India

<sup>3</sup> Department of Orthopedics, Government Medical College, Amritsar, Punjab, India

<sup>4</sup> Department of Orthopedics, AIMC Bassi Hospital, Ludhiana, Punjab, India

Address for correspondence Kavin Khatri, MS, DNB, FACS, Department of Orthopaedics, All India Institute of Medical Sciences, Bathinda, Punjab, India (e-mail: kavinkhatri84@gmail.com).

Rev Bras Ortop 2022;57(3):511–520.

### Abstract

**Objective** The aim of the present study was to compare functional results after Cemented Calcar replacement vis-a-vis Long stem Cemented hemiarthroplasty in patients aged more than 80 years with unstable intertrochanteric fractures.

**Methods** The present prospective, randomized trial included 140 patients with AO/OTA type 31-A2, A3 intertrochanteric femur fracture, randomized into 2 treatment groups and followed-up for a minimum of 2 years. Sixty-seven patients in group A were treated with a cemented calcar replacing prosthesis, and 65 patients in group B were treated with a cemented long stem femoral stem prosthesis. The primary end points were hip functions at 2 years. The secondary end points were the complications encountered, mortality, surgical time, reoperation, blood loss, and activities of daily living.

**Results** There were no major differences between the groups in terms of hip function, quality of life (health related), reoperation, mortality, and blood loss. However, the function in hip joint and activities of daily living deteriorated in both groups in comparison with prefracture levels.

**Conclusion** In octogenarians with an unstable intertrochanteric fracture, cemented calcar replacing prosthesis has similar clinical results in comparison with long stem cemented hemiarthroplasty. Hemiarthroplasty with either implant is a good option in this subset of patients. Level of evidence: I

### Keywords

- ▶ hemiarthroplasty
- ▶ hip fractures
- ▶ arthroplasty, replacement, hip
- ▶ hip prosthesis

Work developed at the Mediways Hospital, Ludhiana, Punjab, India.

received

January 7, 2021

accepted after revision

March 8, 2021

published online

September 11, 2021

DOI <https://doi.org/10.1055/s-0041-1732392>

10.1055/s-0041-1732392.

ISSN 0102-3616.

© 2021. Sociedade Brasileira de Ortopedia e Traumatologia. All rights reserved.

This is an open access article published by Thieme under the terms of the Creative Commons Attribution-NonDerivative-NonCommercial-License, permitting copying and reproduction so long as the original work is given appropriate credit. Contents may not be used for commercial purposes, or adapted, remixed, transformed or built upon. (<https://creativecommons.org/licenses/by-nc-nd/4.0/>)

Thieme Revinter Publicações Ltda., Rua do Matoso 170, Rio de Janeiro, RJ, CEP 20270-135, Brazil

## Resumo

**Objetivo** O objetivo do presente estudo foi comparar os resultados funcionais após a substituição do Calcar cimentado em comparação com a hemiartroplastia cimentada de haste longa em pacientes com mais de 80 anos com fratura intertrocanterica instável.

**Métodos** O presente estudo prospectivo e randomizado incluiu 140 pacientes com fratura de fêmur intertrocanterica, conforme classificação AO/OTA tipo 31-A2, A3, randomizados em 2 grupos de tratamento e acompanhados por um período mínimo de 2 anos. Sessenta e sete pacientes do grupo A foram tratados com uma prótese de substituição do calcar cimentada e 65 pacientes do grupo B foram tratados com uma prótese femoral de haste longa cimentada. Os desfechos primários foram as funções do quadril em 2 anos. Os eventos secundários foram as complicações encontradas, a mortalidade, o tempo cirúrgico, segunda cirurgia, perda de sangue e as atividades do cotidiano.

**Resultados** Não houve grandes diferenças entre os grupos em termos de função do quadril, qualidade de vida (relacionada à saúde), segunda cirurgia, mortalidade e perda de sangue. No entanto, a função da articulação do quadril e as atividades da vida diária se deterioraram em ambos os grupos em comparação com os níveis pré-fratura.

**Conclusão** Nos octogenários com fratura intertrocanterica instável, a prótese de substituição do calcar cimentada apresentou resultados clínicos semelhantes em comparação com a hemiartroplastia de haste longa cimentada. A hemiartroplastia com qualquer um dos implantes é uma boa opção nesse subgrupo de pacientes. Nível de evidência: I

## Palavras-chave

- ▶ hemiartroplastia
- ▶ fraturas do quadril
- ▶ artroplastia de quadril
- ▶ prótese de quadril

## Introduction

The elderly population with osteoporosis has a high incidence of implant failure and poor functional results in terms of limb shortening with external rotational deformity following osteosynthesis with dynamic hip screw or intramedullary hip screw fixation in case of unstable intertrochanteric fractures.<sup>1</sup> These fears restrict weight bearing, resulting in prolonged bed rest and subsequent morbidity and mortality.<sup>2,3</sup> The requirement of a second surgery in these cases is an important consideration before choosing the appropriate procedure and implant.

Hemiarthroplasty can be posed as a solution to these problems of osteosynthesis. It allows for immediate weight bearing and allays the fears of nonunion or malunion at the fracture site.<sup>4</sup> Few authors suggest reconstruction of the femoral calcar to avoid early subsidence of the implant and maintain the initial stability.<sup>5,6</sup> However, calcar reconstruction increases the complexity of the procedure and, therefore, the overall complication rates.<sup>7,8</sup> Hence, calcar replacement is an option to avoid complications such as calcar nonunion, especially in octogenarians.<sup>9</sup>

Zha et al.,<sup>10</sup> in their retrospective study, advocate the use of distal fixing long cementless stem to decrease the surgical complications. However, due to osteoporosis and wide femoral canals, there are high chances of implant failure with uncemented stems in the elderly population.<sup>11</sup> There are studies that reported complications with the use of cement in hemiarthroplasty,<sup>12,13</sup> but others have reported good outcomes.<sup>14,15</sup>

We are not aware of any study comparing the results of treatment with cemented calcar replacing with long stem cemented hemiarthroplasty. We hypothesized that calcar replacing cemented hemiarthroplasty would be associated with better hip function and better health-related quality of life in comparison with long stem cemented hemiarthroplasty in cognitively intact octogenarians with an unstable intertrochanteric fracture.

## Materials and Methods

### Study Design

The present single center, prospective randomized controlled trial was conducted according to the guidelines of good practice and the Consolidated Standards of Reporting Trials (CONSORT) statement.<sup>16</sup> Between March 2013 and November 2018, 140 cases with unstable intertrochanteric femoral fractures (AO/OTA type 31-A2, A3) were enrolled in the study, which was approved by the institutional review board (AIMC/CT02092013). Informed consent was taken from all the participants in the trial.

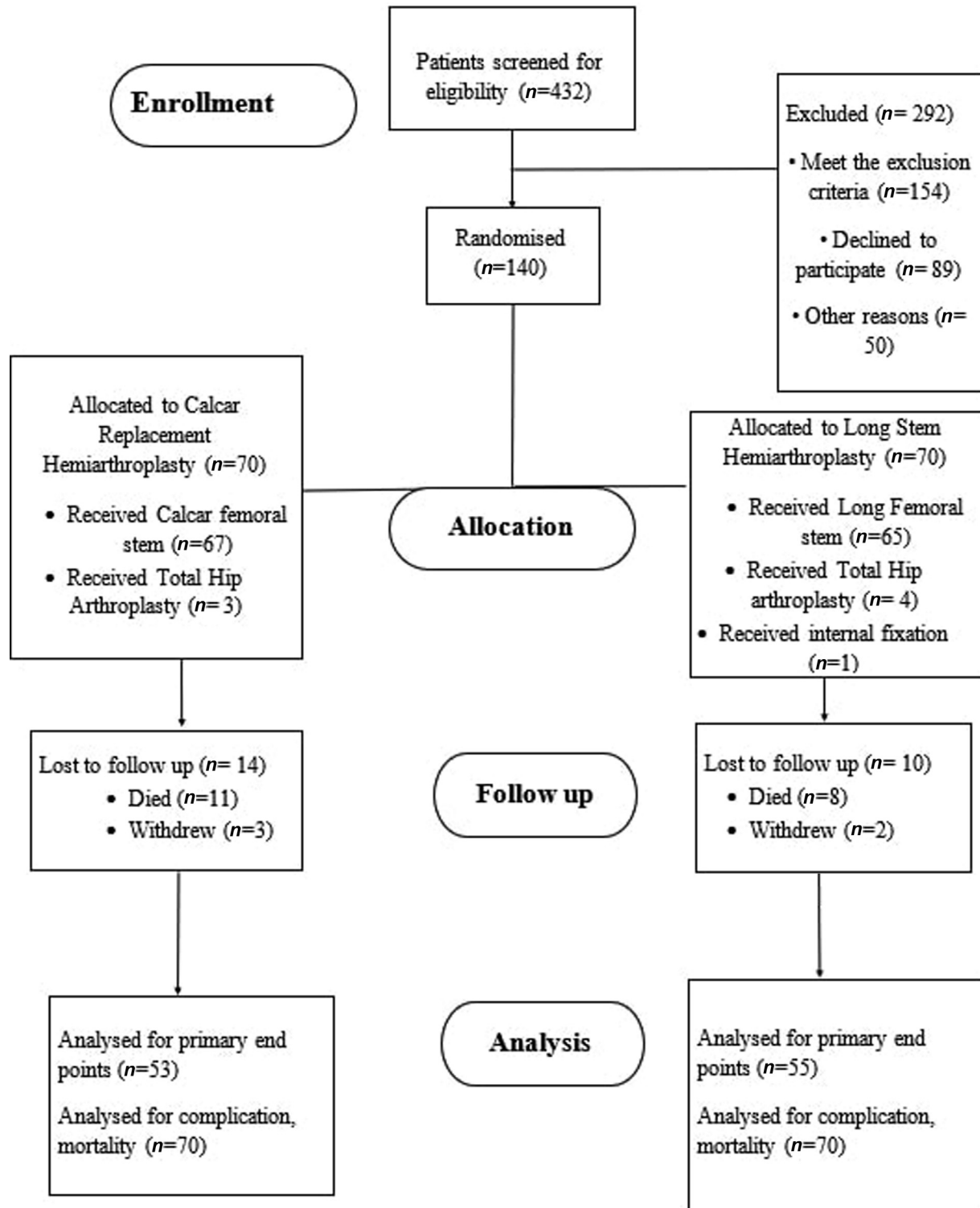
### Participants

All patients with unstable intertrochanteric fracture were screened for participation in the study. The inclusion criteria were unstable intertrochanteric femoral fractures (AO/OTA type 31-A2, A3), age  $\geq 80$  years old, independent walking with or without help of walking aid prior to the injury and intact cognitive function with a short portable mental status questionnaire (SPMSQ) score of 8 to 10 points.<sup>17</sup> Patients

with pathological fracture, rheumatoid arthritis in the involved hip, polytraumatic injuries, simultaneous fractures of the ipsilateral extremity and patients who refused participation and were unfit for operation were excluded from the study (► Fig. 1).

### Randomization and Blinding

The patients were block randomized with a block size of 10 in a ratio of 1:1 to undergo an operative procedure with either calcar replacing or long stem femoral stem hemiarthroplasty. The envelopes were sealed and stratified by gender to ensure similar



**Fig. 1** CONSORT flow diagram of the participants in the study. The surgeon chooses to perform total hip arthroplasty in seven cases due to acetabular erosions encountered during surgery. One patient was taken up for internal fixation due to suspected urinary tract infection.

gender distribution in both groups. The patients were blinded to the treatment while the surgeon and three nursing assistants were not. The nursing assistants were instructed not to reveal the allocation to the patients. The postoperative care protocol did not differ between the two groups. The patients were not shown their radiographs and were asked whether they knew about the treatment at the time of the last follow-up.

### Data Collection

Three nursing assistants involved in the research interviewed the patients and obtained baseline data of the patients 1 week prior to the fracture. The patients were followed-up at 4 months, 1 year and 2 years. The functional outcome was self-reported by the patients.

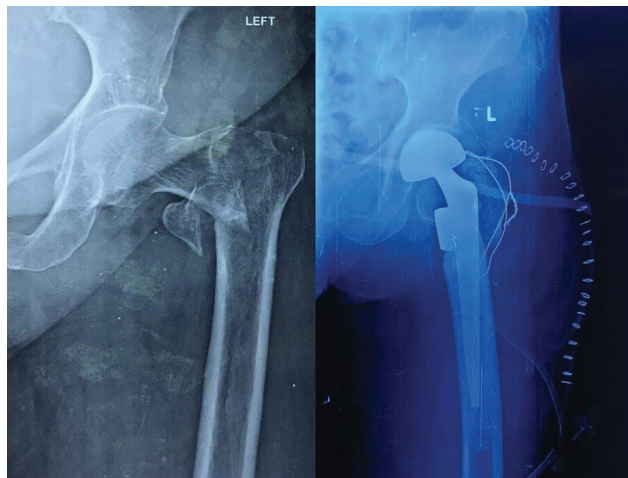
### Operative Technique

#### Cemented Calcar Replacement Hemiarthroplasty

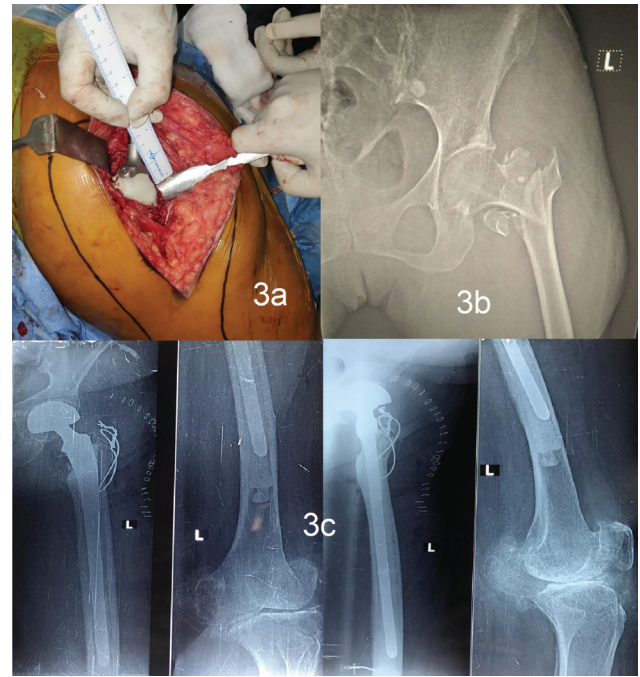The injured hip was approached posterolaterally under spinal anesthesia. We used different lengths of calcar extensions on a case-to-case basis in order to provide a stable platform for the hip prosthesis to rest. The length of the stem varied between 170 and 220 mm with increments of 15 mm. The fractured greater trochanter was attached with help of #5 Ethibond (Ethicon, Somerville, NJ, USA) cerclage wires to the lateral aspect of the femoral stem (→ Fig. 2a-b).

#### Cemented Long Stem Hemiarthroplasty

The surgical approach was similar as that of in cases of calcar replacement. The fractured fragments were removed from the proximal femur. The femoral canal was prepared using broach and a trial modular femoral stem was inserted followed by hip reduction. Preoperative planning helped in deciding intraoperatively the appropriate length of the stem. Bone cement was used to build up the posteromedial defect in proximal femur (→ Fig. 3a). The length of the stem varied between 170 and 300 mm. The stability of the prosthetic hip joint was ascertained and, subsequently, an appropriately sized head was used.



**Fig. 2** (A-B) Radiographic image showing unstable intertrochanteric fracture treated with calcar replacing hemiarthroplasty and greater trochanter attached to the proximal and lateral aspect for femur.



**Fig. 3** (A-C) Build-up of calcar with cement in a case of unstable fracture treated with long stem bipolar hemiarthroplasty.

### Postoperative Protocol

The patients were mobilized and allowed to bear weight as tolerated with the help of crutches. All patients in both groups were administered aspirin 75 mg daily starting on the 1<sup>st</sup> postoperative day and was continued until discharge from the hospital at the 10<sup>th</sup> postoperative day. The radiographic evaluation was done by an independent observer (Lakhani AK) (→ Fig. 3 b-c).

### Primary End Points

The primary end points were the hip function as assessed by the Harris Hip Score (HHS).<sup>18</sup> The HHS is a validated tool for reporting outcomes in pertrochanteric fractures.<sup>19</sup> Harris hip scores were graded < 70 as poor, 70 to 79 as fair, 80 to 89 as good, and 90 to 100 as excellent.

### Secondary End Points

The secondary end points were hip function as assessed by the Barthel Index (BI)<sup>20</sup> and the EuroQol-5 (EQ-5D).<sup>21</sup> The BI includes 10 activities of daily living such as feeding, grooming, bathing, dressing, bowel care, bladder care, toilet use, ambulation, transfers, and stair climbing. The total range of the BI is from zero to 20. The EQ-5D is a generic instrument to measure health-related quality of life. Other parameters studied were hip-related complications, pain in the involved hip, surgical time, intraoperative blood loss, mortality, and ability to regain previous walking function.

### Sample Size

The sample calculation was based on two variables: the HHS and the EQ-5D. Based on a previous study,<sup>22</sup> we assumed that a difference of  $10 \pm 15$  (mean  $\pm$  standard deviation [SD]) would be the smallest clinically relevant change in the

HHS. So, to achieve a power of 80%, a minimum of 60 patients should be enrolled in the study. This calculation also allowed to prove noninferiority in the case of the EQ-5D, with an assumption of mean values of  $0.73 \pm 0.18$  (0.1 as limit of noninferiority). The statistical significance level was set at 0.025 to include multiplicity encountered by the calculation of 2 sample sizes. The final study included 140 patients, with 70 patients in each group to account for attrition.

### Statistical Method

The analyses of outcomes were done on the intent to treat principle, and all patients were analyzed in the group allocated regardless of the treatment administered. Analysis according to protocol was also performed. The chi-squared test was used to test correlations in ordinal data, and the student *t*-test was used to compare the HHS, the BI, and the EQ-5D between the two groups. Analysis of covariance (ANCOVA) of the primary end points was used to decrease variance with inclusion of exposure variables and stratification. Statistical analysis was performed using IBM SPSS Statistics for Windows, Version 22 (IBM Corp., Armonk, NY, USA).

### Results

A total of 432 patients were screened for eligibility, and 292 were excluded for not meeting the inclusion criteria. A total of 140 patients were randomized into 2 groups with 70 cases in each group. In one group, the patients were treated with calcar replacing cemented hemiarthroplasty (calcar replacement stem; Xlo, New Delhi, India); in the other group, the patients were treated with long stem cemented hemiarthroplasty (Xlo, New Delhi, India).

All cases were operated on by a single surgeon (Bansal D.) within an interval of 4 days after the initial injury following management of comorbidities. Both groups were comparable in terms of age, gender, and osteoporosis index as defined by Singh et al.<sup>23</sup> (► **Table 1**).

### Primary End Points

In the intent to treat analysis, the functional outcome scales (HHS, EQ-5D, and BI) deteriorated over time and revealed no significant difference between cemented calcar replacing and long stem hemiarthroplasty (► **Table 2**; ► **Figs. 4** and **5**). The findings remained similar after per protocol and ANCOVA analysis of end points. The American Society of Anesthesiologists (ASA) classification at baseline and higher walking ability prior to injury did not affect the primary end point.

### Secondary End Points

The intraoperative parameters are listed in ► **Table 3**. There was no significant difference in pain scores and activities of daily living in the two groups. Both parameters deteriorated with time (► **Table 2**).

The complications encountered in the postoperative period are presented in ► **Table 4**. There were two cases of hip dislocation in the calcar replacing hemiarthroplasty group A.

**Table 1** Patient Demographics

	Group A (n = 70) *	Group B (n = 70)
Age (years old) <sup>#</sup>	83 ± 3.7	82 ± 3.4
Gender		
Male	48	48
Female	12	12
Body Mass Index (kg/m <sup>2</sup> ) <sup>#</sup>	21 ± 3.2	22 ± 2.4
Singh osteoporosis Index	2.7 ± 0.6	2.6 ± 0.7
Charnley functional classification (number of patients)		
A	58	56
B	7	11
C	5	3
ASA classification (number of patients)		
1–2	43	38
3–4	27	32

Abbreviation: ASA, American Association of Anesthesiologists.

\*\*n denotes number of subjects; # denotes mean ± standard deviation; Group A: Cemented calcar replacing hemiarthroplasty; Group B: Cemented long stem hemiarthroplasty.

One patient suffered dislocation while sitting on a traditional woven bed, while another had fallen in the washroom. In both cases, the dislocation was reported after discharge from hospital. Prosthetic hip dislocation was reduced by open reduction in both cases. Hip abduction braces were advised to be worn for 6 weeks. There were no subsequent recurrences.

Two patients had trochanteric nonunion in group B (► **Fig. 6**), and one of them had symptomatic lurch. The patient who had symptomatic lurch refused any further intervention. Three patients in group A and four patients in group B had superficial infection, which was treated with antibiotics and regular dressings (► **Fig. 7**). One patient in group A developed deep seated infection, and debridement was performed, but no organism was obtained on culture sensitivity reports. The patient developed discharging sinus 3 weeks after debridement. He was advised repeat debridement with removal of the prosthesis, but refused any further intervention at our institution.

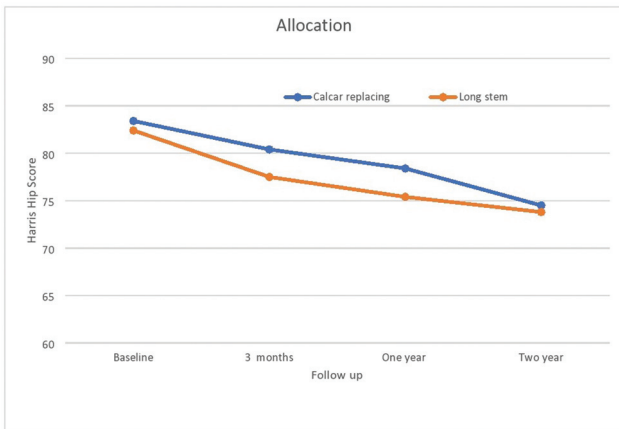
### Success of Blinding

The success of blinding was tested in the 105 patients available at the time of the last follow-up, that is, 2 years after the surgical intervention. A total of 28 patients correctly identified their allocation, 24 did not guess it correctly, and 53 did not know about the allocation (► **Table 5**). In the test for blinding, the difference was not significant between the two groups ( $p = 0.63$ ). Moreover, the difference in the outcomes was not statistically significant between the patients who had correctly guessed the allocation and those who did not (► **Fig. 8**).

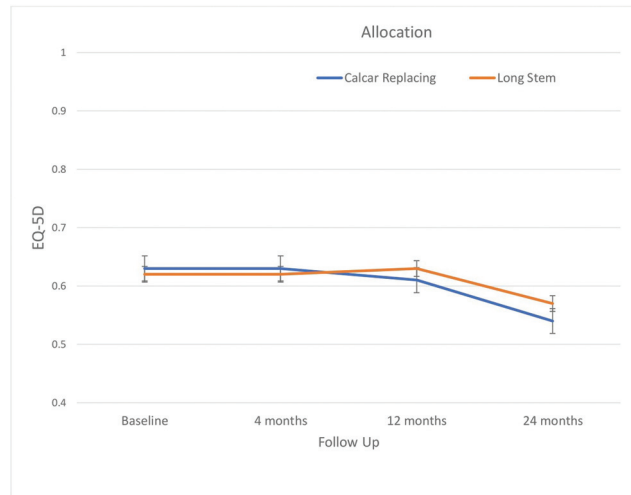
**Table 2** Functional outcome according to treatment allocation

Outcome measure	Intent to Treat			Per Protocol		
	Calcar replacement hemiarthroplasty (n = 70)	Long stem hemiarthroplasty (n = 70)	Mean difference or relative risk (95%CI) <sup>#</sup>	Calcar replacement hemiarthroplasty (n = 67)	Long stem hemiarthroplasty (n = 65)	Mean difference or relative risk (95%CI) <sup>#</sup>
<b>Harris Hip Score</b>						
Baseline	83.4 ± 8.6* (n = 69)	82.4 ± 11.2 (n = 70)	1.0 (-5.7373-3.7373)	83.4 ± 8.6 (n = 69)	82.4 ± 11.2 (n = 65)	1.0 (-5.7373-3.7373)
4 months	80.4 ± 9.4 (n = 64)	77.5 ± 8.1 (n = 62)	2.9 (7.0953-1.2953)	80.4 ± 9.4 (n = 64)	77.5 ± 8.3 (n = 58)	3.9 (8.0953-1.2953)
12 months	78.4 ± 8.7 (n = 59)	75.4 ± 9.6 (n = 60)	3.0 (-7.3414-1.3414)	78.4 ± 8.7 (n = 59)	75.4 ± 9.6 (n = 55)	3.0 (-7.3414-1.3414)
24 months	74.5 ± 9.6 (n = 53)	73.8 ± 7.8 (n = 55)	0.7 (-6.78-2.348)	74.5 ± 9.6 (n = 53)	73.5 ± 7.8 (n = 51)	1.0 (-6.78-2.348)
<b>Barthel Index</b>						
Baseline	18 (51%)	17 (49%)	1.04 (0.7888-1.3734)	18 (51%)	17 (49%)	1.04 (0.876-1.4573)
4 months	16 (46%)	16 (46%)	0.9409 (0.6974-1.2695)	16 (46%)	14 (43%)	0.8409 (0.7074-1.256)
12 months	15 (43%)	14 (41%)	1.0238 (0.7416-1.4134)	15 (44%)	13 (42%)	1.0238 (0.7416-1.4134)
24 months	12 (38%)	13 (39%)	1.3214 (0.7653-1.3675)	12 (38%)	11 (36%)	1.1214 (0.8765-1.4675)
<b>EQ-5D</b>						
Baseline	0.63 ± 0.29 (n = 69)	0.62 ± 0.31 (n = 70)	0.01 (-0.18-0.02)	0.63 ± 0.29 (n = 69)	0.62 ± 0.31 (n = 65)	0.01 (-0.18-0.02)
4 months	0.63 ± 0.27 (n = 64)	0.62 ± 0.25 (n = 62)	0.01 (-0.06-0.11)	0.63 ± 0.27 (n = 64)	0.59 ± 0.25 (n = 58)	0.04 (-0.08-0.12)
12 months	0.61 ± 0.25 (n = 59)	0.63 ± 0.23 (n = 60)	0.02 (-0.18-0.02)	0.61 ± 0.25 (n = 59)	0.62 ± 0.23 (n = 55)	0.01 (-0.18-0.02)
24 months	0.54 ± 0.26 (n = 53)	0.57 ± 0.30 (n = 55)	0.03 (-0.18-0.02)	0.54 ± 0.26 (n = 53)	0.56 ± 0.30 (n = 51)	0.02 (-0.16-0.01)
<b>Pain Rating Scale</b>						
Baseline	0.5 ± 1.3 (n = 69)	0.43 ± 1.7 (n = 70)	0.02 (0.4-0.6)	0.5 ± 1.3 (n = 69)	0.41 ± 1.7 (n = 65)	0.19 (0.3-0.6)
4 months	2.1 ± 1.8 (n = 64)	2.0 ± 1.5 (n = 62)	0.1 (0.4-1)	2.1 ± 1.8 (n = 64)	2.0 ± 1.5 (n = 58)	0.1 (0.4-1)
12 months	1.5 ± 1.6 (n = 59)	1.3 ± 1.2 (n = 60)	0.02 (0.6-0.9)	1.5 ± 1.6 (n = 59)	1.4 ± 1.2 (n = 55)	0.1 (0.6-0.9)
24 months	1.4 ± 1.9 (n = 53)	1.5 ± 1.6 (n = 55)	0.2 (0.8-0.6)	1.5 ± 1.9 (n = 53)	1.2 ± 1.6 (n = 51)	0.3 (0.8-0.6)
<b>Ability to walk with aid</b>						
Baseline	33 (94%)	32 (88%)	1.0682 (0.9785-1.1661)	31 (91%)	32 (88%)	1.2422 (0.7895-1.4325)
4 months	27 (78%)	29 (80%)	0.9750 (0.8451-1.1248)	27 (78%)	29 (80%)	0.8897 (0.8456-1.1248)
12 months	30 (85%)	30 (84%)	0.9882 (0.8776-1.1128)	30 (85%)	27 (81%)	0.7654 (0.8965-1.5643)
24 months	28 (79%)	27 (78%)	0.8977 (0.7894-1.2314)	26 (74%)	25 (75%)	0.9875 (0.6754-1.3345)

Abbreviation; CI, confidence interval.  
<sup>#</sup>values are expressed as mean with standard deviation in parentheses.



**Fig. 4** Line graph showing mean Harris Hip Score during the study period.



**Fig. 5** Line graph showing mean EQ-5D index scores (a health-related quality of life measure) during the study period.

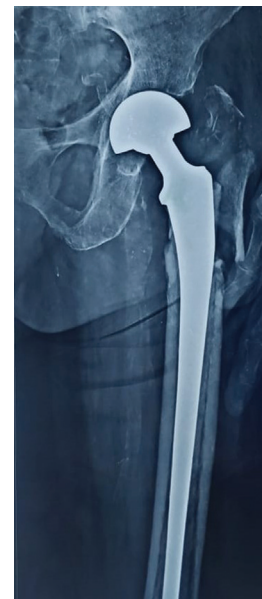**Table 3** Intraoperative parameters recorded according to the allocated treatment

Parameter	Calcar replaced (n = 67)	Long Stem (n = 65)	Mean Difference	95%CI	p-value
Operative time (minutes)	109 ± 20 <sup>†</sup>	104 ± 23	- 5.000	-15.2166-5.2166	0.3323
Blood loss (ml)	730 ± 112	745 ± 109	15.000	-37.3229-67.3229	0.5692
Blood transfused (units)	2.3 ± 0.6	2.5 ± 0.7	0.200	-0.1091-0.5091	0.2010

\*values are expressed as mean with standard deviation in parentheses, <sup>#</sup> CI = 95% Confidence Interval

**Table 4** Complications encountered in two comparison groups

	Calcar replacement (n = 67) group	Long stem (n = 65) group
<b>Immediate postoperative</b>		
a. Cardiovascular events	4	2
b. Urinary tract infection	2	0
c. Neurologic complications	0	1
d. Deep vein thrombosis	1	0
e. Respiratory complications	2	3
f. Superficial infection	3	4
g. Deep infection	1	0
h. Mortality in hospital	1	0
i. Nerve injury	0	1
<b>Late postoperative complications</b>		
a. Mortality within one year	3	2
b. Mortality after one year	8	6
c. Dislocation	2	0
d. Trochanteric nonunion	0	2



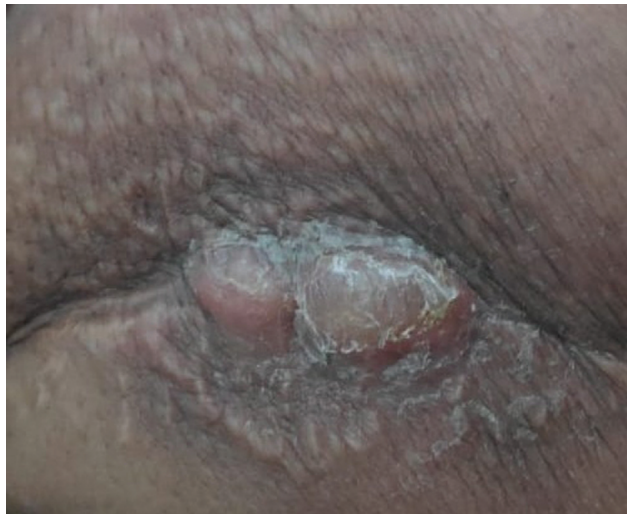**Fig. 6** Radiographic image showing trochanteric nonunion.

**Discussion**

Hip fractures are among the most frequent causes of morbidity and mortality in the elderly population.<sup>24</sup> Intertrochanteric fractures account for 50% of all hip fractures. The majority of these fractures is unstable, with loss of

**Participants Who Refused Participation**

There were 89 patients who declined participation in the study; they were similar in terms of gender ( $p = 0.56$ ), age ( $p = 0.53$ ), and ASA classification (0.23).



**Fig. 7** Clinical Image showing bleb formation in case of superficial infection treated with debridement.

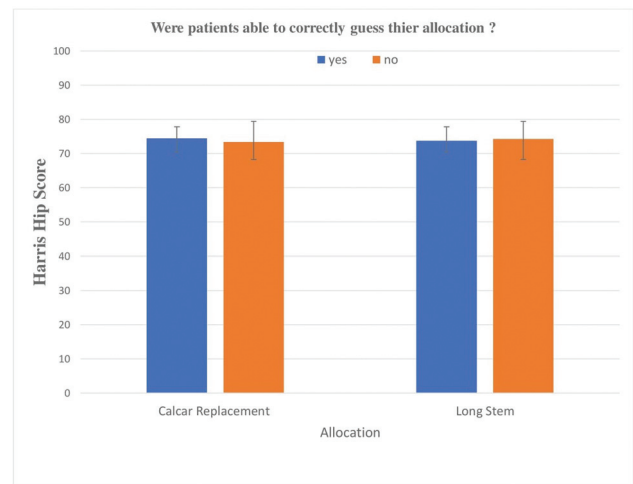
**Table 5** Test for blinding at the time of last follow-up

Actual number of patients underwent allocation		
	Calcar replaced (n = 48) hemiarthroplasty	Long stem (n = 57) hemiarthroplasty
In which you were allocated?		
Calcar replacing hemiarthroplasty	12 (25%)	16 (28%)
Long stem hemiarthroplasty	13 (27%)	11 (19%)
Don't know	23 (48%)	30 (53%)

posteromedial support and displaced lesser trochanteric fragment.<sup>25</sup> Although surgical techniques and patient care have improved a lot in recent years, the ideal treatment for intertrochanteric fractures is still under debate.<sup>25</sup>

Currently, the treatment options for unstable intertrochanteric fracture are internal fixation or hemiarthroplasty with either cemented or cementless stems. High union rates have been reported with internal fixation of stable intertrochanteric fractures, but failure rates of up to 55% have been recorded in unstable, osteoporotic fracture patients.<sup>26</sup> The poor bone quality in the elderly population does not provide firm purchase in many cases, leading to failure in terms of screw cut-out, varus collapse, and retroversion of femoral head.<sup>27</sup>

Bipolar hemiarthroplasty is proposed as a treatment modality for managing unstable intertrochanteric fractures due to its advantages such as early mobilization, good functional results, and lower implant failure rates. Although uncemented femoral stems have lower chances of cement implantation syndrome, there is always risk of femoral stem loosening with rates varying up to 18%.<sup>28</sup> Cobden et al.<sup>28</sup>



**Fig. 8** Test for blinding at the time of last follow up.

reported a higher rate of femoral stem loosening, especially in the elderly population.

Using the HHS, Socci et al.<sup>1</sup> reported good to excellent results in ~ 80% of the patients; there was no case of dislocation or of loosening. Zha et al.,<sup>10</sup> in their study of patients > 75 years old treated with hemiarthroplasty, reported good results in 83% of the subjects. Many authors believe that following surgery, the patient should be mobilized as early as possible to prevent complications and reduce mortality.<sup>3,27</sup> Our patients were permitted weight bearing using a walker on day one of the surgery. Our study demonstrated that elderly patients with unstable intertrochanteric fractures treated with either cemented calcar replacement or long stem hemiarthroplasty had successful clinical results. The cost of the implants (calcar replacing or long stem hemiarthroplasty) used in either treatment group are comparable but are more expensive than the implants routinely used in the treatment of unstable intertrochanteric fractures.

To obtain good implant stability, a few authors suggested reconstructing the calcar femorale.<sup>29-31</sup> However, others argue that calcar replacement with prosthesis augments the deficit in the proximal medial part of the femur. To reconstruct the calcar femorale, it would require further wound exposure for fixation of the lesser trochanteric fragment. An extensive soft tissue stripping and reconstruction technique is likely to result in longer operative time and increased blood loss in already cardiovascularly compromised patients. Abdelkhalik et al.<sup>32</sup> reported an average operative time of 140 minutes using cemented hemiarthroplasty with reconstruction of the calcar femorale in elderly patients. In contrast, a shorter operative time of  $109 \pm 20$  minutes in calcar replacement and of  $104 \pm 23$  minutes in the long stem group was noted in our study. However, there was a higher number of cases of limb length discrepancy noted with use of calcar replacing prosthesis than with calcar reconstruction. Knutson et al.<sup>33</sup> reported that a limb length discrepancy < 1 cm does not lead to any major function disability. In our study, the limb length discrepancy was between 4 and 8 mm, so the patients had good functional outcomes.



## Strength of the Study

The strengths of the present study were its prospective nature, blinding, randomization, inclusion of intention treat and per protocol analyses, randomization stratified by gender to attain equal gender distribution in both groups, and adherence to a predefined hypothesis and outcome measurements assessment. Other significant strength factors were inclusion of methods like check for success of blinding and analysis of patients who had declined to participate in the study. To the best of our knowledge, this is the first randomized controlled trial (RCT) comparing calcar replacing with long stem hemiarthroplasty.

Nonetheless, the present study has a few limitations. First, it did not include a large number of patients. Second, the follow-up of patients was relatively short; therefore, long-term complications such as acetabular erosion, stem failure, late dislocation or infection could not be reported. However, a long-term follow-up is difficult due to the typical senile age of the patients and its questionable clinical relevance in view of their remaining life expectancy. Third, the cases that required greater trochanteric fixation might have different outcomes in comparison with those with an intact greater trochanter.

## Conclusion

With the increase in the number of geriatric populations worldwide, the choice of implant with better and long-term results is taking a center stage. Our study did not find any significant difference between the two groups in terms of functional outcome and complication rates. Long-term studies may be required to identify any long-term advantage of calcar replacing versus long stem hemiarthroplasty. Hence, surgeons have a choice to opt for calcar replacement or long hemiarthroplasty in the management of unstable intertrochanteric fractures in the elderly population.

### Financial and Material Support

Financial and material support was provided by the administration of the AIMC Bassi Hospital, Ludhiana, Punjab. pIncode-151001

### Conflict of Interests

The authors have no conflict of interests to declare.

## References

- Socci AR, Casemyr NE, Leslie MP, Baumgaertner MR. Implant options for the treatment of intertrochanteric fractures of the hip: rationale, evidence, and recommendations. *Bone Joint J* 2017; 99-B(01):128–133
- Yoo JH, Kim TY, Chang JD, Kwak YH, Kwon YS. Factors influencing functional outcomes in united intertrochanteric hip fractures: a negative effect of lag screw sliding. *Orthopedics* 2014;37(12): e1101–e1107
- Choy WS, Ahn JH, Ko JH, Kam BS, Lee DH. Cementless bipolar hemiarthroplasty for unstable intertrochanteric fractures in elderly patients. *Clin Orthop Surg* 2010;2(04):221–226
- Kim Y, Moon JK, Hwang KT, Choi IY, Kim YH. Cementless bipolar hemiarthroplasty for unstable intertrochanteric fractures in octogenarians. *Acta Orthop Traumatol Turc* 2014;48(04): 424–430
- Harwin SF, Stern RE, Kulick RG. Primary Bateman-Leinbach bipolar prosthetic replacement of the hip in the treatment of unstable intertrochanteric fractures in the elderly. *Orthopedics* 1990;13 (10):1131–1136
- Stern MB, Angerman A. Comminuted intertrochanteric fractures treated with a Leinbach prosthesis. *Clin Orthop Relat Res* 1987; (218):75–80
- Haentjens P, Casteleyn PP, De Boeck H, Handelberg F, Opdecam P. Treatment of unstable intertrochanteric and subtrochanteric fractures in elderly patients. Primary bipolar arthroplasty compared with internal fixation. *J Bone Joint Surg Am* 1989;71(08): 1214–1225
- Green S, Moore T, Proano F. Bipolar prosthetic replacement for the management of unstable intertrochanteric hip fractures in the elderly. *Clin Orthop Relat Res* 1987;(224):169–177
- Thakkar CJ, Thakkar S, Kathalgere RT, Kumar MN. Calcar femorale grafting in the hemiarthroplasty of the hip for unstable intertrochanteric fractures. *Indian J Orthop* 2015;49(06):602–609
- Zha GC, Liu J, Wang Y, et al. Cementless distal fixation modular stem without reconstruction of femoral calcar for unstable intertrochanteric fracture in patients aged 75 years or more. *Orthop Traumatol Surg Res* 2019;105(01):35–39
- Aro HT, Alm JJ, Moritz N, Mäkinen TJ, Lankinen P. Low BMD affects initial stability and delays stem osseointegration in cementless total hip arthroplasty in women: a 2-year RSA study of 39 patients. *Acta Orthop* 2012;83(02):107–114
- Tsai MC, Ng YY, Chen WM, Tsai SW, Wu SC. The effects of cement fixation on survival in elderly patients with hip hemiarthroplasty: a nationwide cohort study. *BMC Musculoskelet Disord* 2019;20(01):628–635
- Donaldson AJ, Thomson HE, Harper NJ, Kenny NW. Bone cement implantation syndrome. *Br J Anaesth* 2009;102(01):12–22
- Shewale SB, Pandit HG, Latham JM. Hemiarthroplasty: To cement or not to cement? A preliminary report. *Hip Int* 2004;14(03): 189–192
- Figved W, Opland V, Frihagen F, Jervidal T, Madsen JE, Nordsletten L. Cemented versus uncemented hemiarthroplasty for displaced femoral neck fractures. *Clin Orthop Relat Res* 2009;467 (09):2426–2435
- Schulz KF, Altman DG, Moher DCONSORT Group. CONSORT 2010 Statement: Updated guidelines for reporting parallel group randomised trials. *J Clin Epidemiol* 2010;63(08):834–840
- Pfeiffer E. A short portable mental status questionnaire for the assessment of organic brain deficit in elderly patients. *J Am Geriatr Soc* 1975;23(10):433–441
- Harris WH. Traumatic arthritis of the hip after dislocation and acetabular fractures: treatment by mold arthroplasty. An end-result study using a new method of result evaluation. *J Bone Joint Surg Am* 1969;51(04):737–755
- Vishwanathan K, Akbari K, Patel AJ. Is the modified Harris hip score valid and responsive instrument for outcome assessment in the Indian population with pertrochanteric fractures? *J Orthop* 2018;15(01):40–46
- Mahoney FI, Barthel DW. Functional Evaluation: The Barthel Index. *Md State Med J* 1965;14:61–65
- Rabin R, de Charro F. EQ-5D: a measure of health status from the EuroQol Group. *Ann Med* 2001;33(05):337–343
- Chammout G, Kelly-Pettersson P, Hedbeck CJ, Stark A, Mukka S, Sköldenberg O. HOPE-Trial: Hemiarthroplasty Compared with Total Hip Arthroplasty for Displaced Femoral Neck Fractures in Cemented Calcar Replacement Octogenarians: A Randomized Controlled Trial. *JB JS Open Access* 2019;4(02):e0059:1–9
- Singh M, Nagrath AR, Maini PS. Changes in trabecular pattern of the upper end of the femur as an index of osteoporosis. *J Bone Joint Surg Am* 1970;52(03):457–467

- 24 Panula J, Pihlajamäki H, Mattila VM, et al. Mortality and cause of death in hip fracture patients aged 65 or older: a population based study. *BMC Musculoskelet Disord* 2011;12:105–110
- 25 Babhulkar S. Unstable trochanteric fractures: Issues and avoiding pitfalls. *Injury* 2017;48(04):803–818
- 26 Kyle RF. Fractures of the Proximal Part of the Femur. *J Bone Joint Surg Am* 1994;76:924–950
- 27 Mariani EM, Rand JA. Nonunion of intertrochanteric fractures of the femur following open reduction and internal fixation. Results of second attempts to gain union. *Clin Orthop Relat Res* 1987; (218):81–89
- 28 Cobden A, Camurcu Y, Duman S, Kocabiyik A, Kıs M, Saklavcı N. Mid-term survivals of cemented calcar-replacement bipolar hemiarthroplasty for unstable intertrochanteric fractures in elderly patients. *Injury* 2019;50(12):2277–2281
- 29 Göçer H, Coşkun S, Karaismailoğlu N. Comparison of treatment of unstable intertrochanteric fracture with different arthroplasty methods. *Niger Med J* 2016;57(02):81–85
- 30 Wang JS, Pei FX, Shen B, Yang J. Coincidence of avascular necrosis of the femoral head and unstable intertrochanteric fracture: is an extensively coated cementless revision stem a reasonable choice? *J Trauma* 2011;71(06):E137–E139
- 31 Lee YK, Ha YC, Chang BK, Kim KC, Kim TY, Koo KH. Cementless bipolar hemiarthroplasty using a hydroxyapatite-coated long stem for osteoporotic unstable intertrochanteric fractures. *J Arthroplasty* 2011;26(04):626–632
- 32 Abdelkhalek M, Ali AM, Abdelwahab M. Cemented bipolar hemiarthroplasty with a cerclage cable technique for unstable intertrochanteric hip fractures in elderly patients. *Eur J Orthop Surg Traumatol* 2013;23(04):443–448
- 33 Knutson GA. Anatomic and functional leg-length inequality: a review and recommendation for clinical decision-making. Part I, anatomic leg-length inequality: prevalence, magnitude, effects and clinical significance. *Chiropr Osteopat* 2005; 13:11