



Difficult Biliary Cannulation for Intradiverticular Papilla: Forceps Technique Revisited

Mahesh Kumar Goenka, MD, DM¹ Gajanan Ashokrao Rodge, DNB¹ Bhavik Bharat Shah, DNB¹
Shivaraj Afzalpurkar, MD¹

¹Institute of Gastrosiences & Liver, Apollo Gleneagles Hospital, Kadapara, Phool Bagan, Kankurgachi, Kolkata, West Bengal, India

Address for correspondence Mahesh Kumar Goenka, MD, DM, Institute of Gastrosiences & Liver, Apollo Gleneagles Hospital, 58, Canal Circular Road, Kadapara, Phool Bagan, Kankurgachi, Kolkata, West Bengal, 700054, India (e-mail: mkgkolkata@gmail.com).

Surg J (NY) 2021;7:e191–e194.

Abstract

Periampullary diverticula (PAD) have been encountered in 5.9 to 18.5% of patients during all the endoscopic retrograde cholangiopancreatography (ERCP). Cannulation in the presence of PAD can sometimes be difficult, time consuming, and often requires a higher level of endoscopic skills.

Keywords

- ▶ periampullary diverticula
- ▶ ERCP
- ▶ two-devices in one-channel method
- ▶ difficult biliary cannulation

Several techniques have been reported to facilitate and increase the chances of successful bile duct cannulation in the presence of PAD. The two-devices in one-channel method has been sparingly used. It involves the simultaneous use of a biopsy forceps and another instrument, either a cannula or sphincterotome through the same working channel. We successfully performed ERCP in three cases, where bile duct cannulation was performed in the setting of intradiverticular papilla using two-devices in one-channel method.

We feel that the two-devices in one-channel method can be very useful and positioned higher up in the algorithm for successful cannulation in patients with PAD.

Periampullary diverticula (PAD) have been encountered in 5.9 to 18.5% of patients during all the endoscopic retrograde cholangiopancreatography (ERCP).^{1,2} These are categorized according to the location of the major papilla in relation to the diverticulum.^{2,3} Cannulation in the presence of PAD can sometimes be difficult, time consuming, and often requires a higher level of endoscopic skills. Several techniques such as submucosal saline injection, endoclip-assisted cannulation, reversed guidewire method, double endoscope method, cap-assisted cannulation, entering the duodenal diverticulum, and dilation of the diverticular neck by balloon have been reported to facilitate and increase the chances of successful bile duct cannulation in the presence of PAD.^{4–11}

The two-devices in one-channel method has been sparingly used. This method involves the simultaneous use of a biopsy forceps and another instrument, either a cannula or a sphincterotome through the same working channel.^{12,13} While the biopsy forceps is used to bring the papilla out of the diverticulum and stabilize it, biliary cannulation is attempted with the sphincterotome or cannula. Since both

the devices enter the same channel of the therapeutic duodenoscope, it is named as two-devices in one-channel method. We successfully performed ERCP in three cases (–Table 1), where bile duct cannulation was performed in the setting of intradiverticular papilla using two-devices in one-channel method.

Case Series

Case 1

A 78-year-old male presented with complaints of fever, jaundice, and pain abdomen and was diagnosed to have cholangitis with choledocholithiasis. He was referred to our center after a failed attempt at ERCP cannulation. He was a known case of type 2 diabetes mellitus, systemic hypertension, obstructive airway disease, chronic kidney disease, dilated cardiomyopathy, and status post cholecystectomy. At the time of admission, the patient was afebrile and hemodynamically stable. Laboratory parameters revealed a hemoglobin (Hb) of 9.9 g/dL, white blood cell

received

September 3, 2020

accepted after revision

April 15, 2021

DOI <https://doi.org/>

10.1055/s-0041-1731442.

ISSN 2378-5128.

© 2021. The Author(s).

This is an open access article published by Thieme under the terms of the Creative Commons Attribution License, permitting unrestricted use, distribution, and reproduction so long as the original work is properly cited. (<https://creativecommons.org/licenses/by/4.0/>)

Thieme Medical Publishers, Inc., 333 Seventh Avenue, 18th Floor, New York, NY 10001, USA

Table 1 Summary of patient characteristics

Sr. no.	Age	Sex	Diagnosis	Position of papilla in relation to PAD	Method used	Successful CBD cannulation	Adverse events
1	78	Male	Choledocholithiasis with recurrent cholangitis in postcholecystectomy status	7 o'clock	Two-devices in one-channel method	Yes	None
2	54	Female	Choledocholithiasis with obstructive jaundice	5 o'clock	Two-devices in one-channel method	Yes	None
3	52	Male	EHBO with mass in uncinata process and head of pancreas	7 o'clock	Two-devices in one-channel method	Yes	None

Abbreviations: CBD, common bile duct; EHBO, extrahepatic biliary obstruction; PAD, periampullary diverticulum.

counts were 4,500 /mm³, and platelets were 1,30,000/mm³. Liver function tests showed total bilirubin of 2.8 mg/dL, aspartate transaminase (AST) of 273 U/L, alanine transaminase (ALT) of 294 U/L, and alkaline phosphatase (ALP) of 343 U/L. Multiple intraluminal calculi at the distal end of the common bile duct (CBD) with proximal dilatation were seen at magnetic resonance cholangiopancreatography (MRCP) (→Fig. 1A and 1B).

The patient was managed conservatively with intravenous antibiotics and other supportive measures after admission. At ERCP, a therapeutic duodenoscope (channel diameter 4.2 mm) was used, and a large PAD (around 1.5 cm in diameter) was seen in side view endoscopy (→Fig. 1A). The papillary orifice could not be visualized for biliary cannulation. A pediatric biopsy forceps (diameter—2 mm) was used to grasp the inferior lip of the diverticulum, and the diverticular mucosa was pulled out, exposing the papilla, which was located inside the diverticulum at 7 o'clock position. The sphincterotome (diameter—1.8 mm) was used simultaneously, and successful biliary cannulation was achieved (→Fig. 1B). Cholangiogram of the biliary system revealed a filling defect in the CBD (→Fig. 1C) after which endoscopic sphincterotomy and stone extraction were performed. Post-procedure was uneventful and the patient was asymptomatic for 3 months on follow-up.

Case 2

A 54-year-old female, known case of type 2 diabetes mellitus, hypothyroidism, chronic kidney disease, and coronary artery

disease, presented with pain abdomen, jaundice, and vomiting for 2 weeks. At the time of admission, the patient was hemodynamically stable, afebrile, and icterus was present. Laboratory parameters revealed a Hb of 6.5 g/dL, white blood cell counts were 10,100/mm³, and platelets were 90,000/mm³. Liver function tests showed total bilirubin of 9.4 mg/dL (direct bilirubin of 5.9 mg/dL), AST of 46 U/L, ALT of 9 U/L, ALP of 328 U/L, and gamma-glutamyl transpeptidase (GGT) of 164 U/L. MRCP showed chronic calculous cholecystitis and choledocholithiasis with dilated intrahepatic biliary radicles.

During ERCP, a large PAD (around 2 cm in diameter) was seen with the papillary orifice at 5 o'clock position in relation to the diverticulum. Two-devices in one-channel method, as described above, was used and biliary cannulation was attempted by simultaneous use of pediatric biopsy forceps and sphincterotome (→Fig. 2A). Guidewire inadvertently entered in the main pancreatic duct (MPD), after which pancreatic duct assisted CBD cannulation was done. Cholangiogram of the biliary system revealed dilated CBD with a filling defect (→Fig. 2B), after which endoscopic sphincterotomy and removal of stone were performed. A plastic stent was deployed in PD (5 Fr × 5 cm) and another plastic stent was positioned in the CBD (10 Fr × 10 cm). Postprocedure was uneventful and the patient was asymptomatic for 3 weeks on follow-up.

Case 3

A 52-year-old male, known case of type 2 diabetes mellitus, presented with jaundice and fever for the last 2 weeks. On

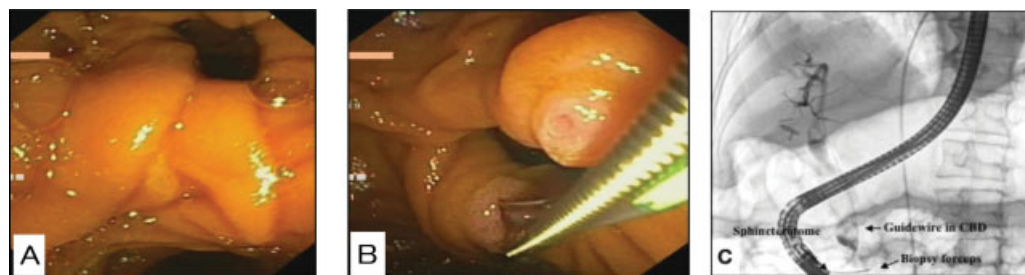

Fig. 1 (A) Side view endoscopy showing a large periampullary diverticulum. Papilla could not be identified. (B) Sphincterotome and biopsy forceps being used simultaneously to explore the papilla and facilitate cannulation. (C) Fluoroscopy image showing biliary cannulation by simultaneous use of biopsy forceps and sphincterotome.

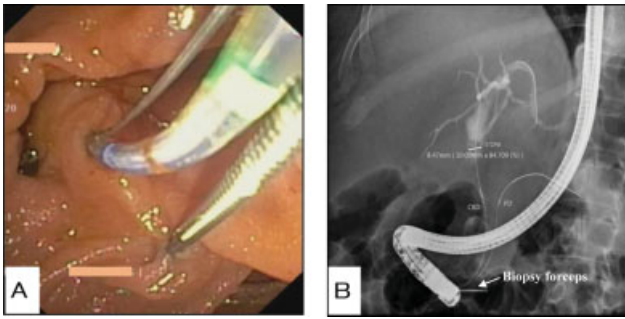


Fig. 2 (A) Sphincterotome and biopsy forceps being used simultaneously leading to exposure of papilla and successful cannulation. (B) Fluoroscopy image showing pancreatic duct-assisted biliary cannulation by simultaneous use of biopsy forceps and sphincterotome.

admission, the patient was hemodynamically stable, febrile and icterus was present. Laboratory parameters showed a Hb of 12.4 g/dL, white blood cell counts were 9,200/mm³ and platelets were 5,94,000/mm³. Liver function tests showed total bilirubin of 12.5 mg/dL (direct bilirubin of 7.5 mg/dL), AST of 105 U/L, ALT of 120 U/L, ALP of 1,297 U/L, and GGT of 807 U/L. Carbohydrate antigen 19-9 levels were 220 U/mL. Computed tomography abdomen revealed an ill-defined hypodense mass in the head and uncinate process of pancreas with dilated CBD and MPD, likely carcinoma head of the pancreas.

At ERCP, a PAD was visualized with the papillary orifice at 7 o'clock position in relation to the diverticulum. Two-devices in one-channel method as described in the first case was used, and biliary cannulation was attempted with the simultaneous use of pediatric biopsy forceps and sphincterotome. Cholangiogram of the biliary system revealed stricture in lower CBD with upstream dilatation. Brush

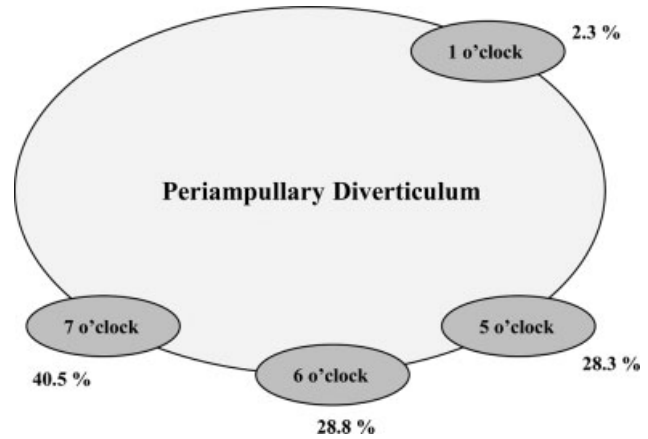


Fig. 3 Different locations of the papilla in relation to the diverticulum. (Adapted and modified from Parlak et al.²)

cytology was taken from the stricture area. Biliary sphincterotomy was done, and a 6 cm fully covered self-expanding metal stent was deployed across the stricture. Subsequent liver function tests showed a downward trend. Brush cytology from CBD did not show any malignant cells and subsequent endoscopic ultrasound-guided fine needle aspiration from the pancreatic head mass was suggestive of adenocarcinoma. Postprocedure was uneventful, and the patient was asymptomatic for 3 weeks on follow-up.

Discussion

ERCP in patients with PAD requires the use of specialized techniques and an experienced endoscopist. Out of the 410 cases who underwent ERCP during the study duration, PAD was seen in 34 cases. Cannulation was achieved successfully

Table 2 ERCP techniques to facilitate biliary cannulation in presence of PAD

Sr. no.	Technique	Devices used	Remarks
1	PD stent placement followed by precut sphincterotomy	PD stent precut needle knife	Stent placement keeps papilla out of the diverticulum
2	Submucosal saline injection	Saline injector	2–4 mL of normal saline is injected in the submucosa that enables intradiverticular papillary eversion
3	Endoclip-assisted cannulation	Endoclips	Endoscopic clips evert and stabilize the papillary opening
4	Reversed guidewire method	Reversed guidewire (stiff end forward)	Reverse end of the guidewire used to push papillary mucosa toward the lumen and thus everting the papilla
5	Double endoscope method	Duodenoscope, gastroscope, FB forceps	Grasping tissue adjoining the papilla with forceps through the gastroscope followed by insertion of the duodenoscope
6	Cap-assisted cannulation	Transparent cap, papillotome	Papillary orifice is directly seen using cap-assisted forward viewing endoscopy
7	Entering the diverticulum	Duodenoscope	Enter the duodenal diverticulum with distal end of the duodenoscope
8	Dilatation of the diverticular neck by balloon	Stone retrieval balloon	Intradiverticular balloon dilatation allows eversion of the papilla
9	Two-devices in one-channel method	Biopsy forceps, catheter (cannula, sphincterotome)	Simultaneous use of biopsy forceps and sphincterotome

Abbreviations: ERCP, endoscopic retrograde cholangiopancreatography; FB, foreign body; PAD, periaampullary diverticulum; PD, pancreatic duct.

by the standard technique in 31 cases with PAD; however, despite 10 minutes of efforts, cannulation was not achieved in three patients for whom the two-devices in one-channel method was used.

Ease of cannulating the papilla also depends on the position according to the diverticulum. ►**Fig. 3** shows the different locations of the papilla in relation to the diverticulum.² Cannulation procedures are more difficult in the 1 o'clock position as compared with the other locations of the papilla. The rates of successful cannulation reported in PAD patients vary from 61 to 95.4%, which are markedly lower than that seen in patients without PAD.¹⁴

Patients with PAD are more likely (1.8–6 times) to have retained CBD stones as compared with those without PAD.^{15,16} The possible factors leading to increased formation of biliary stones in the presence of PAD are dysfunction in the sphincter of Oddi,¹⁷ diverticula causing spasm of the sphincter, and increased biliary tract pressure¹⁸ or diverticula, leading to biliary stasis by compression of the distal part of the CBD.¹⁹

Several methods have been described in the literature to facilitate difficult biliary cannulation in the presence of PAD that has been summarized in ►**Table 2**. The method to be used counts on the endoscopist's choice and patient conditions. The central goal of the different techniques is to bring the papilla in a better position and angle, suitable for cannulation. We have successfully used the two-devices in one-channel method in three cases with PAD. We feel that this can be a very useful technique that can be positioned higher up in the algorithm for successful cannulation in patients with PAD.

Financial Support and Sponsorship

Nil.

Author Contributions

Mahesh Goenka was involved in conceptualization, methodology, supervision, writing, reviewing, and editing.

Gajanan Rodge was involved in visualization, data curation, writing, original draft preparation, and investigation. Bhavik Shah and Shivaraj Afzalpurkar were involved in writing, reviewing, and editing of the manuscript.

Conflict of Interests

None.

References

- 1 Fogel EL, Sherman S, Lehman GA. Increased selective biliary cannulation rates in the setting of periampullary diverticula: main pancreatic duct stent placement followed by pre-cut biliary sphincterotomy. *Gastrointest Endosc* 1998;47(05):396–400
- 2 Parlak E, Suna N, Kuzu UB, et al. Diverticulum with papillae: does position of papilla affect technical success? *Surg Laparosc Endosc Percutan Tech* 2015;25(05):395–398
- 3 Boix J, Lorenzo-Zúñiga V, Añaños F, Domènech E, Morillas RM, Gassull MA. Impact of periampullary duodenal diverticula at endoscopic retrograde cholangiopancreatography: a proposed classification of periampullary duodenal diverticula. *Surg Laparosc Endosc Percutan Tech* 2006;16(04):208–211
- 4 Harada H, Suehiro S, Shimizu T, Katsuyama Y, Hayasaka K. Submucosal injection can facilitate biliary access in patients with periampullary diverticula. *Gastrointest Endosc* 2016;84(01):185–186
- 5 Cappell MS, Mogrovejo E, Manickam P, Batke M. Endoclips to facilitate cannulation and sphincterotomy during ERCP in a patient with an ampulla within a large duodenal diverticulum: case report and literature review. *Dig Dis Sci* 2015;60(01):168–173
- 6 Kim HJ, Kim YS, Myung SJ, et al. A novel approach for cannulation to the ampulla within the diverticulum: double-catheter method. *Endoscopy* 1998;30(09):S103–S104
- 7 Elmunzer BJ, Boetticher NC. Reverse guidewire anchoring of the papilla for difficult cannulation due to a periampullary diverticulum. *Gastrointest Endosc* 2015;82(05):957
- 8 Külling D, Haskell E. Double endoscope method to access intradiverticular papilla. *Gastrointest Endosc* 2005;62(05):811–812
- 9 Myung DS, Park CH, Koh HR, et al. Cap-assisted ERCP in patients with difficult cannulation due to periampullary diverticulum. *Endoscopy* 2014;46(04):352–355
- 10 Wang BC, Shi WB, Zhang WJ, et al. Entering the duodenal diverticulum: a method for cannulation of the intradiverticular papilla. *World J Gastroenterol* 2012;18(48):7394–7396
- 11 Tóth E, Lindström E, Fork FT. An alternative approach to the inaccessible intradiverticular papilla. *Endoscopy* 1999;31(07):554–556
- 12 Fujita N, Noda Y, Kobayashi G, Kimura K, Yago A. ERCP for intradiverticular papilla: two-devices-in-one-channel method. *Gastrointest Endosc* 1998;48(05):517–520
- 13 Inamdar S, Stein PH, Han D, Trindade AJ, Sejjal DV. Difficult biliary cannulation achieved in the setting of periampullary diverticulum with the simultaneous use of biopsy forceps and wire-guided cannulation. *VideoGIE* 2017;2(02):25–26
- 14 Zoepf T, Zoepf DS, Arnold JC, Benz C, Riemann JF. The relationship between juxtapapillary duodenal diverticula and disorders of the biliopancreatic system: analysis of 350 patients. *Gastrointest Endosc* 2001;54(01):56–61
- 15 Rajnakova A, Goh PM, Ngoi SS, Lim SG. ERCP in patients with periampullary diverticulum. *Hepatogastroenterology* 2003;50(51):625–628
- 16 Mohammad Alizadeh AH, Afzali ES, Shahnazi A, et al. ERCP features and outcome in patients with periampullary duodenal diverticulum. *ISRN Gastroenterol* 2013;2013:217261
- 17 Yildirgan MI, Başoğlu M, Yılmaz I, et al. Periampullary diverticula causing pancreaticobiliary disease. *Dig Dis Sci* 2004;49(11–12):1943–1945
- 18 Hagège H, Berson A, Pelletier G, et al. Association of juxtapapillary diverticula with choledocholithiasis but not with cholecystolithiasis. *Endoscopy* 1992;24(04):248–251
- 19 Miyazaki S, Sakamoto T, Miyata M, Yamasaki Y, Yamasaki H, Kuwata K. Function of the sphincter of Oddi in patients with juxtapapillary duodenal diverticula: evaluation by intraoperative biliary manometry under a duodenal pressure load. *World J Surg* 1995;19(02):307–312