



Arthroscopy Limits on Anterior Shoulder Instability

Limites da artroscopia na instabilidade anterior do ombro

Jair Simmer Filho¹ Raul Meyer Kautsky¹

¹Hospital Santa Rita, Vitória, ES, Brazil

Rev Bras Ortop 2022;57(1):14–22.

Address for correspondence Raul Meyer Kautsky, M.D., Rua Carlos Eduardo Monteiro de Lemos, 262, sala 209, Jardim da Penha, Vitória, ES, 29060-120, Brasil (e-mail: raulkautsky@gmail.com).

Abstract

Much is discussed about the limits of the treatment of anterior shoulder instability by arthroscopy. The advance in understanding the biomechanical repercussions of bipolar lesions on shoulder stability, as well as in the identification of factors related to the higher risk of recurrence have helped us to define, more accurately, the limits of arthroscopic repair. We emphasize the importance of differentiation between glenoid bone loss due to erosion (GBLE) and glenoid edge fractures, because the prognosis of treatment differs between these forms of glenoid bone failure. In this context, we understand that there are three types of bone failure: a) bone Bankart (fracture); b) combined; and c) glenoid bone loss due to anterior erosion (GBLE), and we will address the suggested treatment options in each situation.

Until recently, the choice of surgical method was basically made by the degree of bone involvement. With the evolution of knowledge, the biomechanics of bipolar lesions and the concept of *glenoid track*, the cutoff point of critical injury, has been altered with a downward trend. In addition to bone failures or losses, other variables were added and made the decision more complex, but a little more objective.

The present update article aims to make a brief review of the anatomy with the main lesions found in instability; to address important details in arthroscopic surgical technique, especially in complex cases, and to bring current evidence on the issues of greatest divergence, seeking to guide the surgeon in decision making.

Keywords

- ▶ shoulder joint
- ▶ arthroscopy
- ▶ glenoid cavity
- ▶ rotator cuff injuries
- ▶ shoulder injuries
- ▶ shoulder dislocation

Resumo

Muito se discute sobre os limites do tratamento da instabilidade anterior do ombro por artroscopia. O avanço no entendimento das repercussões biomecânicas das lesões bipolares sobre a estabilidade do ombro, bem como na identificação de fatores relacionados ao maior risco de recidiva têm nos ajudado a definir, de forma mais apurada, os limites do reparo por via artroscópica.

Ressaltamos a importância de diferenciação entre perda óssea por erosão da glenoide (POAG) e fraturas da borda da glenoide, pois o prognóstico do tratamento diverge entre essas formas de falha óssea da glenoide. Neste contexto, entendemos que há três tipos de falha óssea: a) Bankart ósseo (fratura); b) combinada; e c) POAG, e abordaremos as opções de tratamento sugerido em cada situação.

Palavras-chave

- ▶ articulação do ombro
- ▶ artroscopia
- ▶ cavidade glenoide
- ▶ lesões do manguito rotador
- ▶ lesões do ombro
- ▶ luxação do ombro

received

December 7, 2020

accepted after revision

January 15, 2021

published online

October 25, 2021

DOI <https://doi.org/>

10.1055/s-0041-1731357.

ISSN 0102-3616.

© 2021. Sociedade Brasileira de Ortopedia e Traumatologia. All rights reserved.

This is an open access article published by Thieme under the terms of the Creative Commons Attribution-NonDerivative-NonCommercial-License, permitting copying and reproduction so long as the original work is given appropriate credit. Contents may not be used for commercial purposes, or adapted, remixed, transformed or built upon. (<https://creativecommons.org/licenses/by-nc-nd/4.0/>)

Thieme Revinter Publicações Ltda., Rua do Matoso 170, Rio de Janeiro, RJ, CEP 20270-135, Brazil

Até há pouco tempo, a escolha do método cirúrgico era norteadada basicamente pelo grau de acometimento ósseo. Com a evolução do conhecimento, da biomecânica das lesões bipolares e do conceito do *glenoid track* (trilho da glenoide), o ponto de corte da lesão crítica, vem sendo alterado com tendência de queda. Além das falhas ou perdas ósseas, outras variáveis foram adicionadas e tornaram a decisão mais complexa, porém um pouco mais objetiva.

O presente artigo de atualização tem como objetivo fazer uma breve revisão da anatomia com as principais lesões encontradas na instabilidade; abordar detalhes importantes na técnica cirúrgica artroscópica, em especial nos casos complexos, e trazer as evidências atuais sobre os assuntos de maior divergência, buscando guiar o cirurgião na tomada de decisão.

Introduction

Arthroscopy is widely used in the treatment of anterior shoulder instability and has results comparable to open repair techniques.¹ The progress in understanding the biomechanical repercussions of bipolar lesions on shoulder stability, as well as in the identification of factors related to the higher risk of recurrence,^{1,2} have helped us to define more accurately the limits of arthroscopic repair.

The surgeon should reason the data and the patient's expectations, as well as be trained and comfortable to use the surgical resources and techniques based on the most recent evidence. Thus, good results can be achieved with arthroscopic treatment, including in high-demand athletes.³

The objective of the present work is to discuss the limits of arthroscopic labrum-ligament repair in the treatment of anterior shoulder instability.

Surgical anatomy and major lesions found in instability

The shoulder joint has a large range of motion (ROM) at the expense of a shallow glenoid articulating with an almost spherical humerus head. This inherently unstable configuration relies on other structures for the prevention of instability, including static stabilizers (bone architecture, glenoidal labrum, joint capsule, and glenohumeral ligaments). Additionally, the coordination of dynamic muscle forces generated by the rotator cuff and adequate control of scapular positioning are fundamental to maintain stability.⁴

The structures most commonly injured in anterior dislocation are: the anterior labrum, the anterior edge of the glenoid, the joint capsule and the anterior bundle of the lower glenohumeral ligament, as well as the posterosuperior impaction of the humeral head, also known as Hill-Sachs lesion (HSL). Occasionally, there may be an associated lesion of the rotator cuff;⁴ as well as chondral detachment on the articular surface of the humerus and glenoid.

Labrum-ligament complex

The glenoidal labrum is the fibrocartilaginous structure where the capsule and the upper, middle and lower

glenohumeral ligaments are inserted medially. In addition, the labrum increases the surface area and depth of the glenoidal cavity, serving as a type of anterior bulkhead to the humerus head. The anteroinferior detachment of the glenoidal labrum was described by Bankart⁵ as the essential lesion necessary to cause anterior instability. Bankart lesion, as it is commonly known, may be just labrum detachment or have a bony avulsion of the anterior edge of the associated glenoid (commonly called bony Bankart). An isolated Bankart lesion results in a loss of between 7 and 5% of the contact area of the joint,⁶ but isolated labrum detachment may not be sufficient to produce anterior glenohumeral instability. Biomechanical studies show that stretching of the anterior capsule and its associated ligaments is necessary to create glenohumeral instability.⁷

In some cases, the labrum-ligament complex may be avulsed from the anterior edge of the glenoid along with the periosteum and heal medially in the glenoid neck, which is known as anterior labrum-ligament periosteal sleeve avulsion (ALPSA) lesion.^{8,9} This lesion is distinguished from the classical Bankart lesion, as it practically only occurs in cases of chronic instability. Failure to identify this lesion, to mobilize and to restore the labrum to its original position is associated with higher recurrence rates after arthroscopic repair.^{9,10}

Another lesion of the labrum-ligament complex that is also distinguished from Bankart lesion is the glenoid labrum articular disruption (GLAD) injury. In this lesion, there is rupture and detachment of a fragment of articular cartilage of the glenoid near the labrum, often with elevation of a cartilaginous flap, exposing the subchondral bone.⁸ The GLAD lesion is also associated with a higher rate of recurrence of instability by modifying the version of the articular surface. The loss of part of the cartilage in the anterior region of the glenoid, even with intact bone, may generate an anteversion that would facilitate recurrence.²

The anterosuperior quadrant of the glenoid has anatomical variations (sublabral foramen and Buford complex) prevalent in up to 25% of arthroscopies for instability,¹¹ being very important to recognize them in order to differentiate them from pathological changes during joint inspection, thus avoiding inadequate treatment. In the presence of a sublabral foramen, the labrum is partially inserted into the

anterior edge of the glenoid, while in the Buford complex the anterosuperior labrum is absent. These changes seem to predispose to the development of a superior labrum anterior and posterior (SLAP) lesion and the finding of a cord like medium glenohumeral ligament should draw the attention of the surgeon to these variations.^{11,12}

More rarely (between 1 and 9% of cases), we may encounter lower humeral avulsion of the glenohumeral ligament (HAGL). This lesion is often related to high-energy trauma,¹³ and it may also be present in cases with large bone losses in the glenoid.¹⁴ The inferior glenohumeral ligament (IGHL) is formed by the anterior and posterior bundles with the axillary recess between both. The HAGL lesion can then be classified according to the involvement of the anterior IGHL (AHAGL) or to the posterior IGHL (PHAGL).^{10,13} A bipolar lesion may also occur, where a HAGL lesion and an anterior labial lesion (floating HAGL) coexist.¹³

Glenoid

The glenoid is pear-shaped and measures 5 cm in its cranio-caudal dimension and 2.5 cm in the anteroposterior dimension of its lower half. The glenoid is relatively shallow, with a concavity measuring 2.5 mm deep; thus, providing a limited restriction to humeral translation. The anteroinferior edge of the glenoid is very important for anterior glenohumeral stability and is compromised in 90% of cases of instability.¹⁵ In these situations, there are bone failures that can be caused by an acute fracture (bony Bankart) or by bone erosion after numerous episodes of dislocation that we consider as an anterior glenoid bone loss due to erosion (GBLE), or even a combination of GBLE with partially reabsorbed bone fragment. It is important to highlight the difference between GBLE and glenoid edge fracture (► **Figure 1**). When there is a viable bone fragment, whether acute or chronic, we should not consider it as a GBLE itself.^{16,17} Incorporating the bone

fragment into arthroscopic labrum repair offers advantages in the face of an invasive and nonanatomical bone graft procedure¹⁸ (► **Figure 2**). Sugaya et al.¹⁶ described good results with arthroscopic repair of bone fragments that had an average of 24.8% (ranging from 11.4 to 38.6%) of the diameter of the glenoid. Functional results tend to be satisfactory with the consolidation of the fragment even in cases in which there is partial resorption in preoperative examinations. Studies have shown a potential remodeling

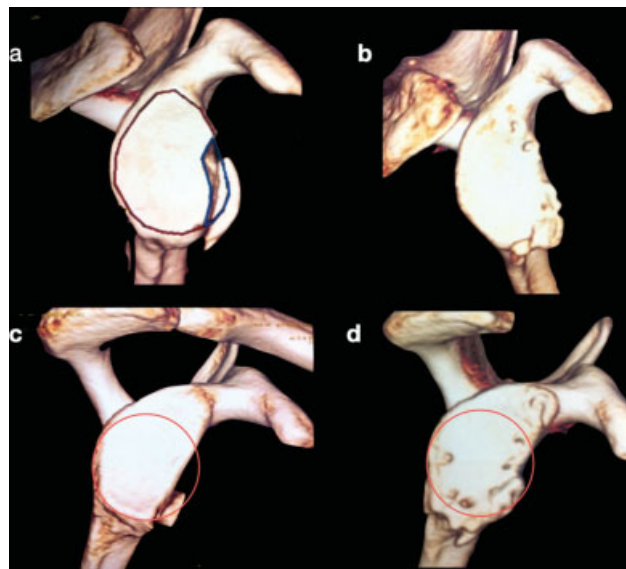


Fig. 2 Images of 3D tomographic reconstruction, before and after surgery, in cases of bone failure that were treated arthroscopically. (A) Fracture (bony Bankart) at the anterior edge of the glenoid with viable fragment. (B) Late postoperative arthroscopic repair of case A. (C) Combined bone failure in which there is erosion of the glenoid with partially reabsorbed bone fragment. (D) Late postoperative in the case with combined bone failure evidencing remodeling of the bone structure after repair, with the recovery of much of the lower circle of the glenoid.

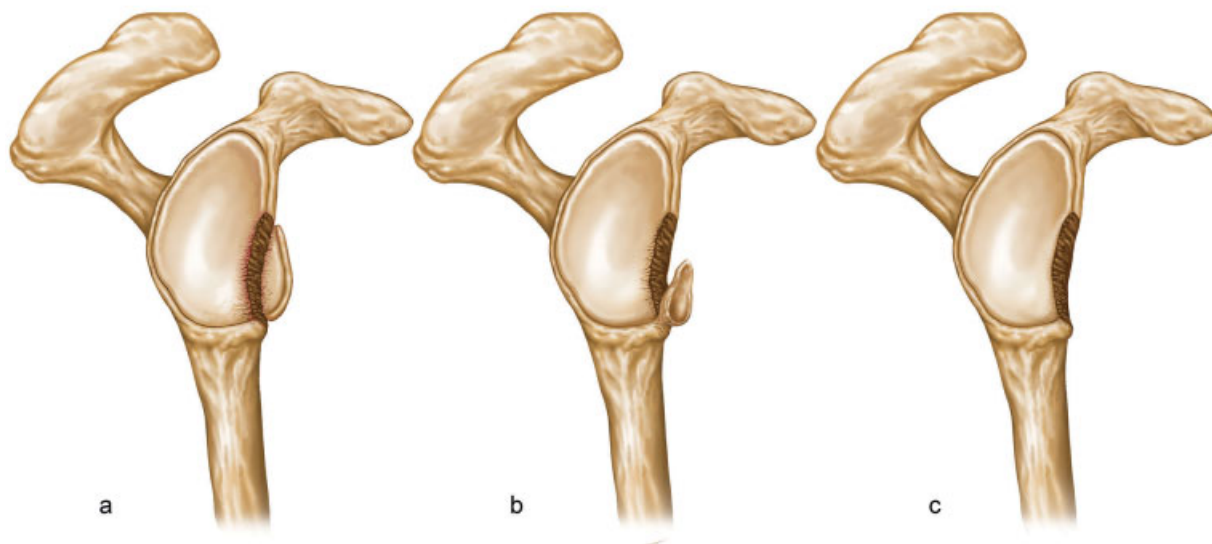


Fig. 1 Illustration representing the types of glenoid bone failure found in anterior shoulder instability. (A) Presence of fracture (bony Bankart) with viable bone fragment. (B) Combined, in which there is a partially reabsorbed bone fragment associated with glenoid erosion. (C) Glenoid bone loss due to erosion (GBLE).

Table 1 Suggested treatment according to types of bone failure found

Types of bone failure	Failure presentation	Conduct
Bony Bankart/Fracture	Viable bone fragment	Consider arthroscopic repair, especially if fragment < 25% of the anteroposterior diameter of the glenoid.
Combined	Erosion + partially reabsorbed fragment	Consider arthroscopic repair when there is a possibility of reconstruction of 80% of the area of the lower circle of the glenoid
Bone loss (GBLE)	Erosion	Consider bone graft depending on failure size and demand

and recovery of bone structure after repair,^{17,18} with a tendency to normalize the morphology of the glenoid in the medium and long term.¹⁸ Jiang et al.¹⁷ demonstrated a low recurrence rate after surgery when preoperative tomographic evaluation projects the possibility of recovery of at least 80% of the area of the lower circle of the glenoid after fragment reduction. **Table 1** summarizes conduct guidelines that can be considered based on the type of bone failure found in the glenoid. Bone losses (GBLE) with erosion of 20% at the anterior edge of the glenoid can significantly reduce the force required for anterior glenohumeral translation,¹⁹ as well as produce a loss of ~ 30% of the joint contact area.⁶ In 2000, Burkhart et al.²⁰ observed a high rate of recurrence of instability (61%) after arthroscopic treatment in cases with significant GBLE, in which the glenoid seen by the upper portal presented the aspect of "inverted pear". Based on another study by Bigliani et al.,²¹ the authors defined that the critical lesion for arthroscopic treatment would be the loss of 25% of the anteroposterior diameter.

This cutoff point between 20 and 25% loss of the anteroposterior diameter of the glenoid has been revised and tends to be reduced. Shaha et al.²² analyzed a group of patients formed by military personnel with high functional demand and recommended a review of bone lesions considered "critical" to the level of 13.5%. Shin et al.,²³ in a case-control study with 169 patients with anterior instability and GBLE, defined that a loss $\geq 17.3\%$ would lead to a higher recurrence rate after isolated arthroscopic labrum repair. Other authors have indicated bone block surgeries even for bone lesions ~ 10%.²⁴ In general, the current discussion about "critical injury" has revolved around a limit between 13.5 and 15% of GBLE, which may not be easy to distinguish in daily practice. For this reason, there is a tendency to establish an integer for "critical injury" (15% GBLE).^{25,26}

Humerus head

Postero-supero-lateral impaction of the humerus head against the anterior edge of the glenoid can lead to bone deformation. Hill-Sachs lesion occurs in between 40 and 90% of anterior shoulder dislocation events, although it is present in 100% of recurrent cases.²⁷ This humeral bone failure is important in the recurrence of instability, as it can fit the anterior edge of the glenoid during abduction movement with lateral rotation (engaging Hill-Sachs),²⁰ increasing the

risk of recurrence after isolated repair of Bankart lesion.^{28,29} This risk can be mitigated by associating the remplissage procedure,²⁸ especially in cases in which there is fit without significant GBLE.³⁰

Rotator cuff

The rotator cuff and the long head tendons of the biceps arm muscle play a key role in dynamic shoulder stability. The incidence of these lesions increases with age and with the number of episodes, being higher in patients with primodislocation after the age of 40 years old.⁴ Lesions range from partial joint injuries that require only debridement¹⁰ to complete lesions, in which repair is required. Complete rotator cuff lesions occur more in patients between 40 and 60 years old, are usually posterosuperior, and are strongly associated with the number of dislocations, especially when there are > 7 episodes.³¹

Bipolar shoulder injury and glenoid track concept

The name of bipolar lesion is used for cases of glenohumeral instability with bone losses both in the anterior rim of the glenoid and in the posterolateral region of the humeral head (HSL). Its prevalence can vary between 62 and 84% of cases of anterior recurrent shoulder dislocation^{26,32} and this percentage increases significantly according to the number of episodes of dislocation and to the type of sport.³² Nakagawa et al.³² observed an average prevalence of bipolar injuries in 33% of cases of primary instability against 61.8% of cases of instability recurrence. In the same study, the authors found a prevalence of 58.9% in cases of collision sports, of 53.3% in contact sports, and of 29.4% in sports that use the arm above the head; the difference between the first 2 groups (collision and contact athletes) and sports with the arm above the head group is statistically significant.

Currently, the mechanism of the dynamic relationship of these bone losses and their contribution to the episodes of shoulder dislocation and recurrence of surgical treatment are recognized as decisive for the choice of surgical technique, and should be routinely addressed during the treatment of glenohumeral instability.^{3,25,26}

Understanding the role of bone losses in the treatment of anterior shoulder instability continues to evolve.

Historically, emphasis has been placed on bone losses in the glenoid. Although HSL was also pointed out as a risk factor for recurrence, it was not evaluated in conjunction with anterior GBLE. Only more recently, through the glenoid track concept, there has been the development of a better understanding of the role of humeral bone loss, as well as the way it interacts biomechanically with anterior bone loss in the glenoid.

The glenoid track concept emphasizes the importance of preoperative evaluation of bipolar lesions to determine the possibility of fitting the HSL during the shoulder range of motion and thus try to guide the best approach strategy. It provides us with a practical form of evaluation and has been validated by clinical and biomechanical studies as a way to help preventing poor outcomes in the treatment of instability.^{1,22,33-35} Failure to identify the docking mechanism may result in recurrence and eventual need for surgical revision.

Yamamoto et al.³⁵ introduced this concept in 2007 and helped to understand the biomechanical interaction between GBLE and HSL. Their study in cadavers showed that the glenoid track is equivalent to ~ 84% of the width of a normal glenoid, discounting 16% equivalent to the space occupied by the insertion of the rotator cuff when the arm is in 60° abduction, horizontal extension and maximum lateral rotation, simulating the apprehension test. Thus, the presence of bone defects in the anterior edge determines a reduction in the anteroposterior diameter of the glenoid, and consequently a narrower rail for excursion of the humerus head. On the other hand, the larger and/or more medial the HSL, the more likely it is to fit into the anterior edge of the glenoid,¹⁹ and, apparently, it is unreliable to only make the isolated repair of Bankart injuries due to the great risk of continuing to fit the glenoid and, consequently, of recurrence of instability.

In 2014, in a joint study between Di Giacomo et al.,³⁰ the concept of glenoid track has become more widely disseminated. The authors evaluated bilateral computed tomography scans of patients with anterior shoulder instability and were able to predict which HSL would generate engaging. Thus, the glenoid track concept can predict a higher risk of dislocation recurrence when HSL fits into the glenoid, known as off-track injury, and a lower risk when the HSL does not fit the glenoid, known as on-track injury. In another study, Locher et al.¹ evaluated retrospectively 100 patients and reported that off-track HSL was an important risk factor for recurrence of instability after arthroscopic repair of Bankart lesions.

Hartzler et al.³⁶ conducted a biomechanical study evaluating shoulder stability in the repair of Bankart lesions alone compared with the repair associated with the remplissage procedure. The results showed that, with the shoulder at 90° of abduction and 90° of lateral rotation, the isolated labrum repair prevented the fitting of the HSL in all cases of 15% of GBLE associated with an HSL of 15% (on-track). On the other hand, the isolated labrum repair did not prevent the fitting of HSL in any of the cases of 15% of GBLE associated with an off-track HSL. This study corroborates the concept of glenoid track and the dynamics of the interaction between bone failure at the anterior glenoid edge and HSL.

As mentioned above, bipolar lesions and the glenoid track concept are well established, with off-track injuries associated with higher recurrence rates after isolated Bankart repairs, since this type of ligament repair does not correct bone defects such as the Latarjet and remplissage procedures.³⁵ Some authors have developed algorithms to facilitate clinical decision making. In 2014, Di Giacomo et al.³⁰ established an algorithm for the treatment of bipolar lesions based on the concept of the glenoid track, using a 25% GBLE limit for arthroscopic labrum repair. In 2019, this algorithm was reviewed by Gowd et al.,²⁵ reducing the GBLE limit to 15%. Both studies do not consider risk factors related to patients (age, activity level, expectations, sports contact/collision and ligament laxity), nor the possibility of incorporating bone fragments from the glenoid. As an example of situations not contemplated, we can mention the possibility of arthroscopic treatment in sedentary and low-demand patients with intermediate bone loss. On the other hand, in the same category of bone loss (intermediate), we can indicate the reconstruction of the glenoid with bone graft in patients with high demand and/or in contact/collision athletes. In 2020, Di Giacomo et al.²⁶ proposed a new algorithm contemplating these situations, aiming to facilitate clinical decision-making (► **Figure 3**).

Arthroscopic treatment

Arthroscopic shoulder stabilization is widely performed and has the advantage of evaluating the joint more effectively and reliably, and other lesions that may not be noticed on preoperative physical examination or that are not documented in imaging associated with anterior labrum detachment may be diagnosed, documented and treated.^{4,37} Arthroscopy offers lower morbidity and better cosmetics, besides reducing the chance of problems in the subscapularis muscle (insufficiency and/or adhesions) because it is not necessary to highlight or to divide the tendon to expose the joint.⁴

The success of the treatment depends on the selection of patients and details in the execution of the technique. There are some factors that may be associated with a higher risk of relapse from instability and that should be thoroughly evaluated by the attending physician to guide the best surgical indication. The most impacting factors for the risk of recurrence of anterior instability are bipolar injuries and the level of patient activity (contact and collision sports).^{25,26,38} Other risk factors are: young patient, male, many previous episodes, ligament hyperlaxity, HSL, bone failures in the glenoid, ALPSA lesion, and GLAD lesion.^{1,2,26,37,39}

Following the criteria of indication and selection of patients, as well as performing the arthroscopic technique based on current evidence, we can obtain good and excellent results even in collision and/or contact athletes,³ especially when operated after the first episode.⁴⁰ Leroux et al.,³ in a systematic review, evaluated the results of arthroscopic treatment of anterior instability in collision and contact athletes. They found an overall failure rate of ~ 18%.

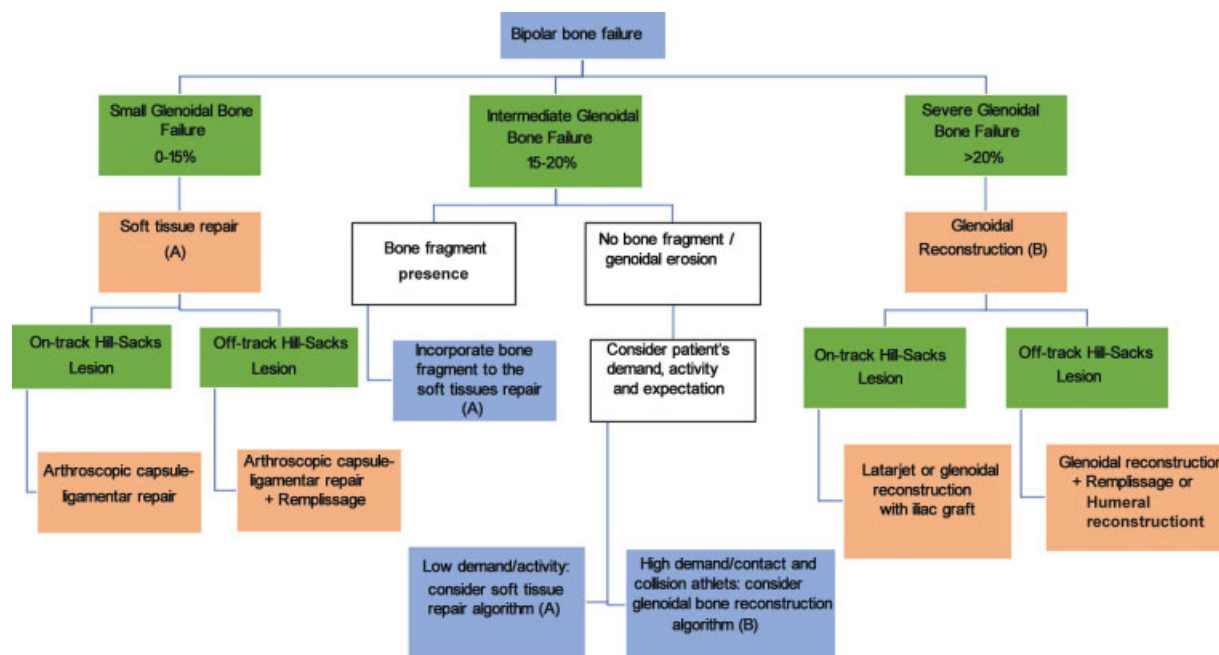


Fig. 3 New algorithm proposed by Giacomo et al.²⁶ considering the possibility of incorporation of the bone fragment and the degree of patient activity in intermediate bone lesions.

However, when filtering only the studies that excluded athletes with significant bone losses, surgery performed in lateral decubitus and using a minimum of 3 anchors, the failure rate dropped to 8%.³

Arthroscopic technique

Some details can make a big difference to improve arthroscopic technique results in the treatment of anterior shoulder instability. We have summed up some tips (► **Table 2**) that we consider important because they can help in daily practice, which will be addressed below.

Patient position

Good results can be obtained regardless of positioning, although lateral decubitus may offer some advantages.³ The vision through the anterosuperior portal, as well as the easy alternation between the portals allows simultaneous access to the anterior and posterior part of the shoulder, facilitating joint inspection, the observation of possible anterior, inferior and posterior capsular redundancy to evaluate tissue quality, besides facilitating implant insertion and balanced capsuloligamentar tensioning.

Portals and cannulas

Arthroscopic portals should be established with care as they are of paramount importance for the success of the procedure. Poorly positioned portals create difficulties such as cannula conflict and exaggerated infiltration of the shoulder, hindering instrumentation, bone bed preparation, and the precise passage of suture points, as well as impairing the angle of attack for anchor placement. The surgeon should be

prepared to perform the most diverse portals, safely accessing all quadrants of the glenoid, since some lesions of the posterior and superior labrum are only evidenced in the intraoperative period.^{37,41,42} All these portals can be safely performed in the outside-in shape using a needle or percutaneous guide.⁴² In addition to the posterior, anterior, and anterosuperior portals, we must also master the execution of the posterior accessory (which provides access to the posteroinferior quadrant) portal, of the trans-subscapular or 5-hour portal (which provides access to the anteroinferior quadrant), and to the Wilmington and Rothmann portals (which provide access to the posterosuperior quadrant).⁴³

In 2008, Simmer Filho et al.⁴⁴ showed the safety and reproducibility of the routine use of the trans-subscapular portal (5-hour portal) used in a series of 126 cases of arthroscopic labrum repair, in which they did not observe any neurovascular alteration.

The placement of three cannulas (two anterior through the anterior and anterosuperior portals and one by the posterior portal) facilitates instrumentation and visualization changes during surgery, maintains stable serum pressure within the joint, and reduces tissue infiltration throughout the procedure.

Anchors

For good repair, it is recommended to have an adequate number of anchors available, since the labral lesion is often more extensive than it appears in imaging.³⁷ In previous dislocations, it is recommended to use at least three or four anchors to reduce the chance of recurrence.⁴⁵ Preferably, these anchors should be made from a material that integrates into the bone to avoid future complications.⁴⁶ More recently, "knotless" implants have been suggested for use as a way to

Table 2 Tips and tricks for advancing the limits of arthroscopic technique

Tips and tricks	Possible advantages
Preference for lateral decubitus.	It allows a better visualization of bone injury as well as of secondary lesions in the other quadrants of the glenoid and facilitates implant insertion and balanced capsuloligamentar tensioning.
Use 3 cannulas.	Facilitates switching between portals, decreases tissue infiltration.
Liberal use of anchors (at least 3 to 4).	Decrease the risk of relapse.
Use delicate suture needles.	Prevents tissue straining, decreases surgical time and allows a more accurate stitch passage.
Mastering of the technique of using accessory portals (in particular the transsubscapular or 5-hour portal and the accessory rear portal).	Allows the positioning of anchors with a better angle of attack.
In the preparation of the posterior portal, enter the stitch that is 2 cm posterior and 1 cm medial to the posterolateral angle of the acromial.	Thus, it is possible to have a better view of labrum repair, as it allows a broader view, from lateral to medial.
Remplissage	<ul style="list-style-type: none"> - Positioning of the anchor in the deep region of the bone defect. - Pass stitches at the beginning of the procedure when there is still no infiltration and tie after previous labrum repair - Be careful not to pass the suture stitched too medially, as this restricts movement.

avoid chondral lesions caused by suture threads. This seems to be a valid alternative especially in panlabral lesions in which many implants and upper labrum lesions are used to avoid the abrasion of the node against the humerus head during abduction and lateral rotation.⁴⁷

After adequate labrum mobilization and opening of the bone bed, the anchors should be inserted into the articular face of the glenoid.⁴⁸ Its medial positioning, towards the glenoid neck, constitutes a technical error that predisposes the recurrence of instability. When the surgeon deems it necessary, the 2 lower anchors in the glenoid can be inserted through a percutaneous trans-subscapular portal (5-hour portal), because a lower position is achieved in the glenoid this way, with an orthogonal angle of insertion, thus improving the quality of implant fixation in the bone.^{49,50} In addition, in cases in which the lesion extends to the lower

or to the posteroinferior region, the positioning of an even lower anchor facilitates labrum-ligament plication at the level of the axillary recess.

Labral repair and capsular plicature

The suture points should always be positioned distally to the implants and ~ 0.5 to 1.0 cm lateral to the labral edge, so that we can perform a capsular tension and plication with superior traction, thus reducing the anteroinferior capsular volume. In cases with a multidirectional component, there is a large capsular volume in the axillary recess and in the posteroinferior region. This volume should be reduced by capsular plication. In these cases, even if there is no labral lesion, the plication with anchors presents better biomechanical and clinical results.^{51,52}

Remplissage

Remplissage is a procedure consisting of capsulomyodesis, using the tendon and infraspinous muscle to fill the HSL.^{28,29,53} It reduces the anterior translation of the humerus head dynamically by prevent engaging. It is indicated for the treatment of off-track injuries, with a potential restriction of lateral rotation with the shoulder in abduction.⁵⁴

In the general population, repair of the anterior labrum associated with remplissage promotes clinical results similar to Latarjet surgery, but with less chance of complications. However, when assessing collision and contact athletes more objectively or patients undergoing revision surgery who have intermediate and large GBLE, Latarjet surgery seems to offer better results.^{26,55}

Remplissage can be performed with one or two anchors depending on the size of the bone failure. The anchors should be inserted early in the surgery and positioned preferably in the deeper region of the bone defect to improve tissue contact with bone and to increase the chance of healing.^{29,55} Also, at the beginning of the procedure, when there is no joint swelling and we have better vision, the suture points are placed through the capsule and infraspinous. It is important to keep in mind that if the suture points become medial, it is possible to restrict the lateral rotation movement of the shoulder in abduction excessively, causing pain and functional loss.^{56,57}

Final considerations

Arthroscopy is an important weapon in the treatment of anterior shoulder instability. The success of the procedure depends on a good indication, on the selection of patients, and on the appropriate surgical technique. We emphasize the importance of differentiating GBLE and fractures of the glenoid edge, because the prognosis of treatment differs between these forms of glenoid bone failure.

Until recently, the choice of surgical method was basically based on the degree of bone involvement, and bone block was indicated for bone failures in the glenoid above between 20 and 25% (critical bone loss). With the evolution of

knowledge, the biomechanics of bipolar lesions and the concept of glenoid track, the cut-off point of critical injury, has been altered with a downward trend (15%). In addition to bone failures or losses, other variables were added and made the decision more complex, but a little more objective.

The careful evaluation of the existence or not of bone lesions, as well as their type and magnitude is paramount, but we should also make use of the current evidence and include in our decision-making analysis the association of other risk factors for recurrence, as well as the individual characteristics of each patient. Following these principles, it is possible to expand the limits of arthroscopic treatment and achieve better results.

Conflict of Interests

The authors have no conflict of interests to declare.

Dr. Simmer Filho reports personal fees from Arthrex, outside the submitted work.

References

- Locher J, Wilken F, Beitzel K, et al. Hill-Sachs Off-track Lesions as Risk Factor for Recurrence of Instability After Arthroscopic Bankart Repair. *Arthroscopy* 2016;32(10):1993–1999
- Pogorzelski J, Fritz EM, Horan MP, Katthagen JC, Provencher MT, Millett PJ. Failure following arthroscopic Bankart repair for traumatic anteroinferior instability of the shoulder: is a glenoid labral articular disruption (GLAD) lesion a risk factor for recurrent instability? *J Shoulder Elbow Surg* 2018;27(08):e235–e242
- Leroux TS, Saltzman BM, Meyer M, et al. The Influence of Evidence-Based Surgical Indications and Techniques on Failure Rates After Arthroscopic Shoulder Stabilization in the Contact or Collision Athlete With Anterior Shoulder Instability. *Am J Sports Med* 2017;45(05):1218–1225
- Streubel PN, Krych AJ, Simone JP, et al. Anterior glenohumeral instability: a pathology-based surgical treatment strategy. *J Am Acad Orthop Surg* 2014;22(05):283–294
- Bankart AS. Recurrent or habitual dislocation of the shoulder-joint. *BMJ* 1923;2(3285):1132–1133
- Greis PE, Scuderi MG, Mohr A, Bachus KN, Burks RT. Glenohumeral articular contact areas and pressures following labral and osseous injury to the anteroinferior quadrant of the glenoid. *J Shoulder Elbow Surg* 2002;11(05):442–451
- Stefko JM, Tibone JE, Cawley PW, ElAttrache NE, McMahon PJ. Strain of the anterior band of the inferior glenohumeral ligament during capsule failure. *J Shoulder Elbow Surg* 1997;6(05):473–479
- Neviaser TJ. The GLAD lesion: another cause of anterior shoulder pain. *Arthroscopy* 1993;9(01):22–23
- Ozbaydar M, Elhassan B, Diller D, Massimini D, Higgins LD, Warner JJ. Results of arthroscopic capsulolabral repair: Bankart lesion versus anterior labroligamentous periosteal sleeve avulsion lesion. *Arthroscopy* 2008;24(11):1277–1283
- Yiannakopoulos CK, Mataragas E, Antonogiannakis E. A comparison of the spectrum of intra-articular lesions in acute and chronic anterior shoulder instability. *Arthroscopy* 2007;23(09):985–990
- Ilahi OA, Labbe MR, Cosculluela P. Variants of the anterosuperior glenoid labrum and associated pathology. *Arthroscopy* 2002;18(08):882–886
- Williams MM, Snyder SJ, Buford D Jr. The Buford complex—the “cord-like” middle glenohumeral ligament and absent anterosuperior labrum complex: a normal anatomic capsulolabral variant. *Arthroscopy* 1994;10(03):241–247
- Schmidem U, Watson A, Perriman D, Liodakis E, Page R. Arthroscopic repair of HAGL lesions yields good clinical results, but may not allow return to former level of sport. *Knee Surg Sports Traumatol Arthrosc* 2019;27(10):3246–3253
- Bhatia DN, DasGupta B. Surgical treatment of significant glenoid bone defects and associated humeral avulsions of glenohumeral ligament (HAGL) lesions in anterior shoulder instability. *Knee Surg Sports Traumatol Arthrosc* 2013;21(07):1603–1609
- Sugaya H, Moriishi J, Dohi M, Kon Y, Tsuchiya A. Glenoid rim morphology in recurrent anterior glenohumeral instability. *J Bone Joint Surg Am* 2003;85(05):878–884
- Sugaya H, Moriishi J, Kanisawa I, Tsuchiya A. Arthroscopic osseous Bankart repair for chronic recurrent traumatic anterior glenohumeral instability. Surgical technique. *J Bone Joint Surg Am* 2006;88(Suppl 1 Pt 2):159–169
- Jiang CY, Zhu YM, Liu X, Li FL, Lu Y, Wu G. Do reduction and healing of the bony fragment really matter in arthroscopic bony Bankart reconstruction?: a prospective study with clinical and computed tomography evaluations. *Am J Sports Med* 2013;41(11):2617–2623
- Kitayama S, Sugaya H, Takahashi N, et al. Clinical Outcome and Glenoid Morphology After Arthroscopic Repair of Chronic Osseous Bankart Lesions: A Five to Eight-Year Follow-up Study. *J Bone Joint Surg Am* 2015;97(22):1833–1843
- Yamamoto N, Muraki T, Sperling JW, et al. Stabilizing mechanism in bone-grafting of a large glenoid defect. *J Bone Joint Surg Am* 2010;92(11):2059–2066
- Burkhart SS, Debeer JF, Tehrany AM, Parten PM. Quantifying glenoid bone loss arthroscopically in shoulder instability. *Arthroscopy* 2002;18(05):488–491
- Bigliani LU, Newton PM, Steinmann SP, Connor PM, McIlveen SJ. Glenoid rim lesions associated with recurrent anterior dislocation of the shoulder. *Am J Sports Med* 1998;26(01):41–45
- Shaha JS, Cook JB, Song DJ, et al. Redefining “Critical” Bone Loss in Shoulder Instability: Functional Outcomes Worsen With “Subcritical” Bone Loss. *Am J Sports Med* 2015;43(07):1719–1725
- Shin SJ, Kim RG, Jeon YS, Kwon TH. Critical Value of Anterior Glenoid Bone Loss That Leads to Recurrent Glenohumeral Instability After Arthroscopic Bankart Repair. *Am J Sports Med* 2017;45(09):1975–1981
- Willemot LB, Elhassan BT, Verborgt O. Bony Reconstruction of the Anterior Glenoid Rim. *J Am Acad Orthop Surg* 2018;26(10):e207–e218
- Gowd AK, Liu JN, Cabarcas BC, et al. Management of Recurrent Anterior Shoulder Instability With Bipolar Bone Loss: A Systematic Review to Assess Critical Bone Loss Amounts. *Am J Sports Med* 2019;47(10):2484–2493
- Di Giacomo G, Pugliese M, Lie DTT, et al. How to handle minor and major bone loss in the shoulder? Current concepts. *J ISAKOS* 2020; 5(03):117–122
- Provencher MT, Frank RM, Leclere LE, et al. The Hill-Sachs lesion: diagnosis, classification, and management. *J Am Acad Orthop Surg* 2012;20(04):242–252
- Purchase RJ, Wolf EM, Hobgood ER, Pollock ME, Smalley CC. Hill-sachs “remplissage”: an arthroscopic solution for the engaging hill-sachs lesion. *Arthroscopy* 2008;24(06):723–726
- Wolf EM, Arianjam A. Hill-Sachs remplissage, an arthroscopic solution for the engaging Hill-Sachs lesion: 2- to 10-year follow-up and incidence of recurrence. *J Shoulder Elbow Surg* 2014;23(06):814–820
- Di Giacomo G, Itoi E, Burkhart SS. Evolving concept of bipolar bone loss and the Hill-Sachs lesion: from “engaging/non-engaging” lesion to “on-track/off-track” lesion. *Arthroscopy* 2014;30(01):90–98
- Porcellini G, Paladini P, Campi F, Paganelli M. Shoulder instability and related rotator cuff tears: arthroscopic findings and treatment in patients aged 40 to 60 years. *Arthroscopy* 2006;22(03):270–276
- Nakagawa S, Ozaki R, Take Y, Mae T, Hayashida K. Bone fragment union and remodeling after arthroscopic bony bankart repair for

- traumatic anterior shoulder instability with a glenoid defect: influence on postoperative recurrence of instability. *Am J Sports Med* 2015;43(06):1438-1447
- 33 Di Giacomo G, de Gasperis N, Scarso P. Bipolar bone defect in the shoulder anterior dislocation. *Knee Surg Sports Traumatol Arthrosc* 2016;24(02):479-488
 - 34 Omori Y, Yamamoto N, Koishi H, et al. Measurement of the Glenoid Track In Vivo as Investigated by 3-Dimensional Motion Analysis Using Open MRI. *Am J Sports Med* 2014;42(06):1290-1295
 - 35 Yamamoto N, Itoi E, Abe H, et al. Contact between the glenoid and the humeral head in abduction, external rotation, and horizontal extension: a new concept of glenoid track. *J Shoulder Elbow Surg* 2007;16(05):649-656
 - 36 Hartzler RU, Bui CNH, Jeong WK, et al. Remplissage of an Off-track Hill-Sachs Lesion Is Necessary to Restore Biomechanical Glenohumeral Joint Stability in a Bipolar Bone Loss Model. *Arthroscopy* 2016;32(12):2466-2476
 - 37 Song DJ, Cook JB, Krul KP, et al. High frequency of posterior and combined shoulder instability in young active patients. *J Shoulder Elbow Surg* 2015;24(02):186-190
 - 38 Balg F, Boileau P. The instability severity index score. A simple pre-operative score to select patients for arthroscopic or open shoulder stabilisation. *J Bone Joint Surg Br* 2007;89(11):1470-1477
 - 39 Liu JN, Gowd AK, Garcia GH, Cvetanovich GL, Cabarcas BC, Verma NN. Recurrence Rate of Instability After Remplissage for Treatment of Traumatic Anterior Shoulder Instability: A Systematic Review in Treatment of Subcritical Glenoid Bone Loss. *Arthroscopy* 2018;34(10):2894-2907.e2
 - 40 Miyazaki AN, Fregoneze M, Santos PD, et al. Avaliação dos resultados do tratamento cirúrgico artroscópico da luxação traumática anterior de ombro: Primeiro episódio. *Rev Bras Ortop* 2012;47(02):222-227
 - 41 Seroyer ST, Nho SJ, Provencher MT, Romeo AA. Four-quadrant approach to capsulolabral repair: an arthroscopic road map to the glenoid. *Arthroscopy* 2010;26(04):555-562 Erratum in: *Arthroscopy*. 2010;26(6):866
 - 42 Lo IK, Lind CC, Burkhart SS. Glenohumeral arthroscopy portals established using an outside-in technique: neurovascular anatomy at risk. *Arthroscopy* 2004;20(06):596-602
 - 43 Ciccotti MG, Kuri JA 2nd, Leland JM, Schwartz M, Becker C. A cadaveric analysis of the arthroscopic fixation of anterior and posterior SLAP lesions through a novel lateral transmuscular portal. *Arthroscopy* 2010;26(01):12-18
 - 44 Simmer Filho J, Pombo EH, de Almeida BPS. A segurança do Portal 5 Horas no tratamento das lesões labiais ântero-inferiores. *CBCOC, Búzios-RJ*; 2008
 - 45 Boileau P, Villalba M, Héry JY, Balg F, Ahrens P, Neyton L. Risk factors for recurrence of shoulder instability after arthroscopic Bankart repair. *J Bone Joint Surg Am* 2006;88(08):1755-1763
 - 46 Nho SJ, Provencher MT, Seroyer ST, Romeo AA. Bioabsorbable anchors in glenohumeral shoulder surgery. *Arthroscopy* 2009;25(07):788-793
 - 47 Knapik DM, Kolaczko JG, Gillespie RJ, Salata MJ, Voos JE. Complications and Return to Activity After Arthroscopic Repair of Isolated Type II SLAP Lesions: A Systematic Review Comparing Knotted Versus Knotless Suture Anchors. *Orthop J Sports Med* 2020;8(04):2325967120911361
 - 48 Miyazaki AN, Fregoneze M, Santos PD, et al. Avaliação Dos Resultados Do Tratamento Cirúrgico Artroscópico Da Instabilidade Anterior Traumática Do Ombro Com Sutura Da Lesão Na Margem Cruentizada Da Cavidade Glenoidal. *Rev Bras Ortop* 2012;47(03):318-324
 - 49 Ilahi OA, Al-Fahl T, Bahrani H, Luo ZP. Glenoid suture anchor fixation strength: Effect of insertion angle. *Arthroscopy* 2004;20(06):609-613
 - 50 Dwyer T, Petrera M, White LM, et al. Trans-subscapularis portal versus low-anterior portal for low anchor placement on the inferior glenoid fossa: a cadaveric shoulder study with computed tomographic analysis. *Arthroscopy* 2015;31(02):209-214
 - 51 Provencher MT, Verma N, Obopilwe E, et al. A biomechanical analysis of capsular plication versus anchor repair of the shoulder: can the labrum be used as a suture anchor? *Arthroscopy* 2008;24(02):210-216
 - 52 Bradley JP, McClincy MP, Arner JW, Tejwani SG. Arthroscopic capsulolabral reconstruction for posterior instability of the shoulder: a prospective study of 200 shoulders. *Am J Sports Med* 2013;41(09):2005-2014
 - 53 Lädermann A, Arrigoni P, Barth J, et al. Is arthroscopic remplissage a tenodesis or capsulomyodesis? An anatomic study. *Knee Surg Sports Traumatol Arthrosc* 2016;24(02):573-577
 - 54 França F, Godinho A, Carneiro Leal D, et al. Resultados clínicos e de imagem da abordagem da lesão de Hill-Sachs pela técnica de remplissage na instabilidade anterior do ombro. *Rev Bras Ortop* 2019;54(01):13-19
 - 55 Yang JS, Mehran N, Mazzocca AD, Pearl ML, Chen VW, Arciero RA. Remplissage Versus Modified Latarjet for Off-Track Hill-Sachs Lesions With Subcritical Glenoid Bone Loss. *Am J Sports Med* 2018;46(08):1885-1891
 - 56 Elkinson I, Giles JW, Boons HW, et al. The shoulder remplissage procedure for Hill-Sachs defects: does technique matter? *J Shoulder Elbow Surg* 2013;22(06):835-841
 - 57 Elkinson I, Giles JW, Faber KJ, et al. The effect of the remplissage procedure on shoulder stability and range of motion: an in vitro biomechanical assessment. *J Bone Joint Surg Am* 2012;94(11):1003-1012