



Digital Glomus Tumor: Bibliographic Review of the Studies Published over the Past 10 Years

Tumor glómico digital: revisión bibliográfica de estudios publicados en los últimos 10 años

Victoria Hernández¹ Tania Lena² Eliana Camacho¹ Matías Craviotto²

¹Plastic, Reconstructive and Esthetic Surgery Resident, Hospital de Clínicas Dr. Manuel Quintela, Plastic Surgery Department, Montevideo, Uruguay

²Plastic surgeon, Hospital Central de las Fuerzas Armadas, Montevideo Uruguay

Address for correspondence Dra. Victoria Hernández Sosa, Residente de Cirugía Plástica, Reparadora y Estética, Hospital de Clínicas Dr. Manuel Quintela, Montevideo 11600, Uruguay (e-mail: victoria.hernandezsosa@gmail.com).

Rev Iberam Cir Mano 2021;49:46–55.

Abstract

Glomus tumors are a mostly benign neoplasm that constitutes less than 4% of upper-limb soft-tissue tumors. Its unspecific clinical presentation, added to its low frequency, leads to a late diagnosis.

The objective of the present study is to update the clinical-paraclinical approach and the surgical technique used in the treatment.

We carried out a literature review from 2014 to 2019 on digital glomus tumor in the hand in adult patients using the PubMed search engine.

In most of the publications analyzed, the diagnosis was clinical, with a delay of 1 to 10 years. Plain radiography is the most requested study; of the 16 articles reporting its indication, only half evidenced compatible changes. Magnetic resonance imaging (MRI) was requested in 15 articles, presenting normal results in 3 of them. The treatment of choice was surgical excision using a transungual approach. Only 4 articles report recurrence after excision.

Although there is diversity in the approach to these tumors, we conclude that the diagnosis is clinical, and the treatment surgical, and there is no consensus regarding the paraclinical indication. The information available comes mainly from case reports, publications that contribute to the generation of evidence for the clinical practice in rare diseases such as this one.

Keywords

- ▶ glomus tumor
- ▶ fingers
- ▶ literature review as a topic

Resumen

El tumor glómico es una neoplasia en su mayoría benigna, que constituye menos del 4% de los tumores de tejidos blandos del miembro superior. Su presentación clínica inespecífica, sumada a su baja frecuencia, lleva a un diagnóstico tardío.

El objetivo del presente estudio es realizar una actualización sobre el abordaje clínico-paraclínico y la técnica quirúrgica utilizada en el tratamiento.

received
May 15, 2020
accepted
February 12, 2021

DOI <https://doi.org/10.1055/s-0041-1730392>.
ISSN 1698-8396.

© 2021. SECMA Foundation. All rights reserved.
This is an open access article published by Thieme under the terms of the Creative Commons Attribution-NonDerivative-NonCommercial-License, permitting copying and reproduction so long as the original work is given appropriate credit. Contents may not be used for commercial purposes, or adapted, remixed, transformed or built upon. (<https://creativecommons.org/licenses/by-nc-nd/4.0/>)
Thieme Revinter Publicações Ltda., Rua do Matoso 170, Rio de Janeiro, RJ, CEP 20270-135, Brazil

Realizamos una revisión bibliográfica desde 2014 a 2019 sobre tumor glómico digital en la mano en pacientes adultos utilizando el buscador PubMed.

El diagnóstico de tumor fue mayormente clínico, con un retraso desde 1 a 10 años. La radiografía simple es el estudio más solicitado; de los 16 artículos que informan su indicación, sólo la mitad evidenciaron cambios compatibles. La resonancia magnética (RM) se solicitó en 15 artículos, y presentó resultados normales en 3 de ellos. El tratamiento de elección fue la exéresis quirúrgica utilizando un abordaje transungueal. Solamente en cuatro artículos se reporta recidiva luego de la exéresis.

Palabras Clave

- ▶ tumor glómico
- ▶ dedos
- ▶ revisión de literatura como asunto

Si bien existe diversidad en el abordaje de estos tumores, concluimos que el diagnóstico es clínico y el tratamiento, quirúrgico, no existiendo consenso en cuanto a la indicación paraclínica. La información proviene principalmente de reportes de casos, publicaciones que contribuyen a generar evidencia para la práctica clínica en patologías poco frecuentes como esta.

Introduction

Glomus tumor is a cell proliferation originating from the glomus body, a contractile neuromyoarterial receptor located at the dermoepidermal junction that is responsible for regulating peripheral blood flow and temperature.¹ It was described by Wood² as a “painful subcutaneous tubercle” in 1812, and was renamed vascular hamartoma or neuromyoarterial hyperplasia in 1924, when Barre and Masson described its histology. Today, the term used in the literature is glomus tumor.

They represent 1% to 4% of upper-limb soft-tissue tumors, and are largely benign. They are more frequent among women aged between 40 and 50 years, in a 4:1 ratio when they are digital, and in a 3:1 ratio when they are extradigital.¹ In 75% of the cases, they tend to be located in the subungual area.^{3,4}

Clinically, they can manifest as a small, round tumor, rarely larger than 1 cm, presenting the classic triad of intense spontaneous pain, exquisite pain on palpation, and hypersensitivity to cold. They are characterized by presenting a positive result of the Love, Hildreth and pain tests when exposed to cold. In cases of subungual presentation, the tumor can be visible through the nail plate and even deform it.⁴ (▶ **Figure 1**).

However, the presentation without an evident tumor is frequent, which, added to its low frequency and the presence of nonspecific symptoms, contributes to the late diagnosis, with publications reporting more than 10 years of delay from the onset of symptoms to the diagnosis.⁵

The indication of the different imaging studies is controversial, and the importance of the clinical practice for the diagnosis and the indication of surgical treatment is accepted in the literature.^{1,6,7}

Given the variability of criteria regarding the approach to glomus tumors, the purpose of the present work is to describe the clinical presentation, the imaging studies requested, and the treatment chosen in international publications over the last 10 years.

Materials and Methods

We performed a literature review on glomus tumor on the fingers of the hand in adults. Using the Pubmed search engine,

we looked for articles published between January 2009 and June 2019 with the keywords: *glomus*, *tumor* and *finger*.

The abstracts of the articles found in the first search were analyzed by the authors, who selected the publications that met the following inclusion criteria: clinical trials, case series, case reports, and literature reviews that included patients aged 18 years or older with a diagnosis of glomus tumor and digital topography in the hand.

The exclusion criteria were: extradigital topography, main subject other than glomus tumor, and publications without an identifiable scientific article format.

All the articles were analyzed by the authors, who inserted the following data in a spreadsheet: general information on the work (main author, journal name, and year), characteristics of the work, clinical presentation, paraclinical examinations requested, surgical technique, evolution

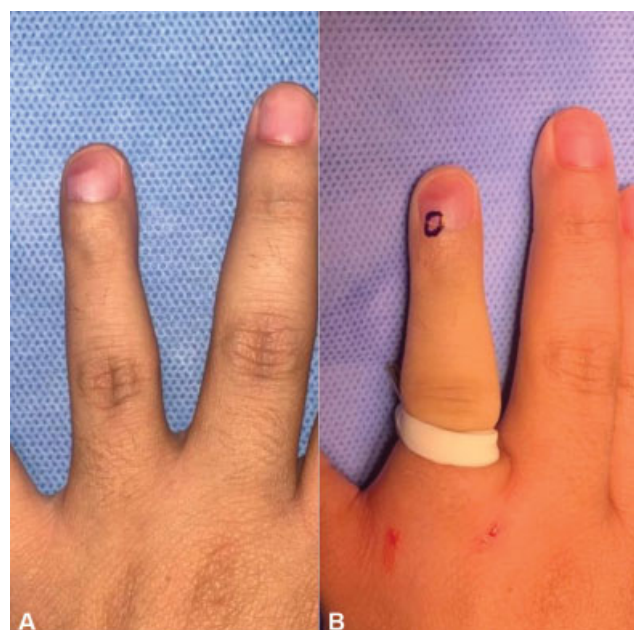


Fig. 1 (A) Clinical case showing nail deformity caused by a tumor. (B) Area of greatest pain on palpation.

(recurrence, complications), and presence of malignancy in the anatomopathological diagnosis.

The present work was carried out in accordance with the rules of the Ethics Committee of Hospital de Clínicas Dr. Manuel Quintela, Montevideo, Uruguay. The patients gave their informed consent regarding the publication of images featuring them.

Results

In the initial primary search, we retrieved a total of 59 articles. After applying the inclusion and exclusion criteria, we selected 30 publications to analyze: 22 were case reports,⁸⁻³⁰ 5 were retrospective cohorts,^{4,31-34} and 3 were case series.^{1,35,36}

The general data of the articles are presented in ►Table 1, and the clinical variables described below are summarized in ►Table 2.

Clinical diagnosis

Time until Diagnosis

Regarding the delay in diagnosis, defined as the time elapsed from the onset of symptoms to the definitive diagnosis, 22 articles mention this variable, with a maximum value of 50 years in 1 publication,⁹ and a minimum of 6 months in 2,^{12,15} although most of them (19 articles^{10,12,14-16,19-21,23-26,28-30,33,36,40}) refer to periods from 1 to 10 years.

Tumor Size

Regarding the clinical presentation as a tumor, 19 articles^{1,8-10,13-15,18,19,21,23,24,28,30,32-35,40} describe its size with a variability from 1.8 mm to 26 mm, with a predominance of 10 mm or smaller, reported in 17 articles.^{1,9,10,13-15,18,19,21,23,28,30,32-35,37}

Nail deformity

The initial clinical presentation with nail deformation is found in 15 articles,^{1,9,11,15,19,20,24-27,30,31,34-36} is specified as absent in 10, while 5 articles don't mention it.^{12,23,29,32,33}

Clinical Triad

The classic clinical triad was reported with all its components in most cases (16 articles): the most frequent symptom was spontaneous pain, found in 24 articles,^{1,8-10,12-16,18-23,25,26,28,29,32,35,36,40} while only El Jouari et al.²⁴ and Kallis et al.²⁷ specified the absence of this symptom in their case reports.

Regarding the exacerbation of pain on palpation or minimal contact, 21 articles^{1,8-12,14-16,18-21,25-29,32,36,37} refer to it as present at the time of diagnosis, and only El Jouari et al.²⁴ refer to the absence of this symptom.²⁴

Hypersensitivity to cold is present in most cases (17 articles^{1,8-10,12,14-16,19-21,23,25,26,32,36,40}); in 2 publications,^{18,24} it is reported as absent, while its presence or absence is not mentioned in the remaining articles.

The diagnosis of asymptomatic glomus tumor was reported by El Jouari et al.²⁴ in a male patient whose only pathology was a tumor with a 3-year progressive growth that produced nail deformity.

Love Test, Hildreth Test and Cold Immersion Test

Regarding the clinical tests for diagnosis, 20 articles report a positive Love test in 100% of the patients, 9 articles^{1,8-10,12,14-16,19-21,23,25,26,32,36,40} do not specify its performance, and only Jouari et al.²⁴ report negative results.

Regarding the Hildreth test, only 11 articles mention its performance, 9 of which report positivity in 100% of the cases.^{18-20,22,23,33,34,36,40}

The cold immersion test is reported as positive in 20 articles,^{1,8-12,14-16,19-21,23,25,26,28-30,32,36} and negative in 2.^{18,24}

Epidemiology

Regarding the distribution by gender, 65% of the cases occurred in female patients. In 17 articles,^{8-13,15,16,18-23,25-27} the case reported involved female patients, while 5^{14,24,28-30} publications only reported cases involving male patients. The average age of the patients was 47 years, ranging from 23 to 78 years.

Of the 30 articles included in the present review, 8 reported cases with topography on the index finger, 5, on the thumb, 5, on the ring finger, 5, on the little finger, and 3 articles^{14,26,28} referred to the third finger. The rest of the works did not specify the exact topography.

In 70% of the cases, the tumors were at the subungual level, while 20% were cases of volar glomus tumors. The remaining 10% of the studies reported cases of tumors at the level of the first, second or third phalange.

Image Studies

Plain radiography is the most requested study: 18 articles^{1,8,10,12,15,16,18,20-22,24,26,29,32,35,36,40} report its indication in the preoperative period; and, in 8^{1,8,15,22,26,32,35,37} of them, compatible radiographic changes are evident. The radiographic reports vary, and, in most cases, they are of bone erosion and dorsal deformity in the distal phalanx due to extrinsic compression, and in fewer cases, of soft tissue edema and scalloping with sclerotic edges.

Le Corroller et al.²² report a case of intraosseous glomus tumor in the middle phalanx, with particular radiographic findings such as a radiolucent image in the medullary and proximal epiphysis of the middle phalanx, with erosion of the endosteum of the adjacent cortical bone. The result of the X-ray was normal in the remaining eight articles.^{10,12,16,20,24,28,29,36}

Magnetic resonance imaging was performed in at least 1 of the patients in 15 articles.^{1,12,16,18-20,22,24-26,28-30,35,36} In general, the finding of a soft-tissue image hypointense in T1 and hyperintense in T2 was described,^{24-26,28,29} also presenting enhancement after contrast injection.^{24,25,28} Gandhi et al.,³⁶ in their series of 12 cases, included 1 patient who underwent MRI after a recurrence, using a 1.5-Tesla scanner with fine sections, without obtaining an image of the tumor. In 3 publications,^{16,20,30} the result was normal. Mitchell et al.¹⁸ report a case in which the MRI presented findings compatible with a tendon giant cell tumor, but, after excision, they confirmed it was a glomus tumor.

Regarding ultrasound, its use is mentioned in 6 articles.^{1,11,14,19,23,31} In the series of 33 cases with digital

Table 1 General characteristics of the articles included in the review

Authors	Journal	Year	Title	Article Type
Chou et al. ¹	<i>Annals of Plastic Surgery</i>	2016	Glomus tumor: twenty-year experience and literature review	CS
Senhaji et al. ⁸	<i>Journal of Medical Case Reports</i>	2018	Rare tumor in unusual location - glomus tumor of the finger pulp (clinical and dermoscopic features): a case report	CR
Duarte et al. ⁹	<i>Dermatology Online Journal</i>	2016	Giant subungual glomus tumor: clinical, dermoscopy, imaging and surgery details	CR
Komforti and Cummings ²⁰	<i>American Journal of Dermatopathology</i>	2015	An extraordinary association of glomus tumor and Pacinian hyperplasia in the hand of a female patient	CR
Kabukcuoğlu et al. ²³	<i>Türk Patoloji Dergisi</i>	2015	Symplastic glomus tumor	CR
El Jouari et al. ²⁴	<i>Journal of Medical Case Reports</i>	2018	A painless glomus tumor: a case report	CR
Vieira et al. ²⁵	<i>Journal of Clinical Rheumatology</i>	2016	Subungual glomus tumor	CR
Santoshi JA ⁴⁰	<i>Journal of Family Medicine and Primary Care</i>	2017	Glomus tumor of the fingertips: a frequently missed diagnosis	RC
Lee et al. ³²	<i>Archives of Plastic Surgery</i>	2015	Glomus tumor of the hand	RC
Lu et al. ²⁶	<i>BMC Cancer</i>	2018	Rupture of a subungual glomus tumor of the finger	CR
Kallis et al. ²⁷	<i>Skin Appendage Disorders</i>	2015	Onychomatricoma with concomitant subungual glomus tumor	CR
Rosner et al. ²⁸	<i>Plastic and Reconstructive Surgery - Global Open</i>	2017	Unusual volar pulp location of glomus tumor	CR
Huang et al. ⁴	<i>Dermatologic Surgery</i>	2015	Outcome of microscopic excision of a subungual glomus tumor: a 12-year evaluation	CR
Bousbaa and Amhaji ²⁹	<i>Pan African Medical Journal</i>	2017	Case study of glomus tumor of the index finger	CR
Stošić et al. ¹⁰	<i>Srpski Arhiv za Celokupno Lekarstvo</i>	2016	Glomus tumor – a case report	CR
Bordianu and Zamfirescu ¹⁹	<i>Journal of Medicine and Life</i>	2019	The hidden cause of chronic finger pain: glomus tumor – a case report	CR
Singh et al. ¹²	<i>Journal of Orthopaedic Case Reports</i>	2016	Glomus tumor - a rarity; M.R.I - a big help in early diagnosis	CR
Domínguez-Cruz et al. ¹³	<i>Actas Dermo-Sifiliográficas</i>	2018	Extirpación eco-guiada mínimamente invasiva del tumor glómico digital	CR
Macharia and Nthumba ¹⁴	<i>Journal of Medical Case Reports</i>	2015	Glomus tumor presenting as complex regional pain syndrome of the left upper limb: a case report	CR
Falletti et al. ¹⁵	<i>Pathology Research and Practice</i>	2012	Symplastic glomus tumor: report of a challenging lesion with literature review	CR
Fernandez-Vázquez et al. ³⁵	<i>Acta Ortopédica Mexicana</i>	2011	Tumor glomus en la mano	CS and R
Thatte et al. ¹⁶	<i>Indian Dermatology Online Journal</i>	2015	“Pink glow”: A new sign for the diagnosis of glomus tumor on ultraviolet light dermoscopy	CR
Cigna et al. ³³	<i>Journal of Cutaneous Medicine and Surgery</i>	2011	Short-scar surgical approach for the treatment of glomus tumor of the digit	RC

(Continued)

Table 1 (Continued)

Authors	Journal	Year	Title	Article Type
Lin et al. ³⁴	<i>Dermatologic Surgery</i>	2010	Recurrent digital glomus tumor: analysis of 75 cases	RC
Mitchell et al. ¹⁸	<i>Journal of Hand Surgery (American Volume)</i>	2012	Glomus tumor of digital nerve: case report	CR
Gandhi et al. ³⁶	<i>Journal of Hand Surgery (American Volume)</i>	2010	The anatomic location of digital glomus tumor recurrences	CS
Chuang et al. ¹⁹	<i>Journal of the American Academy of Dermatology</i>	2012	Intraosseous subungual glomus tumor: a cautionary tale	CR
Shin et al. ²¹	<i>Journal of Korean Neurosurgical Society</i>	2010	A painful glomus tumor on the pulp of the distal phalanx	CR
Le Corroller et al. ²²	<i>Skeletal Radiology</i>	2012	Primary intraosseous glomus tumor in a middle phalanx	CR
Smalberger et al. ³⁰	<i>Dermatology online Journal</i>	2011	Painful growth on right index finger. Subungual glomus tumor	CR

Abbreviations: CR, case report; CS, case series; R, review; RC, retrospective cohort.

glomus tumor published by Chou et al.,¹ it was only performed in 2 cases, and the authors did not describe the findings. In the publications in which the result is detailed, it is generally described as a solid, hypoechoic, well-defined lesion, with regular borders, in some cases showing hypervascularization compared to Doppler ultrasound, which tells us about the vascular nature of the tumor.^{16,21,25}

Ultrasound was either not performed, or its performance was not reported, in 23 studies.^{4,8-10,12,14,15,18-20,23,24,26-30,32-34,36,40}

Treatment

Surgical Technique

Regarding the surgical approaches used, the transungual approach was used in 52% of the publications, the volar approach, in 35%, and the lateral subperiosteal, in 29%. Dominguez-Cruz et al.¹³ report one case of treatment using ultrasound-guided transungual punch.

Complications

The complication most frequently found was nail deformity,^{1,28} and, less frequently, hypoesthesia and hypertrophic scar.³³ No complications were reported in 16 articles.^{4,8-16,18-29,32-37}

Recurrence

Recurrence, was reported in 5 articles,^{1,13,19,32,34} with a frequency ranging from 0% to 100%.

Chou et al.¹ described a relapse rate of 3.03%; Lee et al.,³² of 6.6%, Lin et al.,³⁴ of 13%, and Domínguez-Cruz et al.¹³ and Chuang et al.,¹⁹ 100%. The latter¹⁹ performed the partial amputation of the distal phalanx in the presence of recurrence of an intraosseous glomus tumor.

Gandhi et al.³⁶ reported an initial recurrence in 41.6% of the patients, and a second recurrence in 25%.

In 19 articles,^{4,8-10,12,14,15,18-23,26,28,29,33,35,40} there was no recurrence after surgical excision.

Pathological Anatomy

Regarding the definitive diagnosis, in 28 articles,^{1,4,8-10,12-14,16,18-22,24-30,32-36,40} it was confirmed by pathological anatomy without describing the details of the analysis.

On microscopy, the presence of tumor proliferation made up of aggregates of monomorphic cells with round nuclei and eosinophilic cytoplasm surrounding vascular structures is characteristic of these tumors.

Kabukçuoğlu et al.²³ and Falletti et al.¹⁵ described a variant of symplastic glomus tumor, characterized by the presence of nuclear atypia in the absence of any other characteristic of malignancy.

None of the articles reported the presence of glomangiosarcoma, a malignant variant of glomus tumor.

Table 2 Description of the clinical variables extracted from the articles

Authors	N	Size (mm)	Delay in diagnosis (years)	Clinical triad			Clinical tests				Nail deformity
				Spontaneous pain	Pain on palpation	Pain when exposed to cold	Love test	Cold immersion	Hildreth test		
Chou et al. ¹ (2016)	33	44 ± 24	NR	Positive	Positive	Positive (42%)	Positive	Positive (42.4%)	NR	YES (30.3%)	
Senhaji et al. ⁸ (2018)	1	10.5	10	Positive	Positive	Positive	Positive	Positive	NR	NO	
Duarte et al. ⁹ (2016)	1	8	50	Positive	Positive	Positive	Positive	Positive	NR	YES	
Komforti and Cummings ²⁰ (2015)	1	NR	1	Positive	Positive	Positive	NR	Positive	Negative	YES	
Kabukcuoğlu et al. ²³ (2015)	1	5	1	Positive	NR	Positive	NR	Positive	NR	NR	
El Jouari et al. ²⁴ (2018)	1	26	3	Negative	Negative	Negative	Negative	Negative	Negative	YES	
Vieira et al. ²⁵ (2016)	1	NR	3	Positive	Positive	Positive	Positive	Positive	Positive	YES	
Santoshi JA. (2017)	37	3.8	3.8	Positive	Positive	Positive	NR	NR	NR	YES (48.6%)	
Lee et al. ³² (2015)	15	6	NR	Positive	Positive	Positive (6.6%)	Positive	Positive	Positive	NR	
Lu et al. ²⁶ (2018)	1	NR	5	Positive	Positive	Positive	Positive	Positive	Positive	YES	
Kallis et al. ²⁷ (2015)	1	NR	10	Negative	Positive	NR	Positive	NR	NR	YES	
Rosner et al. ²⁸ (2017)	1	8	2	Positive	Positive	NR	Positive	Positive	NR	NO	
Huang et al. ⁴ (2015)	22	NR	NR	NR	Positive	NR	Positive	NR	NR	YES (11.7%)	
Bousbaa and Amhajji ²⁹ (2017)	1	NR	2	Positive	Positive	NR	Positive	Positive	Positive	NR	
Stošić et al. ¹⁰ (2016)	1	10	3	Positive	Positive	Positive	Positive	Positive	Positive	NO	
Bordianu and Zamfirescu ¹⁹ (2019)	1	NR	8	Positive	Positive	Positive	Positive	Positive	Positive	NO	
Singh et al. ¹² (2016)	1	NR	0.5	Positive	Positive	Positive	Positive	Positive	NR	NR	
Domínguez-Cruz et al. ¹³ (2018)	1	3.1	NR	Positive	NR	NR	Positive	NR	NR	NO	
Macharia and Nthumba ¹⁴ (2015)	1	10	8	Positive	Positive	Positive	Positive	Positive	Positive	NO	
Falletti et al. ¹⁵ (2012)	1	7	0.5	Positive	Positive	Positive	Positive	Positive	Positive	YES	
Fernandez-Vázquez et al. ³⁵ (2011)	11	6	NR	Positive	NR	NR	Positive	NR	NR	YES (41.6%)	
Thatte et al. ¹⁶ (2015)	1	NR	3	Positive	Positive	Positive	Positive	Positive	NR	NO	
Cigna et al. ³³ (2011)	25	< 10	4	NR	NR	NR	NR	NR	NR	NR	
Lin et al. ³⁴ (2010)	75	2 to 8	3.9	NR	NR	NR	NR	NR	NR	YES	
Mitchell et al. ¹⁸ (2012)	1	7	NR	Positive	Positive	Negative	NR	Negative	NR	NO	
Gandhi et al. ³⁶ (2010)	12	NR	1.5	Positive	Positive	Positive	NR	Positive	NR	YES	
Chuang et al. ¹⁹ (2012)	1	3	NR	Positive	NR	NR	NR	Positive	NR	YES	
Shin et al. ²¹ (2010)	1	6	8	Positive	Positive	Positive	Positive	Positive	Positive	NO	
Le Corroller et al. ²² (2012)	1	NR	NR	Positive	NR	NR	NR	NR	NR	NO	
Smalberger et al. ³⁰ (2011)	1	1.8 to 8	1	NR	NR	NR	Positive	Positive	NR	YES	

Abbreviation: NR, Not reported.

Table 3 Description of the paraclinical, therapeutic, histological and evolutionary variables extracted from the articles

Authors	Imaging studies			Surgical approach		Evolution		Malignancy
	MRI	Ultrasound	X-ray			Relapse	Complications	
Chou et al. ¹ (2016)	Positive (15.15%)	Positive (6%)	Positive (12.2%)	Transungueal		YES (3.03%)	YES: deformation (9%)	NO
Senhaji et al. ⁸ (2018)	NP	NP	Positive	Paramedian volar		NO	NO	NO
Duarte et al. ⁹ (2016)	NP	NP	NP	Transungueal		NO	NR	NO
Komforti and Cummings ²⁰ (2015)	Negative	NP	Negative	NR		NO	NR	NO
Kabukcuoğlu et al. ²³ (2015)	NR	NR	NR	NR		NO	NR	Symphastic
El Jouari et al. ²⁴ (2018)	Positive	NR	Negative	NR		NR	NO	NO
Vieira et al. ²⁵ (2016)	Positive	Positive	NR	NR		NR	NR	NO
Santoshi JA. (2017)	NR	NR	Positive (40.5%)	Transungueal		NO	NO	NO
Lee et al. ³² (2015)	NR	NR	Positive (20%)	Transungueal (73.3%), volar (20%), lateral subperiosteal (6.6%)		YES (6.6%)	YES: deformation (20%)	NO
Lu et al. ²⁶ (2018)	Positive	NR	Positive	Lateral subperiosteal		NO	NO	NO
Kallis et al. ²⁷ (2015)	NR	NR	NR	NR		NR	NR	NO
Rosner et al. ²⁸ (2017)	Positive	NR	Negative	Volar		NO	NO	NO
Huang et al. ⁴ (2015)	NR	NR	NR	Transungueal (59%), volar (22.7%), lateral subperiosteal (18.1%)		NO	YES: deformation (9.09%)	NO
Bousbaa and Amhaji ²⁹ (2017)	Positive	NR	Negative	Volar		NO	NO	NO
Stošić et al. ¹⁰ (2016)	NP	NP	Negative	Transungueal		NO	NO	NO
Bordianu and Zamfirescu ¹⁹ (2019)	Positive	NR	NR	Lateral subperiosteal		NO	NO	NO
Singh et al. ¹² (2016)	Positive	NR	Negative	NR		NO	NO	NO
Domínguez-Cruz et al. ¹³ (2018)	NR	Positive	NR	echography-guided transungueal punch		YES (previous)	NO	NO
Macharia and Nthumba ¹⁴ (2015)	NP	NP	NP	Volar		NO	NO	NO
Falletti et al. ¹⁵ (2012)	NR	NR	Positive	Transungueal		NO	NO	Symphastic
Fernandez-Vázquez et al. ³⁵ (2011)	Positive (9%)	Positive (9%)	Positive (75%)	Transungueal		NO	NO	NO
Thatte SS. (2015)	Negative	Positive	Negative	NR		NI	NR	NO
Gigna et al. ³³ (2011)	NR	NR	NR	Transungueal		NO	YES: hypoesthesia and hypertrophic scar	NO
Lin et al. ³⁴ (2010)	NR	NR	NR	NR		YES (13%)	NR	NO
Mitchell et al. ¹⁸ (2012)	Wrong report	NP	Negative	NR		NO	NO	NO
Gandhi et al. ³⁶ (2010)	Positive (8.3%)	NP	Positive	Transungueal		YES (41.6%); second relapse (25%)	NR	NO
Chuang et al. ¹⁹ (2012)	NP	NP	NR	Partial amputation of the distal phalanx		YES	NR	NO
Shin et al. ²¹ (2010)	NP	Positive	Negative	Lateral subperiosteal		NO	NO	NO
Le Corroller et al. ²² (2012)	Positive	Positive	Positive	NR		NO	NO	NO
Smalberger et al. ³⁰ (2011)	Negative	NR	NR	NR		NR	NR	NO

Abbreviations: Negative, performed, and the result was normal; NP, not performed; NR, not reported; Positive, performed, and the result showed compatible changes.

The data extracted regarding the paraclinical, therapeutic, histology and evolution variables are shown in ► **Table 3**.

Discussion

The present review reflects the variety of clinical presentations and diagnostic algorithms, as well as the fact that most of the references come from case series.

Glomus tumors represent a pathology characterized by a late diagnosis, with multiple previous consultations mainly motivated by spontaneous and disabling pain after tactile or thermal stimuli. A classic triad of spontaneous pain, pain on minimal contact, and hypersensitivity to cold is described; combined, these symptoms increase the diagnostic precision.⁸ Some authors⁵ state that difficult-to-manage paroxysmal pain is pathognomonic for the diagnosis. Several hypotheses are suggested regarding the cause of pain in glomus tumors. The abundant mast cells in glomus tumors release substances such as heparin, 5-hydroxytryptamine, and histamine, which makes pressure or cold stimulation receptors sensitive even to a minor stimulus.^{32,38} In addition, it has been proposed as a cause the existence of numerous unmyelinated nerve fibers that penetrate glomus tumors and vasodilation of the Sucquet-Hoyer arteriovenous canals, which dilate in response to cold to avoid excessive heat loss in the fingers.²⁸ In our review, spontaneous pain was not reported only in 2 cases.^{24,27}

For the clinical diagnosis, in addition to the classical triad, three characteristic signs are described: the Love pin test, the Hildreth test and the cold immersion test.⁹ The Love pin test involves the application of targeted pressure with a clip or the head of a pin, and the area of pain defines the topography of the tumor.

The Hildreth test is performed by inducing transient ischemia using a tourniquet, and is considered positive when the patient manifests pain relief with the provocation of ischemia, and sudden severe pain when the tourniquet is released. The cold immersion test is positive when the hand is immersed in cold water and this causes severe pain in and around the injury. This is produced by stimulation of the receptors that are sensitive to cold, producing a vasodilation of the arteriovenous canals, which dilate in response to the cold to avoid excessive heat loss. Bhaskaranand and Navadgi,⁴¹ in a study with 18 patients, reported a sensitivity of 100% and a specificity of 78% in the Love test, and 100% of sensitivity and specificity in the cold immersion test, while the Hildreth test was 71.4% sensitive and 100% specific.⁴¹ Although these tests are characteristic, we found 19 publications that do not specify their complete results.^{1,4,8,9,12,13,16,18,19,22,23,27,28,30,33-36,40}

In the literature, the diagnosis is described with an average delay of seven years since the onset of symptoms, which may be due to the lack of knowledge of the clinician regarding this pathology. Its nonspecific clinical presentation can raise the diagnostic doubt with differentials such as neuroomas, foreign bodies, melanoma, pigmented nevi, hemangiomas and hyperplasia of the Pacinian corpuscle.^{20,35}

They are generally small lesions of less than 10 mm, which, at the beginning, may not be palpable due to their size and depth. In these cases, for the diagnosis, there are complementary clinical tests such as transillumination, which is only mentioned by Bousbaa and Amhaji.²⁹

In the present review, the average age at presentation was of 47 years, which coincides with previous reviews on the subject,³ in which the mean age shows a peak in the fifth decade of life for men, and in the fourth for women.

These tumors are more frequent in the distal segment of the fingers, given the higher density of the glomus bodies in that area.¹ In total, 70% of the articles report glomus tumors at the subungual level, followed in 20% of cases of exclusive presentation at the level of the fingertip, and 10% at the digital level, in the first, second or third phalanges.

It occurred more frequently at the level of the index finger (30%), followed by the thumb, ring, and little fingers, the latter with the same proportion each (19%); this differs from previous reviews, in which the thumb was the most affected and the little finger, the least affected.³

According to their clinical presentation, these tumors are classified as solitary or multiple, the former being the most frequent. In our initial search, we found publications on multiple extradigital tumors; not so on multiple digital tumors.

We found no evidence of the indication for imaging tests, although plain radiography was the most requested test in the present review. Radiography enables the assessment of the presence of bone erosion, found in most subungual tumors.³⁵ Ultrasound and MRI are reserved for doubtful cases, in which the symptoms do not present the classic triad, and cases of recurrent tumors, or of multiple or atypical locations.³⁶ On the MRI, they are described as mildly hypointense to mildly hyperintense on T1-weighted images and hyperintense on T2-weighted images. Studies^{12,40} show that the MRI is highly sensitive years after the onset of symptoms, detecting 82% to 90% of glomus tumors in the hand. However, a small tumor cannot be ruled out with a negative MRI result; therefore, when there is clinical suspicion, surgery is recommended.^{11,37}

The treatment of choice is complete surgical excision. In subungual tumors, this can be performed through a transungual approach, which requires careful extraction of the nail plate and a longitudinal incision in the bed. This approach is the most widely used method, enabling complete removal of the tumor and resulting in a lower recurrence rate.⁴ (► **Figure 2**).

In proximal subungual lesions, a lateral subperiosteal approach has been described. The main disadvantage is the lower visibility and the consequent risk of incomplete tumor excision.³²

Recurrence rates vary depending on the technique used and on the incomplete excision of the tumor. It has been observed that symptoms that appear days to weeks after the surgical excision may be due to incomplete excision, whereas, when symptoms appear 2 to 3 years after surgery, this may indicate multiple tumors.³⁷

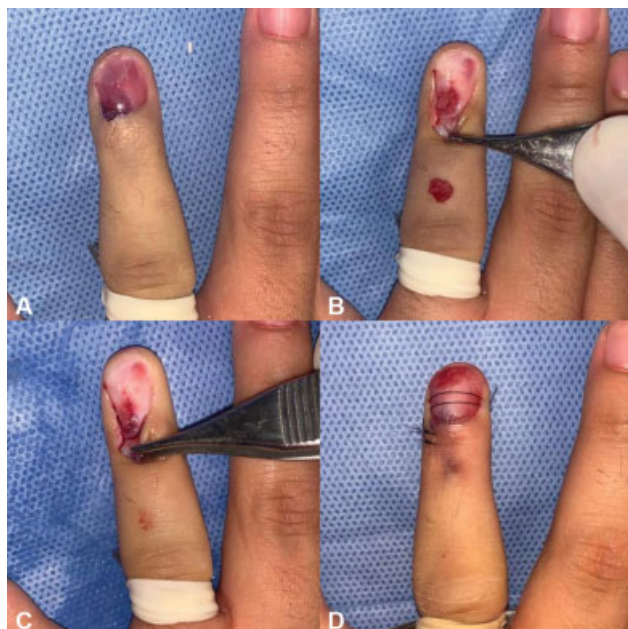


Fig. 2 Clinical case of glomus tumor. (A) The tumor is seen after resection of the nail plate. (B and C) With the dissecting forceps, the eponychium flap is indicated below which the matrix defect is closed. (D) Repositioning of the nail plate.

Kim et al.³⁹ analyzed the risk factors related to recurrence and complications in the postoperative period. The factors analyzed related to a higher risk of recurrence were tumor size, bone erosion, anatomical location, surgical approach, and the method used. Recurrence did not present a greater statistical significance in the risk groups analyzed. The complications described were nail deformities, generally minor striations, and numbness of the fingertips, with no statistically significant differences regarding the approach used. The transungual approach is thought to offer a better view of the surgical field for tumor excision, but it has the disadvantage of damaging the nail bed, thus presenting a higher incidence of postoperative nail deformity. A nail-sparing approach prevents adhesion between the matrix and the eponychium during healing of the nail bed, avoiding postoperative nail deformities.

In the present review, minor complications, such as nail deformity,^{1,28} and, less frequently, hypoesthesia and hypertrophic scar, have been found.³³

Glomus tumors are classified into three types according to their composition: glomangiomas or ganglioma are formed mainly by vessels (60%); solid glomus tumors are mainly composed of glomus cells (25%); and glomangiomyoma shows a predominance of smooth-muscle cells (15%).^{10,32} In the present review, the histological type^{15,23} is only reported in two cases.

There are limited reports of glomangiosarcoma, a malignant variant of glomus tumor described in less than 1% of the cases, more frequently at visceral level; the established guiding criteria for malignancy are size greater than 2 cm, deep location, and presence of atypical mitoses or nuclear atypia.¹¹ We did not find articles that report the presence of glomangiosarcoma, a malignant variant of glomus tumor.

Glomus tumors that show nuclear pleomorphism without any other malignant feature have been defined as symplastic glomus tumors, which behave clinically as benign, and must be differentiated from glomangiosarcoma. This atypia is recognized as a degenerative change, and is accepted as benign.^{15,23}

Since glomus tumor is a rare pathology, case reports or cohort studies carried out with methodological rigor are important, including as much detail as possible regarding the findings, once this enables the development of a database to improve diagnostic and therapeutic procedures.

Conclusions

Glomus tumors are a mostly benign neoplasm, with no reported cases of malignancy found in the present review. Although most studies report spontaneous pain and the classic clinical triad, its presentation is nonspecific. It is a rare pathology, which coincides with the fact that in the last 10 years almost all of the publications found are case reports. These factors together contribute to the late diagnosis: in the present review, 1 to 10 years elapsed since the onset of symptoms. Plain radiology was the most requested test in the present review, followed by ultrasound and MRI, and its main indication is to rule out differential diagnoses in cases of diagnostic doubt.

In rare pathologies like this, the publication of case reports and series, as well as reviews, is important in order to generate scientific evidence that contributes to decision-making at a practical level.

Conflict of interests

The authors have no conflict of interests to declare.

References

- 1 Chou T, Pan SC, Shieh SJ, Lee JW, Chiu HY, Ho CL. Glomus tumor: twenty-year experience and literature review. *Ann Plast Surg* 2016;76(March):(Suppl 1):S35–S40. Doi: 10.1097/SAP.0000000000000684
- 2 Wood W. On painful subcutaneous tubercle. *Edinb Med Surg J* 1812;8(31):283–291
- 3 Barreiro G, Bestilleiro A, del Castillo F, Martel RM, García J, Loureda R. Tumores glómicos en el miembro superior. Revisión de la literatura e informe de 14 casos. *Rev Iberoam Cirugía la Mano* 2016;44(02):069–077. Doi: 10.1016/j.ricma.2016.08.003
- 4 Huang HP, Tsai MC, Hong KT, et al. Outcome of microscopic excision of a subungual glomus tumor: a 12-year evaluation. *Dermatol Surg* 2015;41(04):487–492. Doi: 10.1097/DSS.0000000000000329
- 5 Carroll RE BA. Glomus tumors of the hand: review of the literature and report on twenty-eight cases. *J Bone Jt surgery Am* 1972Jun;54(04):691–703
- 6 Nazerani S, Motamedi MHK, Keramati MR. Diagnosis and management of glomus tumors of the hand. *Tech Hand Up Extrem Surg* 2010;14(01):8–13. Doi: 10.1097/BTH.0b013e3181c767d4
- 7 Trehan SK, Athanasian EA, DiCarlo EF, Mintz DN, Daluiski A. Characteristics of glomus tumors in the hand not diagnosed on magnetic resonance imaging. *J Hand Surg Am* 2015;40(03):542–545. Doi: 10.1016/j.jhssa.2014.12.002
- 8 Senhaji G, Gallouj S, El Jouari O, Lamouaffaq A, Rimani M, Mernissi FZ. Rare tumor in unusual location - glomus tumor of the finger

- pulp (clinical and dermoscopic features): a case report. *J Med Case Reports* 2018;12(01):196. Doi: 10.1186/s13256-018-1721-0
- 9 Duarte AF, Correia O, Barreiros H, Haneke E. Giant subungual glomus tumor: clinical, dermoscopy, imagiologic and surgery details. *Dermatol Online J* 2016;22(10):6
 - 10 Stošić M, Stojanović I, Lalić M. Glomus tumor – A case report. *Srp Arh Celok Lek* 2016;144(7-8):443–445. Doi: 10.2298/SARH1608443S
 - 11 Bordianu A, Zamfirescu D. The hidden cause of chronic finger pain: Glomus Tumor - A Case Report. *J Med Life* 2019;12(01):30–33. Doi: 10.25122/jml-2018-0060
 - 12 Singh D, Garg RSVikas Garg Y, Arora V. Glomus Tumor - A Rarity; M.R.I- A big help in early Diagnosis. *J Orthop Case Rep* 2016;6(03):38–39. Doi: 10.13107/jocr.2250-0685.494
 - 13 Domínguez-Cruz J, Ortiz-Prieto A, Martín-Carrasco P, Conejo-Mir J. Ultrasound-Guided, Minimally Invasive Resection of a Digital Glomus Tumor. *Actas Dermosifiliogr* 2018;109(03):271–273. Doi: 10.1016/j.ad.2017.07.016
 - 14 Macharia C, Nthumba PM. Glomus tumor presenting as complex regional pain syndrome of the left upper limb: a case report. *J Med Case Reports* 2015;9(01):293. Doi: 10.1186/s13256-015-0793-3
 - 15 Falletti J, Vita G, De Cecio R, et al. Symplastic glomus tumor: report of a challenging lesion with literature review. *Pathol Res Pract* 2012;208(06):372–375. Doi: 10.1016/j.prp.2012.04.001
 - 16 Thatte SS, Chikhalkar SB, Khopkar US. "Pink glow": A new sign for the diagnosis of glomus tumor on ultraviolet light dermoscopy. *Indian Dermatol Online J* 2015;6(07, Suppl 1):S21–S23. Doi: 10.4103/2229-5178.171041
 - 17 Abbassi A, Amrani A, Dendane MA, El Alami Z, El Madhi T, Gourinda H. Tumeur glomique pulpaire de l'enfant : à propos d'un cas inhabituel. *J Mal Vasc* 2012;37(04):219–221. Doi: 10.1016/j.jmv.2012.05.004
 - 18 Mitchell A, Spinner RJ, Ribeiro A, Mafra M, Mouzinho MM, Scheithauer BW. Glomus tumor of digital nerve: case report. *J Hand Surg Am* 2012;37(06):1180–1183. Doi: 10.1016/j.jhsa.2012.02.035
 - 19 Chuang GS, Branch KD, Cook J. Intraosseous subungual glomus tumor: a cautionary tale. *J Am Acad Dermatol* 2012;67(01):e58–e60. Doi: 10.1016/j.jaad.2011.01.011
 - 20 Komforti M, Cummings TJ. An extraordinary association of glomus tumor and pacinian hyperplasia in the hand of a female patient. *Am J Dermatopathol* 2015;37(09):719–720. Doi: 10.1097/DAD.0000000000000374
 - 21 Shin DK, Kim MS, Kim SW, Kim SH. A painful glomus tumor on the pulp of the distal phalanx. *J Korean Neurosurg Soc* 2010;48(02):185–187. Doi: 10.3340/jkns.2010.48.2.185
 - 22 Le Corroller T, Hargunani R, Khashoggi K, et al. Primary intraosseous glomus tumor in a middle phalanx. *Skeletal Radiol* 2012;41(02):227–230. Doi: 10.1007/s00256-011-1217-0
 - 23 Kabukçuoğlu F, Özkayalar H, Sakiz D, Kabukçuoğlu Y. Simplastik glomus tümör. *Türk Patoloji Derg* 2015;31(03):211–214. Doi: 10.5146/tjpath.2014.01247
 - 24 El Jouari O, Gallouj S, Elloudi S, Senhaji G, Rimani M, Mernissi FZ. A painless glomus tumor: a case report. *J Med Case Reports* 2018;12(01):302. Doi: 10.1186/s13256-018-1837-2
 - 25 Vieira FG, Nakamura R, Costa FM, Canella C, Marchiori E. Subungual glomus tumor. *J Clin Rheumatol* 2016;22(06):331. Doi: 10.1097/RHU.0000000000000418
 - 26 Lu H, Chen LF, Chen Q. Rupture of a subungual glomus tumor of the finger. *BMC Cancer* 2018;18(01):505. Doi: 10.1186/s12885-018-4377-7
 - 27 Kallis P, Miteva M, Patel T, Zaiac M, Tosti A. Onychomatricoma with Concomitant Subungual Glomus Tumor. *Skin Appendage Disord* 2015;1(01):14–17. Doi: 10.1159/000371582
 - 28 Rosner IA, Argenta AE, Washington KM. Unusual Volar Pulp Location of Glomus Tumor. *Plast Reconstr Surg Glob Open* 2017;5(01):e1215. Doi: 10.1097/gox.0000000000001215
 - 29 Bousbaa H, Amhaji L. A propos d'une observation de tumeur glomique de l'index. *Pan Afr Med J* 2017;26:155. Doi: 10.11604/pamj.2017.26.155.11899
 - 30 Smalberger GJ, Suszko JWKA, Khachemoune A. Painful growth on right index finger. Subungual glomus tumor. *Dermatol Online J* 2011;17(09):12
 - 31 Kale SS, Rao VK, Bentz ML. Glomus tumor of the index finger. *J Craniofac Surg* 2006;17(04):801–804. Doi: 10.1097/00001665-200607000-00037
 - 32 Lee W, Kwon SB, Cho SH, Eo SR, Kwon C. Glomus tumor of the hand. *Arch Plast Surg* 2015;42(03):295–301. Doi: 10.5999/aps.2015.42.3.295
 - 33 Cigna E, Palumbo F, De Santo L, Edoardo Zampieri A, Soda G. Short-scar surgical approach for the treatment of glomus tumor of the digit. *J Cutan Med Surg* 2011;15(01):21–28. Doi: 10.2310/7750.2010.09083
 - 34 Lin YC, Hsiao PF, Wu YH, Sun FJ, Scher RK. Recurrent digital glomus tumor: analysis of 75 cases. *Dermatol Surg* 2010;36(09):1396–1400. Doi: 10.1111/j.1524-4725.2010.01647.x
 - 35 Fernández-Vázquez JM, Camacho-Galindo J, Ayala-Gamboa U, Ochoa-Olvera L. Tumor glomus en la mano. *Acta Ortop Mex* 2011;25(02):103–107
 - 36 Gandhi J, Yang SS, Hurd J. The anatomic location of digital glomus tumor recurrences. *J Hand Surg Am* 2010;35(06):986–989. Doi: 10.1016/j.jhsa.2010.02.019
 - 37 Faizi N, Kazmi S. Universal health coverage - There is more to it than meets the eye. *J Family Med Prim Care* 2017;6(01):169–170. Doi: 10.4103/jfmpc.jfmpc
 - 38 Lee CH, Byeon JH, Rhie JW, et al. Clinical analysis of twenty cases of glomus tumor in the digits. *Korean Soc Plast Reconstr Surg* 1995;22:169–178
 - 39 Kim YJ, Kim DH, Park JS, Baek JH, Kim KJ, Lee JH. Factors affecting surgical outcomes of digital glomus tumour: a multicentre study. *J Hand Surg Eur Vol* 2018;43(06):652–658. Doi: 10.1177/1753193418774176
 - 40 Santoshi JA, Vivek Kumar Kori UK. Glomus tumor of the fingertips: A frequently missed diagnosis. *J Fam Med Prim Care* 2017;6(02):169–170
 - 41 Bhaskaranand K, Navadgi BC. Glomus tumour of the hand. *J Hand Surg [Br]* 2002;27:229–231