



Cerebral Venous Sinus Stenting for the Treatment of Idiopathic Intracranial Hypertension in a Child

Angioplastia de Seio Venoso Cerebral para Tratamento de Hipertensão Intracraniana Idiopática em Criança

Leonardo Henrique da Silva Rodrigues¹ Guilherme Brasileiro de Aguiar¹
Hélio Henrique Jorge Torres¹ Paulo Adolfo Wessel Xander¹ Fernanda Boldrini Assunção¹
Thiago Luiz Pereira Donoso Scopetta¹ Mauricio Jory¹ José Carlos Esteves Veiga¹
Mario Luiz Marques Conti¹

¹ Division of Neurosurgery, Department of Surgery, Faculdade de Ciências Médicas da Santa Casa de São Paulo, São Paulo, SP, Brazil

Arq Bras Neurocir 2023;42(2):e189–e194.

Address for correspondence Guilherme Brasileiro de Aguiar, PhD, Division of Neurosurgery, Department of Surgery, Faculdade de Ciências Médicas da Santa Casa de São Paulo, Rua Dr. Cesário Motta Júnior 61, Vila Buarque, São Paulo, SP, 01221-020, Brasil (e-mail: guilhermebraguiar@yahoo.com.br).

Abstract

Idiopathic intracranial hypertension (IIH) is a disease characterized by an increase in the opening pressure of the cerebrospinal fluid (CSF) associated with symptoms of elevated intracranial pressure (ICP). The condition is more prevalent in women and typically managed clinically. Surgical treatment is reserved for select refractory cases. The well-established surgical procedures for the management of IIH are CSF shunting and fenestration of the optic nerve sheath. These procedures, however, are associated with high rates of complication and recurrence.

More recently, venous sinus angioplasty with stents has been employed in cases with documented narrowing of the sigmoid-transverse sinuses. This technique is associated with a significant reduction in the venous pressure gradient at the stenosis site, alleviating the symptoms of intracranial hypertension.

We report a case of a previously healthy 12-year-old patient who presented with 10-day history of headaches, blurring of vision, nausea and vomiting, which evolved with worsening of the visual acuity and papilledema. Imaging scans disclosed stenosis of the right transverse and sigmoid sinuses. The patient underwent stenting of the stenotic venous segments and showed good evolution, with significant clinical improvement within 24 hours of the procedure.

Keywords

- ▶ intracranial hypertension
- ▶ papilledema
- ▶ pseudotumor cerebri
- ▶ intracranial thrombosis
- ▶ endovascular procedures

Resumo

A hipertensão intracraniana idiopática (HII) é uma doença caracterizada pelo aumento da pressão de abertura do líquido cefalorraquidiano associado a sintomas de aumento da pressão intracraniana. É mais frequente em mulheres, sendo habitualmente tratada

received
September 25, 2020
accepted
January 21, 2021
article published online
September 28, 2022

DOI <https://doi.org/10.1055/s-0041-1730331>.
ISSN 0103-5355.

© 2022. Sociedade Brasileira de Neurocirurgia. All rights reserved. This is an open access article published by Thieme under the terms of the Creative Commons Attribution-NonDerivative-NonCommercial-License, permitting copying and reproduction so long as the original work is given appropriate credit. Contents may not be used for commercial purposes, or adapted, remixed, transformed or built upon. (<https://creativecommons.org/licenses/by-nc-nd/4.0/>)
Thieme Revinter Publicações Ltda., Rua do Matoso 170, Rio de Janeiro, RJ, CEP 20270-135, Brazil

Palavras-chave

- ▶ hipertensão intracraniana
- ▶ papiledema
- ▶ pseudotumor cerebral
- ▶ trombose intracraniana
- ▶ procedimentos endovasculares

com medidas clínicas. O tratamento cirúrgico é reservado a uma minoria de casos que se mostram refratários. Os procedimentos cirúrgicos consagrados para este fim são a derivação liquórica e a fenestração de bainha do nervo óptico. Entretanto, eles estão associados a altos índices de complicações e recorrência.

Mais recentemente, a angioplastia de seio venoso com uso do *stent* vem sendo utilizada em casos em que há redução documentada no calibre dos seios transverso-sigmoide com repercussão comprovada no gradiente pressórico. Essa técnica está associada a uma redução significativa no gradiente de pressão venosa no local da estenose. Consequentemente, resulta em alívio dos sintomas da hipertensão intracraniana.

Neste trabalho, descrevemos o caso de um paciente de 12 anos de idade, sem doenças prévias, que apresentava quadro de cefaleia, turvação visual, náuseas e vômitos de início havia dez dias, tendo evoluído com piora da acuidade visual e papiledema. Realizou exame de imagem que identificou estenose dos seios transversos e sigmoide à direita. O paciente foi submetido a angioplastia dos segmentos venosos estenosados, apresentando boa evolução, com melhora clínica significativa já nas primeiras 24 horas após o procedimento.

Introduction

Idiopathic intracranial hypertension (IIH), also known as pseudotumor cerebri, is a syndrome with unknown etiology characterized by documented high opening pressure of the cerebrospinal fluid (CSF) on lumbar puncture (initial pressure > 25 cm H₂O).¹ The condition is associated with increased intracranial pressure (ICP), no localizing focal neurological signs (with exception of abducens nerve palsy), together with neuroimaging disclosing no cerebral abnormalities or hydrocephaly.¹

The physiopathology of IIH is not fully understood, and a number of mechanisms have been proposed to explain the condition, ranging from increased CSF production/reduced CSF absorption, to increased cerebral venous pressure.² It has been acknowledged that patients with IIH often present unilateral or bilateral stenosis of the transverse sinus.³ Despite controversy over whether transverse sinus stenosis plays a role in the physiopathology of IIH, angioplasty of the transverse sinus by stent placement can lower pre- and poststenosis gradient pressure, reduce venous and intracranial pressures by improving CSF reabsorption, and promote an improvement in symptoms.

In the present study, we report the case of a pediatric patient with IIH who underwent venous sinus stenting with subsequent improvement in symptoms. We also discuss the main aspects of this condition, based on a review of the literature.

Case Report

A previously healthy 12-year-old male patient presented with a 10-day history of headache together with blurred vision, dizziness, nausea and vomiting. The patient's condition declined, with worsening visual acuity, in the three days leading up to admission to the Emergency Room. A consul-

tation with the ophthalmologist resulted in a diagnosis of papilledema on an ocular fundus exam.

Computed tomography (CT) and magnetic resonance imaging (MRI) scans of the head with arterial and venous angiography (▶ **Fig. 1**) revealed signs of intracranial hypertension and narrowing at the transition of the transverse/sigmoid sinuses bilaterally. Given the suspected case of IIH associated with bilateral stenosis of the venous sinuses, cerebral angiography with microcatheter placement was performed to measure the pressure gradient and determine the need for angioplasty.

Endovascular Procedure

The night prior to the procedure, clopidogrel 300 mg and acetylsalicylic acid (ASA) 200 mg were administered. The procedure commenced with puncture of the left femoral artery and right common femoral vein with introduction of a 4F sheath using the Seldinger technique. A 4F vertebral diagnostic catheter was advanced via the left for the cerebral angiography study, which revealed severe stenosis of around 80% to 85% at the transition of the sigmoid-transverse sinuses bilaterally (▶ **Fig. 2A**). The study also showed redirecting of the supratentorial venous drainage to the diploic veins, and from the scalp in the frontoparietal convexity bilaterally.

A Head-Hunter (Merit Medical OEM, Salt Lake City, UT, US) 4F catheter was then advanced via the femoral vein, positioned at the right internal jugular vein, and, using coaxial catheter placement, an Excelsior (Stryker Neurovascular, Fremont, CA, US) SL10 microcatheter was advanced with the aid of a Transend Platinum (Stryker Neurovascular) microguide. Manometry of the intracranial venous sinuses was then performed, disclosing pre- and poststenosis pressure gradients, as described in ▶ **Table 1**.

Angioplasty with right stent placement was performed, because the left sinuses exhibited hypoplasia. The jugular-

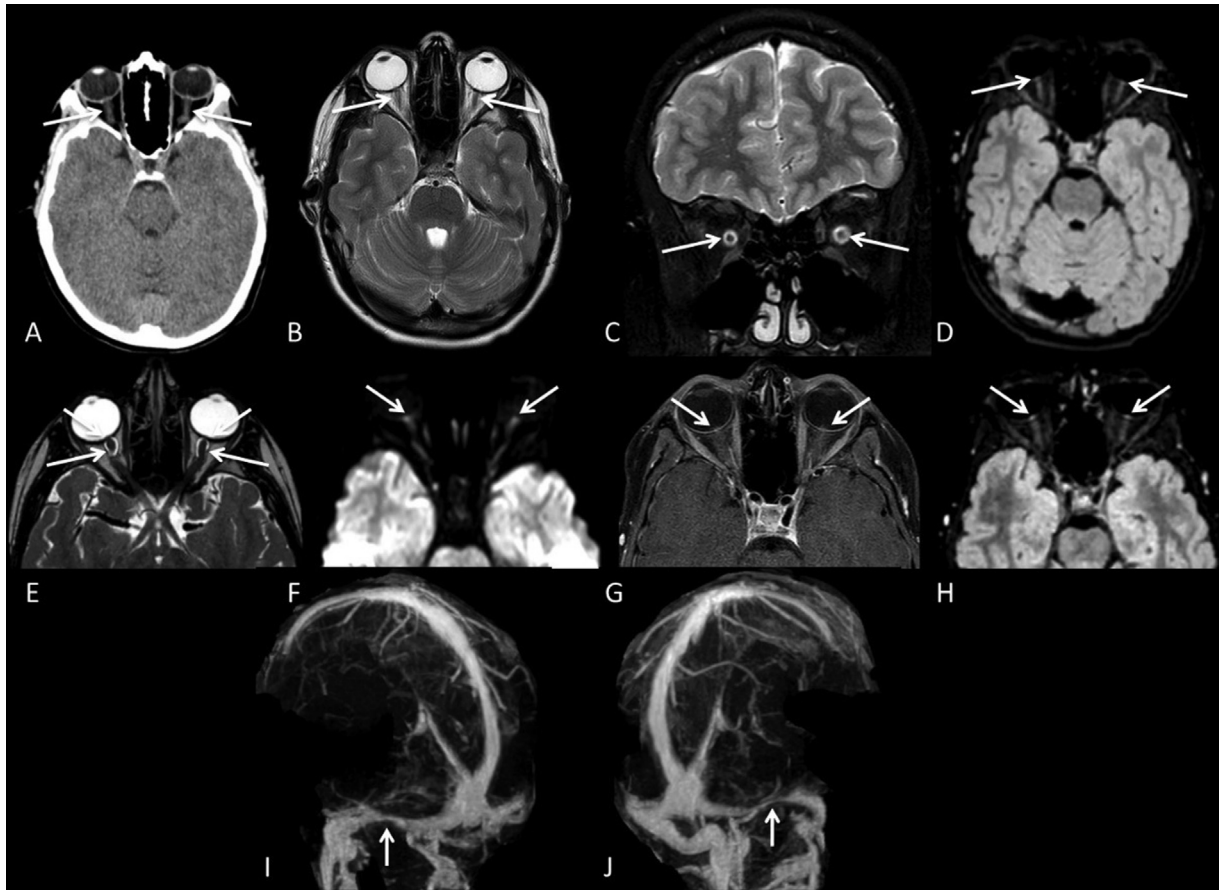


Fig. 1 (A) Computed tomography (CT) without contrast revealing cerebrospinal fluid (CSF) distension of the optic nerve sheath (white arrows). (B,C) T2-weighted axial and coronal sequences again showing CSF distension of the optic nerve sheath (white arrows). (D) Fluid-attenuated inversion recovery (FLAIR) weighted axial sequence revealing hyperintensity of the optic papilla (red arrows). (E,F,G,H) T2 driven equilibrium (DRIVE), diffusion-weighted imaging (DWI), T1 postcontrast and FLAIR postcontrast sequences to assess orbits provide a clearer view of the CSF sheath distension (blue arrows) and signs of bilateral papilledema (red arrows), displaying hyperintensity in diffusion sequence, postcontrast intensity on T1 and FLAIR, with the latter providing greater sensitivity. (I,J) Magnetic resonance angiography showing bilateral stenosis at the transition between the transverse and sigmoid sinuses (green arrows).

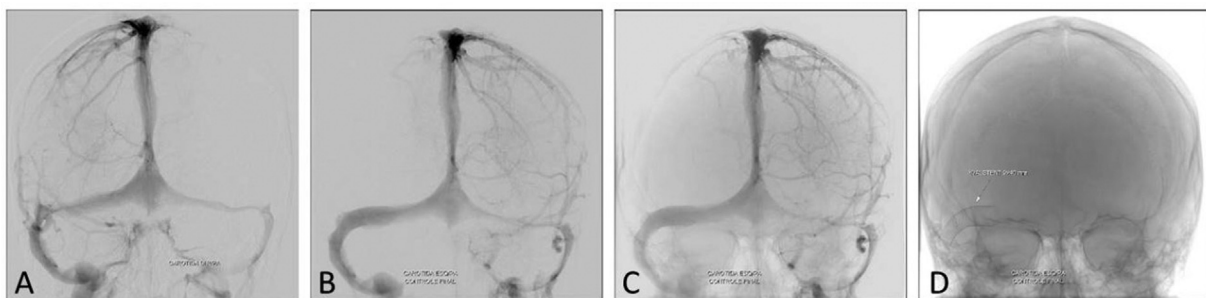


Fig. 2 (A-C) Front carotid angiogram disclosing: (A) bilateral stenosis at the transition of the transverse and sigmoid sinuses; (B,C) after venous angioplasty of the right transverse and sigmoid sinuses, with restoration of the normal caliber; (D) final position of the stent at the topography of the transition between the right transverse and sigmoid sinuses. A and B: with bone subtraction; C and D: without bone subtraction.

vein catheter was removed, and the short 4F sheath was replaced by a long NeuroMax (Penumbra, Inc., Alameda, CA, US) 8F sheath. With the aid of a Neuron Select (Penumbra, Inc.) 6F catheter and hydrophilic 0.035" stiff guidewire, the NeuroMax (Penumbra, Inc.) 8F sheath was advanced up to the right transverse sinus beyond the stenosis site. A 9 × 40 mm Carotid Wallstent (Boston Scientific Corporation, Marlborough, MA, US) was then advanced and deployed to

cover the transition of the right sigmoid-transverse sinuses (→ Fig. 2). An *Excelsior* (Stryker Neurovascular) SL10 microcatheter was then advanced with the aid of a *Transend Platinum* (Stryker Neurovascular) microguide, and manometry of the intracranial venous sinuses was performed (data shown in → Table 1).

The endovascular procedure was performed under general anesthesia and systemic heparinization. In the first 24 hours

Table 1 Values obtained by intracranial sinus manometry, before and after angioplasty

SITE	PREANGIOPLASTY MANOMETRY	POSTANGIOPLASTY MANOMETRY
Right internal jugular vein	10 mmHg	9 mmHg
Left internal jugular vein	10 mmHg	10 mmHg
Right sigmoid sinus	11 mmHg	10 mmHg
Left sigmoid sinus	11 mmHg	10 mmHg
Right transverse sinus	22 mmHg	10 mmHg
Left transverse sinus	22 mmHg	11 mmHg
Torcula	23 mmHg	11 mmHg

after the procedure, the patient reported an improvement in the headache. The blurring of vision gradually improved over the ensuing days. The patient was discharged from hospital on the third postoperative day, and was prescribed clopidogrel 75 mg/day for 3 months and ASA 100 mg/day for 1 year. A 3-month follow-up MRI confirmed improvement in the signs of intracranial hypertension (► Fig. 3).

Discussion

The annual incidence of IIH is of approximately 1 case for every 100,000 people, reaching up to 20 cases per 100,000 people when the population is constrained to obese women aged between 20 and 44 years.^{4,5}

For many years, IIH was interpreted as “intracranial hypertension secondary to arterial hypertension”, and regarded as a manifestation of brain edema due to a variety of different pathologies, including obstructive sleep apnea, chronic kidney disease, or connective tissue disorders.⁶ Another theory involves impairment of CSF absorption due to overuse of vitamin A derivatives, antibiotics, and hormonal contraceptives.⁷ Other studies highlight the importance of obesity in compromising intracranial venous drainage as a result of elevated intra-abdominal and right atrial venous pressures. These increases in pressure hamper cerebral venous return flow, increasing cerebral venous pressure.⁸

Unlike the cases typically found in the literature, in which around 86% of the patients with IIH are adult females with an average body mass index (BMI) > 30 kg/m²,⁹ the case herein reported is of a boy with normal BMI. However, recent recommendations do not support the use of BMI as a predictive factor for venous sinus stenosis.¹⁰ Thus, BMI should not be employed as a criteria to select patients for complementary investigations using angiography by catheter.

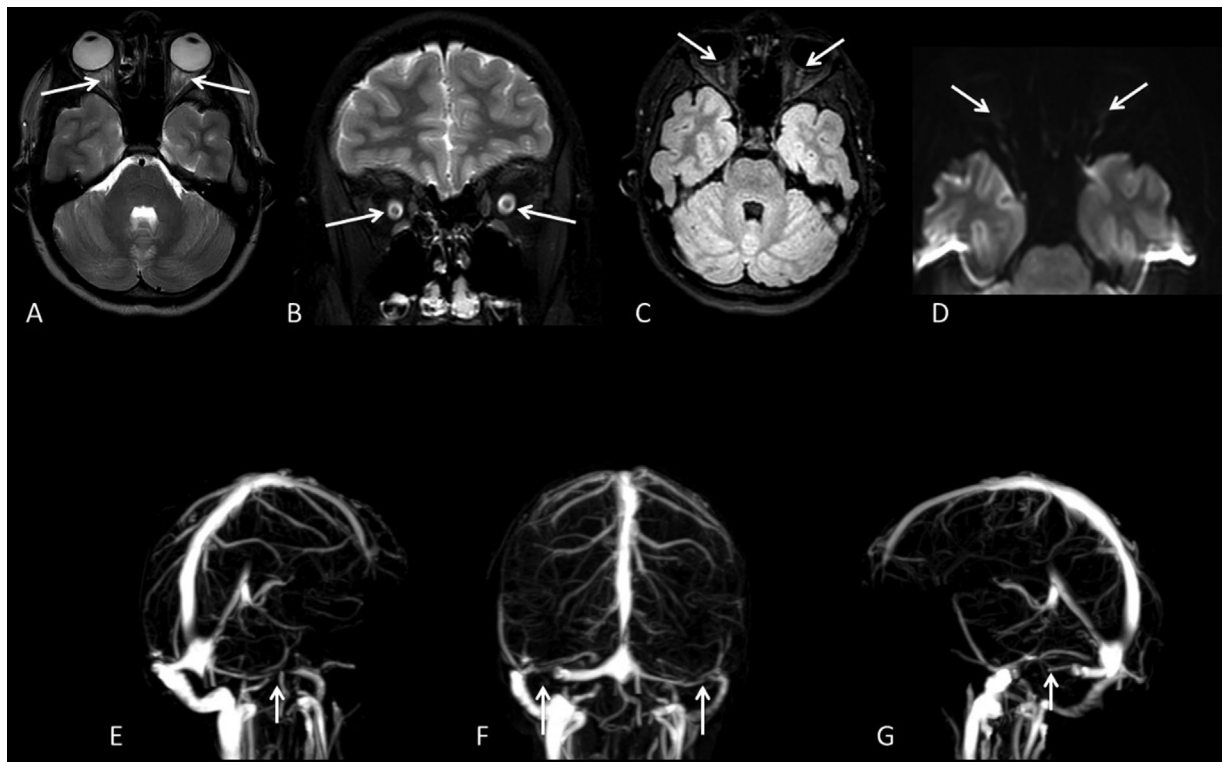


Fig. 3 (A,B): T2-weighted axial and coronal sequences showing distension of the optic nerve sheath, which was stable relative to a previous study. (C,D) FLAIR and DWI-weighted axial sequence revealing slight protrusion of the optic papilla, characterized by a slight hypersignal on the FLAIR sequence (white arrows), lower than that of the previous study, but not exhibiting hypersignal on the diffusion sequence (white arrows). (E,F,G) Magnetic resonance angiography showing stenosis at the transition between the left transverse and sigmoid sinuses (white arrows), stable relative to that of the previous study, highlighting material characterizing artefact with magnetic susceptibility contralaterally consistent with the stent (white arrow).

In IIH patients, MRI studies reveal empty sella turcica, cerebellar tonsillar herniation, meningoceles, CSF fistula, and venous stenoses of the sigmoid-transverse sinuses.¹¹ In the case herein reported, the patient presented distension of the optic nerve sheath and hyperintensity of the optic papilla. The main goals of the treatment include reducing the ICP to alleviate the symptoms of headache and preserve vision.¹¹ Persistent papilledema can develop with progressive optic atrophy, visual disability, and blindness.

The classic approaches for the management reported in the literature include weight loss, treatment using a carbonic anhydrase inhibitor (acetazolamide), and serial lumbar taps, traditionally considered auxiliary measures in the treatment of select cases.^{12,13} Patients with refractory IIH can be treated by fenestration of the optic nerve sheath or CSF shunts (ventriculoperitoneal or lumboperitoneal CSF shunting). These procedures, however, are associated with high rates of complication and recurrence.¹²

Recently, impaired venous drainage systems due to bilateral focal stenosis of cerebral venous sinuses (generally at the transverse-sigmoid transition) have become the focus of attention as a possible cause of IIH. Bilateral stenosis of venous sinuses is commonly associated with the occurrence of IIH, found in more than 50% of the patients. Most of these cases fail to respond to initial the weight-loss and acetazolamide therapy. The rates can reach 100% among patients refractory to the initial procedures.^{11,13,14} Whether venous stenosis is a cause or consequence of IIH remains unclear, but studies^{11,13} show that reducing cerebral venous pressure by implanting stents within the narrow venous segment is an effective approach to resolve the signs and symptoms of IIH.

In fact, decreasing the intraluminal pressure of the venous system promotes greater CSF absorption in the arachnoid granulations, in turn reducing the ICP.^{11,14} This notion was confirmed by Ding et al.¹⁵ in 2014, who showed a reduction in ICP after venous sinus stenting in a patient with IIH. Akin to the case herein reported, most previous studies^{4,11,16} show pre- and poststenosis sinus pressure gradients. Some reports^{4,11,16} demonstrate the importance of a pressure gradient ≥ 8 mmHg as a criteria for an indication of sinus stenting – as applied in the case herein presented. Patients with a pressure gradient between 4 mmHg and 7 mmHg can show some benefit from stenting in specific cases.^{4,11,16}

Stenosis of the transverse/sigmoid sinus can be classified into two types: intrinsic discrete stenosis, with clearly demarcated intraluminal narrowing, secondary to arachnoid granulations, fibrous septa, or fat deposits; and long stenosis narrowing with normal arachnoid granulations on imaging, secondary to extrinsic compression from swollen brain parenchyma.¹⁶ Patients with IIH generally present the latter pattern of transverse/sigmoid sinus stenosis, the same pattern seen in the case reported in the current study.¹⁶

This stenosis causes a slowing of venous outflow, resulting in venous hypertension. Consequently, CSF reabsorption is decreased, and ICP is further increased. External compression of the sinus then increases, with progressive collapse of its walls and further stenosis, exacerbating venous and intracranial hypertension via a feedback mechanism.^{4,13}

The use of venous stents is associated with a significant reduction in venous pressure gradient across the stenosis site before and after the procedure, as evidenced in the case herein presented (–Table 1). Consequently, stent deployment can interrupt the feedback mechanism described and result in relief of the IIH symptoms.¹⁷

Currently, there is no evidence suggesting that one type of stenting is superior to another to treat venous sinus stenosis. Similarly, the benefits of bilateral versus unilateral stent implantation in transverse sinuses remain unclear. In the present case, unilateral venous stent implant was performed in the dominant transverse/sigmoid segment only.¹⁸

Adjuvant antiplatelet therapy can be administered before stent implantation and maintained for 3 to 6 months, although there is no consensus on the optimal length of treatment.^{11,18,19} No data are available to support the inferiority of single versus dual antiplatelet therapy, but thromboembolic complications have been reported with the use of aspirin alone.¹⁷

Some complications with the technique have been reported (venous sinus perforation, stent migration, intra-procedural stent thrombosis, subdural hemorrhage, and development of further stenoses immediately proximal or distal to the stent), although no complications were observed in the case herein presented.^{12,13}

Conclusion

Venous sinus stent implantation is increasingly used for the management of IIH in the presence of bilateral stenosis of the cranial sinuses. Stent implantation can widen the narrowed sinus and facilitate venous drainage, thereby reducing intracranial hypertension. Although long-term follow-up is necessary, several studies show that stent placement for the management of symptomatic stenoses of transverse-sigmoid sinuses may be a safe and durable treatment that provides symptom relief in IIH patients.

Conflict of Interests

The authors have no conflict of interests to declare.

References

- Friedman DI, Jacobson DM. Diagnostic criteria for idiopathic intracranial hypertension. *Neurology* 2002;59(10):1492–1495
- McGeeney BE, Friedman DI. Pseudotumor cerebri pathophysiology. *Headache* 2014;54(03):445–458
- Elder BD, Goodwin CR, Kosztowski TA, et al. Venous sinus stenting is a valuable treatment for fulminant idiopathic intracranial hypertension. *J Clin Neurosci* 2015;22(04):685–689
- Dinkin MJ, Patsalides A. Venous sinus stenting in idiopathic intracranial hypertension: results of a prospective trial. *J Neuroophthalmol* 2017;37(02):113–121
- Durcan FJ, Corbett JJ, Wall M. The incidence of pseudotumor cerebri. Population studies in Iowa and Louisiana. *Arch Neurol* 1988;45(08):875–877
- Acheson JF. Idiopathic intracranial hypertension and visual function. *Br Med Bull* 2006;79-80:233–244
- Warner JEA, Larson AJ, Bhosale P, et al. Retinol-binding protein and retinol analysis in cerebrospinal fluid and serum of patients with and without idiopathic intracranial hypertension. *J Neuroophthalmol* 2007;27(04):258–262

- 8 Binder DK, Horton JC, Lawton MT, McDermott MW. Idiopathic intracranial hypertension. *Neurosurgery* 2004;54(03):538–551, discussion 551–552
- 9 Galgano MA, Deshaies EM. An update on the management of pseudotumor cerebri. *Clin Neurol Neurosurg* 2013;115(03):252–259
- 10 Hornby C, Mollan SP, Botfield H, O'Reilly MW, Sinclair AJ, O'Reilly MW, Sinclair AJ. Metabolic concepts in idiopathic intracranial hypertension and their potential for therapeutic intervention. *J Neuroophthalmol* 2018;38(04):522–530
- 11 Al-Mufti F, Dodson V, Amuluru K, et al. Neuroendovascular cerebral sinus stenting in idiopathic intracranial hypertension. *Intervent Neurol* 2020;8(2-6):164–171
- 12 Satti SR, Leishangthem L, Chaudry MI. Meta-Analysis of CSF diversion procedures and dural venous sinus stenting in the setting of medically refractory idiopathic intracranial hypertension. *AJNR Am J Neuroradiol* 2015;36(10):1899–1904
- 13 Daggubati LC, Liu KC. Intracranial venous sinus stenting: a review of idiopathic intracranial hypertension and expanding indications. *Cureus* 2019;11(02):e4008
- 14 Gurney SP, Ramalingam S, Thomas A, Sinclair AJ, Mollan SP. Exploring the current management idiopathic intracranial hypertension, and understanding the role of dural venous sinus stenting. *Eye Brain* 2020;12:1–13
- 15 Ding D, Starke RM, Durst CR, Crowley RW, Liu KC. Venous stenting with concurrent intracranial pressure monitoring for the treatment of pseudotumor cerebri. *Neurosurg Focus* 2014;37(1, Suppl):1
- 16 Miyachi S, Hiramatsu R, Ohnishi H, Takahashi K, Kuroiwa T. Endovascular treatment of idiopathic intracranial hypertension with stenting of the transverse sinus stenosis. *Neurointervention* 2018;13(02):138–143
- 17 Giridharan N, Patel SK, Ojugheli A, et al. Understanding the complex pathophysiology of idiopathic intracranial hypertension and the evolving role of venous sinus stenting: a comprehensive review of the literature. *Neurosurg Focus* 2018;45(01):E10
- 18 Saber H, Lewis W, Sadeghi M, Rajah G, Narayanan S. Stent survival and stent-adjacent stenosis rates following venous sinus stenting for idiopathic intracranial hypertension: a systematic review and meta-analysis. *Intervent Neurol* 2018;7(06):490–500
- 19 Silva JMA, Conti MLM, Aguiar GB, et al. Endovascular treatment for idiopathic intracranial hypertension improves clinical symptoms and signs. *Arq Bras Neurocir* 2017;36:1–6