



# Retrograde Approach for Intra-arterial Chemotherapy Delivery in Retinoblastoma

Giancarlo Saal-Zapata<sup>1</sup> Walter Durand<sup>1</sup> Alfredo Ramos<sup>1</sup> Raúl Cordero<sup>2</sup> Rodolfo Rodríguez<sup>1</sup>

<sup>1</sup>Interventional Neurosurgery Division, Clínica Angloamericana, San Isidro, Lima, Perú

<sup>2</sup>Oncological Ophthalmology Division, Clínica Angloamericana, San Isidro, Lima, Perú

**Address for correspondence** Giancarlo Saal-Zapata, MD, Interventional Neurosurgery Division, Clínica Angloamericana, 350 Alfredo Salazar Street, San Isidro 15073, Lima, Perú (e-mail: gian\_carlo1987@hotmail.com, gsaal@angloamericana.com.pe).

J Clin Interv Radiol ISVIR 2021;5:116–118.

## Abstract

Intra-arterial chemotherapy (IAC) is currently, the first-line treatment for retinoblastomas with successful cure rates. In difficult access or unsuccessful catheterization of the ophthalmic artery (OA), the middle meningeal artery is a second alternative followed by the Japanese technique using balloon. Nevertheless, when a well-developed posterior communicating artery is present, a retrograde approach to the OA through this vessel can be performed to deliver the chemotherapeutic drugs. We present a case of an unsuccessful catheterization of the OA through the internal carotid artery due to a challenging configuration of the OA/carotid siphon angle and describe an alternative form of navigation and catheterization through the posterior circulation. To our knowledge, this is the third report of a successful retrograde catheterization of the OA for IAC and constitutes an alternative route to deliver chemotherapy.

## Keywords

- retinoblastoma
- intra-arterial chemotherapy
- ophthalmic artery

## Background

Rb is the most frequent intraocular malignancy in the pediatric population and is more commonly diagnosed in the first 2 years of life.<sup>1,2</sup>

Currently, IAC is the first-line treatment for Rbs, achieving cure in low-grade cases (International Classification of Retinoblastoma grades A, B, and C), advanced cases (International Classification of Retinoblastoma grades D and E), and refractory cases.<sup>3–5</sup> The aim of this treatment is the successful catheterization of the OA to deliver a high concentration of chemotherapeutic agents directly, avoiding systemic toxicity, and achieving cure while preserving the visual function and the ocular globe.<sup>1,6</sup>

## Case Presentation

A 4-year-old child with prior enucleation of the right eye due to an advanced Rb was admitted to our institution with a class D Rb of the left eye. The visual acuity in the affected eye was severely compromised. Due to the advanced disease in the left eye, IAC was indicated.

Under general anesthesia, the right femoral artery was approached by Seldinger technique with manual palpation using the double-wall puncture technique followed by the insertion of a 5-French sheath. The 5-French Envoy (Cordis, Neurovascular Systems, Milpitas, California, United States) guide catheter over a 0.035-inch guidewire was navigated to the left ICA under fluoroscopic guidance. Irrigation with nimodipine in the saline solution was used to avoid OA spasm (► Fig. 1).

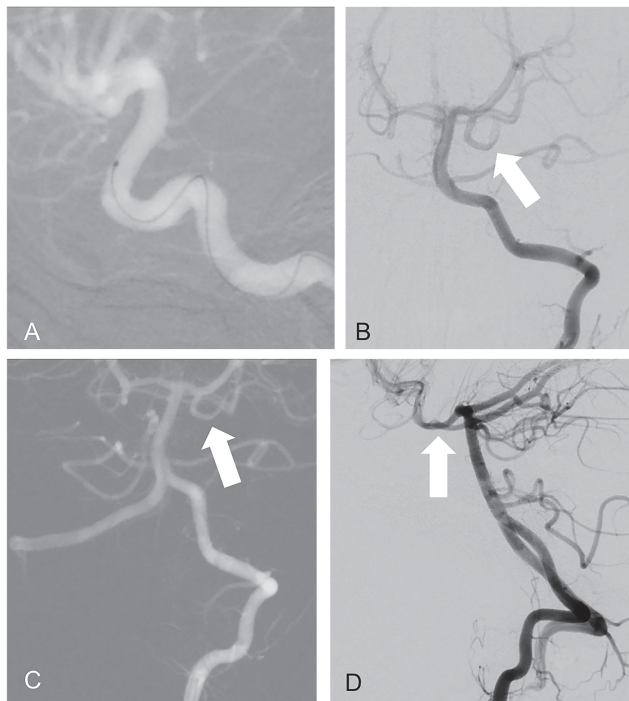
published online  
June 1, 2021

DOI <https://doi.org/10.1055/s-0041-1727584>  
ISSN 2457-0214

© 2021. Indian Society of Vascular and Interventional Radiology. This is an open access article published by Thieme under the terms of the Creative Commons Attribution-NonDerivative-NonCommercial-License, permitting copying and reproduction so long as the original work is given appropriate credit. Contents may not be used for commercial purposes, or adapted, remixed, transformed or built upon. (<https://creativecommons.org/licenses/by-nc-nd/4.0/>). Thieme Medical and Scientific Publishers Pvt. Ltd. A-12, 2nd Floor, Sector 2, Noida-201301 UP, India

The initial angiogram showed a challenging OA/carotid siphon angulation. The 1.3F Headway Duo (Microvention, Tustin, California, United States) microcatheter over an Hybrid 008 microwire (Balt Extrusion, Montmorency, France) was navigated to the ophthalmic segment of the ICA, but catheterization of the OA was unsuccessful due to the challenging morphology; the angle between ICA and the OA was 50 degrees. Placed in the left ICA, a strong injection of contrast showed the patency of a well-developed PComA and we decided to withdraw the guiding catheter from the left ICA and navigate through the left vertebral artery (VA) and perform a new angiogram revealing patency of both PComA. An angiogram of the external carotid artery (ECA) was not performed to evaluate if an ICA-ECA anastomosis was present. Once in the left VA, the Headway Duo microcatheter over a Hybrid 008 microwire was navigated easily through the basilar artery, P1 segment of the left posterior cerebral artery, and left PComA (►Fig. 1).

Due to the geometrical distribution and anatomy of the PComA in relation to the OA, with an obtuse angle of 144 degrees between these two arteries, the catheterization was successful using a retrograde approach and this was confirmed with a superselective injection from the OA ostium without reflux into the ICA (►Fig. 2). Posteriorly, the chemotherapeutic agent melphalan was delivered by pulsatile hand injection. A postprocedure angiogram was performed to rule out vascular injuries. The femoral sheath was withdrawn and hemostasis with manual compression was employed.



**Fig. 1** (A) Internal carotid artery navigation with microcatheter showing challenging morphology of the ICA to catheterize the ophthalmic artery. (B–D) Left vertebral artery angiogram and road mapping showing patency of the left posterior communicating artery (arrow). ICA, internal carotid artery.

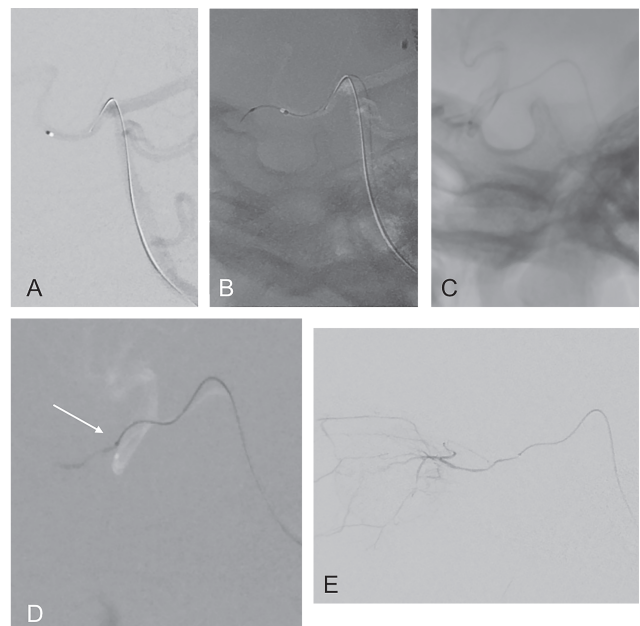
The patient’s evolution was uneventful after the endovascular procedure. There was no groin hematoma. No allergic reactions or secondary side effects of the chemotherapy were reported. Posteriorly, intravitreal chemotherapy was administered by the ophthalmologist without complications followed by two more sessions of IAC and the patient achieved cure at follow-up. The visual acuity after the procedures improved and the patient was able to distinguish and follow objects (►Fig. 2).

## Discussion

IAC is the first-line therapy for Rb. It can be used as primary or salvage treatment, achieving cure in 100% of groups B and C, 94% for group D, and 25% for group E.<sup>1,7</sup> It also allows the preservation of the ocular globe and visual function, especially in advanced cases.<sup>3,5,8</sup>

This treatment has demonstrated more advantages in advanced cases and refractory cases compared with systemic chemotherapy.<sup>3</sup> Moreover, for groups D and E, intravitreal chemotherapy has increased the cure rates successfully.<sup>7</sup>

Other alternatives for catheterization of the OA have been described previously: through the middle meningeal artery if an adequate anastomosis is developed between the ICA and ECA and on the other hand, the “Japanese technique” using a balloon just distal to the OA origin to deliver the drugs are available methods.<sup>4,9,10</sup>



**Fig. 2** Retrograde approach through vertebral artery. (A–C) Acquisition and road mapping to navigate through the posterior communicating artery, the internal carotid artery, and the ophthalmic artery. (D) Under road mapping, the microcatheter is placed in the ophthalmic artery ostium (arrow). (E) Ophthalmic artery angiogram shows the correct position of the microcatheter to deliver the drug into the tumor and without reflux.

In cases in which the catheterization of the OA is unsuccessful through the ICA due to a challenging carotid siphon or angulation, assessment of a well-developed PComA can help to navigate and catheterize the OA in a geometric and retrograde fashion successfully. The position of the OA and the configuration of the carotid siphon correlate with higher fluoroscopy times.<sup>11</sup> In our case, the time to cannulate the OA through the retrograde approach was 5 minutes. The radiation exposure and fluoroscopy time of the initial attempt through the ICA were higher compared with the retrograde approach (30 minutes 1,500 mGy vs. 10 minutes 500 mGy). This is explained due to the multiple attempts to catheterize the OA. The following interventions were faster and with less radiation.

Two authors previously described this approach when a tortuous carotid siphon was present.<sup>12,13</sup> Pham et al reported two cases which were treated successfully by the retrograde approach through the PComA associated with a faster time to catheterize due to anatomical considerations between the PComA and the OA without complications.<sup>12</sup>

Saglam et al reported their experience with the retrograde approach navigating through the PComA and the anterior communicating artery.<sup>13</sup> Their analysis involved the measurement of the angle between the PComA and the OA, being wider and allowing a straightforward access for the catheterization of the OA.

Whether the presence of a dominant PComA is frequent in the pediatric population is unknown. Arat evaluated the anterior circulation in children and found a correlation between age and ICA diameters.<sup>14</sup>

Our case met the criteria for an advanced disease and the decision was made to start IAC. Moreover, prior contralateral disease may be associated with a genetic predisposition in this particular patient.<sup>15</sup>

Advanced Rbs (grades D and E) have variable ocular salvage rates, ranging from 35 to 78.7%.<sup>5,8,16</sup> This heterogeneity of results is explained due to the adjunctive treatment that many patients receive.

Based on the overwhelming literature regarding IAC, the route through the ICA should be of preference. When dealing with challenging cases, options such as middle meningeal artery catheterization or retrograde approaches should be considered. However, a retrograde approach is a fast and straightforward option for navigation and selectively catheterize the OA if a dominant or well-developed PComA is present.

## Conclusion

The retrograde approach is a safe, fast, and straightforward alternative to catheterize the OA in cases of challenging carotid siphons if a dominant or well-developed PComA is present.

### Conflict of Interest

None declared.

## References

- Jabbour P, Chalouhi N, Tjoumakaris S, et al. Pearls and pitfalls of intraarterial chemotherapy for retinoblastoma. *J Neurosurg Pediatr* 2012;10(3):175–181
- Abramson DH, Dunkel IJ, Brodie SE, Marr B, Gobin YP. Superselective ophthalmic artery chemotherapy as primary treatment for retinoblastoma (chemosurgery). *Ophthalmology* 2010;117(8):1623–1629
- Abramson DH, Daniels AB, Marr BP, et al. Intra-arterial chemotherapy (ophthalmic artery chemosurgery) for group D retinoblastoma. *PLoS One* 2016;11(1):e0146582
- Manjandavida FP, Stathopoulos C, Zhang J, Honavar SG, Shields CL. Intra-arterial chemotherapy in retinoblastoma—a paradigm change. *Indian J Ophthalmol* 2019;67(6):740–754
- Wang L, Han M, Zhao J, et al. Intra-arterial chemotherapy for unilateral advanced intraocular retinoblastoma: results and short-term complications. *Medicine (Baltimore)* 2018;97(42):e12676
- Wyse E, Handa JT, Friedman AD, Pearl MS. A review of the literature for intra-arterial chemotherapy used to treat retinoblastoma. *Pediatr Radiol* 2016;46(9):1223–1233
- Dalvin LA, Kumari M, Essuman VA, et al. Primary intra-arterial chemotherapy for retinoblastoma in the intravitreal chemotherapy era: five years of experience. *Ocul Oncol Pathol* 2019;5(2):139–146
- Ravindran K, Dalvin LA, Pulido JS, Brinjikji W. Intra-arterial chemotherapy for retinoblastoma: an updated systematic review and meta-analysis. *J Neurointerv Surg* 2019;11(12):1266–1272
- Klufas MA, Gobin YP, Marr B, Brodie SE, Dunkel IJ, Abramson DH. Intra-arterial chemotherapy as a treatment for intraocular retinoblastoma: alternatives to direct ophthalmic artery catheterization. *Am J Neuroradiol* 2012;33(8):1608–1614
- Quinn C, Tummala R, Anderson J, Dahlheimer T, Nascene D, Jagadeesan B. Effectiveness of alternative routes of intra-arterial chemotherapy administration for retinoblastoma: potential for response and complications. *Interv Neuroradiol* 2019;25(5):556–561
- Area C, Yen CJ, Chevez-Barrios P, et al. Technical and anatomical factors affecting intra-arterial chemotherapy fluoroscopy time and radiation dose for intraocular retinoblastoma. *J Neurointerv Surg* 2019;11(12):1273–1276
- Pham C-T, Blanc R, Lumbroso-Le Rouic L, Pistocchi S, Bartolini B, Piotin M. Access to the ophthalmic artery by retrograde approach through the posterior communicating artery for intra-arterial chemotherapy of retinoblastoma. *Neuroradiology* 2012;54(8):845–848
- Saglam M, Sarici A, Anagnostakou V, et al. An alternative technique of the superselective catheterization of the ophthalmic artery for intra-arterial chemotherapy of the retinoblastoma: retrograde approach through the posterior communicating artery to the ophthalmic artery. *Neuroradiology* 2014;56(9):751–754
- Arat YO, Arat A, Aydin K. Angiographic morphometry of internal carotid artery circulation in Turkish children. *Turk Neurosurg* 2015;25(4):608–616
- Dimaras H, Corson TW, Cobrinik D, et al. Retinoblastoma. *Nat Rev Dis Primers* 2015;1:15021
- Yousef YA, Soliman SE, Astudillo PP, et al. Intra-arterial chemotherapy for retinoblastoma: a systematic review. *JAMA Ophthalmol* 2016;134(5):584–591