



Anti-IgE Monoclonal Antibody in Allergic Bronchopulmonary Aspergillosis Not Responding to Systemic Steroids

Pratibha Sharma¹ Ranganath T. Ganga^{2,✉}

¹Department of Microbiology, AIIMS Raipur, Raipur, Chhattisgarh, India

²Department of Pulmonary Medicine, All India Institute of Medical Sciences, Raipur, Chhattisgarh, India

Address for correspondence Ranganath T. Ganga, MD, Department of Pulmonary Medicine, All India Institute of Medical Sciences, D Block 1st Floor Gate No 4, Tatibandh, GE Road, Raipur, Chhattisgarh 4920, India (e-mail: ranganathtg@aiimsraipur.edu.in).

J Health Allied Sci^{NU} 2021;11:204–206.

Abstract

Keywords

- ▶ allergic bronchopulmonary aspergillosis
- ▶ aspergillus
- ▶ omalizumab
- ▶ prednisolone

Allergic bronchopulmonary aspergillosis (ABPA) is a hypersensitivity disorder caused by *Aspergillus fumigatus* commonly among patients of bronchial asthma. Early diagnosis is the key to successful management and preventing parenchymal destruction. Most of the patients respond well to systemic steroids. In patients not responding to standard treatment, the other treatment options include pulse steroids, antifungals, immunosuppressants, and omalizumab. But exact indication for each of these is not well established. Here we report a 41-year-old ABPA patient who was not responding to systemic steroids became totally asymptomatic with the administration of omalizumab.

Case Report

A 41-year-old never smoker lady on treatment for bronchial asthma for the past 15 years presented to our department with worsening cough, chest tightness, and breathlessness for the past 3 months. Her general examination revealed tachypnea (18 cycles/min) and tachycardia (146 beats/min). She was using accessory muscles of respiration. Chest examination revealed diffuse bilateral polyphonic rhonchi. Other systemic examinations were within normal limits. Chest X-ray (▶ **Fig. 1**) done was normal and her blood investigations revealed total leukocyte count of 8,900 cells/mm³, differential leukocyte count showed 61 polymorphs, 23 lymphocytes, 15 eosinophils, and 1 monocyte. Absolute eosinophil count was 1,335 cells/mm³. Total serum immunoglobulin E (IgE) was 1,644 IU/mL and *Aspergillus*-specific IgG was 32 IU/mL and IgM was 49 IU/mL. Her stool for ova and cyst examination and thyroid profile was normal. Skin prick test for aspergillus was positive for both *Aspergillus flavus* and *Aspergillus fumigatus*. High-resolution CT scan of thorax

(▶ **Fig. 2**) was normal except minimal traction bronchiectasis. She was unable to perform spirometry. A diagnosis of allergic bronchopulmonary aspergillosis (ABPA) without central bronchiectasis was made and patient was started on oral prednisolone 60 mg/d along with inhaled corticosteroid (ICS) budesonide 800 µg and long acting β agonist (LABA) formoterol 24 µg/d via metered dose inhaler with spacer. There was no clinical improvement at 2 weeks and oral itraconazole 200 mg twice daily was added to the regimen. She continued the same treatment for 2 months but with no improvement. Her total serum IgE and absolute eosinophil count (AEC) at monthly interval remained elevated. Meanwhile she started showing signs of corticosteroid adverse effects like skin bruises, proximal muscle weakness, gained 7 kg of weight by the end of 2 months of oral steroids. Hence, she was started on subcutaneous omalizumab 300 mg twice monthly along systemic steroids and ICS and LABA combination. Her symptoms improved gradually, and she was asymptomatic at the end of 7 days. Tapering of oral steroids was started after 7 days and stopped after 4 weeks along with itraconazole.

published online
May 25, 2021

DOI <https://doi.org/10.1055/s-0041-1726688>
ISSN 2582-4287

© 2021. Nitte (Deemed to be University).

This is an open access article published by Thieme under the terms of the Creative Commons Attribution-NonDerivative-NonCommercial-License, permitting copying and reproduction so long as the original work is given appropriate credit. Contents may not be used for commercial purposes, or adapted, remixed, transformed or built upon. (<https://creativecommons.org/licenses/by-nc-nd/4.0/>).

Thieme Medical and Scientific Publishers Pvt. Ltd. A-12, 2nd Floor, Sector 2, Noida-201301 UP, India

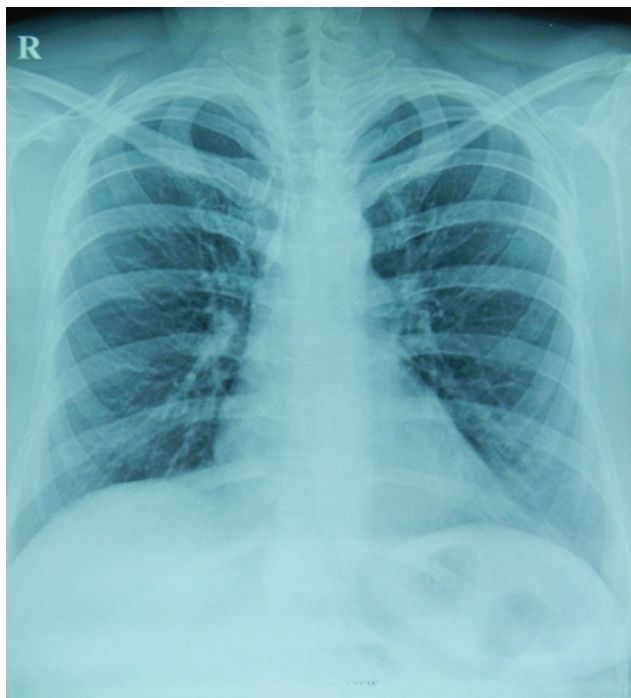


Fig. 1 Chest X-ray PA view showing normal lung fields. PA, posteroanterior.

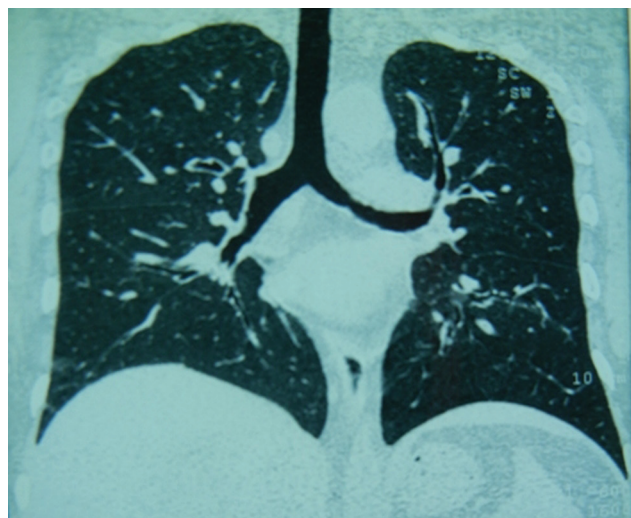


Fig. 2 HRCT thorax coronal reformation showing normal lung parenchyma with minimal bronchiectatic changes. HRCT, high-resolution computed tomography.

She was continued on budesonide 400 µg and formoterol 12. FEV1%, total serum IgE, and AEC monitored once monthly till 6 months. No clinically significant adverse events were observed during this period. The findings including clinical follow-up, IgE levels, and eosinophil count are summarized in **Table 1**. After 6 months omalizumab was given once in a month with good symptom control.

Discussion

ABPA is an allergic pulmonary disorder caused by hypersensitivity to *Aspergillus fumigatus*¹ first recognized by Hinson et al in 1962 in the United Kingdom.² The prevalence of ABPA is approximately 1 to 2% in asthma and 2 to 15% in cystic fibrosis.³ There is no gender predilection. Patients usually present in fourth or fifth decade of life with worsening cough, expectoration of tenacious sputum, breathlessness, low-grade fever, and hemoptysis.⁴ Early diagnosis and treatment are important in preventing parenchymal damage and loss of lung function. Diagnosis can be confirmed using the Rosenberg-Peterson criteria⁵ or the minimal diagnostic criteria.⁶ Common differential diagnoses include tuberculosis, sarcoidosis, tropical pulmonary eosinophilia, Churg Strauss syndrome, eosinophilic pneumonia, and malignancy.

Majority of the patients usually respond to systemic steroids.¹ Other therapeutic options among those not adequately responding include addition of itraconazole⁷ or voriconazole,⁸ pulse doses of IV methylprednisolone,⁹ nebulized amphotericin, and budesonide.¹⁰

Omalizumab (Xolair) is a humanized monoclonal anti-IgE antibody that binds to FcεRI (high-affinity IgE receptor) and FcεRII (low-affinity receptor) areas of the IgE heavy chain (CH3 region), preventing the interaction of free IgE with its receptors on mast cells and basophils.¹¹ Omalizumab-IgE complex does not bind to the FcεRI-bound IgE on the mast cells and basophils, thereby avoiding anaphylactic reaction.¹² Omalizumab has already been used as add on therapy for moderate to severe asthma. It has also been used successfully in allergic asthma. It causes an 88 to 99% reduction in free IgE levels and symptomatic relief very rapidly following administration.¹³ It has very high safety profile. Omalizumab has been successfully used in the case of ABPA with cystic fibrosis.¹⁴ But the use of the same in ABPA without cystic fibrosis has been not

Table 1 Showing clinical monitoring over 6 months

Months	0	1	2	3	4	5	6
PEFR	90	270	390	450	510	550	560
IgE level	1,873	–	1,000.1	–	900.3	–	733.1
ACT score	5	13	23	23	24	24	24
AEC in cell/ mL ³	1,342	455	313	376	312	297	310
Dose of budesonide ^a	800	800	400	400	400	400	400

Abbreviations: ACT, asthma control test; AEC, absolute eosinophil count; FEV1, peak expiratory flow rate (mL/s); IgE, immunoglobulin E; PEFR, peak expiratory flow rate.

^aDose per day via metered dose inhaler (µg/d).

well studied. Decision to use omalizumab in our patient was taken as an end resort because of its high cost and patient responded well to omalizumab and her symptoms were well controlled on continued use along with other objective markers of disease control.

Conclusion

Our case report highlights that omalizumab can be a safer therapeutic option among ABPA patients who do not adequately respond to systemic steroids.

Conflict of Interest

None declared.

References

- 1 Greenberger PA. Allergic bronchopulmonary aspergillosis. *J Allergy Clin Immunol* 2002;110(5):685–692
- 2 Hinson KFW, Moon AJ, Plummer NS. Broncho-pulmonary aspergillosis; a review and a report of eight new cases. *Thorax* 1952;7(4):317–333
- 3 Greenberger PA. Clinical aspects of allergic bronchopulmonary aspergillosis. *Front Biosci* 2003;8:s119–s127
- 4 Kumar R. Mild, moderate, and severe forms of allergic bronchopulmonary aspergillosis: a clinical and serologic evaluation. *Chest* 2003;124(3):890–892
- 5 Rosenberg M, Patterson R, Mintzer R, Cooper BJ, Roberts M, Harris KE. Clinical and immunologic criteria for the diagnosis of allergic bronchopulmonary aspergillosis. *Ann Intern Med* 1977;86(4):405–414
- 6 Schwartz HJ, Greenberger PA. The prevalence of allergic bronchopulmonary aspergillosis in patients with asthma, determined by serologic and radiologic criteria in patients at risk. *J Lab Clin Med* 1991;117(2):138–142
- 7 Wark PA, Hensley MJ, Saltos N, et al. Anti-inflammatory effect of itraconazole in stable allergic bronchopulmonary aspergillosis: a randomized controlled trial. *J Allergy Clin Immunol* 2003;111(5):952–957
- 8 Mulliez P, Croxo C, Roy-Saint Georges F, Darras A. Allergic broncho-pulmonary aspergillosis treated with voriconazole. *Rev Mal Respir* 2006;23(1 Pt 1):93–94
- 9 Thomson JM, Wesley A, Byrnes CA, Nixon GM. Pulse intravenous methylprednisolone for resistant allergic bronchopulmonary aspergillosis in cystic fibrosis. *Pediatr Pulmonol* 2006;41(2):164–170
- 10 Laoudi Y, Paolini JB, Grimfed A, Just J. Nebulised corticosteroid and amphotericin B: an alternative treatment for ABPA? *Eur Respir J* 2008;31(4):908–909
- 11 Avila PC. Does anti-IgE therapy help in asthma? Efficacy and controversies. *Annu Rev Med* 2007;58:185–203
- 12 Infar D, Crameri R, Lamers R, Achatz G. Molecular and cellular targets of anti-IgE antibodies. *Allergy* 2005;60(8):977–985
- 13 Strunk RC, Bloomberg GR. Omalizumab for asthma. *N Engl J Med* 2006;354:2689–2695
- 14 van der Ent CK, Hoekstra H, Rijkers GT. Successful treatment of allergic bronchopulmonary aspergillosis with recombinant anti-IgE antibody. *Thorax* 2007;62(3):276–277