

Bipolar Radiofrequency Ablation of Benign Symptomatic Thyroid Nodules: Initial Experience

Bipolare Radiofrequenzablation von gutartigen, symptomatischen Schilddrüsenknoten: Erste Erfahrungen

Authors

Y. Korkusuz¹, C. Erbeling¹, K. Kohlhasse¹, W. Luboldt², C. Happel¹, F. Grünwald¹

Affiliations

¹ Department of Nuclear Medicine, Johann Wolfgang von Goethe University Hospital, Frankfurt, Germany

² Department of Diagnostic and Interventional Radiology, Johann Wolfgang von Goethe University Hospital, Frankfurt, Germany

Key words

- thyroid
- head/neck
- ablation procedures
- radionuclide imaging
- ultrasound
- hyperthermia

received 7.9.2015

accepted 9.11.2015

Bibliography

DOI <http://dx.doi.org/10.1055/s-0041-110137>
 Published online: 29.12.2015
 Fortschr Röntgenstr 2016; 188: 671–675 © Georg Thieme Verlag KG Stuttgart · New York · ISSN 1438-9029

Correspondence

Christian Erbeling
 Department of Nuclear Medicine, University Hospital Frankfurt
 Theodor Stern Kai 7
 60590 Frankfurt
 Germany
 Tel.: ++49/1 52/21 78 17 70
 Fax: ++49/69/63 01 71 43
cerbeld@googlemail.com

Zusammenfassung



Ziel: Bestimmung der Sicherheit und Wirksamkeit des Einsatzes von bipolarer Radiofrequenzablation (RFA) in gutartigen Schilddrüsenknoten.

Material und Methoden: 23 Patienten mit 24 symptomatischen gutartigen Schilddrüsenknoten (21 regressive, 3 autonome Adenome), welche zwischen 0,5 ml und 112 ml maßen (Mittelwert \pm s: $18 \pm 24,4$), wurden mittels bipolarer RFA behandelt. Während der Behandlung auftretende Schmerzen wurden auf einer 10-Punkte-Skala gemessen. Nebenwirkungen, welche durch Ultraschall festgestellt wurden oder von Patienten angegeben worden sind, wurden dokumentiert. Die periablativ Wirksamkeit wurde 24 Stunden nach der RFA mittels der Änderung (Δ) der Thyreoglobulin(Tg)-Konzentration im Serum und sonografischer Kriterien gemessen. Echogenität und Blutfluss wurden auf einer 3-Punkte-Skala gemessen, während die Elastizität auf einer 4-Punkte-Skala gemessen wurde. Die Wirksamkeit der Behandlung in den Adenomen wurde mittels der Normalisierung des ^{99m}Tc -pertechnetate-Szintigramms bestimmt.

Ergebnisse: Bipolare RFA wurde von allen Patienten gut toleriert. Sie zeigten eine mediane Schmerzintensität von $3 \pm 1,5$, wobei die Ausprägungen von 1 bis 7 reichten. Nebenwirkungen waren Hämatome bei 4 von 23 Patienten (17%). Bipolare RFA führte zu einer signifikanten ($p < 0,01$) Abnahme der Echogenität, des Blutflusses und der Elastizität ($\Delta = 1 \pm 0,28$, $1 \pm 0,46$ und $1 \pm 0,85$ Punkte), zu einer medianen Steigerung der Tg-Konzentration von 403 ± 2568 ng/ml sowie zu einer Normalisierung der Szintigrafiebildgebung.

Schlussfolgerung: Bipolare RFA ist eine sichere und effektive Behandlung für gutartige symptomatische Schilddrüsenknoten.

Abstract



Purpose: To determine the safety and efficacy of bipolar radiofrequency ablation (RFA) in benign thyroid nodules.

Methods: 23 patients with 24 symptomatic benign thyroid nodules (21 regressive, 3 adenomas) ranging in volume from 0.5 to 112 ml (mean \pm sd: 18 ± 24.4 ml) underwent bipolar RFA. Pain during the procedure was measured on a 10-point scale. Side-effects revealed by ultrasound or patients' complaints were documented. Periablativ efficacy was measured 24 hours after RFA as change (Δ) in serum thyreoglobulin (Tg) and sonographic criteria (echogenicity, Doppler blood flow and elasticity) categorized on a 3-point scale (echogenicity, Doppler blood flow) or 4-point scale (elasticity). Efficacy in the 3 autonomous adenomas was measured as normalization of ^{99m}Tc -pertechnetate scintigraphy.

Results: Bipolar RFA was well tolerated by all patients with a median pain score of 3 ± 1.5 (range: 1–7). Side-effects were hematomas in 4 of 23 patients (17%). Bipolar RFA resulted in a significant ($p < 0.01$) decrease in echogenicity, blood flow, elasticity ($\Delta = 1 \pm 0.28$, 1 ± 0.46 and 1 ± 0.85 points, respectively), a median increase in Tg of 403 ± 2568 ng/ml as well as in a normalization of scintigraphy.

Conclusion: Bipolar RFA is a safe and effective treatment option for symptomatic benign thyroid nodules.

Key points:

- ▶ Bipolar RFA is a safe and effective treatment for benign thyroid nodules.
- ▶ Ultrasound imaging allows guidance during bipolar radiofrequency ablation.
- ▶ ^{99m}Tc -pertechnetate is able to detect the ablation area of autonomous adenomas.

Kernaussagen:

- ▶ Bipolare RFA ist eine sichere und effektive Behandlungsoption für gutartige Schilddrüsenknoten.
- ▶ Ultraschallbildgebung erlaubt die Kontrolle der Ablation während der RFA.
- ▶ ^{99m}Tc -pertechnetate Szintigrafie ermöglicht die Erfassung der Ablationszone in autonomen Adenomen.

Introduction

Bipolar radiofrequency ablation (RFA) is a new method to treat symptomatic thyroid nodules. The precursor method, monopolar RFA, has been already used for years in treating tumors in liver, osteoid osteomas [1] and thyroid nodules [2]. In monopolar ablation there is a need for a grounding pad in addition to the treating electrode, whereas bipolar RFA has its anode and cathode integrated into one single electrode. Consequently, in monopolar RFA systems the electric current runs through the entire body, whereas the zone of electric current is limited to the area around the active tip of the bipolar electrode. High-frequency alternating electric current is applied to the electrode, which forces the dipoles of the surrounding water molecules to change direction accordingly. Due to the frictional heat arising from this ionic agitation the surrounding tissue is heated to more than 60 °C, causing instantaneous protein denaturation and irreversible cell death [3]. The resulting coagulative necrosis is then degraded by the patient's own immunosystem including neutrophils, macrophages and T-lymphocytes as effector cells [4]. The purpose of the study was to determine the safety and efficacy of bipolar RFA in treating benign thyroid nodules.

Material and methods**Patients**

23 patients (6 men, 17 women) with median age 49 years (range: 36–75 years) with a total of 24 nodules (3 autonomous adenomas, 21 regressive nodules) underwent bipolar RFA on an outpatient basis. Nodule volume ranged from 0.5 ml to 112.3 ml with a mean volume of 18 ± 24.4 ml. Inclusion criteria were symptoms requiring surgery (cosmetic problems; compressive symptoms such as foreign body sensation, hoarseness and dysphagia) but also refusal of radioiodine therapy or surgery, high surgical risk or contraindications to surgery. Exclusion criteria included excessive thyroid volume with retrosternal growth, critical position to adjacent structures such as vessels, trachea, esophagus and nerves as well as malignancy. Malignancy was excluded in all patients by ^{99m}Tc -pertechnetate scintigraphy followed by ^{99m}Tc -MIBI scintigraphy and fine needle aspiration biopsy in case of a "cold" nodule in ^{99m}Tc -pertechnetate scintigraphy [5] as well as by normal calcitonin blood levels. The study was approved by the local ethics committee.

Bipolar RFA

For bipolar RFA, a generator with a maximum output of 250 W at a frequency of 470 ± 10 kHz was used (POWER System, Olympus Hamburg, Germany) with an internally-cooled 15 gauge electrode with an active tip of 20 to 40 mm or un-cooled 18 gauge electrode with an active tip of 9 to 15 mm (CelonProSurge, Olympus Hamburg, Germany).

Prior to the procedure a short 0.9% NaCl infusion with 2 mg Metamizole (Novaminsulfon-ratiopharm, Ulm, Germany) is admi-

Citation Format:

- ▶ Korkusuz Y, Erbeling C, Kohlhasse K et al. Bipolar Radiofrequency Ablation of Benign Symptomatic Thyroid Nodules: Initial experience with Bipolar Radiofrequency. Fortschr Röntgenstr 2016; 188: 671–675

nistered. Then, the position of the nodule was marked on the skin. Under ultrasound-guidance local anesthesia (Mepivacain-hydrochloride 1% (AstraZeneca, Wedel, Germany)) was injected to reduce the pain during the skin incision and insertion of the electrode. In case of a complex cystic nodule the anesthetic needle was simultaneously used to drain the fluid from the cystic nodule. This was done in order to both minimize the pre-procedural ablation volume and to exclude possible heat-sink effects resulting from cystic fluids.

After local anesthesia of the skin was achieved, a 2 mm incision was made to place the RFA electrode via a transisthmic approach into the nodule. This transisthmic approach enables optimal visualization of the electrode as well as a maximum safety margin to vulnerable structures like carotid arteries, jugular veins, vagus nerve and the recurrent laryngeal nerve which is situated in the so called "danger triangle" between trachea and thyroid [6]. If a transisthmic approach was not possible, a craniocaudal approach was chosen. Treatment was started using a footswitch and monitored by ultrasound. Ablation was achieved by a so-called multi-shot technique, beginning with ablation at the deepest point of the nodule and then repositioning the electrode thereby creating multiple overlapping ablation zones. This procedure was repeated until the whole nodule was hollowed out or the safety margin was reached. Before removing the electrode a control ultrasound was performed to ensure that the nodule was treated successfully.

Assessment of patient's tolerance and safety

Pain during the procedure was measured on a 10-point scale ranging from no pain = 0 to the most imaginable pain = 10. Side-effects revealed by ultrasound as well as patient complaints were documented.

Assessment of efficacy

Periablative efficacy was measured 24 hours after RFA as the change (Δ) in serum thyreoglobulin (Tg) and ultrasound-measured criteria compared to the baseline values obtained before RFA. For that purpose echogenicity, Doppler blood flow and elasticity were categorized: echogenicity on a 3-point scale (hypo-echogenic = 1; iso-echogenic = 2; hyper-echogenic = 3), Doppler blood flow on a 3-point scale (no perfusion = 1; slight perfusion = 2; marked perfusion = 3) [7] and elasticity on a 4-point scale (soft = 1, more soft than solid = 2, more solid than soft = 3, solid = 4) [8]. Ultrasound data was generated by the SonixTOUCH system (Ultrasonix Medical Corporation, Richmond, BC, Canada). Patients with autonomous adenomas additionally got a ^{99m}Tc -pertechnetate scintigraphy 24 hours after thermal ablation to ensure complete elimination of the hot spot area defined as successful therapy [9].

Statistical analysis

Statistical analysis was performed using Prism 6 for Mac OS X Version 6.0 f (GraphPad Software, La Jolla, California, USA). Wilcoxon matched-pairs signed rank tests were performed to com-

pare blood levels and the above mentioned sonographic scores before and after treatment. Statistical significance was indicated with p -values < 0.05 .

Results

Patient's tolerance and safety

Bipolar RFA was well tolerated by all patients with a median pain score of 3 ± 1.5 (range: 1 – 7). Patients complained of pain during local anesthesia and when power was activated. When the patient's pain was too great the treatment was paused for a short time until the patient was comfortable again. After turning off power to the electrode, the pain stopped within seconds. The treatment never had to be abandoned. In 19 of 23 patients (83%) spread of pain was observed to the following locations: tooth ($n=5$), ears ($n=3$), neck ($n=3$), spine ($n=1$), gonial angle ($n=9$) and shoulder ($n=1$). Additional heat was felt by 9 of 23 patients (39%). Side effects included a hematoma in 4 of 23 patients (17%) (► **Tab. 1**). Side effects that did not occur included dysphagia, hoarseness, infections, burns at puncture site, nodule rupture or Horner's syndrome and vagal reactions.

Efficacy

Bipolar RFA resulted in a significant ($p < 0.01$) decrease in echogenicity ($\Delta = 1 \pm 0.28$ points) (► **Fig. 1**), blood flow ($\Delta = 1 \pm 0.46$ points) (► **Fig. 2**) and elasticity ($\Delta = 1 \pm 0.85$ points) with a significant ($p < 0.01$) increase in Tg (median $\Delta Tg = 403 \pm 2568$ ng/ml) (► **Fig. 3**). The 3 cases with autonomous adenomas showed a normalization of scintigraphy (► **Fig. 4**).

Discussion

Our feasibility study shows that bipolar RFA provides a safe and effective treatment option for benign thyroid nodules as an alternative to radioiodine-therapy and surgery. The switch from mono- to bipolar RFA avoids burns at the grounding pad site [10] and the risk of RFA associated malfunction of implanted electrical devices such as pacemakers [11] should be reduced, since the electric current is limited to the area between the two poles of the bipolar electrode and does not stream omnidirectionally between the skin and a monopolar electrode. The fact that the electric current is limited to the area surrounding the bipolar electrode leads to a more predictable ablation zone in terms of size and geometric shape, a higher energy density and a shorter duration of ablation time [12]. Since no shaving is needed to place a grounding pad, the treatment is less discom-

Table 1 Side effects rate in $n = 23$ patients.

Tab. 1 Nebenwirkungen in $n = 23$ Patienten.

side effects	n (%)
pain during ablation	23 (100 %)
hematoma	4 (17 %)
hoarseness	0 (0 %)
burns	0 (0 %)
infection	0 (0 %)
nodule rupture	0 (0 %)
dysphagia	0 (0 %)
horner's syndrome	0 (0 %)
vagal reaction	0 (0 %)

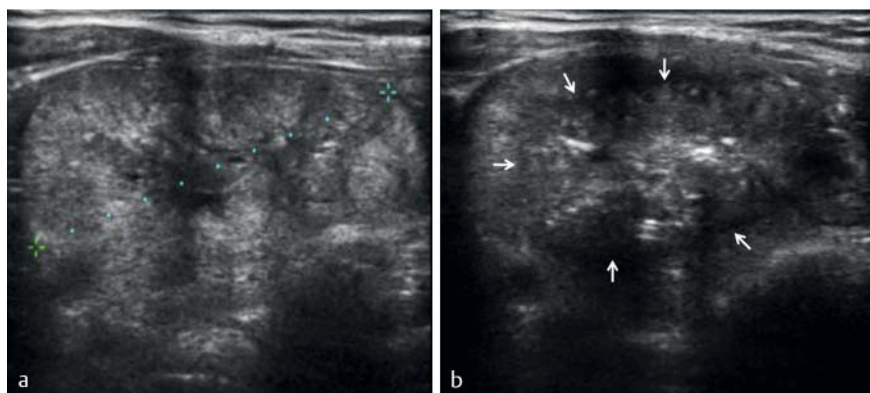


Fig. 1 Decrease of echogenicity of a nodule (dotted line = diameter) after bipolar radiofrequency ablation (RFA) as proof of efficacy. (Isoechogenic before **a** and hypoechogenic after therapy **b**); note that the hyperechoic spots represent so-called microbubbles. White arrows are displaying the border of the ablation zone.

Abb. 1 Abnahme der Echogenität eines Knotens (gepunktete Linie = Durchmesser) nach der Radiofrequenzablation als Beweis der Effektivität. (Isoechogen vor **a** und hypoechogen nach **b** der Therapie); beachten Sie, dass die hyperechoischen Flecken sogenannte Microbubbles sind. Die weißen Pfeile markieren die Grenzen der Ablationszone.

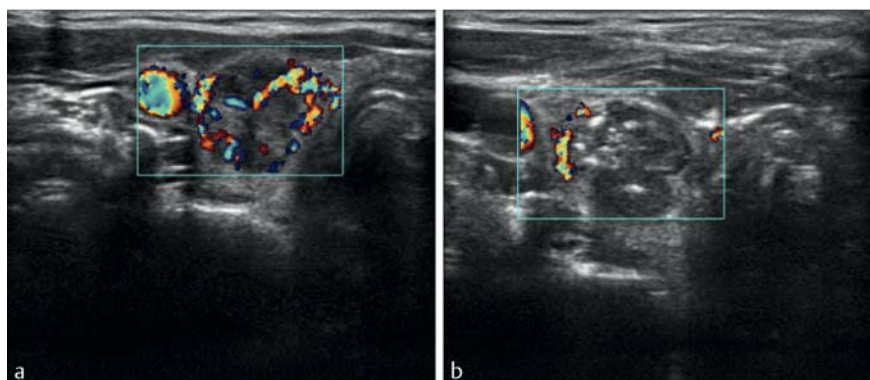


Fig. 2 Decrease of Doppler blood flow after bipolar radiofrequency ablation (RFA) as proof of efficacy. (Ratings: marked intra-/perinodal perfusion before **a** and slight intra-/perinodal perfusion after therapy **b**).

Abb. 2 Abnahme des Doppler-Blutflusses nach bipolarer Radiofrequenzablation als Beweis der Effektivität. (ausgeprägte intra-/perinodale Perfusion vor **a** und leichte intra-/perinodale Perfusion nach **b** der Therapie).

portable and saves time in comparison to monopolar RFA. Additionally, this study suggests that bipolar RFA can also be used as a radiation-free alternative to radioiodine therapy. This is particularly interesting when autonomous adenomas need to be treated in pregnant or lactating women where radioiodine therapy is contraindicated [13], or when patients deny radioiodine therapy because they fear radiation. RFA can thus be used as a less invasive alternative to surgery in cases where radioiodine-therapy cannot be performed. In contrast to radioiodine-therapy, bipolar RFA works independently of the uptake of iodine which limits radioiodine therapy for volume-reduction and consequently generally requires surgery for that purpose. This feasibility study therefore focused on the treatment of benign thyroid nodules, where RFA can offer an alternative to surgery. Alternative treatment options for benign thyroid nodules include percutaneous ethanol injections (PEI) [14], high-intensity focused ultrasound (HIFU) [15] as well as laser, microwave or radiofrequency ablation [2, 5, 16]. The percutaneous ethanol injection shows excellent results in cystic nodule volume reduction but poor results in solid nodules [14]. High intensity focused ultrasound is the only non-invasive technique however it works only in small nodules [15].

Benign nodules do not take up enough iodine for radioiodine therapy, so surgery is recommended. This explains the high rate

of 59 000 thyroid nodule-related operations per year in Germany. However, surgery has the disadvantages of general anesthesia, scar formation, the risk of hypoparathyroidism [17] as well as the risk of recurrent laryngeal nerve palsy. Thus, RFA may become an alternative to surgery and it can be performed on an out-patient basis thus reducing costs [18].

Finally, bipolar RFA is relatively straightforward to perform. The placement of the electrode and RFA can be guided by ultrasound. RFA is associated with a decrease in echogenicity which can be used to monitor the procedure. The formation of hyper-echogenic dots, so called microbubbles can be used to assess the spread of heat during the procedure (Fig. 1) [19]. Since there is the risk of thermal damage to the recurrent laryngeal nerve [20] and the fact that the tissue temperature cannot be assessed without inserting further temperature electrodes into the thyroid, the patient is encouraged throughout the entire procedure to speak from time to time to assess if any voice changes or hoarseness occur which would indicate thermal damage to the recurrent laryngeal nerve. Before removing the electrode a control ultrasound was performed to ensure that the nodule was treated successfully. In addition to B-mode and Doppler flow imaging, elastography also showed a significant change and thus could be also used to monitor the procedure -particularly where it indicates the margin of the nodule better than B-mode ultrasound [21].

However, further studies are necessary to optimize procedure monitoring and to calculate the necessary energy transfer to achieve ablation. Further investigation is also needed into the final reduction in nodule volume and its sustainability as well as the risk of inducing autoimmune thyroiditis which should be evaluated in a follow-up study. Analysis of volume reduction was not within the scope of the study as its effects take longer than the 24 hours we had allocated. The periablative efficacy is proven by the increase in Tg because Tg is liberated by cell destruction so that the increase in Tg reflects thyroid cell death. The promising results of this feasibility study regarding the periablative efficacy warrant further research.

Our study has several limitations as it is not a randomized trial which compares monopolar to bipolar RFA in benign thyroid nodules in general, or bipolar RFA to radioiodine therapy and surgery in hyperfunctioning thyroid nodules. Yet the promising results of this feasibility study regarding the periablative efficacy and safety warrant further research with a larger study population in order to gain a better understanding of the possible adverse effects.

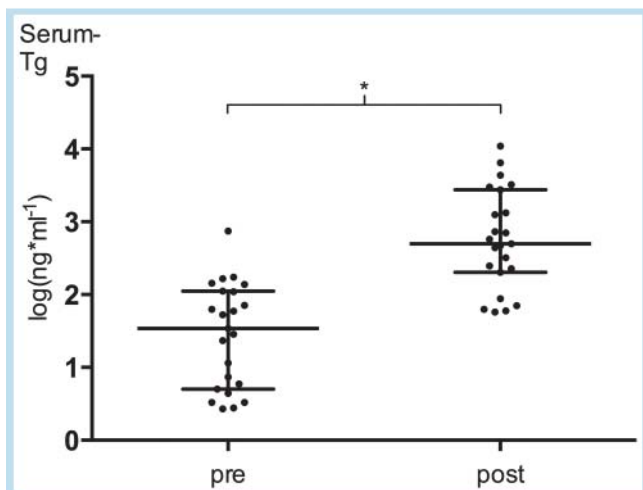


Fig. 3 Significant increase of serum Thyroglobulin (Tg)-levels ($p < 0.01$) as evidence that thyroid tissue has been destroyed.

Abb. 3 Signifikanter Anstieg der Serum Thyreoglobulin-(Tg)-Konzentration ($p < 0,01$) als Beweis dafür, dass Schilddrüsengewebe zerstört wurde.

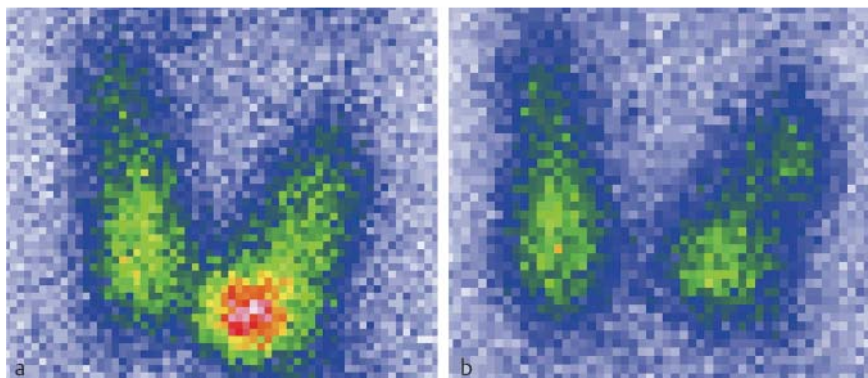


Fig. 4 Normalisation of an autonomous hyperfunctioning area in ^{99m}Tc -pertechnetate scintigraphy before **a** and after **b** bipolar radiofrequency ablation as proof of efficacy.

Abb. 4 Normalisierung einer autonomen hyperfunktionellen Zone in der ^{99m}Tc -pertechnetate-Szintigrafie vor **a** und nach **b** der bipolaren Radiofrequenzablation als Beweis der Effektivität.

Conclusion

Bipolar RFA has the potential to be a safe and effective treatment option for symptomatic benign thyroid nodules and thus deserves further refinements.

Clinical Relevance

- ▶ Bipolar RFA is an advancement of monopolar RFA and is an effective treatment option for benign thyroid nodules.
- ▶ Since bipolar RFA has no grounding pad it facilitates the preparation of the patient and eliminates the risk of skin burns
- ▶ A median pain-score of 3 ± 1.5 on a 10-point scale shows that bipolar RFA is a gentle alternative to invasive thyroid surgery.

References

- 1 Shah DR, Green S, Elliot A. Current oncologic applications of radiofrequency ablation therapies. *WJGO* 2012; 5: 71–80
- 2 Jeong WK, Baek JH, Rhim H et al. Radiofrequency ablation of benign thyroid nodules: safety and imaging follow-up in 236 patients. *Eur Radiol* 2008; 18: 1244–1250
- 3 Goldberg SN, Gazelle GS, Mueller PR. Thermal Ablation Therapy for Focal Malignancy. *Am J Roentgenol* 2000; 174: 323–331
- 4 Oyama Y, Nakamura K, Matsuoka T et al. Radiofrequency Ablated Lesion in the Normal Porcine Lung: Long-Term Follow-Up with MRI and Pathology. *Cardiovasc Intervent Radiol* 2005; 28: 346–353
- 5 Korkusuz H, Happel C, Heck K et al. Percutaneous thermal microwave ablation of thyroid nodules. *Nuklearmedizin* 2014; 53: 123–130
- 6 Shin JH, Baek JH, Ha EJ et al. Radiofrequency Ablation of Thyroid Nodules: Basic Principles and Clinical Application. *Int J Endocrinol* 2012; 2012: 1–7
- 7 Rago T, Santini F, Scutari M et al. Elastography: New Developments in Ultrasound for Predicting Malignancy in Thyroid Nodules. *J Clin Endocrinol Metab* 2007; 92: 2917–2922
- 8 Etzel M, Happel C, von Müller F et al. Palpation and elastography of thyroid nodules in comparison. *Nuklearmedizin* 2013; 52: 97–100
- 9 Klebe J, Happel C, Grünwald F et al. Visualization of tissue alterations in thyroid nodules after microwave ablation. *Nucl Med Commun* 2015; 36: 260–267
- 10 Huffman SD, Huffman NP, Lewandowski R et al. Radiofrequency Ablation Complicated by Skin Burn. *Semin Intervent Radiol* 2011; 28: 179–182
- 11 Sadoul N, Blankoff I, de Chillou C et al. Effects of radiofrequency catheter ablation on patients with permanent pacemakers. *J Interv Card Electrophysiol* 1997; 1: 227–233
- 12 Yi B, Somasundar P, Espat NJ. Novel laparoscopic bipolar radiofrequency energy technology for expedited hepatic tumour ablation. *HPB* 2009; 11: 135–139
- 13 Gurgul E, Sowiński J. Primary hyperthyroidism – diagnosis and treatment. Indications and contraindications for radioiodine therapy. *Nucl Med Rev Cent East Eur* 2011; 14: 29–32
- 14 Basu N, Dutta D, Maisnam I et al. Percutaneous ethanol ablation in managing predominantly cystic thyroid nodules: An eastern India perspective. *Indian J Endocr Metab* 2014; 18: 662–668
- 15 Korkusuz H, Sennert M, Fehre N et al. Local thyroid tissue ablation by High-Intensity Focused Ultrasound: Effects on thyroid function and first human feasibility study with hot and cold thyroid nodules. *Int J Hyperthermia* 2014; 30: 480–485
- 16 Achille G, Zizzi S, Di Stasio E et al. Ultrasound-guided percutaneous laser ablation in treating symptomatic solid benign thyroid nodules: Our experience in 45 patients. *Head Neck* 2015; DOI: 10.1002/hed.23957
- 17 Bron LP, O'Brien CJ. Total thyroidectomy for clinically benign disease of the thyroid gland. *Br J Surg* 2004; 91: 569–574
- 18 Bernardi S, Dobrinja C, Fabris B et al. Radiofrequency Ablation Compared to Surgery for the Treatment of Benign Thyroid Nodules. *Int J Endocrinol* 2014; 2014: 1–10
- 19 Nouse K, Shiraga K, Uematsu S et al. Prediction of the ablated area by the spread of microbubbles during radiofrequency ablation of hepatocellular carcinoma. *Liver International* 2005; 25: 967–972
- 20 Kim YS, Rhim H, Tae K et al. Radiofrequency ablation of benign cold thyroid nodules: initial clinical experience. *Thyroid* 2006; 16: 361–367
- 21 Van Vledder MG, Boctor EM, Assumpcao LR et al. Intra-operative ultrasound elasticity imaging for monitoring of hepatic tumour thermal ablation. *HPB* 2010; 12: 717–723