

Diagnostic Accuracy of Full-Body Linear X-Ray Scanning in Multiple Trauma Patients in Comparison to Computed Tomography

Diagnostische Genauigkeit eines Ganzkörper-Linearröntgenscanners bei Polytraumapatienten im Vergleich zur Computertomografie

Authors

A. P. W. Jöres¹, J. T. Heverhagen¹, H. Bonél¹, A. Exadaktylos², T. Klink^{1,3}

Affiliations

¹ University Institute of Diagnostic, Interventional and Pediatric Radiology, Inselspital – University Hospital Bern, Switzerland

² Department of Emergency Medicine, Inselspital – University Hospital Bern, Switzerland

³ University of Würzburg, Institute of Diagnostic and Interventional Radiology, Germany

Key words

- multiple trauma
- ATLS
- full-body X-ray
- Lodox

received 18.2.2015
accepted 7.9.2015

Bibliography

DOI <http://dx.doi.org/10.1055/s-0041-107199>
Published online: 3.11.2015
Fortschr Röntgenstr 2016; 188: 163–171 © Georg Thieme Verlag KG Stuttgart · New York · ISSN 1438-9029

Correspondence

Andreas Jöres
University Institute of Diagnostic, Interventional, and Paediatric Radiology, INSELSPITAL, Bern University Hospital Freiburgstrasse 10 3008 Bern Switzerland
Tel.: ++41/31/6 32 25 27
Fax: ++41/31/6 32 48 74
andreas.joeres@insel.ch

Zusammenfassung

Ziel: Ziel dieser Studie war die Evaluation der diagnostischen Genauigkeit eines Ganzkörper-Linearröntgenscanners (LS) bei Polytraumapatienten im Vergleich zur 128-Zeilen-Mehrschicht-Computertomografie.

Material und Methoden: 106 Polytraumapatienten (33 Frauen; 73 Männer) wurden retrospektiv in diese Studie eingeschlossen. Alle Patienten erhielten eine LS-Untersuchung des gesamten Körpers sowie ein MSCT, welches Hals, Thorax, Abdomen und Becken einschloss. Die diagnostische Genauigkeit von LS hinsichtlich der Detektion von Frakturen des Stammskeletts sowie der Detektion von Pneumothoraces wurde im Vergleich zum MSCT durch zwei Untersucher evaluiert. Extremitätenfrakturen welche durch LS detektiert wurden, wurden dokumentiert.

Ergebnisse: Insgesamt lag die Sensitivität von LS bei 49,2%, die Spezifität bei 93,3%, der positive Vorhersagewert 91% und der negative Vorhersagewert 57,5%. Die Sensitivität hinsichtlich Wirbelkörperfrakturen war 16,7% sowie die Spezifität 100%. Für alle anderen Frakturen betrug die Sensitivität 48,7% und die Spezifität 98,2%. Pneumothoraces wurden bei insgesamt 12 Patienten mittels CT detektiert – nicht jedoch durch LS. 40 Extremitätenfrakturen konnten mittels LS erkannt werden, von denen 4 Frakturen disloziert waren und lediglich 2 Frakturen vollständig durch die MSCT Untersuchung erfasst worden sind.

Schlussfolgerung: Die diagnostische Genauigkeit von LS ist in der Evaluation von Traumapatienten hinsichtlich des Stammskeletts limitiert. LS erlaubt eine zügige Ganzkörper-Röntgenuntersuchung und kann nützlich sein, um Extremitätenfrakturen in Ergänzung zum CT zu detektieren.

Kernaussagen:

- ▶ Die Gesamtsensitivität von LS für Verletzungen des Stammskeletts bei Polytraumapatienten beträgt < 50%.

Abstract

Purpose: The purpose of this study was to evaluate the diagnostic accuracy of full-body linear X-ray scanning (LS) in multiple trauma patients in comparison to 128-multislice computed tomography (MSCT).

Materials and Methods: 106 multiple trauma patients (female: 33; male: 73) were retrospectively included in this study. All patients underwent LS of the whole body, including extremities, and MSCT covering the neck, thorax, abdomen, and pelvis. The diagnostic accuracy of LS for the detection of fractures of the truncal skeleton and pneumothoraces was evaluated in comparison to MSCT by two observers in consensus. Extremity fractures detected by LS were documented.

Results: The overall sensitivity of LS was 49.2%, the specificity was 93.3%, the positive predictive value was 91%, and the negative predictive value was 57.5%. The overall sensitivity for vertebral fractures was 16.7%, and the specificity was 100%. The sensitivity was 48.7% and the specificity 98.2% for all other fractures. Pneumothoraces were detected in 12 patients by CT, but not by LS. 40 extremity fractures were detected by LS, of which 4 fractures were dislocated, and 2 were fully covered by MSCT.

Conclusion: The diagnostic accuracy of LS is limited in the evaluation of acute trauma of the truncal skeleton. LS allows fast whole-body X-ray imaging, and may be valuable for detecting extremity fractures in trauma patients in addition to MSCT.

Key Points:

- ▶ The overall sensitivity of LS for truncal skeleton injuries in multiple-trauma patients was < 50%.
- ▶ The diagnostic reference standard MSCT is the preferred and reliable imaging modality.
- ▶ LS may be valuable for quick detection of extremity fractures.

- ▶ Daher ist der diagnostische Referenzstandard MSCT als verlässlicheres bildgebendes Verfahren vorzuziehen.
- ▶ LS kann ergänzend für die schnelle Detektion von Extremitätenfrakturen sinnvoll sein.

Citation Format:

- ▶ Jöres APW., Heverhagen JT, Bonél H et al. Diagnostic Accuracy of Full-Body Linear X-Ray Scanning in Multiple Trauma Patients in Comparison to Computed Tomography. Fortschr Röntgenstr 2016; 188: 163–171

Introduction

Fast and accurate diagnosis of potentially lethal injuries is mandatory in multiple-trauma patients. Standard advanced trauma life support (ATLS) diagnostic workup algorithms include several imaging steps with different modalities, particularly conventional radiography, sonography, and computed tomography. Our emergency department has decided to replace conventional radiography with full-body linear X-ray scanning (LS). This modified ATLS algorithm has been introduced [1] (▶ Fig. 2) and includes an ultrasound (Focused Assessment with Sonography in Trauma, FAST) and an LS whole-body scan during the primary survey, and subsequent multi-slice computed tomography (MSCT) of the head, neck, thorax and abdomen, when US or LS reveals pathologic findings, or when the clinical suspicion for severe injuries persists without pathologic findings on primary imaging. Previous studies have shown that replacement of conventional radiography with LS significantly reduced the primary imaging time from 25.7 to 3.5 minutes. Furthermore, LS has been shown to be comparable to the diagnostic accuracy of conventional radiography in several studies [2, 3].

LS is performed using the “Lodox Statscan” X-ray machine (Statscan Critical Imaging System, Lodox Systems [Pty] Ltd, Johannesburg, South Africa) (▶ Fig. 1). The Lodox Statscan has been approved for diagnostic digital X-ray imaging by the Food and Drug Administration (FDA) since 2002 and by the European Union since 2004. In our emergency department, LS is immediately available in the emergency/trauma room and provides a full-body a./p. and lateral view based on linear slot scan technology. According to the manufacturer’s information, 33 trauma centers worldwide are currently using this technology. LS may be utilized for skeletal and chest X-ray imaging and applies less radiation than conventional acquisitions [4, 5]. LS has been tested in a wide range of possible applications. LS is used in polytrauma patients [1, 2, 4–8], for identifying body packers/body stuffers [9], for evaluating gunshot injuries, for measuring distortion of skeletal elements [10], for visualization of ventriculoperitoneal shunt dysfunction [11], for evaluation of bone dysplasia, for cephalometry, for spinal shape assessment, and for postmortem examinations at forensic laboratories [12].

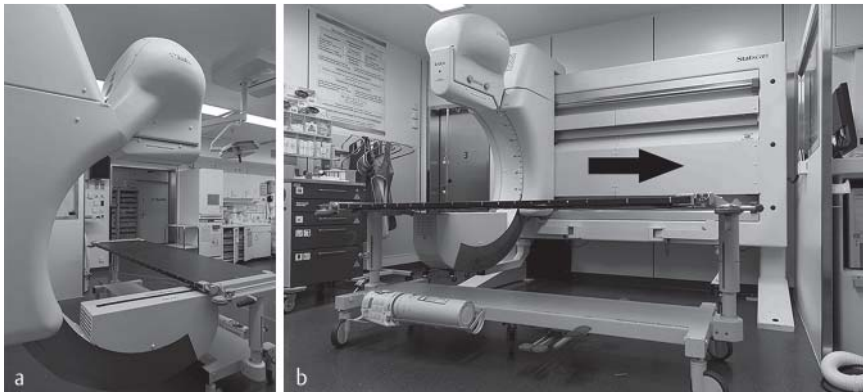


Fig. 1 Lodox Statscan in the emergency department. **a** shows the C-arm with the rotating anode X-ray tube above and the X-ray detector unit under the table. **b** shows the carbon fiber table of LS with the Statscan operator console on the right side. The arrow indicates the scanning direction of the C-arm.

Abb. 1 Lodox-Statscan im Schockraum. **a** zeigt den C-Arm mit der Röntgenröhre oberhalb und dem Röntgendetektor unter dem Tisch. **b** zeigt den Karbonfasertisch mit der Statscan-Bedienkonsole auf der rechten Seite. Der Pfeil gibt die Scanrichtung des C-Arms an.

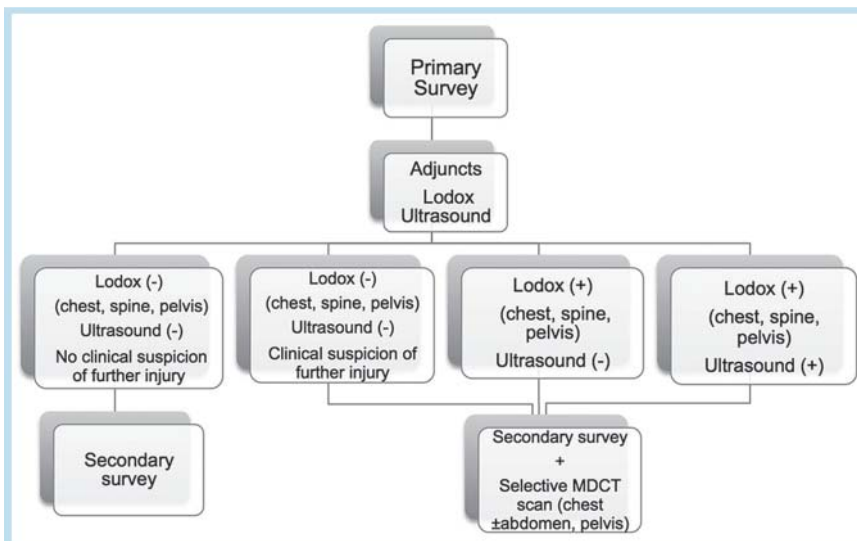


Fig. 2 Modified ATLS protocol with the integration of LS. Modified as described in [1].

Abb. 2 Modifiziertes ATLS-Protokoll mit der Integration von LS. Modifiziert nach: [1].

The purpose of our study was to evaluate the diagnostic accuracy and the clinical value of full-body linear X-ray scanning (LS) as part of the modified ATLS protocol in multiple-trauma patients in comparison to the diagnostic reference standard MSCT. We also assessed the applicability of LS for detecting extremity fractures, which were not included in the CT scan volume. Moreover, LS was compared to CT topogram as a potential, further time-sparing substitute. Finally, the time delay between the LS scan and MSCT was evaluated.

Materials and methods



Subjects

Following institutional review board approval, 106 consecutive patients (female: 33; male: 73; mean age: 46.7 years; age range: 16–93) were retrospectively included in this study.

The criteria for inclusion were: They had to be multiple-trauma patients with a diagnostic workup according to the previously described, modified ATLS protocol during the year 2012 including a whole-body LS scan and an MSCT scan covering the neck, thorax, abdomen and pelvis.

Patient data were retrieved from the radiology information system (RIS) and Picture Archiving and Communication System (PACS).

Linear slot X-ray scanning (LS)

All patients underwent linear slot X-ray scanning (LS; Statscan Critical Imaging System, Lodox Systems [Pty] Ltd. Johannesburg, South Africa) of the whole body, including the extremities and multi-slice computed tomography covering the neck, thorax, abdomen and pelvis, but not the extremities.

The Statscan X-ray machine uses a rotating anode X-ray tube that is mounted on a C-arm. An X-ray detector unit (scintillator array) is fixed on the other end of the C-arm. The spatial resolution can be selected from 1.04 up to 5.0 line pairs/mm [13]. The C-arm is rotated axially around the patient for scanning at different angles. The C-arm's longitudinal motion speed is from 35 to 140 mm/s. Due to slit scanning technology, which collimates the X-ray beam to 0.4 mm, LS is able to stand free in the resuscitation room. The scan time of LS is less than 13 s for the whole body and the diagnostic image is available for viewing in less than 15 s after the end of the scan [14]. The unit includes a carbon fiber table to eliminate transfers from and to the trolley that would otherwise be necessary. The instantaneous exposure time with LS is 22 ms, so that, although high mA values are used, low patient exposure can be realized. For LS imaging, the patient is in a supine position and the C-arm can rotate around the patient to achieve additional views if required (e. g. lateral views).

Multislice Computed Tomography (MSCT)

Multislice computed tomography was performed using a 128-slice CT scanner (Somatom Definition Edge, Siemens Medical, Erlangen, Germany). The tube current of the p./a. and/or lateral CT topogram was 100 kV, with a fixed tube current exposure time of 35 mAs. Raw data acquisition was performed with a collimation of 128 × 0.6 mm and a tube current of 120 kV (for thorax, abdomen and pelvis). All CT scans were performed using tube current modulation (CARE Dose 4D™) with a pre-set range of 100–500 mAs. Images were first reconstructed in axial planes using soft tissue and bone kernels at slice thicknesses of 3 mm and 1 mm, respectively. Multiplanar reconstructions (MPR) in sa-

gittal and coronal planes were performed in all patients as part of our standard procedure. The images were reconstructed with a soft tissue kernel at a slice thickness and increment of 5 mm. Moreover, images were reconstructed with a bone kernel (170 f kernel) at a slice thickness and increment of 1 mm. All patients received 120 ml Iomeron® 400 i.v. in the split-bolus technique [15]. The first bolus consisted of 60 ml contrast medium with a flow rate of 4 ml/s, followed by 20 ml saline at a flow rate of 1 ml/s. The second bolus consisted of 60 ml contrast medium with a flow rate of 3.5 ml/s, followed by 20 ml saline injection at a flow rate of 3.5 ml/s.

Image Evaluation

All images were reviewed on a workstation with a high luminance 3 MP, 21.3" color display for diagnostic imaging (TOTOKU CCL 254i2) using the Picture Archiving and Communication System (PACS, IDS 5, Sectra AB, Sweden).

All LS images were evaluated in consensus by two board certified radiologists. The evaluation criteria are presented below. Both observers were blinded to all clinical information and CT images. After completing the evaluation of LS images, all CT topograms were analyzed. Finally, CT reports, which had been generated in a double reading by a resident and a board certified radiologist, were reviewed in the RIS for documentation of all injuries and fractures. CT imaging was considered the diagnostic reference standard to which LS images and the CT topogram were compared.

For LS, CT topogram and CT images, the following data were recorded:

► Chest evaluation criteria

- Presence (yes/no) and dislocation (yes/no) of rib fractures and detection of multiple rib fractures (yes/no)
- Presence (yes/no) of fractures of the clavicle, sternum and scapula
- Presence (yes/no) of pneumothorax, pleural effusion, widening of the mediastinum, and infiltrates

► Abdomen evaluation criteria

- Presence of pneumoperitoneum (yes/no)

► Pelvis evaluation criteria

- Presence of fracture of symphysis, anterior and posterior ring, acetabulum, hip joint, proximal femur (yes/no)

► Spine evaluation criteria

- Presence of fractures of the spine and whether the fracture involved the rear edge of the vertebral body (yes/no)

► Extremity fractures

- Detected extremity fractures by LS (yes/no) and displacement of these fractures

For our analysis of the time span between both imaging modalities, we compared the time stamp of the last acquired LS image with the time stamp of the CT topogram.

After analyzing the LS images, CT topogram, and CT images, a second reading was performed. CT scans of all patients with extremity fractures, which were detected using LS, were reviewed. Whenever an extremity fracture was detected on LS images, it was recorded whether this fracture was completely covered by MSCT (complete/incomplete).

Furthermore, LS images of all patients with a pneumothorax detected on CT images were reassessed. The observers documented, whether pneumothoraces could be detected using LS in awareness of the CT diagnosis. The width of the pneumothorax was noted, and whether the pneumothorax was treated with chest tube drainage.

Table 1 Non-skeletal injuries in our multiple-trauma patient collective that are not directly assessable using the LS technique.

Tab. 1 Nicht-skeletale Verletzungen in unserem Patientenkollektiv, die mittels LS-Technik nicht direkt erfasst werden können.

type of injury	n
aortic rupture	1
active arterial bleeding	4
liver laceration	3
spleen laceration	5
renal contusion	2
dissection of renal artery	1
hematoma (without active bleeding)	5

Finally, for all spine fractures detected by MSCT, the readers documented, whether the fracture needed surgical treatment. All potentially life-threatening injuries, which were technically non-detectable using LS but documented using CT (e. g. organ lacerations, bleeding), were recorded separately (► **Table 1**).

Statistical Analysis

First, we assessed the diagnostic accuracy of LS. The sensitivity, specificity, positive and negative predictive values of LS were calculated in comparison to the reference standard MSCT. Second, the diagnostic accuracy of the CT topogram was calculated similarly to the LS scans. Results were compared to test for a potential replacement of LS by CT topogram. Injuries were grouped as described under "Image evaluation criteria". Each injury detected on the LS image was compared to the corresponding MSCT scan. The time delay between the LS scan and the MSCT scan was calculated using the time stamps on LS images and CT topogram.

Results

The different trauma mechanisms of all 106 included patients are given in ► **Table 2**. None of the patients had to be excluded.

Projection and acquisition numbers

The number of LS views was not identical for each of the included patients. 76 patients received an a./p. view, 28 patients an a./p. and lateral view and 2 patients a lateral view only.

In 106 patients, 6 patients received a CT topogram of the whole spine in a lateral view and 9 patients received a CT topogram of the whole spine in a./p. view. 28 patients received a CT topogram of the whole spine in an a./p. and a lateral view. 63 patients received a lateral CT topogram of the cervical spine and an a./p. view of the thoracic and lumbar spine.

Diagnostic accuracy of LS in comparison to MSCT

The overall sensitivity of LS in comparison to MSCT was 49.2%, the specificity was 93.3%, the positive predictive value was 91%, and the negative predictive value was 57.5%. The overall and subgroup results are presented in detail in ► **Table 3**.

Chest evaluation

Rib fractures were the most common type of chest injury in our collective. Rib fractures were found in 37 of 212 hemithoraces (in 106 patients). LS rendered a sensitivity of 37.8% and a specificity of 98.3%. Multiple rib fractures were detected in 23 of 212 (10.8%) hemithoraces by MSCT and in 10 (4.7%) by LS.

Table 2 Overview of trauma mechanisms.

Tab. 2 Übersicht über die Traumamechanismen.

trauma mechanism	n
motor vehicle accident (MHA)	49
fall	32
other	21
attempted suicide	4
total	106

Table 3 Sensitivity, specificity, positive and negative predictive value of Lodox (LS) compared to MSCT.

Tab. 3 Sensitivität, Spezifität, positiver und negativer Vorhersagewert von Lodox (LS) im Vergleich zu MSCT.

	sensitivity	specificity	PPV	NPV	RP	FP	RN	FN
whole body without extremities	43.8 %	95.2 %	93.3 %	52.6 %	28	2	40	36
subgroup analysis								
chest ¹	50.0 %	97.1 %	90.0 %	79.1 %	18	2	68	18
abdomen ²	n/a	100.0 %	n/a	100.0 %	0	0	106	0
pelvis ³	44.4 %	100.0 %	100.0 %	95.1 %	4	0	97	5
spine ⁴	13.5 %	100.0 %	100.0 %	68.3 %	5	0	69	32

PPV = positive predictive value / NPV = negative predictive value / TP = right positive / FP = false positive / TN = right negative / FN = false negative.

¹ Chest evaluation criteria: fractures of ribs, clavicle, sternum, scapula, pneumothorax, pleural effusion, mediastinal widening, pulmonary consolidation.

² Abdomen evaluation criteria: pneumoperitoneum.

³ Pelvis evaluation criteria: fractures of symphysis, anterior and posterior ring, acetabulum, hip joint, proximal femur.

⁴ Spine evaluation criteria: fractures, alignment injury.

8 patients had single-sided pneumothorax, and 2 had bilateral pneumothoraces. 3 pneumothoraces were wider than 3 cm, 9 pneumothoraces were smaller than 3 cm. None of the pneumothoraces could be detected using LS during the first reading, but 2 after another reading in awareness of the CT diagnosis. Overall 6 pneumothoraces were treated with chest tube drainage.

LS displayed the following further chest findings: clavicle fractures in 5 patients (right side: 2 patients/left side: 3 patients), hip fracture in 1 patient, scapula fractures in 2 patients, and sternum fracture in 1 patient. Pulmonary consolidations were found in 3 patients and pleural effusion in 1 patient.

Pelvic evaluation

Nine patients had pelvis fractures detected on MSCT images. Four pelvis fractures could be detected with LS. The anterior ring was fractured in 2 patients, the posterior ring in 1 patient, and the acetabulum in 1 patient.

Spine evaluation

In 36 patients, spine fractures were diagnosed using MSCT. In all patients with a spine fracture, 28 received an a. p. view only, 7 patients an a. p. and lateral view and 1 patient received a lateral view only. 15 of these patients required surgical therapy. Spine fractures occurred in the following locations and with the following frequency:

- Cervical spine: C1 (1x), C5 (5x), C6 (2x), C7 (4x).
- Thoracic spine: Th3 (2x), Th4 (1x), Th5 (2x), Th6 (3x), Th7 (2x), Th8 (1x), Th9 (1x), Th10 (2x), Th11 (3x).
- Lumbar spine: L1 (10x), L2 (11x), L3 (11x), L4 (6x), L5 (3x).

In 5 patients, 9 spine fractures could be detected using LS in the following vertebral segments C7 (1x), Th 12 (2x), L1 (2x), L2 (1x), and L3 (3x). In these patients, a. p. views were obtained in 3 patients, and a. p. and lateral views in 2 patients. 3 patients required surgical therapy for vertebral stabilization.

Diagnostic accuracy of CT topograms in comparison to MSCT for all fractures and injuries

The overall sensitivity of the CT topograms in comparison to MSCT was 23%, the specificity was 100%, the positive predictive value was 100%, and the negative predictive value was 49%.

CT topogram of the chest revealed 2 fractures of the clavicle, 2 fractures of the scapula, 2 patients with serial rib fractures, and pulmonary consolidation in 1 patient. None of the pneumothoraces were detected on CT topogram.

CT topogram of the abdomen and pelvis revealed one hip fracture and one anterior pelvic ring fracture.

2 fractures of the cervical spine and 3 fractures of the lumbar spine could be detected on CT topogram.

Detection of extremity fractures

30 of 106 patients presented with extremity fractures. Overall, 40 fractures were detected – 6 patients with upper extremity fractures (4 left/2 right), 34 patients with lower extremity fractures (14 left/20 right). 27 fractures were dislocated. Only 2 of these fractures – 1 fracture of the right arm and 1 fracture of the left leg – were fully covered by MSCT due to an extended CT scan (• Fig. 3).

Time delay between LS and MSCT

The minimum time span between LS and MSCT was 10 minutes, the maximum time span was 1 hour 46 minutes and the average time span was 37 minutes (25th percentile, 23 minutes/75th percentile, 49 minutes). During the 12-month retrospective analysis period, the mean time span between the two imaging modalities could be reduced from 55 to 25 minutes (• Fig. 6).

Documentation of thoraco-abdominal injuries which are not directly detectable on LS images

21 visceral injuries were detected in 106 patients using MSCT (• Table 1).

One patient presented with occult rupture of the thoracic aorta distally to the left subclavian artery origin. LS revealed bilateral serial rib fractures, pleural effusions and pneumothoraces.

Visceral injuries of the lungs, such as alveolar hemorrhage or pneumothorax, were potentially visible on LS images, and thus not included in • Table 1. The remaining 20 visceral injuries were detected in the abdomen and included particularly organ lacerations and bleeding.

Discussion



In our study of 106 multiple trauma patients, 2 observers performed 49.2% sensitivity and 93.3% specificity for LS imaging in the detection of truncal skeleton injuries in comparison to the diagnostic reference standard MSCT. These figures are comparable to that of conventional radiography in emergency settings [16].

The low sensitivity of LS for detecting injuries of the truncal skeleton in multiple-trauma patients limits its application in emergency settings, and leads to the discussion, whether LS can provide adequate diagnostic value. The high specificity, which would allow for quick clearing-off in the emergency room, is not reliable due to high false-negative numbers. Thus, LS may better fulfil the role of screening tool for the detection of extremity fractures as image acquisition had been shown to require significantly less time than conventional radiography [17]. Thus, LS may be implemented during the primary survey, when it can be performed without significant time delay to the subsequent CT scan. In our experience, LS can be performed almost simultaneously to FAST ultrasound. Alternatively, or under potentially unstable conditions, the patient should go straight to the CT scan. In situations with mass casualties, LS enhances the capacity of a trauma unit [18]. Moreover, LS has been proven to have diagnostic value in poorly equipped hospitals [18].

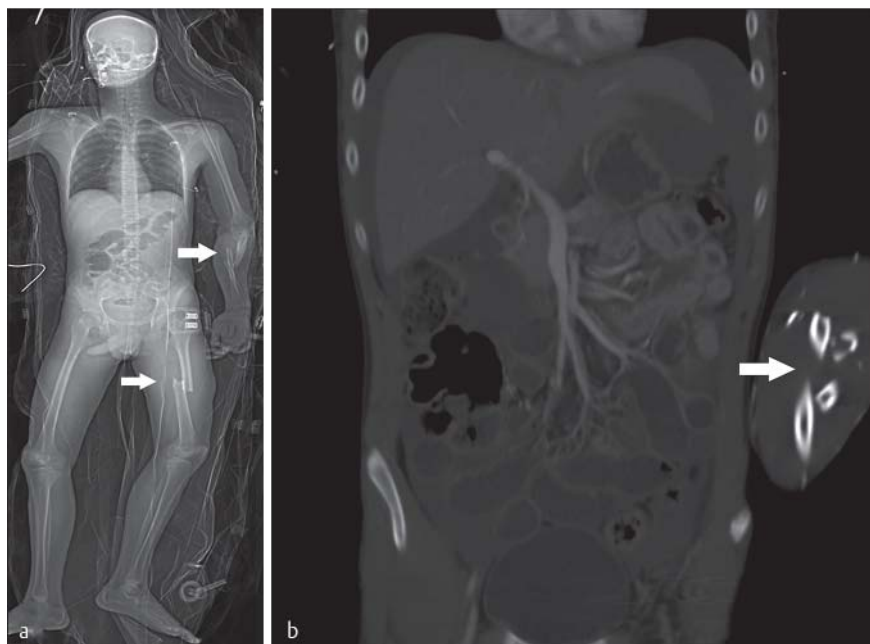


Fig. 3 LS-scan of a 19-year-old man after a motor vehicle accident and resuscitation **a**. While the whole-body scan with LS covered the dislocated fracture of the left thigh as well as the dislocated fracture of the left forearm (indicated by arrows) **a**, the CT scan only covered the left forearm fracture (indicated by arrow) (**b**; CT, coronal reformation).

Abb. 3 LS-Scan eines 19-jährigen Mannes nach einem Verkehrsunfall mit anschließender Reanimation **a**. Während der Ganzkörper-Scan mittels LS sowohl die dislozierte Fraktur des linken Oberschenkels, als auch die dislozierte Fraktur des linken Unterarms abdeckte (markiert mittels Pfeil) **a**, deckte der CT-Scan lediglich die Fraktur des linken Unterarms ab (markiert mittels Pfeil) (**b**, CT, coronare Rekonstruktion).

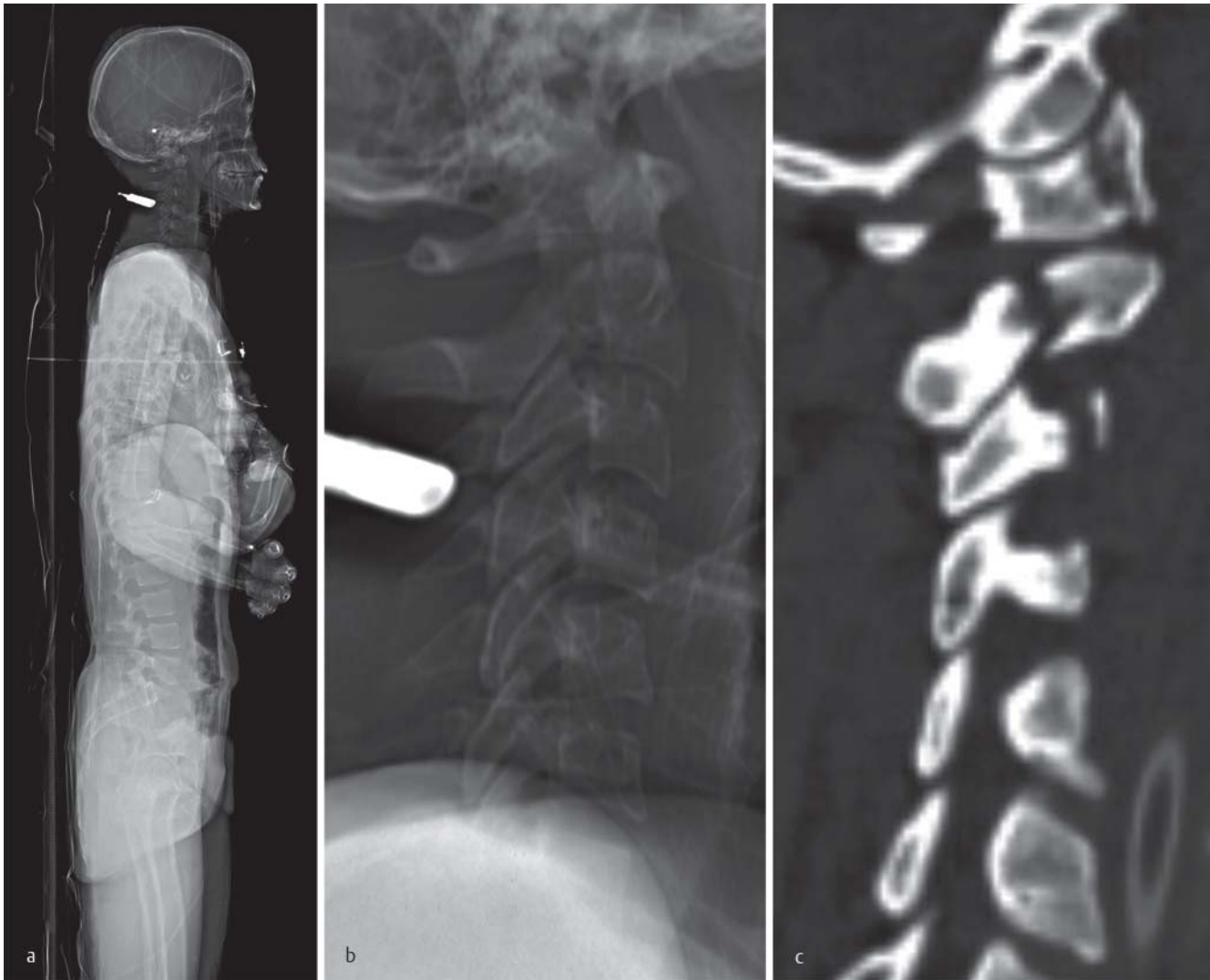

Fig. 4 A 23-year-old woman presented with multiple fractures of the cervical spine after falling. **a** shows the lateral Lodox Statscan view and its enlargement of the cervical spine. **b** shows an anteriorly dislocated fracture of the second vertebra and a widening of the prevertebral soft tissue. The sagittal reformation of the CT scan shows fractures of the first to third cervical vertebra (**c**). Moreover, the CT scan revealed a fracture of the atlas, a hangman's fracture of the second cervical vertebra, a fracture of the arcus vertebrae of the fifth and sixth cervical vertebra, and a fracture of the transverse process of the seventh cervical vertebra.

Abb. 4 Eine 23-jährige Patientin stellte sich nach einem Sturz mit zahlreichen Frakturen der HWS vor. **a** zeigt die laterale LS-Aufnahme und **b** die entsprechende Ausschnittsvergrößerung, auf der eine nach anteriore dislozierte Fraktur des HWK 2 sowie eine Verbreiterung der prävertebralen Weichteile zu erkennen ist. Die sagittale Rekonstruktion des CT-Datensatzes stellt die Frakturen des ersten bis dritten HWK dar **c**. Darüberhinaus konnten mittels CT eine Fraktur des Atlas, eine Hangman-Fraktur, eine Fraktur des Arcus vertebrae von HWK 5 und 6 sowie eine Fraktur des Processus transversus von HWK 7 detektiert werden.

LS was strongly limited in the diagnosis of pneumothoraces. Even during a second reading in awareness of the CT findings, only two of the particularly small and anterior pneumothoraces were detectable. In the study of Chen et al., 5 of 24 pneumothoraces were missed by LS [19]. It is well known that pneumothoraces are frequently missed on conventional X-ray images [20] – particularly when the patient is in a supine position [21]. For compensation of this limitation, e-FAST is routinely performed during the primary survey. E-FAST is fast and allows for accurate detection of pneumothoraces [22].

Diagnostic accuracy of LS was very low for the detection of vertebral fractures (• Fig. 4). The sensitivity of LS was only 16.7% in comparison to MSCT. Spinal fractures were detected in only 5 of 36 patients. 15 of these 36 patients had fractures requiring spine surgery, of which LS could only detect 3. The limited sensitivity

was due to predominantly non-dislocated fractures and fractures of the processus spinosi and/or processus transversi which could not be detected with LS. It also has to be noted that the detection rate of vertebral fractures can potentially be improved with the acquisition of sagittal LS views. As noticed in previous studies, a drawback of LS seems to be the bad visualization of the cervicothoracic junction because of the superimposed soft tissue of the shoulder girdle. One example of a patient with multiple fractures of the cervical spine where superimposition and patient positioning play a critical role is given in • Fig. 4. An example regarding limitations of LS and CT topogram for the detection of spinal fractures is given in • Fig. 7.

In a retrospective study, Chen RJ et al. compared the diagnostic accuracy of LS to CT in a study of 184 patients with multiple injuries. 7 cervical spine fractures and 24 thoracolumbar-spine inju-

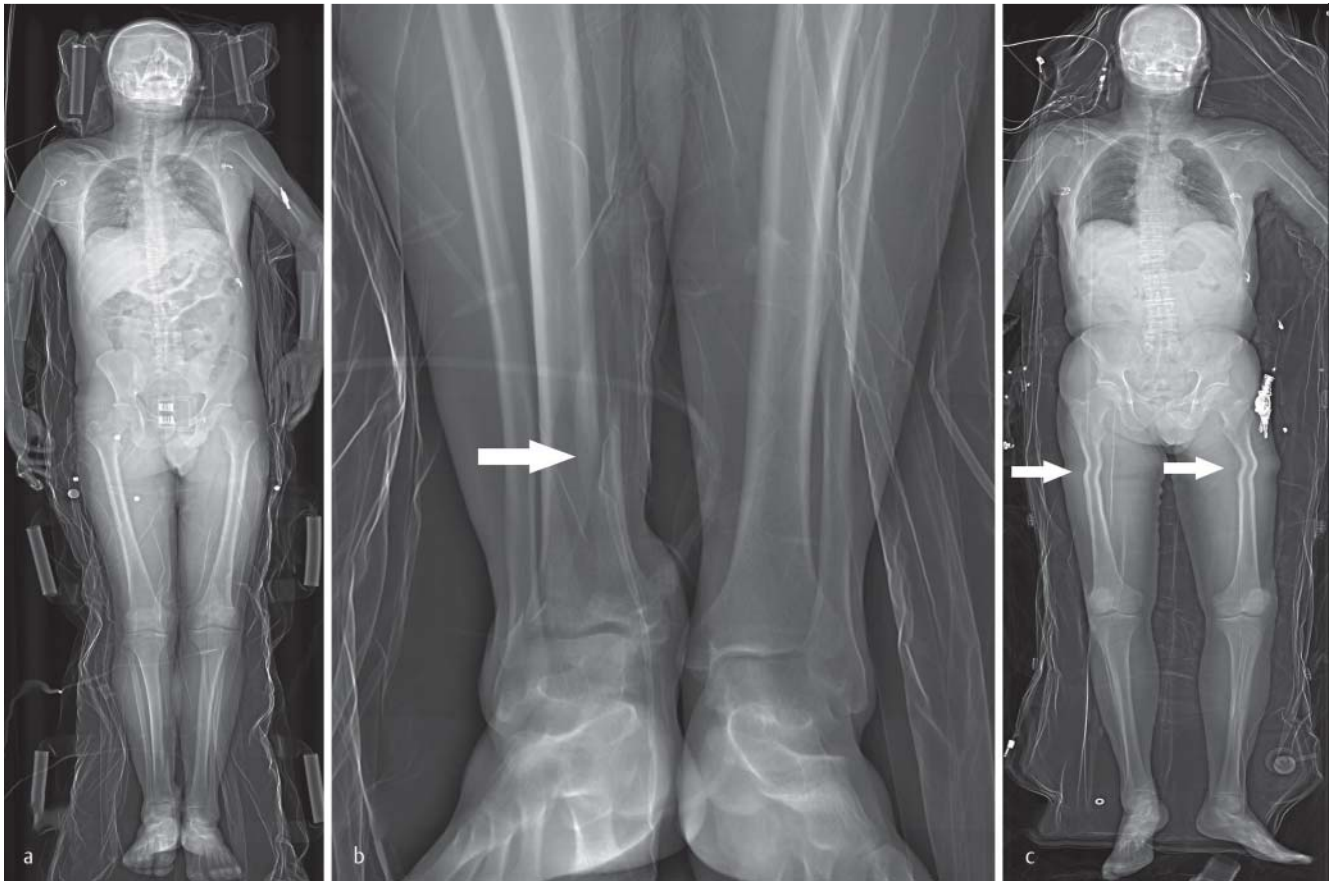

Fig. 5 a and b show a 40-year-old man after a fall from a height of 5 meters, presenting with a dislocated fracture of the right distal tibia (arrow; b, image enlargement of a). c: 74-year-old patient who was struck by a lorry while riding on his bike. Image quality may be impaired due to overlay – as in this case – due to the vacuum mattress or due to distortion (arrow in c).

Abb. 5 a und b zeigen einen 40-Jahre-alten Mann nach einem Sturz aus einer Höhe von 5 m mit einer dislozierten Fraktur der rechten distalen Tibia (Pfeil; b, vergrößerter Ausschnitt von a). c – 74-Jahre-alter Patient, welcher als Fahrradfahrer von einem LKW erfasst wurde. Die Bildqualität kann aufgrund von Überlagerungen – wie in diesem Fall – durch Vakuummatratze oder Verzerrungen (Pfeil, c) eingeschränkt sein.

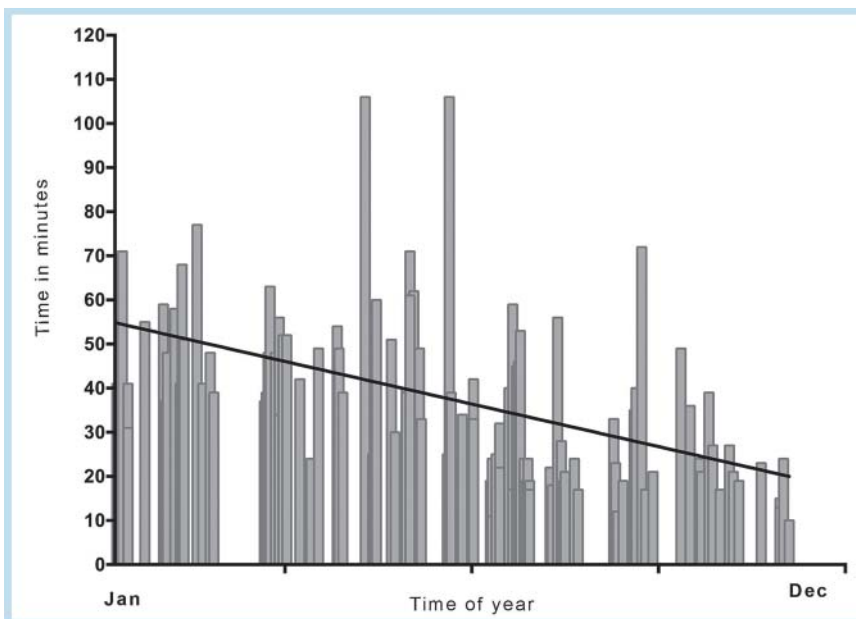


Fig. 6 Improvement of time interval between the LS examination and the MSCT scan during the selected year.

Abb. 6 Verbesserung des zeitlichen Intervalls zwischen der LS-Aufnahme und dem MSCT-Scan während des evaluierten Jahres.

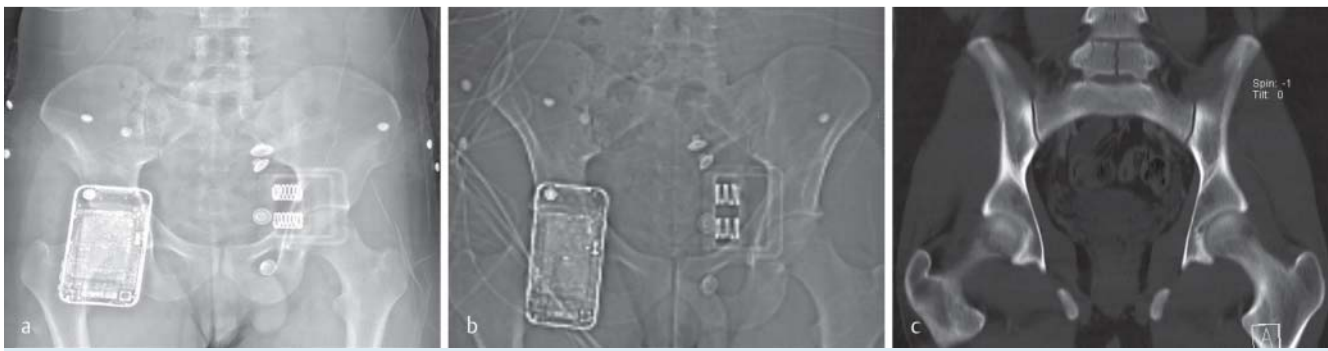

Fig. 7 23-year-old man who was involved in a motor vehicle accident. In LS **a** and CT topogram **b** the split fracture of the 5th lumbar vertebra is not visible. The coronal reformation **c** of the MSCT data clearly shows the fracture.

Abb. 7 zeigt einen 23-jährigen Mann, der in einem Verkehrsunfall involviert war. In LS **a** und im CT-Topogramm **b** ist die Split-Fraktur des fünften Lumbalwirbels nicht erkennbar. Die coronare Reformatierung **c** des MSCT zeigt deutlich die vorhandene Fraktur.

ries were detected by MSCT, of which 4 cervical spine and 20 thoracolumbar spine injuries were already treated after LS [19]. MSCT is performed at our institution for demonstrating the exact fracture extent and for preoperative planning.

In a recently published review with 256 included articles, LS demonstrated sensitivities ranging from 62% to 73%, and specificities ranging from 99% to 100% compared to CT in the evaluation of multiple trauma patients [16]. The authors reported conflicts of interest for several of the included and reviewed studies, giving a potential explanation for the lower diagnostic accuracy observed in our analysis.

LS revealed 40 extremity fractures. Only 2 of these fractures were fully covered by MSCT. Positioning the patient with the whole body in the scan volume is critical. As demonstrated in **Fig. 3**, the right arm of the patient is located outside the scan field, so that possible extremity fractures could be missed. Moreover, it can be noted that the positioning of the extremities is not strictly in the a. p. plane, which may hamper the assessment of fractures of the peripheral skeleton. We consider the rapid image acquisition and the significantly lower dose of a single or double-view LS scan in comparison to several conventional radiographies a major and potentially advantageous strength of this technique.

The diagnostic accuracy of CT topogram was lower than LS. A probable cause was the much lower resolution of CT topogram than of LS. Lateral CT topograms can be helpful in the detection of spine fractures [23]. Despite the fact that the reported figures of the diagnostic accuracy of CT topograms significantly vary [23, 24], we do not see a diagnostic value and cannot recommend the substitution of LS with CT topogram.

The average time span between performing LS and the MSCT examinations was 37 minutes (minimum: 10 minutes, maximum: 1 hour 46 minutes). This time span significantly decreased over the selected year (**Fig. 6**) – probably due to improved cooperation within the well-rehearsed, interdisciplinary trauma team. The large discrepancy in time between performing LS/MSCT is due to the fact that treatment was necessary already within the trauma room in some patients (e.g. unstable patients, patients with severe dyspnea and detected pneumothorax during e-FAST).

In our study, 21 potentially life-threatening injuries could be detected with MSCT, which are technically not assessable using LS (**Table 1**). During the diagnostic ATLS workup, clinical examination and history of the patient in addition to ultrasound imaging can lead to the suspicion of visceral or vascular injuries, which should have diagnostic priority. It is accepted that MSCT is the

gold standard for multiple trauma patients [24, 25]. However, there is limited data on the improvement of patient outcome when using body MSCT in multiple trauma patients.

In our study we listed non-skeletal injuries in our multiple-trauma patient collective, which are not detectable using LS in **Table 1**. Most of the injuries can be suspected with the help of ultrasound and clinical suspicion depending on trauma mechanism. Besides the injury of the thoracic aorta, all other injuries were abdominal injuries, some of which can be detected with the help of ultrasound. In emergency settings, image quality may be impaired due to overlay of external material, e.g. in immobilized patients on a vacuum mattress or due to distortion of images (**Fig. 5**).

Our study has the following limitations: Retrospectively, we were not able to recover the effective dose of the LS scans. The entrance dose for full-body anterior/posterior is 0.2 mGy and full spine lateral is 0.75 mGy [13]. Wedegärtner et al. [26] analyzed the effective dose applied to multiple trauma patients. Conventional X-ray imaging resulted in mean effective doses of 2 mSv, and MSCT of the whole body in approximately 20 mSv. The effective dose can change dramatically depending on the scan protocol and the MSCT scanner [27].

Conclusions

In multiple-trauma patients LS has a limited diagnostic accuracy regarding injuries of the truncal skeleton in comparison to the diagnostic reference standard MSCT. LS may be valuable for the quick detection of extremity fractures in emergency patients during the primary survey and functions – together with FAST ultrasound – as a complimentary imaging modality to CT.

References

- 1 Evangelopoulos DS, Deyle S, Zimmermann H et al. Personal experience with whole-body, low-dosage, digital X-ray scanning (LODOX-Statscan) in trauma. *Scandinavian journal of trauma, resuscitation and emergency medicine* 2009; 17: 41
- 2 Exadaktylos AK, Benneker LM, Jeger V et al. Total-body digital X-ray in trauma. An experience report on the first operational full body scanner in Europe and its possible role in ATLS. *Injury* 2008; 39: 525–529
- 3 McKenney KL, Nunez DB Jr, McKenney MG et al. Sonography as the primary screening technique for blunt abdominal trauma: experience with 899 patients. *American journal of roentgenology* 1998; 170: 979–985

- 4 Deyle S, Wagner A, Benneker LM et al. Could full-body digital X-ray (LODOX-Statscan) screening in trauma challenge conventional radiography? *The Journal of trauma* 2009; 66: 418–422
- 5 Pitcher RD, Wilde JC, Douglas TS et al. The use of the Statscan digital X-ray unit in paediatric polytrauma. *Pediatric radiology* 2009; 39: 433–437
- 6 Boffard KD, Goosen J, Plani F et al. The use of low dosage X-ray (Lodox/Statscan) in major trauma: comparison between low dose X-ray and conventional x-ray techniques. *The Journal of trauma* 2006; 60: 1175–1181; discussion 81–3
- 7 Mulligan ME, Flye CW. Initial experience with Lodox Statscan imaging system for detecting injuries of the pelvis and appendicular skeleton. *Emergency radiology* 2006; 13: 129–133
- 8 Pitcher RD, van As AB, Sanders V et al. A pilot study evaluating the "STATSCAN" digital X-ray machine in paediatric polytrauma. *Emergency radiology* 2008; 15: 35–42
- 9 Flach PM, Ross SG, Ampanozi G et al. "Drug mules" as a radiological challenge: sensitivity and specificity in identifying internal cocaine in body packers, body pushers and body stuffers by computed tomography, plain radiography and Lodox. *European journal of radiology* 2012; 81: 2518–2526
- 10 Stull KE, L'Abbe EN, Steiner S. Measuring distortion of skeletal elements in Lodox Statscan-generated images. *Clinical anatomy* 2013; 26: 780–786
- 11 Schaller BB, Exadaktylos AK, Andres RH et al. A new full body low-dose x-ray technique is an alternative to conventional "shunt series" in patients with ventriculoperitoneal shunt dysfunction. *The American journal of emergency medicine* 2007; 25: 702–703
- 12 Nobel GJ, Flash G, Bowie GF. Lodox Statscan proves to be invaluable in forensic medicine. *South African medical journal = Suid-Afrikaanse tydskrif vir geneeskunde* 2006; 96: 593–594, 596
- 13 Irving BJ, Maree CJ, Hering ER et al. Radiation dose from a linear slit scanning X-ray machine with full-body imaging capabilities. *Radiation protection dosimetry* 2008; 130: 482–489
- 14 Lodox Systems – Statscan critical imaging system -Product Specifications and Physical Dimensions; 2006, Lodox, technical report.
- 15 Loupatatzis C, Schindera S, Gralla J et al. Whole-body computed tomography for multiple traumas using a triphasic injection protocol. *European radiology* 2008; 18: 1206–1214
- 16 Yang L, Ye L, Ding J et al. Use of a full-body digital X-ray imaging system in acute medical emergencies: a systematic review. *Emergency medicine journal: EMJ* 2014
- 17 Evangelopoulos DS, von Tobel M, Cholewa D et al. Impact of Lodox Statscan on radiation dose and screening time in paediatric trauma patients. *European journal of pediatric surgery: official journal of Austrian Association of Pediatric Surgery [et al] = Zeitschrift für Kinderchirurgie* 2010; 20: 382–386
- 18 Whiley SP, Alves H, Grace S. Full-body x-ray imaging to facilitate triage: a potential aid in high-volume emergency departments. *Emergency medicine international* 2013; 2013: 437078
- 19 Chen RJ, Fu CY, Wu SC et al. Diagnostic accuracy, biohazard safety, and cost effectiveness—the Lodox/Statscan provides a beneficial alternative for the primary evaluation of patients with multiple injuries. *The Journal of trauma* 2010; 69: 826–830
- 20 Lamb AD, Qadan M, Gray AJ. Detection of occult pneumothoraces in the significantly injured adult with blunt trauma. *Eur J Emerg Med* 2007; 14: 65–67
- 21 Omar HR, Abdelmalak H, Mangar D et al. Occult pneumothorax, revisited. *Journal of trauma management & outcomes* 2010; 4: 12
- 22 Ianniello S, Di Giacomo V, Sessa B et al. First-line sonographic diagnosis of pneumothorax in major trauma: accuracy of e-FAST and comparison with multidetector computed tomography. *La Radiologia medica* 2014
- 23 Samelson EJ, Christiansen BA, Demissie S et al. Reliability of vertebral fracture assessment using multidetector CT lateral scout views: the Framingham Osteoporosis Study. *Osteoporosis international: a journal established as result of cooperation between the European Foundation for Osteoporosis and the National Osteoporosis Foundation of the USA* 2011; 22: 1123–1131
- 24 Huber-Wagner S, Lefering R, Qvick LM et al. Effect of whole-body CT during trauma resuscitation on survival: a retrospective, multicentre study. *Lancet* 2009; 373: 1455–1461
- 25 Fabian T. Whole-body CT in multiple trauma. *Lancet* 2009; 373: 1408–1409. DOI: 10.1016/S0140-6736(09)60354-8 Epub 2009 Mar 25
- 26 Wedegartner U, Lorenzen M, Nagel HD et al. Diagnostic imaging in polytrauma: comparison of radiation exposure from whole-body MSCT and conventional radiography with organ-specific CT. *Fortschr Röntgenstr* 2004; 176: 1039–1044
- 27 Frellesen C, Stock W, Kerl JM et al. Topogram-based automated selection of the tube potential and current in thoraco-abdominal trauma CT – a comparison to fixed kV with mAs modulation alone. *European radiology* 2014; 24: 1725–1734