

# Selective arterial Embolisation of Aneurysmal Bone Cysts of the Sacrum: a promising Alternative to Surgery

## Die transarterielle Embolisation von Aneurysmatischen Knochenzysten des Os sacrum: eine vielversprechende Alternative zur Operation

### Authors

M. P. Henrichs<sup>1</sup>, L. Beck<sup>2</sup>, G. Gosheger<sup>1</sup>, A. Streitbuenger<sup>1</sup>, M. Koehler<sup>2</sup>, W. Heindel<sup>2</sup>, J. Harges<sup>1</sup>, V. Vieth<sup>2</sup>

### Affiliations

<sup>1</sup> General Orthopaedics and Tumororthopaedics, University Hospital Münster, Germany

<sup>2</sup> Department of Clinical Radiology, University Hospital Münster, Germany

### Key words

- aneurysmal bone cyst
- selective arterial embolization
- sacrum
- bone tumor

received 2.3.2015  
accepted 17.7.2015

### Bibliography

DOI <http://dx.doi.org/10.1055/s-0041-106069>  
Published online: 2015  
Fortschr Röntgenstr 2016; 188: 53–59 © Georg Thieme Verlag KG Stuttgart · New York · ISSN 1438-9029

### Correspondence

**Dr. Marcel-Philipp Henrichs**  
Allgemeine Orthopädie und Tumororthopädie, Universitätsklinikum Münster  
Albert-Schweitzer-Campus 1  
48149 Münster  
Germany  
Tel.: ++49/2 51/8 34 79 38  
Fax: ++49/2 51/8 34 79 57  
[mp.henrichs@gmail.com](mailto:mp.henrichs@gmail.com)

### Abstract



**Purpose:** The sacrum is a rare but unfavourable location for Aneurysmal Bone Cysts (ABCs), surgical procedures aiming to achieve local tumour control can be mutilating. Aim of this study was to evaluate whether selective arterial embolisation (AE) of ABC of the sacrum is an effective treatment and might be an alternative to surgical treatment options.

**Materials and Methods:** Between 2007 and 2011 six patients (mean age 13.7 years, range 8 – 18 years) with an ABC of the sacrum were treated by AE. Follow-up was performed by MRI-scans as well as clinical examination (mean 36.5 months, range 14 – 56 months).

**Results:** No treatment related complications have been observed. AE resulted in devascularisation of ABC and led to local tumour control in all patients. A partial consolidation was noticed in three patients. Pain relief was achieved in five of six patients, neurological deficits dissolved. In two patients more than one embolization was necessary. In one of these patients due to exacerbation of pain a surgical decompression was performed.

**Conclusion:** AE of sacral ABCs can serve as an effective and safe treatment option. Thus it might be an alternative to potentially harmful surgical procedures. In case of ongoing tumour growth or pain recurrence AE can be repeated. In case of treatment failure surgical interventions are still possible.

### Key Points:

- ▶ transarterial embolisation enables local tumour control in sacral ABCs
- ▶ transarterial embolisation of sacral ABCs is a safe procedure
- ▶ in case of tumour progression repetitive embolisations are possible and effective

### Citation Format:

- ▶ Henrichs MP, Beck L, Gosheger G et al. Selective arterial Embolisation of Aneurysmal Bone Cysts of the Sacrum: a promising Alternative to Surgery. Fortschr Röntgenstr 2016; 188: 53–59

### Zusammenfassung



**Ziel:** Das Os sacrum ist eine seltene Lokalisation der Aneurysmatischen Knochenzyste (AKZ). Die chirurgische Behandlung führt an dieser Stelle nicht selten zu ernsthaften Komplikationen. Ziel dieser retrospektiven Studie war es zu überprüfen, ob eine lokale Tumorkontrolle allein mittels transarterieller Embolisation als Alternative zur Operation zu erreichen ist.

**Material und Methoden:** Zwischen 2007 und 2011 wurden sechs Patienten (Durchschnittsalter 13,7 Jahre, Spanne 8 – 18 Jahre) mit einer AKZ des Os sacrum mittels transarterieller Embolisation behandelt. Die Nachuntersuchungen erfolgten klinisch und mittels MRT-Kontrollen (Nachbeobachtungszeitraum 36,5 Monate, Spanne 14 – 56 Monate).

**Ergebnisse:** Behandlungsassoziierte Komplikationen wurden nicht beobachtet. Die transarterielle Embolisation führte zur Devaskularisation der AKZ und resultierte in einer lokalen Tumorkontrolle bei allen Patienten. Eine teilweise Konsolidierung der AKZ wurde in drei Fällen beobachtet. Eine vollständige Beschwerdefreiheit wurde in fünf von sechs Patienten erreicht, sogar neurologische Ausfallserscheinungen bildeten sich zurück. Bei zwei Patienten musste mehr als eine Embolisation erfolgen. Bei einem Patienten hiervon wurde auf Grund einer Exazerbation der Schmerzsymptomatik eine operative Dekompression durchgeführt.

**Schlussfolgerung:** Die transarterielle Embolisation von AKZ des Os sacrum ist nicht nur eine adjuvante Maßnahme, sondern kann als effektive Behandlung eine Alternative zu potenziell gefährlichen chirurgischen Eingriffen darstellen. Im Falle weiteren Tumorwachstums oder bei Beschwerdeprogredienz kann die Embolisation mehrfach wiederholt werden. Bei Versagen sind chirurgische Eingriffe weiterhin möglich.

#### Kernaussagen:

- ▶ Die transarterielle Embolisation führt zur lokalen Tumorkontrolle bei AKZs des Os sacrum
- ▶ Die transarterielle Embolisation stellt eine komplikationsarme Alternative zu chirurgischen Eingriffen dar
- ▶ Bei Wachstumsprogredienz ist eine wiederholte Embolisation möglich und effektiv

## Introduction

The aneurysmal bone cyst (ABC) is a benign bone lesion comprising approx. 1 % of all primary osseous lesions. The typical patient's age is below 20 years [1]. Although ABC was initially described by Jaffe and Liechtenstein in 1942, to-date little is known about its origin. The ABC consists of cyst-like chambers made up of fibrous tissue filled with free-flowing blood [1, 2]. The typical visual appearance in imaging is usually characterized by a balloon-like thinned cortex as well as multiple septa [3]. Detection of mirroring and contrast agent absorption by the cystic membranes in magnetic resonance imaging (MRI) should be assessed as almost pathognomonic [4]. Generally ABCs are localized in the metaphyses and diaphyses of the long bones; they infrequently also occur on the spine or in the pelvic region [5]. In extraordinary cases, an ABC can be localized on the sacrum. Mirra describes only three cases in his study cohort of 492 cases [1].

If ABC is suspected, the diagnosis should always be confirmed by biopsy. CT-guided procedures are suitable for this [6, 7]. Especially in the case of solid tumor components, malignant bone lesions such as low-malignant central osteosarcoma or telangiectatic osteosarcoma should be ruled out. Further, the ABC should be distinguished from a so-called secondary aneurysmal bone cyst which can occur as a secondary phenomenon of other bone lesions such as giant cell tumor.

Clinical symptoms of ABC are generally non-specific; however, stress-related pain is frequently reported. If the ABC is located on the spine or in the sacral region, space-occupying ballooning of the cortex may also cause compression of the spinal cord or nerve roots, usually manifested by neurological deficits.

Treatment of an aneurysmal bone cyst is the subject of ongoing discussions. If the ABC is located in the area of the long bones, treatment usually consists of curettage of the cyst, followed by plombage with bone cement or filling with bone or bone replacement material [8, 9]. Other approaches employ local cryotherapy or application of sclerosing agents such as polidocanol [10–13]. Surgical intervention in the spinal or sacral region is not without risk, as it can result in damage to the myelon or nerve roots with accompanying permanent neurological deficits. Furthermore, there are individual case reports of drug treatment using denosumab, but this is likewise risky and has not been approved for treating ABC [14].

Previously, transarterial embolization of bone lesions was generally performed as a preoperative measure to reduce hemorrhaging [15–19]. However, a few recent publications have reported using embolization as a primary treatment of bone lesions at unfavorable anatomical locations [20–22]. The aim of this retrospective study was to evaluate the effectiveness of using transarterial embolization of ABCs of the sacrum as the sole treatment mechanism.

## Materials and Methods

This retrospective study included all patients in our tumor database who were diagnosed with a primary aneurysmal bone cyst of the sacrum via biopsy and who then were treated using transarterial embolization. In total, between 2007 and 2011 six patients (two girls, four boys), between 8–18 years of age were treated (average age 13.7 years, **Table 1**). The period of time between initial MRI imaging and embolization was a maximum of eight weeks. Clinical data were taken from the patients files, including information from the clinical examination and case history collected in the course of aftercare. This also included asking about pain analogously to the numeric rating scale (NRS), in which the patient has to rate pain according to a scale

patient	age (years)	gender	symptoms	duration of symptoms (months)
1	15	female	lower back pain, pain in left thigh (NRS 5)	12
2	8	male	lower back pain (NRS 6), 4/5 paresis of right S1, trendelenburg gait, paresthesia right heel	1
3	14	female	lower back pain, pain in left gluteal (NRS 6)	3
4	18	male	no pain (NRS 0), incidental finding (PET CT)	0
5	11	male	pain right gluteal (NRS 5)	11
6	16	male	pain in right sacral bone (NRS 9), left scrotal paresthesia, bladder dysfunction	6

**Table 1** Patient data, symptoms at time of first presentation including intensity of pain and duration of symptoms.

NRS = numeric rating-scale.

ranging from 0 (no pain) to 10 (maximum imaginable pain). Data were collected during every patient contact. In the first year after embolization, MRI examinations were performed every three months as follow-up and to rule out interventional complications (e.g. osteonecrosis); after that, the interval was extended to six months. After two years had passed, annual MRI follow-up examinations were recommended. The MR images were produced in various institutes; evaluation, however, was performed in one institute by two independent assessors. Local lesion monitoring (no further lesion growth/regression) as well as pain reduction/elimination were considered to be therapeutic success. In addition, changes to the interior structure of the cysts were documented. Enlargement of the ABC after initial embolization as well as persistent/progressive clinical symptoms were considered indications for repeated transarterial embolization.

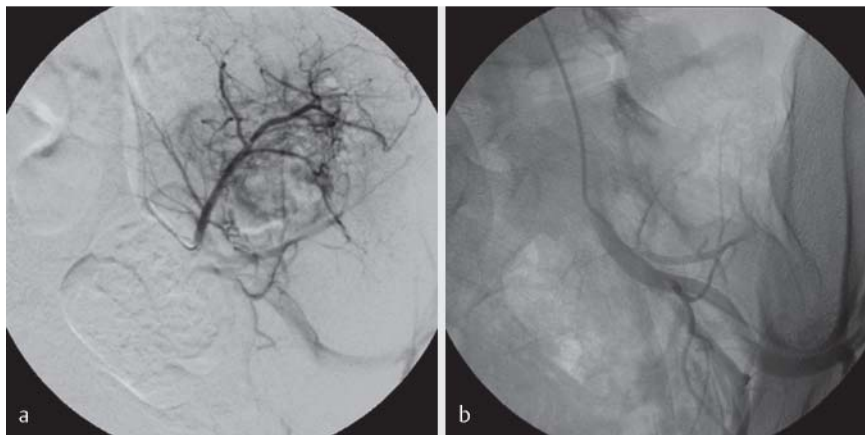
### Treatment

The goal of interventional therapy is the primary particle embolization of the tumor bed to completely devascularize the ABC. In all cases a diagnostic overview and selective angiography were performed first to evaluate the arterial tumor flow (► Fig. 1a, 2a). A 4 or 5 French introducer sheath [Radifocus Introducer II, Terumo Europe N.V., Belgium] was inserted in all patients using a retrograde arterial access point via the femoral artery as an introitus. Selective vas-

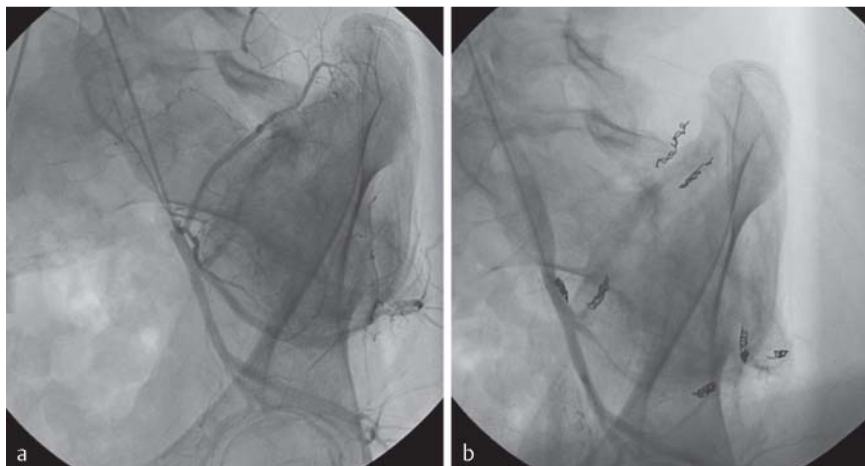
cular exploration used either a UF, cobra or vertebral catheter [SUPER TORQUE Angiographic Catheter, Cordis/Johnson & Johnson Europe, Ireland; Tempo 5 Angiographic Catheter, Cordis/Johnson & Johnson Europe, Ireland]; the DSA series were acquired using mechanical contrast agent application. A hypervascularized tumor bed was diagnosed in 4 patients during the initial angiography. In addition, 2 patients demonstrated outflow via collaterals which had to be closed using protective coil embolization by means of thrombogenic microcoils to avoid undesirable particle outflow prior to tumor embolization itself [Tornado Embolization Coil, Cook Medical Europe, Ireland]. Supraselective exploration of the branches supplying the ABC used a micro-catheter and micro-wire [Progreat, Terumo Europe N.V., Belgium; Fathom Steerable Guidewire, Boston-Scientific Europe, France]; embolization of the tumor bed utilized PVA particles [Contour, 355 – 500 µm, Boston-Scientific Europe, France; Embocept, 400 µm, Pharmacept; Embozene Microspheres, 400 µm, Celonova Biosciences, Texas].

Two of the patients did not demonstrate a hypervascularized tumor bed, and the vascular branches supplying the cysts were closed via coil embolization [Tornado Embolization Coil, Cook Medical Europe, Ireland].

After embolization, a final DSA series was obtained in order to determine the level of devascularization (► Fig. 1b, 2b). If the tumor grew or if pain persisted, an angiography and subsequent arterial embolization were repeated.



**Fig. 1** a Pre-therapeutical DSA picture showing the vascular supply of a huge aneurysmal bone cyst of the sacrum. Main vessels derive from the internal iliac artery. In contrast to the surrounding area a hypervascularisation can be seen. b DSA-Series after embolisation with PVA particles showing an almost complete devascularisation of the ABC.



**Fig. 2** a DSA-picture showing a hypervascularised ABC of the sacrum with several feeding vessels deriving from the internal iliac artery. b Angiogram after selective arterial embolisation. With a combination of coils and 350 – 500 µm sized PVA-particles an embolisation of the main supplying vessels lead to an 80 % devascularisation of the ABC.

## Results



### Initial radiological and clinical findings

The MR images demonstrated an average pre-interventional tumor volume of 145.5 cm<sup>3</sup> (25.34 to 365.20 cm<sup>3</sup>). The midline was exceeded in four cases (Table 2).

Prior to treatment, lower back pain was reported as the most frequent symptom.

Two patients had recurrent sciatica. The average pre-interventional pain intensity came up to 6 of 10 (NRS, numeric rating scale, range 4–9). Pre-therapeutic neurological deficits were documented for two patients. One patient presented with 4/5 paresis of S1; in another patient, scrotal sensitivity deficit combined with bladder function impairment was determined. Symptom duration ranged from 1 to 12 months (Table 1). In one patient, ABC was detected using PET-CT as incidental findings in the course of follow-up of Ewing's sarcoma of the tenth rib and concurrently occurring lung metastasis that had been diagnosed four years previously; six months prior to this, the PET-CT was unremarkable.

### Results of transarterial embolization

The transarterial embolization resulted in complete devascularization (100%) in three patients; 80% devascularization was achieved for the other patients. The degree of devascularization was estimated using a subsequent DSA series. Treatment-related complications were not observed (Table 3).

### Radiological post-treatment examination

The average post-treatment examination time frame using MRI was 32.2 months (10–54 months, Table 2). The objective of local tumor control was achieved with all patients. In four of the six patients, growth inhibition of the ABC was observed after the first embolization; two pa-

tients required a second treatment, and one required a third. Over time, regression of the ABC was observed in three of six patients; in these cases the cystic components developed into solid tissue (Fig. 3–5). The average tumor volume was reduced over time from 145.5 cm<sup>3</sup> to 80.64 cm<sup>3</sup> (Table 2).

### Clinical post-treatment examination

The average post-treatment clinical examination time frame was 36.5 months (14–56 months, Table 2). Four of five symptomatic patients (incidental finding of ABC for Patient no. 4) reported freedom from pain (NRS 0). One patient with a baseline 4/5 paresis of S1 demonstrated complete regression. After seven months, a second embolization was performed on the patient with the coincidentally-discovered ABC, since MR imaging exhibited additional size progression; consequently further growth was inhibited, and finally an onset of consolidation was observed. Initially the sixth patient reported pain intensity of nine on the NRS. The initial arterial embolization did not result in lasting pain reduction; therefore one month later a second angiography and embolization were performed. Complete devascularization was achieved after the second treatment. Due to a sudden exacerbation of sciatica without an identifiable trigger, persistence of scrotal paresthesia and previously reported bladder dysfunction, surgical decompression and neurolysis were performed two months after the initial embolization. The sciatica and bladder dysfunction immediately regressed but the lack of sensitivity in the scrotal region persisted. When symptoms returned, only small-diameter blood vessels were detected and embolized after a third angiography. After eight months the MRI demonstrated that the size remained constant; pain was reported as only 1 (NRS). The patient could return to work as a craftsman without restrictions.

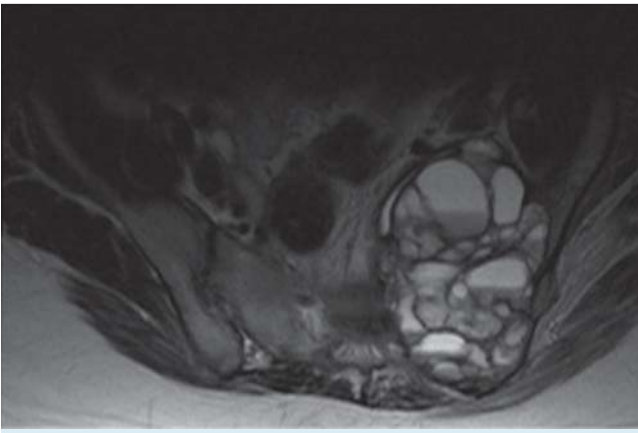
**Table 2** Location and initial dimension of sacral aneurysmal bone cyst, measured in cm<sup>3</sup>. Additionally shown is the dimension at last MRI follow-up. Radiological and clinical follow-up in months.

patient	location (massa lateralis)	initial cyst volume in cm <sup>3</sup>	cyst volume at last follow-up in cm <sup>3</sup>	follow-up MRI	clinical follow-up
1	left, S2 – S3	365.20	65.86	32 months	32 months
2	right, S1 – S2	185.76	184.70	36 months	39 months
3	left, S1 – S2	181.83	158.69	28 months	35 months
4	left, S1 – S2	25.34	8.75	35 months	43 months
5	right, S2 – S5	57.46	11.31	54 months	56 months
6	left, S2 – S4	57.41	54.54	10 months	14 months

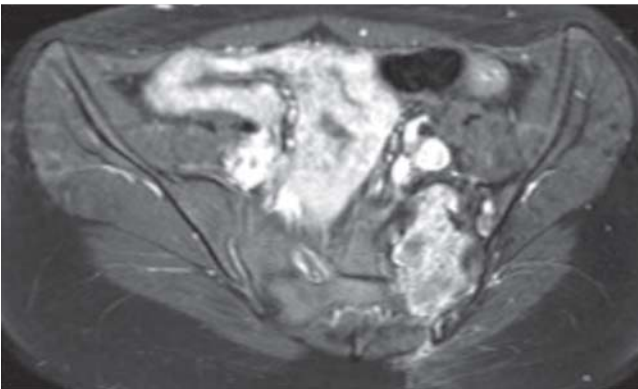
**Table 3** Overview of success, subsequent treatment and treatment-related complications. In addition, symptoms remaining after TAE are shown.

patient	degree of estimated devascularization	subsequent treatment	complications after TAE	symptoms after TAE
1	80 %	none	none	none, NRS 0
2	100 %	none	none	none, NRS 0
3	80 %	none	none	none, NRS 0
4	1. 100 %, 2. 100 %	2. TAE	none	none, NRS 0
5	100 %	none	none	none, NRS 0
6	1. 80 %, 2. 100 %, 3. 100 %	2. TAE decompression 3. TAE	none	paresthesia, intermittent NRS 1

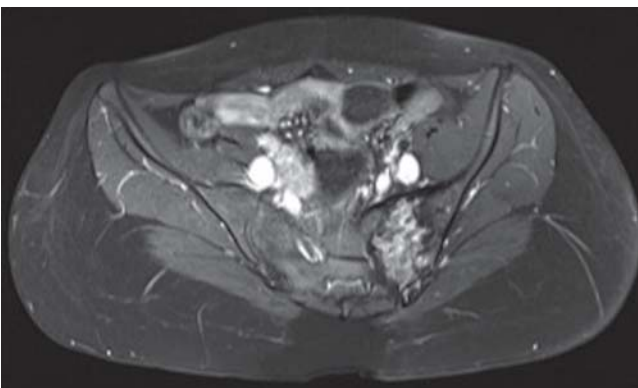
TAE = Transarterial Embolization, NRS = Numeric Rating Scale.



**Fig. 3** Axial MRI-scan (T1 TSE with contrast medium) of a 15 year-old girl revealing a huge ABC of the sacrum. The initial, pre-therapeutical expansion measures  $8.0 \times 5.5 \times 8.3$  cm with extension to the midline. In addition a huge ventral component can be seen.



**Fig. 4** Axial MRI scan (T1 TSE FS with contrast medium) 18 months after embolisation. A shrinking of the ABC to  $3.0 \times 5.4 \times 5.0$  cm can be detected. Further a reduction of cystic areas and fluid levels can be detected.



**Fig. 5** Axial MRI scan (T1 TSE FS with contrast medium) 32 months after embolisation. Minimal further reduction of tumor size ( $2.8 \times 4.8 \times 4.9$  cm) and ongoing transformation of cystic areas into fibrous components.

## Analysis



The goal of treating patients with aneurysmal bone cysts is local tumor control, freedom from pain and restoration of normal anatomy [11]. In the extremities region, surgical treatment is the standard procedure. Generally, curettage is performed; as a local adjuvant treatment, an application of phenol and/or cryotherapy is employed [11, 12]. Reconstruction of the bony defect uses bone (autogenous or allogenic), bone substitutes or bone cement [9, 11, 23]. Another minimally-invasive therapeutic method is percutaneous injection of sclerosing agents such as polidocanol [10]. Treatment of ABCs in the sacral region must be more sophisticated, and frequently requires an interdisciplinary approach. Due to their location, ABCs are frequently diagnosed only after they have expanded to the point where they create irritation or compression of nerve roots or myelom. Pathological fractures of the sacrum causing stress-related pain were not evident in our series of patients [24]. Complete curettage in the sacrum is generally not possible due to the proximity of blood vessels and nerve roots; however there are reports of complication-prone surgical interventions at this location. For example, Pogoda et al. report on an intralesional resection of a large sacral ABC with an extensive ventral soft tissue component. During the operation, the right-lateral components of sacral vertebrae 1 to 3 were removed. To provide dorsal stability, instrumentation from lumbar vertebra 4 deep into the sacrum was performed [25]. Brastianos and colleagues report of a series with 10 patients with an ABC of the sacrum. Broad resection of the tumor was performed on patients with an ABC on the caudal sacrum broad; on the other hand, curettage was performed in the cranial region with protection of the nerve root. Four patients developed local recurrence (on average 17 months postoperatively); in two patients curettage also caused permanent vesicorectal dysfunction [26]. Based on these reports, it should be questioned whether these risky and complication-laden treatment procedures of a benign tumor are justified. Our data show that transarterial embolization used for local lesion control (no further growth or regression) generally results in complete symptom relief. Furthermore, no treatment-related complications have been observed. Recent publications on minimally-invasive techniques (e.g. injection of fibrosing agents or CT-guided injection of demineralized bone and bone marrow) demonstrate that extensive operations can be avoided [2, 16, 27–29].

Likewise, percutaneous injection of polidocanol for sclerotherapy of the cyst is an effective procedure; however, in the case of larger cysts, multiple applications using anesthesia are required [13]. Sequential injection therapy in the sacral region can be usefully employed, especially if angiography rules out a hypervascularized tumor bed, and embolization does not appear to be medically sensible. An additional sclerosing agent is NBCA (N-2-butyl cyanoacrylate). NBCA is successfully used for selective arterial embolization; there are numerous studies of endovascular application in the treatment of ABC [20, 21]. To-date there have been no large-scale studies of the percutaneous use of NBCA in the treatment of ABC.

So far there are hardly any reports regarding transarterial embolization as a sole method of treatment [28, 29]. Gen-

erally embolization is used preoperatively to reduce bleeding [16, 19, 29].

Our series demonstrates that local tumor control can be achieved using transarterial embolization as the sole treatment method. During a follow-up period averaging more than two years there was no size progression; in the case of three patients a noticeable regression was observed as well as partially solid remodeling of the cyst (► Fig. 3–5). Even though long-term results are still pending, stopping cyst growth and remodeling of cystic areas into solid components are indicative of long-lasting beneficial effects. In this regard, only a small number of transarterial embolizations have been necessary. Although in our cases, compared to other series, remineralization of the bone was not observed, five of six patients are symptom-free, their neurological deficits indicated regression [28, 29]. The sixth patient reported that pain had subsided to the point where he could return to work. All patients could engage in full weight-bearing sporting activities without limitation. This suggests that with respect to aneurysmal bone cysts in the sacrum compared to those in long bones of the extremities, restoration of the physiological bone structure appears to be of secondary importance. In our opinion, based on the above-described therapeutic successes, CT and X-ray examinations for more accurate determination of possible remineralization are unnecessary.

If a lesion progresses, then embolization can be repeated, as was the case of the two patients in our series. As shown in post-interventional MRIs, repeated embolization in both cases achieved local tumor control. Our results demonstrate that embolization can be effectively used even for very large ABCs. In the case of recurring bladder or rectal dysfunction as well as apparent paresis, embolization can be utilized for preoperative reduction in bleeding; however, this should not result in unnecessary delay of prompt surgical decompression. Resection of the ABC is not indicated in such cases, however, since embolization can inhibit further growth. If interventional treatment of the ABC is required, regular MRI follow-up is indispensable. In this way the success of the therapy, or, if necessary, the need for further therapeutic actions can be detected promptly.

A basic limitation of this study is the small size of the patient cohort; however this can be ascribed to the low incidence of sacral ABC. A further limitation is the lack of a comparative cohort. Due to the above-mentioned possible treatment complications, delayed action or surgery is not justified, however.

In the case of five of six patients, the follow-up examination time frame is greater than two years; for patient number six, this ended after eight months following surgical decompression. In this case, as well, MR images exhibit local tumor control. Despite these limitations, there are promising results; in our study cohort, transarterial embolization represents a safe and effective therapeutic approach which in our clinic has shown great value in the interdisciplinary treatment of aneurysmal bone cysts of the sacrum.

### Clinical Relevance of the Study

- Transarterial embolization can be successfully employed for the treatment of aneurysmal bone cysts at problematic locations such as the sacrum.
- In addition to local tumor control, transarterial embolization results in pain reduction.
- Complication-prone operations for the purpose of local tumor control have been avoidable in our cohort by using transarterial embolization.
- Even though an ABC has shown progression, repeated embolization can achieve local tumor control.

### Literatur

- 1 Mirra JM. Bone Tumors. Clinical, Radiologic, and Pathologic Correlations. 2 ed. Philadelphia: Lea and Febiger; 1989: 1267–1311
- 2 Donati D, Frisoni T, Dozza B et al. Advance in the treatment of aneurysmal bone cyst of the sacrum. *Skeletal Radiol* 2011; 40: 1461–1466
- 3 Mankin HJ, Hornicek FJ, Ortiz-Cruz E et al. Aneurysmal bone cyst: a review of 150 patients. *Journal of clinical oncology: official journal of the American Society of Clinical Oncology* 2005; 23: 6756–6762
- 4 Woertler K, Blasius S, Hillmann A et al. MR morphology of primary aneurysmal bone cysts: a retrospective analysis of 38 cases. *Fortschr Röntgenstr* 2000; 172: 591–596
- 5 Erlemann R, Picker S, Mueller-Miny H et al. Aneurysmal bone cyst or giant cell tumor. The value of x-ray diagnosis for differential diagnosis. *Fortschr Röntgenstr* 1993; 158: 343–347
- 6 de Bucourt M, Busse R, Zada O et al. CT-guided biopsies: quality, complications and impact on treatment: a retrospective initial quality control. *Fortschr Röntgenstr* 2011; 183: 842–848
- 7 Keulers A, Cunha-Cruz VC, Bruners P et al. Bone biopsy needles: mechanical properties, needle design and specimen quality. *Fortschr Röntgenstr* 2011; 183: 274–281
- 8 George B, Abudu A, Grimer RJ et al. The treatment of benign lesions of the proximal femur with non-vascularised autologous fibular strut grafts. *J Bone Joint Surg Br* 2008; 90: 648–651
- 9 Ozaki T, Hillmann A, Lindner N et al. Cementation of primary aneurysmal bone cysts. *Clin Orthop Relat Res* 1997; 337: 240–248
- 10 Varshney MK, Rastogi S, Khan SA et al. Is sclerotherapy better than intralesional excision for treating aneurysmal bone cysts? *Clin Orthop Relat Res* 2010; 468: 1649–1659
- 11 Peeters SP, Van der Geest IC, de Rooy JW et al. Aneurysmal bone cyst: the role of cryosurgery as local adjuvant treatment. *Journal of surgical oncology* 2009; 100: 719–724
- 12 Tsoumakidou G, Too CW, Garnon J et al. Treatment of a spinal aneurysmal bone cyst using combined image-guided cryoablation and cementoplasty. *Skeletal Radiol* 2015; 44: 285–289
- 13 Brosjo O, Pechon P, Hesla A et al. Sclerotherapy with polidocanol for treatment of aneurysmal bone cysts. *Acta Orthop* 2013; 84: 502–505
- 14 Lange T, Stehling C, Frohlich B et al. Denosumab: a potential new and innovative treatment option for aneurysmal bone cysts. *Eur Spine J* 2013; 22: 1417–1422
- 15 Dick HM, Bigliani LU, Michelsen WJ et al. Adjuvant arterial embolization in the treatment of benign primary bone tumors in children. *Clin Orthop Relat Res* 1979; 139: 133–141
- 16 Yildirim E, Ersozlu S, Kirbas I et al. Treatment of pelvic aneurysmal bone cysts in two children: selective arterial embolization as an adjunct to curettage and bone grafting. *Diagnostic and interventional radiology* 2007; 13: 49–52
- 17 De Cristofaro R, Biagini R, Boriani S et al. Selective arterial embolization in the treatment of aneurysmal bone cyst and angioma of bone. *Skeletal Radiol* 1992; 21: 523–527
- 18 Meyer S, Reinhard H, Graf N et al. Arterial embolization of a secondary aneurysmatic bone cyst of the thoracic spine prior to surgical excision in a 15-year-old girl. *European journal of radiology* 2002; 43: 79–81
- 19 Reuter M, Heller M, Heise U et al. Transcatheter embolization of tumors of the muscular and skeletal systems. *Fortschr Röntgenstr* 1992; 156: 182–188

- 20 Rossi G, Rimondi E, Bartalena T et al. Selective arterial embolization of 36 aneurysmal bone cysts of the skeleton with N-2-butyl cyanoacrylate. *Skeletal Radiol* 39: 161–167
- 21 Rossi G, Mavrogenis AF, Rimondi E et al. Selective arterial embolisation for bone tumours: experience of 454 cases. *La Radiologia medica* 2011; 116: 793–808
- 22 Doss VT, Weaver J, Didier S et al. Serial endovascular embolization as stand-alone treatment of a sacral aneurysmal bone cyst. *J Neurosurg Spine* 2014; 20: 234–238
- 23 Cottalorda J, Bourelle S. Current treatments of primary aneurysmal bone cysts. *J Pediatr Orthop B* 2006; 15: 155–167
- 24 Ludtke CW, Kamusella P, Andresen R. Pain management in pathologic sacrum fracture with CT guided balloon sacral vertebroplasty. *Fortschr Röntgenstr* 2012; 184: 578–580
- 25 Pogoda P, Linhart W, Priemel M et al. Aneurysmal bone cysts of the sacrum. Clinical report and review of the literature. *Archives of orthopaedic and trauma surgery* 2003; 123: 247–251
- 26 Brastianos P, Gokaslan Z, McCarthy EF. Aneurysmal bone cysts of the sacrum: a report of ten cases and review of the literature. *The Iowa orthopaedic journal* 2009; 29: 74–78
- 27 Topouchian V, Mazda K, Hamze B et al. Aneurysmal bone cysts in children: complications of fibrosing agent injection. *Radiology* 2004; 232: 522–526
- 28 Gottfried ON, Schmidt MH, Stevens EA. Embolization of sacral tumors. *Neurosurgical focus* 2003; 15: E4
- 29 Konya A, Szendroi M. Aneurysmal bone cysts treated by superselective embolization. *Skeletal Radiol* 1992; 21: 167–172