



An Unusual Cause of Posterior Knee Pain: Muroid Degeneration of the Anterior Cruciate Ligament – Case Report

Uma causa incomum de dor posterior no joelho: degeneração mucóide do ligamento cruzado anterior – Relato de caso

Fabiano da Silva Marques^{1,4} Pedro Bezzan Rodrigues Alves^{1,4} Sandro Zelada^{1,4}
Rodrigo Pereira da Silva Nunes^{2,3} Wilson Mello Alves^{1,4} Gustavo Constantino de Campos^{1,5}

¹ Department of Orthopedics, Instituto Wilson Mello, São Paulo, Brazil

² Department of Orthopedics, Pontifícia Universidade Católica de Campinas, Campinas São Paulo, Brazil

³ Nunes Orthopedics and Traumatology Clinic (CNOT), Campinas, São Paulo, Brazil

⁴ Knee Surgery Group, Hospital da Pontifícia Universidade Católica de Campinas, Campinas, São Paulo, Brazil

⁵ Department of Orthopedics, Universidade Estadual de Campinas (UNICAMP), Campinas, São Paulo, Brazil

Address for correspondence Fabiano da Silva Marques, MD, Avenida Nelsia Vannucci, 105, apto. 33, Campinas, São Paulo, 13042-104, Brazil (e-mail: fabiano.s.marques@gmail.com).

Rev Bras Ortop 2023;54(5):e826–e830.

Abstract

Muroid degeneration of the anterior cruciate ligament (ACL) is an uncommon cause of pain in the posterior region of the knee, of unknown pathophysiology and underdiagnosed. The best treatment modality is still under discussion. Resection of the lesion with partial ACL debridement has shown good results without the occurrence of instability. The authors present a case of muroid degeneration of the ACL treated with resection of the muroid degeneration and partial debridement of the ACL by arthroscopy.

Keywords

- ▶ anterior cruciate ligament
- ▶ arthroscopy
- ▶ knee joint

Resumo

A degeneração mucoide do ligamento cruzado anterior (LCA) é uma causa pouco frequente de dor na região posterior do joelho, de patofisiologia desconhecida e subdiagnosticada. A melhor modalidade de tratamento ainda está em discussão. A ressecção da lesão com desbridamento parcial do LCA tem apresentado bons resultados, sem a ocorrência de instabilidade. Os autores apresentam um caso de degeneração mucoide do LCA tratado com ressecção da degeneração mucoide e desbridamento parcial do LCA por artroscopia.

Palavras-chave

- ▶ ligamento cruzado anterior
- ▶ artroscopia
- ▶ articulação do joelho

Work developed in the Orthopedics Departments of UNICAMP and of Instituto Wilson Mello, Campinas, São Paulo, Brazil.

received
July 18, 2020
accepted
September 16, 2020

DOI <https://doi.org/10.1055/s-0040-1722593>.
ISSN 0102-3616.

© 2023. Sociedade Brasileira de Ortopedia e Traumatologia. All rights reserved.

This is an open access article published by Thieme under the terms of the Creative Commons Attribution-NonDerivative-NonCommercial-License, permitting copying and reproduction so long as the original work is given appropriate credit. Contents may not be used for commercial purposes, or adapted, remixed, transformed or built upon. (<https://creativecommons.org/licenses/by-nc-nd/4.0/>)

Thieme Revinter Publicações Ltda., Rua do Matoso 170, Rio de Janeiro, RJ, CEP 20270-135, Brazil

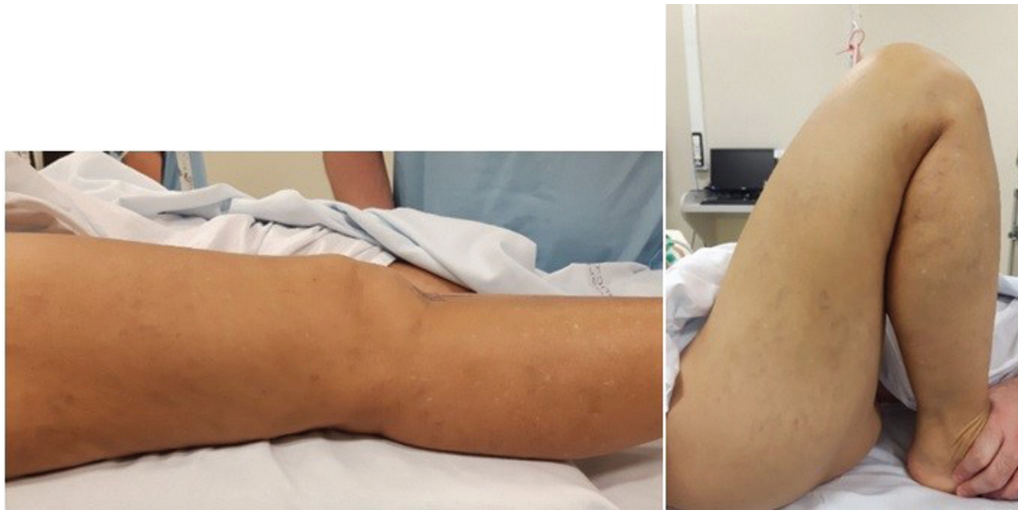

Fig. 1 Preoperative clinical image.

Introduction

Mucoid degeneration of the anterior cruciate ligament (ACL) is a rare entity, of unknown pathophysiology, underdiagnosed and undertreated in our metier.^{1,2} The first case was described by Kumar et al.³ Since then, multiple articles addressing and giving relevance to the theme have been published.¹⁻¹⁰

Case Report

A 51-year-old female patient complaining of pain in the posterior region of the right knee that had begun one year prior to her visit. She denied previous traumas, and her personal and family history were irrelevant.

Upon physical examination, she had no joint effusion or edema, an arc of motion ranging from 0° to 130° (→**Fig. 1**), and pain in the posterior region of the right knee at maximum flexion. There was absence of signs and clinical tests suggestive of instability or meniscal lesions. The routine knee x-rays showed no relevant changes (→**Fig. 2**).

Motor physiotherapy to stretch and strengthen the quadriceps associated with non-steroidal anti-inflammatory drugs (NSAIDs) was prescribed without benefit. A magnetic resonance imaging (MRI) (→**Fig. 3**) scan showed thickening and signal alteration in the anterior cruciate ligament throughout its extension, maintaining the topography and parallelism of its fibers. Signal change in the body and posterior horn of the medial meniscus was also observed.

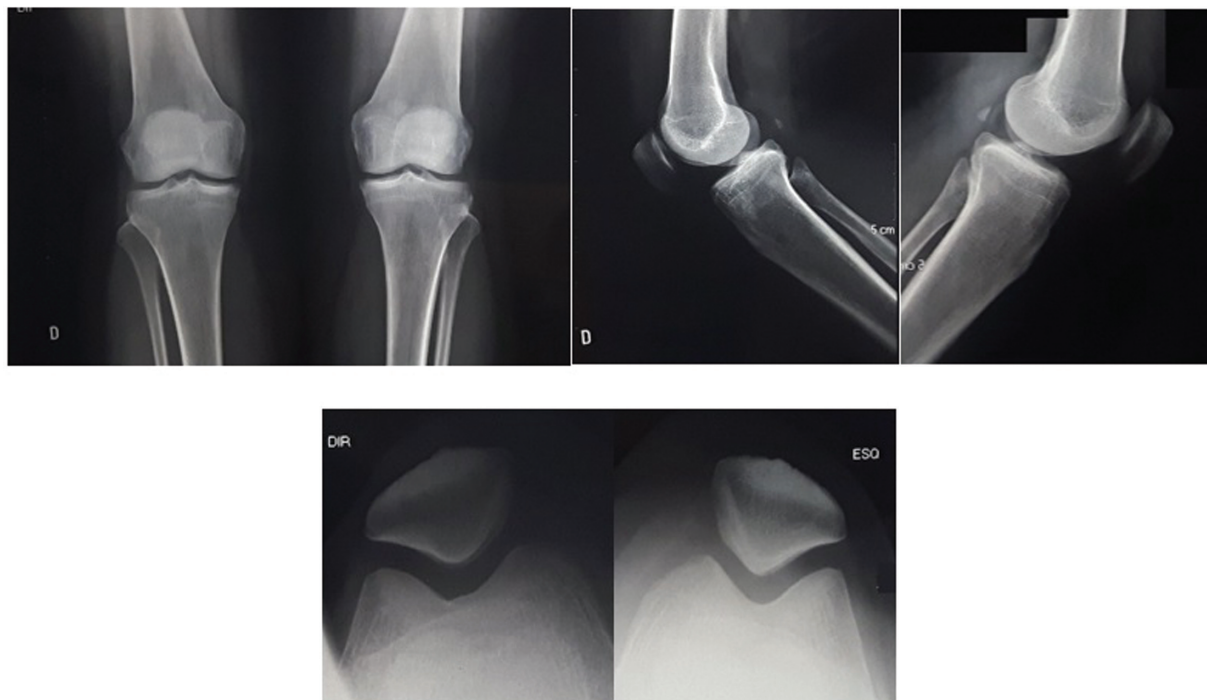


Fig. 2 Preoperative radiographs in anteroposterior, lateral and axial views of the patella of both knees.

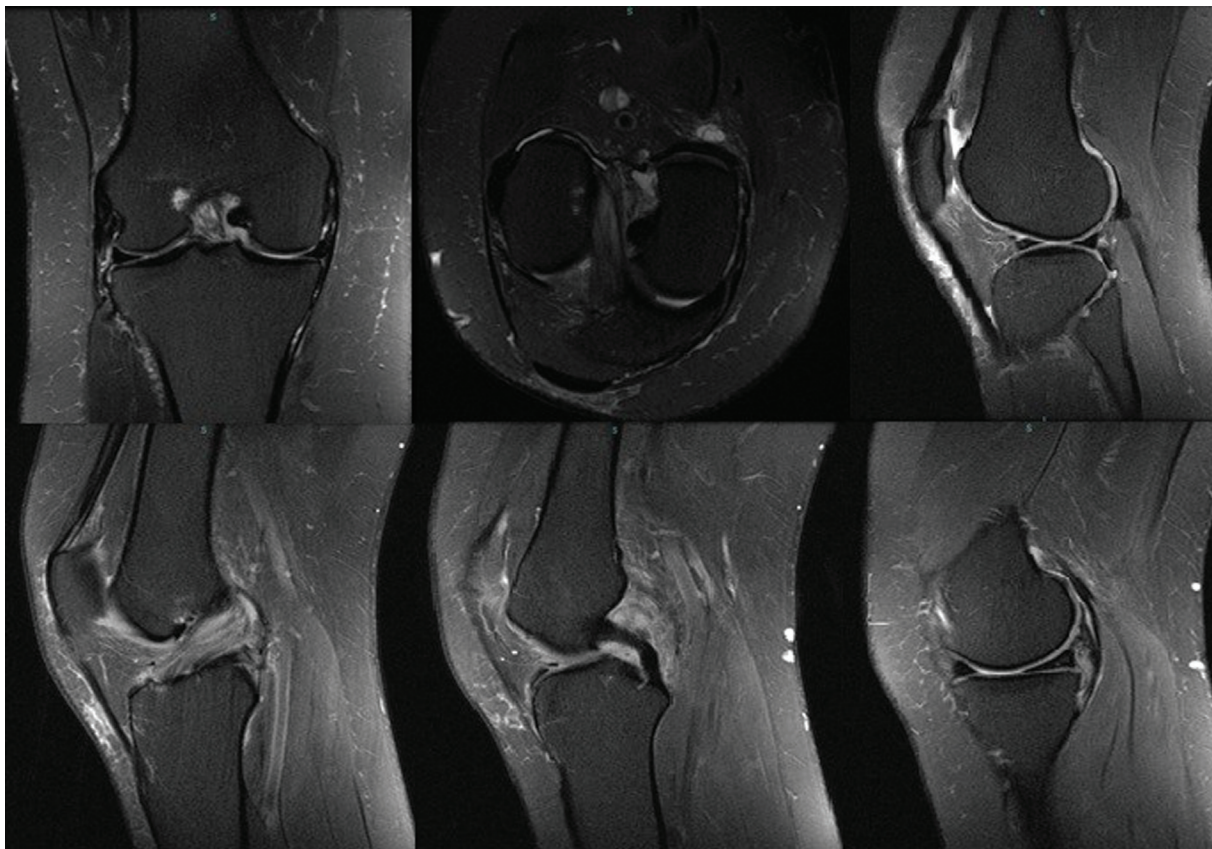


Fig. 3 T2-weighted MRI scan demonstrating hypertrophy of the anterior cruciate ligament (ACL), and signal increase without loss of continuity of its fibers – “celery stalk” sign.

We opted for the videoarthroscopic surgical treatment. During the arthroscopy, we evidenced the yellow/brownish ACL, hypertrophy, and preserved tension of its fibers (→ **Fig. 4A** and **4B**). We performed resection of the degenerate part and partial debridement of the compromised fibers of the ACL (→ **Fig. 4C** and **4D**). We did not observe any other associated lesions. The histological study confirmed the diagnostic hypothesis, showing the presence of a diffuse mucoid substance between the collagen fibers. Four weeks

after surgery, the patient already presented symptomatic relief. After 12 and 24 weeks postoperatively, we repeated the clinical evaluation and objectively evidenced the symptomatic improvement reported by the patient without the development of instability (→ **Fig. 5**).

Discussion

Mucoid degeneration of the ACL is still a little-known pathology. It usually affects men between 40 and 50 years of age, and is often confused with partial rupture of the ACL.²⁻⁶

It is determined by interstitial deposits of glycosaminoglycans amid collagen bundles causing ACL hypertrophy, knee pain, and limitation in range of motion, usually limiting the ends of extension or flexion.⁷

Posterior pain affecting the popliteal fossa is the most consistent finding.^{2,4,7} It is attributed to the ACL mass effect on the notch and/or pathological incarceration of the ACL in the posterior femorotibial compartment, and it is present in 80% of the cases followed by the limitation in flexion, which affects around 50% of patients, who do not fully respond to NSAIDs and physiotherapy.^{3,8,9}

Kumar et al.³ were the first to describe the case of a 35-year-old patient who presented with pain in the posterior face of the knee associated with decreased range of motion.

Multiple theories try to explain the pathophysiology of this lesion. The synovial theory suggests that there is an accumulation of synovial fluid through the herniation of the

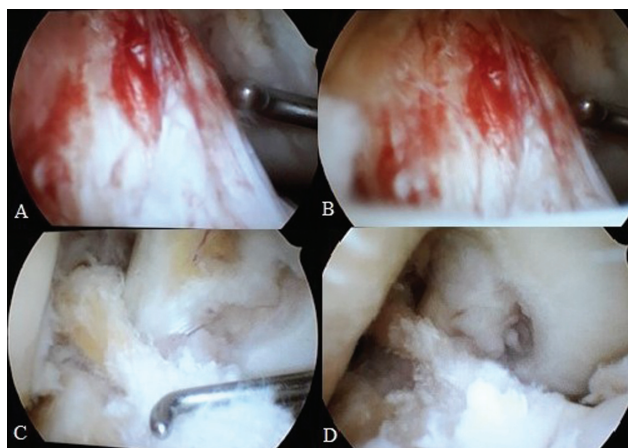


Fig. 4 Perioperative image of the arthroscopy of the right knee (A and B) showing signs of mucoid degeneration of the ACL; (C and D) aspect after debridement and partial resection of the degenerate portion of the ACL.

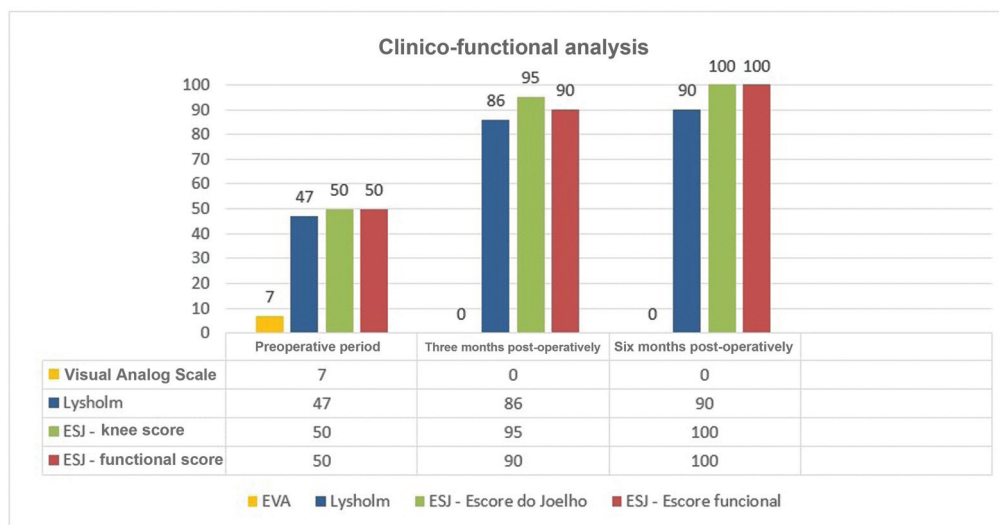


Fig. 5 Graph 1: clinico-functional analysis.

synovial membrane of the ACL. The traumatic theory is based on evidence of glycosaminoglycan secretion by ACL fibroblasts in response to traumatic injuries, and the degenerative theory describes the presence of mucoid tissue as part of the normal aging process of this tissue.^{4,9}

The gold standard test for diagnosis is the MRI. The prevalence in MRI scans ranges from 1.8% to 5.3%.^{2,4} McIntyre et al.⁵ demonstrated that the signs of mucoid ACL degeneration can be confused with rupture of this ligament on the MRI examination, reinforcing the importance of a clinico-radiological correlation for the correct diagnosis.

Fernandes et al.¹ reported that, in this pathology, the ACL is thickened, with intact fibers intertwined with a material of intermediate-to-low signal intensity in T1-weighted images and an intermediate-to-high signal in T2-weighted sequences ("celery stalk" sign) on the MRI, which can be confused with partial ACL ruptures.

The diagnosis should be confirmed histologically with a pathological examination, especially in cases associated with bone erosions. The mucoid lesions contain a brown or yellow basophilic substance, described as thick or dense, containing a high density of glycosaminoglycans.^{2,9}

Arthroscopy is used for both the diagnosis and the definitive treatment.^{2,6} The ACL is characteristically increased in its yellow or brown volume, sometimes without the synovial coating. The ACL fibers are solid, and with usual orientation. The ACL tension is usually normal or even increased. Impingement in the intercondyle can be evidenced during the arthroscopic evaluation, which may explain the extent deficit observed in some patients, as well as the symptoms typically found in cases of meniscal lesions, leading to misdiagnoses.^{4,6}

One of the fears about ACL debridement is the development of postoperative instability. Kumar et al.³ considered total ACL resection a treatment option without resulting in complaints of postoperative instability. However, most authors agree that resection of the mucoid tissue with partial ACL debridement is sufficient.^{2,4,5,7} Dejour et al.¹⁰ reported, in their analysis of 27 patients, the presence of positive

anterior drawer tests in 36% and pivot-shift in 55% of the sample after partial debridement. Lintz et al.² demonstrated 93% of anterior laxity after resection of the mucoid degeneration; however, only 2 out of 29 patients required ACL reconstruction later.

In the case herein reported, there was also no instability after partial ACL resection at a six-month follow-up. There is no evidence in the literature of relapses after resection.

Mucoid degeneration of the ACL should be remembered in the investigation of cases suggestive of partial ruptures associated with posterior knee pain. The performance of MRI scans is elucidative. The pathological study defines the diagnosis. Treatment involves resection of the mucoid material with partial ACL debridement as conservative as possible, with most authors^{3,7,9} reporting good results without postoperative instability.

Financial Support

There was no financial support from public, commercial or non-profit sources.

Conflict of Interests

The authors have no conflict of interests to declare.

References

- Fernandes JL, Viana SL, Mendonça JL, et al. Mucoid degeneration of the anterior cruciate ligament: magnetic resonance imaging findings of an underdiagnosed entity. *Acta Radiol* 2008;49(01): 75-79
- Lintz F, Pujol N, Boisrenoult P, Bargoin K, Beaufils P, Dejour D. Anterior cruciate ligament mucoid degeneration: a review of the literature and management guidelines. *Knee Surg Sports Traumatol Arthrosc* 2011;19(08):1326-1333
- Kumar A, Bickerstaff DR, Grimwood JS, Suvarna SK. Mucoid cystic degeneration of the cruciate ligament. *J Bone Joint Surg Br* 1999; 81(02):304-305
- Bergin D, Morrison WB, Carrino JA, Nallamshetty SN, Bartolozzi AR. Anterior cruciate ligament ganglia and mucoid degeneration:

- coexistence and clinical correlation. *AJR Am J Roentgenol* 2004; 182(05):1283-1287
- 5 McIntyre J, Moelleken S, Tirman P. Muroid degeneration of the anterior cruciate ligament mistaken for ligamentous tears. *Skeletal Radiol* 2001;30(06):312-315
 - 6 Narvekar A, Gajjar S. Muroid degeneration of the anterior cruciate ligament. *Arthroscopy* 2004;20(02):141-146
 - 7 Fealy S, Kenter K, Dines JS, Warren RF. Muroid degeneration of the anterior cruciate ligament. *Arthroscopy* 2001;17(09):E37
 - 8 Hensen JJ, Coerkamp EG, Bloem JL, De Schepper AM. Muroid degeneration of the anterior cruciate ligament. *JBR-BTR* 2007;90(03):192-193
 - 9 Melloni P, Valls R, Yuguero M, Sáez A. Muroid degeneration of the anterior cruciate ligament with erosion of the lateral femoral condyle. *Skeletal Radiol* 2004;33(06):359-362
 - 10 Dejour D, Cohn J, Tavernier T. Anterior Cruciate Ligament Cyst or Spontaneous Mucoide degeneration? Clinical, radiological and histological outcomes. *Rev Chir Orthop Repar Appar Mot* 2005;91(S8):67