



# Intradural Spinal Arachnoid Cyst in a Pediatric Patient: A Case Report

## *Cisto aracnoide espinhal intradural em paciente pediátrico: um relato de caso*

André Bedin<sup>1</sup> Jorge W. J. Bizzi<sup>1</sup> Evelise Vieira Flores<sup>2</sup> Fernando dos Anjos Schmitz<sup>3</sup>  
Cláudia Zanatta<sup>4</sup> Bianca Brinques da Silva<sup>5</sup>

<sup>1</sup> Department of Pediatric Neurosurgery, Hospital Santa Casa de Misericórdia, Porto Alegre, RS, Brazil

<sup>2</sup> Department of Neurosurgery, Hospital de Pronto Socorro de Canoas, Canoas, RS, Brazil

<sup>3</sup> Pediatric Neurosurgery Residency, Hospital Santa Casa de Misericórdia, Porto Alegre, RS, Brazil

<sup>4</sup> Neurosurgery Residency, Hospital Ernesto Dornelles, Porto Alegre, RS, Brazil

<sup>5</sup> Medical School, Hospital Universitário de Canoas, Universidade Luterana do Brasil, Canoas, RS, Brazil

Address for correspondence André Bedin, MD, Serviço de Neurocirurgia Pediátrica, Hospital Santo Antônio da Criança, Porto Alegre, RS, Brazil (e-mail: bedinandre@hotmail.com).

Arq Bras Neurocir 2021;40(2):e183–e185.

### Abstract

The present case reports a 13-year-old patient with an intradural arachnoid cyst, which manifested itself with a sudden loss of strength and sensitivity in the lower and upper limbs and a severe pain in the cervical and thoracic region. On examination, a lesion displayed as an intradural hematoma; however, a laminotomy was performed and it was realized that the lesion was an arachnoid spinal cyst of the cervical-dorsal spine.

### Keywords

- ▶ arachnoid cyst
- ▶ laminotomy
- ▶ spine
- ▶ pediatrics

### Resumo

O presente trabalho relata o caso de um paciente de 13 anos que apresentou um cisto aracnoide intradural espinhal, que se manifestou com uma perda súbita de força e sensibilidade nos membros inferiores e superiores, bem como uma forte dor nas regiões cervical e torácica. Ao exame, a lesão apresentou-se como um hematoma intradural; todavia, ao ser realizada a laminectomia, tratava-se de um cisto aracnoide espinhal da coluna vertebral cérvico-dorsal à direita.

### Palavras-chaves

- ▶ cisto aracnoide
- ▶ laminectomia
- ▶ coluna vertebral
- ▶ pediatria

## Introduction

Spinal arachnoid cysts are uncommon, and intradural cysts are even less common, although the pediatric population is more likely to have an intradural cyst compared with the general

population.<sup>1–3</sup> The intradural cyst consists of an arachnoid bag filled with cerebrospinal fluid, which consists in a benign lesion that is entirely in the dural space.<sup>4,5</sup> The course of the spinal arachnoid cyst is not fully understood, and many authors create theories to explain the pathophysiology.<sup>3</sup>

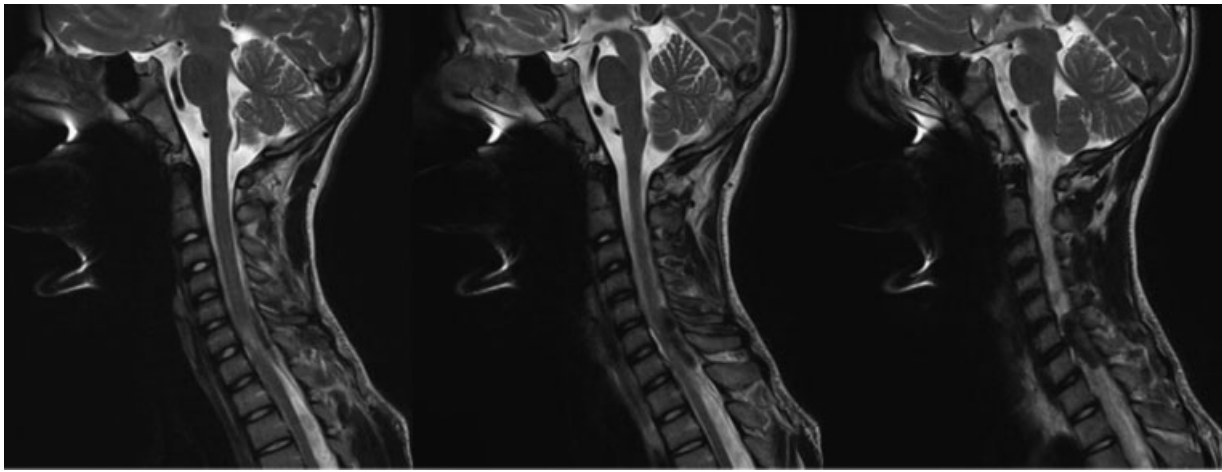
received  
August 6, 2020  
accepted

November 17, 2020  
published online  
January 18, 2021

DOI <https://doi.org/10.1055/s-0040-1722241>.  
ISSN 0103-5355.

© 2021. Sociedade Brasileira de Neurocirurgia. All rights reserved. This is an open access article published by Thieme under the terms of the Creative Commons Attribution-NonDerivative-NonCommercial-License, permitting copying and reproduction so long as the original work is given appropriate credit. Contents may not be used for commercial purposes, or adapted, remixed, transformed or built upon. (<https://creativecommons.org/licenses/by-nc-nd/4.0/>)

Thieme Revinter Publicações Ltda., Rua do Matoso 170, Rio de Janeiro, RJ, CEP 20270-135, Brazil



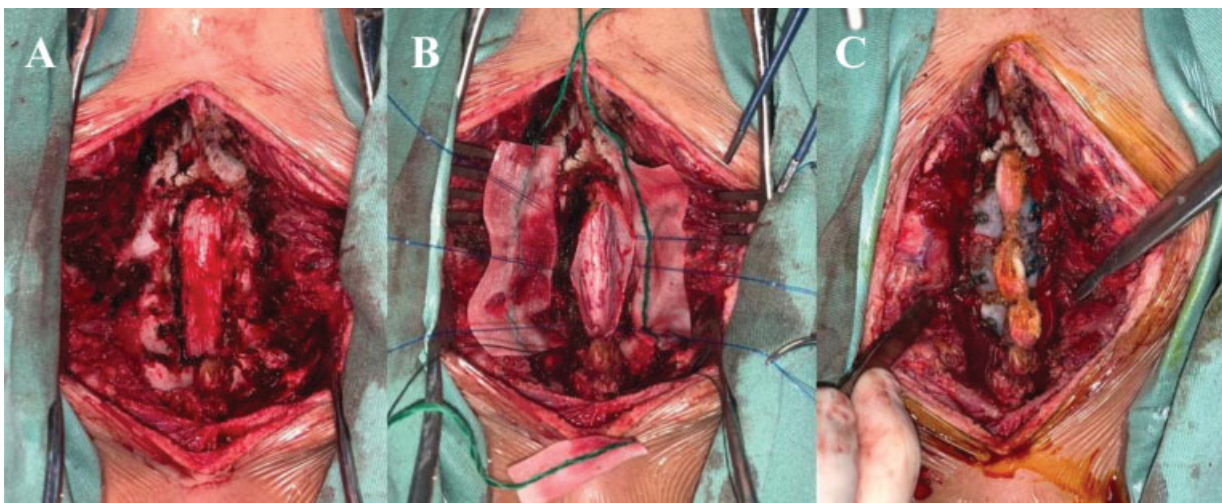
**Fig. 1** Sagittal T2 section shows a lesion in high signal intensity at the right posterolateral level of C6 to D1.

During the first two decades of the patient's life, age and gender do not play an important role in the incidence of the cyst.<sup>1</sup> However, most of the reported cases are single cysts and occur commonly at the level of the thoracic spinal cord, located more often dorsally to the neural elements.<sup>4,6-8</sup>

### Case Report

A 13-year-old male patient arrived at the emergency care unit complaining of sudden back pain in the cervical and thoracic region. At nightfall on the same day, the patient developed severe pain and progressive loss of strength in the legs, resulting in difficulty in walking, followed by loss of sensation, initially in the right lower limb and then in the left lower limb. He was medicated with intravenous symptomatic drugs, however he continued without any improvement in pain. After the patient was forwarded to the hospital, the computed tomography (CT) scan of the cervical and thoracic spine suggested that he had an injury at the C5-C6 level, with a slightly increased density in the vertebral canal. On physical examination, he had hemiplegia in his right lower limb

and weak movement in his left lower limb, with an asymmetric degree of strength (worse on the right). He also had a tingling sensation and decreased bilateral tactile and thermoalgesic sensitivity down to the level of the nipples, strength grade 3 on the right upper limb and grade 2 on the left upper limb. Trauma, as well as similar episodes and symptoms, were denied previously. The patient did not use continuous medications, had never undergone surgery or previous hospitalizations. After performing cervical and dorsal spine magnetic resonance imaging (MRI) (► **Fig. 1**) with weighted sequences in T1 and T2 in the axial and sagittal planes, an expansive lesion was observed in the right posterolateral portion of the spinal canal in an epidural situation, in the C6, C7 and D1 segment, measuring  $\sim 3.2 \times 1.3$  cm (largest craniocaudal diameter), hypointense in the T2-weighted sequence and slightly in hypersignal in T1, compatible with the diagnostic hypothesis of hematoma. This injury had a compressive effect, with alteration in the signal intensity of the adjacent spinal cord (edema). The laminotomy procedure of the C7-D2 segment was performed (► **Fig. 2**), and when entering the arachnoid membrane there



**Fig. 2** (A) Bulging of dural bag at C5-D1. (B). Exposure of the spinal cord with the rightmost arachnoid space, after communication and resection of the cyst. C. Final design after laminotomy with microplates at C5-D1.

was a large spillage of cerebrospinal fluid under high pressure. It was observed that the lesions consisted of a cystic intradural arachnoid lesion and the resection was performed. The anatomopathological result indicated a tiny fragment of connective tissue, apparently derived from the arachnoid, in continuity with some red blood cells. In the postsurgical period, the patient continually improved the pain, the strength and the sensitivity.

## Discussion

Arachnoid cysts are often attributed to congenital defects, therefore being defined as the main origin by the authors.<sup>1,5,9</sup> Although their etiology is inconsistent, it is believed that some of these cysts are derived from trauma, hemorrhage, anesthetic procedures and secondary to inflammation, such as meningitis and arachnoiditis.<sup>10</sup> Despite these cysts being frequently asymptomatic, they eventually are able to produce symptoms when they compress the spinal cord and/or nerve roots, both suddenly and in a progressive manner.<sup>8</sup> They are able to cause pain, weakness, sensory changes, and gait disorders.<sup>11</sup> Large cysts located in the lumbar spine can also lead to loss of bladder and/or intestine control and cramps.<sup>4</sup>

In cases of symptomatic injuries, surgical treatment must occur and is usually performed by simple fenestration or limited laminotomy. The purpose of surgery is neural decompression and prevention of cyst replenishment. Therefore, the cyst is completely dried out and the communication with the arachnoid space is closed, repairing the dural failure.<sup>11-13</sup> If left untreated, spinal cysts would cause permanent severe neurological damage. In the case of asymptomatic individuals, is indicated the constant monitoring of the cyst.

Neurological deficits from arachnoid cysts are treatable. Surgical intervention shows excellent postoperative results. Most patients present complete or significant recovery, and many remain stable, even when symptoms have been present for a long time.<sup>1,14,15</sup>

About the negative findings from this pathology, the most invasive opening in repeated laminectomies is related to complications such as kyphoscoliosis.<sup>2</sup> The patient may also develop syringomyelia and slow progressive myelopathy.<sup>6,8,11</sup>

## Conclusion

Arachnoid cysts of the spine are lesions of uncertain etiology and may not have the characteristics of a cerebrospinal fluid sign on MRI and simulate other pathologies. What is clearly known is that cysts that cause compression of the spinal cord and surrounding nerves cause significant neurological deficits

in the patient. Therefore, it is essential to perform a surgical procedure as soon as possible to obtain the best possible result for the condition, which is complete neurological recovery.

## Conflict of Interests

The authors have no conflict of interests to declare.

## References

- McComb JG. Arachnoid Cysts, Clinical and Surgical Management, 2018, Pages 239-251
- Ying GY, Chang KS, Tang YJ, Cheng CY, Zhu YJ, Chen CM. Utilizing real-time contrast medium to detect the fistula of giant spinal arachnoid cyst and treat with minimal invasive surgery. *BMC Surg* 2019;19(01):11
- Bond AE, Zada G, Bowen I, McComb JG, Krieger MD. Spinal arachnoid cysts in the pediatric population: report of 31 cases and a review of the literature. *J Neurosurg Pediatr* 2012;9(04):432-441
- Baba T, Koyanagi I, Yoshifuji K, Murakami T, Houkin K. Pulsatile wall movement of spinal arachnoid cyst deteriorates spinal cord symptoms: report of three cases. *Acta Neurochir (Wien)* 2010;152(07):1245-1249
- Hughes G, Ugokwe K, Benzel EC. A review of spinal arachnoid cysts. *Cleve Clin J Med* 2008;75(04):311-315
- Logan C, Asadi H, Kok HK, et al. Arachnoid Cysts - Common and Uncommon Clinical Presentations and Radiological Features. *J Neuroimaging Psychiatry Neurol* 2016;1(02):79-84
- Takagaki T, Nomura T, Toh E, Watanabe M, Mochida J. Multiple extradural arachnoid cysts at the spinal cord and cauda equina levels in the young. *Spinal Cord* 2006;44(01):59-62
- Lee HJ, Cho DY. Symptomatic spinal intradural arachnoid cysts in the pediatric age group: description of three new cases and review of the literature. *Pediatr Neurosurg* 2001;35(04):181-187
- Nath PC, Mishra SS, Deo RC, Satapathy MC. Intradural Spinal Arachnoid Cyst: A Long-Term Postlaminectomy Complication: A Case Report and Review of the Literature. *World Neurosurg* 2016;85:367.e1-367.e4
- Kriss TC, Kriss VM. Symptomatic spinal intradural arachnoid cyst development after lumbar myelography. Case report and review of the literature. *Spine* 1997;22(05):568-572
- Moses ZB, Friedman GN, Penn DL, Solomon IH, Chi JH. Intradural spinal arachnoid cyst resection: implications of duraplasty in a large case series. *J Neurosurg Spine* 2018;28(05):548-554
- Krings T, Lukas R, Reul J, et al. Diagnostic and therapeutic management of spinal arachnoid cysts. *Acta Neurochir (Wien)* 2001;143(03):227-234, discussion 234-235
- Bitaraf MA, Zeinalizadeh M, Meybodi AT, Meybodi KT, Habibi Z. Multiple extradural spinal arachnoid cysts: a case report and review of the literature. *Cases J* 2009;2:7531
- Kumar K, Malik S, Schulte PA. Symptomatic spinal arachnoid cysts: report of two cases with review of the literature. *Spine* 2003;28(02):E25-E29
- Evangelou P, Meixensberger J, Bernhard M, et al. Operative management of idiopathic spinal intradural arachnoid cysts in children: a systematic review. *Childs Nerv Syst* 2013;29(04):657-664