



# Video-Assisted Thoracoscopic Segmentectomy for Deep and Peripheral Small Lung Cancer

Satoshi Takamori<sup>1</sup> Hiroyuki Oizumi<sup>1</sup> Jun Suzuki<sup>1</sup> Katsuyuki Suzuki<sup>1</sup> Takanobu Kabasawa<sup>2</sup>

<sup>1</sup>Department of Surgery II, Faculty of Medicine, Yamagata University, Yamagata, Japan

<sup>2</sup>Department of Pathological Diagnostics, Faculty of Medicine, Yamagata University, Yamagata, Japan

Address for correspondence Satoshi Takamori, MD, Department of Surgery II, Faculty of Medicine, Yamagata University, 2-2-2 Iida-Nishi, Yamagata 990-9585, Japan  
(e-mail: s-takamori@med.id.yamagata-u.ac.jp).

Thorac Cardiovasc Surg 2022;70:233–238.

## Abstract

**Background** We aimed to retrospectively compare the long-term prognosis and recurrence after segmentectomy between nonsmall cell lung cancer (NSCLC) patients with deep and peripheral lesions.

**Methods** Data were extracted for 85 lobectomy-tolerable NSCLC patients with tumors measuring  $\leq 2$  cm, who underwent video-assisted thoracoscopic segmentectomy with curative intent during January 2006 to December 2014. Tumor location was determined by the surgeon using thin-slice (1 mm) and three-dimensional computed tomography. Overall and recurrence-free survival was compared between patients with peripheral and deep lesions using univariate and multivariate Cox proportional hazard models. The indications for segmentectomy included NSCLC measuring  $\leq 2$  cm and consolidation/tumor ratio  $\leq 20\%$ , solid NSCLC  $\leq 1$  cm, and indeterminate nodule  $\leq 1.5$  cm.

**Results** No recurrence of peripheral and deep lesions was noted. The 5-year overall survival was 96.4% for all patients, and 100 and 95.3% for patients with deep and peripheral lesions, respectively. There was no significant difference between the overall survival rates associated with the deep and peripheral lesions (95% confidence interval [CI], 89.5–98.8, nonsignificant, 86.4–98.4, respectively;  $p = 0.189$ ). In a multivariate analysis, the American Society of Anesthesiologists score (hazard ratio [HR], 13.30; 95% CI, 1.31–210.36;  $p = 0.028$ ) and histology (HR, 0.03; 95% CI, 0.00–0.32;  $p = 0.037$ ) were independent prognostic factors for overall survival; tumor location was not a prognostic factor.

**Conclusions** When video-assisted thoracoscopic segmentectomy with curative intent was performed with sufficient surgical margins, the location of small NSCLC did not affect recurrence risk and prognosis. Video-assisted thoracoscopic segmentectomy for small NSCLC is acceptable, regardless of the tumor location.

## Keywords

- ▶ small/VATS
- ▶ lung cancer
- ▶ outcomes

## Introduction

Indications for the use of video-assisted thoracoscopic surgery (VATS) segmentectomy are recently becoming more widespread because of the effectiveness and minimal invasiveness

of the procedure. The results of sublobar resection (segmentectomy or wedge resection) have been reported to be relatively good, and segmentectomy for small lung cancer is a potentially acceptable technique.<sup>1–8</sup> Moreover, in recent years, most ground-glass opacity-dominant nodules have been shown to

received  
September 29, 2020  
accepted after revision  
November 18, 2020  
published online  
February 4, 2021

DOI <https://doi.org/10.1055/s-0040-1722172>.  
ISSN 0171-6425.

© 2021. The Author(s).

This is an open access article published by Thieme under the terms of the Creative Commons Attribution-NonDerivative-NonCommercial-License, permitting copying and reproduction so long as the original work is given appropriate credit. Contents may not be used for commercial purposes, or adapted, remixed, transformed or built upon. (<https://creativecommons.org/licenses/by-nc-nd/4.0/>)

Georg Thieme Verlag KG, Rüdigerstraße 14, 70469 Stuttgart, Germany

be adenocarcinoma in situ or minimally invasive adenocarcinoma, both of which have good pathological prognoses.<sup>9,10</sup> Therefore, the procedure for small nodules may change from lobectomy to limited resection. When the tumor is in the deep parenchyma, identifying the tumor location and securing the surgical margin is sometimes difficult with wedge resection because the cutting depth cannot be identified during surgery. Wedge resection may be inadequate and difficult for most primary lung cancers and nodules located deep in the lung. In the case of deeply located lesions, such as small pure ground-glass nodule (GGN), lobectomy may be overly invasive and result in the removal of a relatively large volume of healthy lung tissue. It may result in a poor quality of postoperative life, which reduces the chance for further resections because these patients survive long enough to be at risk for a second or even a third NSCLC. Consequently, a large extent of initial resection limits the surgical options for subsequent resections.<sup>1,11</sup> Sublobar resection (especially segmentectomy) is usually performed for peripherally located NSCLC.

The two ongoing randomized trials (NCT00499330 and JCOG0802/WJOG4607L) required that the center of the tumor be in the outer third of the lung. However, there have been few reports on the long-term effects of segmentectomy on deep-seated early NSCLC. Segmentectomy using three-dimensional (3D) reconstruction of computed tomography (CT) for deep lesions of early NSCLC can ensure anatomical localization of the tumor and reliable resection.<sup>12–15</sup> In addition, there is also the possibility that the outcome of the segmentectomy of deep lesions may be equivalent to that of peripherally located NSCLC when a sufficient surgical margin is secured.<sup>14,15</sup> This retrospective study investigated long-term prognosis and recurrence and analyzed whether segmentectomy was acceptable regardless of tumor location in patients with small NSCLC.

## Patients and Methods

### Patient Selection

We retrospectively reviewed the records of 86 lobectomy-tolerable NSCLC patients with tumors measuring  $\leq 2$  cm between January 2006 and December 2014. Eighty-five patients underwent VATS anatomical segmentectomy with curative intent. The study protocol was approved by the Ethics Committee of our university (#2020–130). In this retrospective analysis, the Ethics Committee of our university waived the need for patient consent. Indications for segmentectomies performed with curative intent at our hospital were defined as NSCLC  $\leq 2$  cm and consolidation/tumor ratio  $\leq 20\%$ , solid NSCLC  $\leq 1$  cm, and indeterminate nodule  $\leq 1.5$  cm. We defined “indeterminate nodules” as nodules that were not diagnosed preoperatively.<sup>16</sup> The patients had a good pulmonary function, enough to allow and tolerate lobectomy for the management of their disease. The location of the tumor was determined by the surgeon using a thin-sliced (1 mm) CT and 3D reconstruction of CT. Peripheral and deep lesions were defined as tumors located in the outer one-third of the thoracic cavity and the hilar two-thirds of the thoracic cavity, respectively.

### Follow-Up

Follow-up visits took place every 3 or 6 months until 12 months after the operation, and every 6 months or yearly thereafter. Standard follow-up consisted of a history, clinical examination, and chest roentgenography. Routine CT of the chest was performed every 6 months or yearly. The median follow-up time was 7.3 years for the entire cohort.

### Recurrence

Locoregional recurrence was defined as evidence of tumor within the same lobe or ipsilateral hilar and mediastinal lymph nodes (LNs) with the same histologic type as the primary tumor. Distant recurrence was defined as evidence of a tumor of the same histologic type as the primary tumor in another lobe, pleural space, or elsewhere outside the hemithorax.

### Operative Procedure

In cases of suspected malignancy, we designed the resection lines with a surgical margin larger than the tumor diameter (at least 1 cm or more even for a tumor smaller than 1 cm). In cases where it was difficult to preserve the margin in a single segment resection, we performed an extended segmentectomy by dissecting the parenchyma across the intersegmental vein or by combined segmentectomy with the adjacent sub-segments. We performed LN sampling instead of dissection in the case of lung cancer presenting with pure GGNs and mediastinal LN dissection in solid tumors and tumors with part-solid GGN.

### Image Analysis

A thoracic surgeon evaluated the images to determine whether the center of the tumor was located from the hilum to the outer third or deep in the lung. To further clarify the tumor location, a 3D simulation as well as the axial, coronal, and sagittal observation of the thin-sliced CT images was used. Complete resection of nonpalpable tumors was attempted by performing segmentectomy for tumors located between intersegmental veins on a preoperative 3D CT simulation. Moreover, when it was assumed that simple segmentectomy alone would yield inadequate surgical margins ( $< 1$  cm) or a margin-to-tumor-diameter ratio  $< 1$  was anticipated, segmentectomy combined with adjacent subsegmentectomy was planned.

### Statistical Analyses

Continuous data are reported as median with interquartile range and were compared using the Mann–Whitney U test. Categorical and count data are presented as frequencies and percentages and were compared using the  $\chi^2$  test or Fisher's exact test. Overall survival (OS) was defined as the time in months from the date of surgery until the last follow-up or date of death. OS was calculated using Kaplan–Meier estimates. Univariate and multivariate analyses for OS were performed using Cox regression modeling stratified by site. A  $p$ -value  $< 0.05$  was considered statistically significant. Statistical analyses were performed using JMP 14 (SAS Institute Inc., Cary, North Carolina, United States).

**Table 1** Characteristics of patients with NSCLC having tumors measuring  $\leq 2$  cm who underwent segmentectomy performed with curative intention

Characteristics	All cases (n = 85)	Deeply (n = 21)	Peripheral (n = 64)	Deeply vs. peripheral (p-value)
Age Median (IQR)—years	64.0 (58.5–72.0)	62.0 (55.0–71.0)	64.5 (59.2–72.7)	0.355
Sex—n (%) Male/Female	36 (42.3)/49 (57.6)	6 (7.1)/15 (17.6)	30 (35.3)/34 (40.0)	0.203
Nodule diameter Median (IQR)—cm	1.4 (1.1–1.6)	1.3 (1.1–1.7)	1.4 (1.1–1.6)	0.922
ASA score Median (IQR)	2 (1–2)	1 (1–2)	2 (1–2)	0.183
Charlson comorbidity index Median (IQR)	0 (0–0.5)	0 (0–0.5)	0 (0–0.7)	0.962
C/T ratio—n (%) $\leq 50\%$ / $> 50\%$	71 (83.5)/14 (16.4)	18 (21.2)/3 (3.5)	53 (62.3)/11 (12.9)	1.000
Lobe of nodule—n (%) RUL/RML/RLL LUL/LLL	36 (42.3)/1 (1.2)/14 (16.4) 21 (24.7)/13 (15.3)	8 (9.4)/0 (0.0)/3 (3.5) 3 (3.5)/7 (8.2)	28 (32.9)/1 (1.2)/11 (12.9) 14 (16.5)/ 10 (11.7)	0.846
Histology—n (%) Adeno/SqCC	81 (94.1)/4 (5.9)	20 (23.5)/1 (1.2)	60 (70.6)/4 (4.7)	1.000
p-stage (TNM 8th)—n (%) stage 0/IA1 or 1A2	51 (60.0)/34 (40.0)	14 (16.4)/7 (8.2)	37 (43.5)/27 (31.7)	0.609
All recurrences—n (%)	0 (0)	0 (0)	0 (0)	1.000
Follow-up duration—years Median (IQR)	7.3 (5.8–9.3)	8.7 (6.6–10.8)	6.9 (5.6–8.9)	0.044
Lymph node dissection—n (%) ND0/ND1/ND2	33 (38.8)/46 (54.1)/6 (7.0)	8 (9.4)/12 (14.1)/1 (1.2)	25 (29.4)/34 (40.0)/5 (5.8)	0.878
Bleeding—g Median (IQR)	50 (3–107)	57 (6–150)	40 (3–104)	0.208
Operation time—months Median (IQR)	177 (145–216)	176 (145–217)	179 (145–211)	0.862
Complications—n Clavien–Dindo grade $>II$	4	1	3	1.000
90-day mortality—n	0	0	0	1.000

Abbreviations: Adeno, adenocarcinoma; ASA, American Society of Anesthesiologists; IQR, interquartile range, LLL, left lower lobe; LUL, left upper lobe; NSCLC, nonsmall cell lung cancer; RLL, right lower lobe; RML, right middle lobe; RUL, right upper lobe; SqCC, squamous cell carcinoma.

## Results

We finally included NSCLC patients who underwent segmentectomy with systematic LN dissection or sampling from January 2006 to December 2014. The baseline characteristics of all patients are presented in ►Table 1. Detailed segmentectomy procedures are shown in ►Table 2. Follow-up time was different between patients with deep lesions and those with peripheral lesions ( $p = 0.044$ ). There were no significant differences in the characteristics between peripheral and deep lesions. The mean age of all patients was 64.0 years. The percentage of male to female was 42.3 and 57.6% in the peripheral and deep lesions groups, respectively. On preoperative CT, ~46 cases (54.1%) of the tumors presented as pure GGN; the tumor size was 1.4 cm. Most of the patients were

pathologically diagnosed with lung adenocarcinoma (80 cases, 94.1%). The pathological stage (the 8th TNM) was IA (34 cases, 40.0%, T1a or T1b N0M0) and 0 (51 cases, 60.0%, Tis N0M0). Complications (higher than Clavien–Dindo grade III, only air leakage) occurred in 4.7% cases. None of the cases had mortality within 90 days, and none had any recurrence.

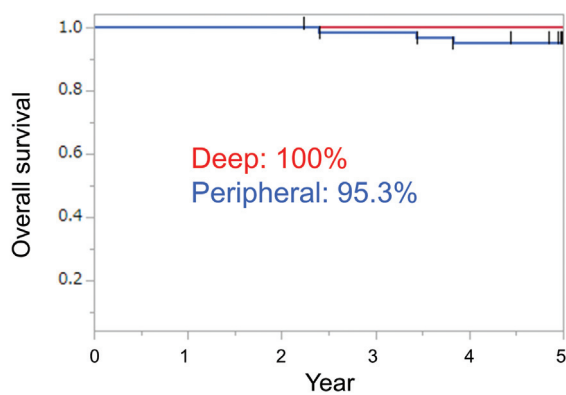
The 5-year cancer-specific survival was 100% (95% confidence interval [CI], not significant) for all cases, including deep lesions and peripheral lesions. The 5-year OS was 96.4, 100, and 95.3% for all cases, deep lesions, and peripheral lesions, respectively (95% CI, 89.5–98.8, not significant, 86.4–98.4, respectively;  $p = 0.189$ ; ►Figs. 1 and 2).

The univariate and multivariable analyses for OS are presented in ►Table 3. In univariate analysis (►Table 3), the American Society of Anesthesiologists (ASA) score (hazard ratio

**Table 2** Details regarding the segmentectomy procedures

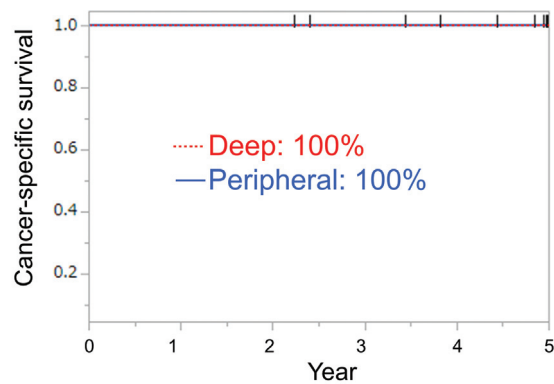
Right	n	Left	n
S1	11	S1 + 2	6
S2	13	S3	1
S3	4	S3 + 4	1
S6	2	S4	1
S8	2	S4 + 5	4
S10	2	S6	3
S1b	1	S8	2
S2b	1	S9	1
S4a	1	S1 + 2a	1
S6c	1	S1 + 2c	1
S8a	1	S3ab	1
S8b	1	S4a	1
S1a + 2a	1	S8a	1
S1b + 3a	1	S1 + 2bc + 4a	1
S1b + 3	1	S6 + <sup>aa</sup> + 8a	1
S2 + 3a	1	S6b + 8a + 9a	1
S6 + 8a	1	S8a + <sup>aa</sup>	1
S2a + 3a	1	S6 + 10	1
S3 + 1bii	1	S1 + 2 + 3	2
S6 + <sup>aa</sup> + 8a	1	S1 + 2 + 3 + 6	1
S6 + <sup>aa</sup> + 8a + 9a	1	S8 + 9 + 10	1
S6 + 8a + 9a + 10a + <sup>aa</sup>	1		
S9 + 10	1		
S7 + 8 + 9 + 10	1		

<sup>a</sup>Subsuperior segment: between S6 and the basal segment.



**Fig. 1** Five-year overall survival.

[HR], 9.34; 95% CI, 2.25–47.29;  $p = 0.002$ ), histology (HR, 0.03; 95% CI, 0.00–0.20;  $p < 0.001$ ), and comorbidity index (HR, 3.11; 95% CI, 1.42–6.60;  $p = 0.006$ ) were significantly associated with OS. In multivariable analysis (► **Table 3**), ASA score (HR, 13.30; 95% CI, 1.31–210.36;  $p = 0.028$ ), histology (HR, 0.03; 95% CI, 0.00–0.32;  $p = 0.037$ ) were independent prognostic factors for OS after segmentectomy. Tumor localization (HR, NS; 95% CI,



Patients at risk	21	21	21	20	20	20
	64	64	64	63	61	56

**Fig. 2** Five-year cancer-specific survival. Red and blue line overlap and are therefore not discriminable.

NS;  $p = 0.999$ ) was not a prognostic predictor in this analysis of segmentectomy for small-sized ( $\leq 2$  cm) NSCLC.

### Discussion

The present study elucidated the relationship between tumor location and prognosis after intentional segmentectomy in patients with small NSCLC who could tolerate lobectomy. VATS segmentectomy may be acceptable for small-sized NSCLC located in the parenchyma when the design of resection is planned appropriately. Local recurrences, such as surgical stumps of lung parenchyma and intrapulmonary metastasis of the preserved lobe—although rare after lobectomy—are significant concerns after segmentectomy. In this study, we did not observe any recurrence, and the prognosis was good, regardless of tumor location.

Previously, we reported the use of 3D CT images for surgical simulation during anatomic thoracoscopic pulmonary segmentectomy and the effectiveness of this technique. We performed thoracoscopic anatomic lung segmentectomy using 3D CT simulation without tumor markings for non-palpable and nonvisualized small lung nodules, and there was no local recurrence.<sup>12–15</sup> We performed a thoracoscopic anatomical lung segmentectomy using a 3D CT simulation, and there was no recurrence.

Segmentectomy is useful in terms of lung preservation, but complications, such as air leakage, are of concern. Suzuki et al compared segmentectomy with lobectomy, and reported that complications (more than Clavien–Dindo grade III) occurred in 4.5 and 4.9% cases, respectively, and air leakage (more than Clavien–Dindo grade III) occurred in 0.2 and 0.5% cases, respectively.<sup>17</sup> In our study, complications (air leakage, more than Clavien–Dindo grade III) occurred in 4.7% cases. Therefore, the frequency of complications was acceptable.

A recent meta-analysis found no significant difference in survival between patients receiving segmentectomy and those with wedge resection for NSCLC  $\leq 1$  cm.<sup>18</sup> Koike et al retrospectively reviewed 223 patients with NSCLC  $\leq 2$  cm who underwent intentional segmentectomy.<sup>19</sup> The result

**Table 3** Univariable and multivariable Cox proportional hazard regression model analysis for overall survival

Cox proportional hazard model for overall survival	Univariable analysis		Multivariable analysis		
	Variable	HR (95% CI)	p-Value	HR (95% CI)	p-Value
Age	1.04 (0.95–1.15)	0.338			
Nodule diameter	0.35 (0.02–4.34)	0.423			
C/T ratio ( $\leq 0.5$ vs. $> 0.5$ )	0.26 (0.04–1.56)	0.171			
Histology (adeno vs. SqCC)	0.03 (0.00–0.20)	< 0.001	0.03 (0.00–0.32)	0.037	
ASA score	9.34 (2.25–47.29)	0.002	13.30 (1.31–210.36)	0.028	
Comorbidity index	3.11 (1.42–6.60)	0.006	0.62 (0.17–2.23)	0.448	
Tumor location (peripheral vs. deep)	NS	0.999			

Abbreviations: Adeno, adenocarcinoma; ASA, American Society of Anesthesiologists; CI, confidence interval; HR, hazard ratio; NS, not specified; SqCC, squamous cell carcinoma.

suggested that the extent of LN resection (sampling or systematic dissection) was not a significant predictor for both recurrence and poor OS. Similar results were presented for locoregional recurrence-free survival in another study.<sup>8</sup> Therefore, segmentectomy may be acceptable for small NSCLC.

In this study, segmentectomy for small NSCLC resulted in a good prognosis regardless of peripheral or deep lesions. As shown in the previous studies, sublobar resection can be performed for small NSCLC, and therefore, segmentectomy may be an important treatment option.

This study has several limitations. First, this is a single-center retrospective analysis with a small number of cases. We plan to accumulate and examine more cases in the future. Second, the results may be misleading because there were many cases with pure GGNs and few cases with solid lesions, which made it impossible to classify the prognosis with solid lesions alone. The prognosis of a solid lesion of 1 cm, excluding pure GGN, should be considered.

In this study cohort, when segmentectomy was performed in lobectomy-tolerable patients to maintain sufficient surgical margin, the tumor localization of small NSCLC did not affect the recurrence risk and prognosis, and we could perform segmentectomy safely for deep lesions. Therefore, the choice of procedure at our institute in this study period was appropriate. Segmentectomy for small NSCLC is acceptable and may be considered regardless of tumor location. Finally, we reached the above conclusions based on NSCLC patients at a single center, but whether the conclusions would represent the whole population or Western populations requires further investigation. Therefore, direct evidence from the two trials (JCOG0802/WJOG4607L and NCT00499330) is definitively required.

#### Clinical Registration Number

The study protocol was approved by the Ethics Committee of our university (#2020–130).

#### Funding

The research reported in this publication was not supported by any external funding or grant.

#### Conflicts of Interest

None declared.

#### Acknowledgments

None.

#### References

- Okada M, Koike T, Higashiyama M, Yamato Y, Kodama K, Tsubota N. Radical sublobar resection for small-sized non-small cell lung cancer: a multicenter study. *J Thorac Cardiovasc Surg* 2006;132(04):769–775
- Subramanian M, McMurry T, Meyers BF, Puri V, Kozower BD. Long-term results for clinical-stage IA lung cancer: comparing lobectomy and sublobar resection. *Ann Thorac Surg* 2018;106(02):375–381
- Sugi K, Kobayashi S, Sudou M, Sakano H, Matsuda E, Okabe K. Long-term prognosis of video-assisted limited surgery for early lung cancer. *Eur J Cardiothorac Surg* 2010;37(02):456–460
- Campione A, Ligabue T, Luzzi L, et al. Comparison between segmentectomy and larger resection of stage IA non-small cell lung carcinoma. *J Cardiovasc Surg (Torino)* 2004;45(01):67–70
- El-Sherif A, Gooding WE, Santos R, et al. Outcomes of sublobar resection versus lobectomy for stage I non-small cell lung cancer: a 13-year analysis. *Ann Thorac Surg* 2006;82(02):408–415, discussion 415–416
- Okada M, Mimura T, Ikegaki J, Katoh H, Itoh H, Tsubota N. A novel video-assisted anatomic segmentectomy technique: selective segmental inflation via bronchofiberoptic jet followed by cautery cutting. *J Thorac Cardiovasc Surg* 2007;133(03):753–758
- Wisnivesky JP, Henschke CI, Swanson S, et al. Limited resection for the treatment of patients with stage IA lung cancer. *Ann Surg* 2010;251(03):550–554
- Kodama K, Higashiyama M, Okami J, et al. Oncologic outcomes of segmentectomy versus lobectomy for clinical T1a N0 M0 non-small cell lung cancer. *Ann Thorac Surg* 2016;101(02):504–511
- Travis WD, Brambilla E, Noguchi M, et al. International association for the study of lung cancer/American Thoracic Society/European Respiratory Society international multidisciplinary classification of lung adenocarcinoma. *J Thorac Oncol* 2011;6(02):244–285
- Asamura H, Hishida T, Suzuki K, et al; Japan Clinical Oncology Group Lung Cancer Surgical Study Group. Radiographically determined noninvasive adenocarcinoma of the lung: survival outcomes of Japan Clinical Oncology Group 0201. *J Thorac Cardiovasc Surg* 2013;146(01):24–30
- Martini N, Bains MS, Burt ME, et al. Incidence of local recurrence and second primary tumors in resected stage I lung cancer. *J Thorac Cardiovasc Surg* 1995;109(01):120–129

- 12 Oizumi H, Kanauchi N, Kato H, et al. Total thoracoscopic pulmonary segmentectomy. *Eur J Cardiothorac Surg* 2009;36(02):374-377, discussion 377
- 13 Oizumi H, Kanauchi N, Kato H, et al. Anatomic thoracoscopic pulmonary segmentectomy under 3-dimensional multidetector computed tomography simulation: a report of 52 consecutive cases. *J Thorac Cardiovasc Surg* 2011;141(03):678-682
- 14 Kato H, Oizumi H, Suzuki J, Hamada A, Watarai H, Sadahiro M. Thoracoscopic anatomical lung segmentectomy using 3D computed tomography simulation without tumour markings for non-palpable and non-visualized small lung nodules. *Interact Cardiovasc Thorac Surg* 2017;25(03):434-441
- 15 Kato H, Oizumi H, Inoue T, et al. Port-access thoracoscopic anatomical lung subsegmentectomy. *Interact Cardiovasc Thorac Surg* 2013;16(06):824-829
- 16 Schuchert MJ, Abbas G, Awais O, et al. Anatomic segmentectomy for the solitary pulmonary nodule and early-stage lung cancer. *Ann Thorac Surg* 2012;93(06):1780-1785, discussion 1786-1787
- 17 Suzuki K, Saji H, Aokage K, et al; West Japan Oncology Group Japan Clinical Oncology Group. Comparison of pulmonary segmentectomy and lobectomy: safety results of a randomized trial. *J Thorac Cardiovasc Surg* 2019;158(03):895-907
- 18 Ghanem S, El Bitar S, Hossri S, Weerasinghe C, Atallah JP. What we know about surgical therapy in early-stage non-small-cell lung cancer: a guide for the medical oncologist. *Cancer Manag Res* 2017;9:267-278
- 19 Koike T, Koike T, Yamato Y, Yoshiya K, Toyabe S. Prognostic predictors in non-small cell lung cancer patients undergoing intentional segmentectomy. *Ann Thorac Surg* 2012;93(06):1788-1794