

Application of Double-Threaded Locking Adaptation Plates used to Repair a Radius and Ulna Fracture in a Domestic Rabbit (*Oryctolagus Cuniculus*)

Anthony Malak¹ Andrew S. Levien¹

¹Veterinary Specialists of Sydney, Miranda, New South Wales, Australia

Address for correspondence Anthony Malak, Veterinary Specialists of Sydney, 106 Parraweena Road, Miranda, New South Wales, Australia (e-mail: anthonyinh@gmail.com).

VCOT Open 2020;3:e182–e186.

Abstract

Keywords

- ▶ locking plates
- ▶ radius
- ▶ ulna
- ▶ rabbit
- ▶ fracture

Objective This study is a case description of the clinical application of locking plates to repair fractures in the radius and ulna of a 9-month-old, male domestic rabbit.

Study Design This study is a case report.

Results Double-threaded locking adaptation plates of 1.5 mm were fixated to the radius and ulna of the rabbit using the principles of orthogonal plating. Radiographs of the left radius and ulna were obtained at 8 weeks postoperatively depicting complete osseous union of the fracture and no implant complications were observed.

Clinical Significance The authors describe the first clinical report of 1.5 mm locking adaptation plates having been used in repairing radius and ulna fractures in a domestic rabbit.

Introduction

Bone fractures are an important and common problem in the domestic rabbit (*Oryctolagus cuniculus*); however, there is little research available on methods of treatment.¹

Causes of fractures in the rabbit occur from a variety of reasons including handling errors, neoplasia and cage injuries; however, the majority occurs with no known cause.^{1,2} Radial and ulnar fractures are recognized as being one of the more prevalent long bone fractures making up 17% of all long bone fractures in the rabbit.² Fractures in the radius and ulna are frequently present in the distal and diaphyseal regions of the bone.^{1,2}

Fractures in the radius and ulna have been treated by external skeletal fixators, transfixation pin splinting, external coaptation and amputation.^{3–5} External skeletal fixator has been the most common treatment option in rabbit long bones due to the brittle nature of these bones making them historically difficult to surgically repair otherwise.^{6,7} Moreover, the absence of plates and screws necessary for internal fixation of thin, short bones such as the radius and ulna renders treatment of these fractures difficult.^{1,3,5}

Previously, clinical reports in the use of internal fixation with plating have been limited to one tibia and four femurs where only one minor complication was reported.^{3,8} Furthermore, tibial fracture models repaired with bone plating have shown greater strength and improved bone healing speed in relation to external skeletal fixator.⁹ The recent availability of 1.5 mm double-threaded locking adaptation plates (LAPs) has allowed for treatment of radial and ulna fractures in toy and miniature breed dogs with encouraging outcomes.¹⁰ These plates offer several advantages to conventional compression plates.¹¹ These advantages include reduced need for plate contouring and secondary loss of reduction is mitigated by axial and angular stability.^{11,12} Locking plates were initially indicated for use in osteoporotic femurs in female humans as the brittle bone made the use of traditional compression plates problematic.^{11–13} A recent publication of a laboratory fracture model described the repair of the radius and ulna in the domestic rabbit using locking plate systems and concluded that locking plates are sufficient for fracture stabilization.¹⁴

Ensuring structural rigidity of a repair is imperative in mitigating implant failure. One technique which has been widely used within dogs and cats to reduce plate strain as

received
April 27, 2020
accepted after revision
October 26, 2020

DOI <https://doi.org/10.1055/s-0040-1721662>.
ISSN 2625-2325.

© 2020 Georg Thieme Verlag KG
Rüdigerstraße 14, 70469 Stuttgart,
Germany

License terms



well as increase overall structural strength of a repair is orthogonal plating.^{15–17} A laboratory fracture model of the radius and ulna of cats showed that when two locking compression plates were fixated orthogonally, the construct had a significantly higher failure load than other radial or dual bone fixation methods.¹⁵ To our knowledge, orthogonal plating by means of locking plate fixation of both the radius and ulna in a clinical case of the domestic rabbit has not been previously reported.

Case Report

A 9-month-old, 2 kg, neutered male Mini Lop Cross was presented to its local general veterinary practice with acute lameness of unknown cause. Clinical examination showed crepitation and deviation of the left forelimb. Diagnostic lateral and craniocaudal radiographs of the radius and ulna were obtained under general anaesthesia using glycopyrrolate (Glycopyrrolate; West-ward, New Jersey, United States; 0.02 mg/kg subcutaneously [SC]) for premedication and fentanyl citrate (Fentanyl; Hospira Inc., Illinois, United States; 0.15 mg/kg intramuscular [IM]) and ketamine (Ketamil; Ilium, New South Wales, Australia; 7 mg/kg IM) for induction. Using a dental radiography unit (CR7 Vet Image Plate X-ray Scanner; iM3, Sydney, Australia), X-rays depicted a mildly comminuted complete mid-diaphyseal radius and ulna fracture with caudoproximal and lateral displacement of the distal fragment (► **Fig. 1**). The left forelimb was then temporary stabilized using a splinted modified Robert Jones dressing, and then given meloxicam (Metacam; Boehringer Ingelheim, Missouri, United States; 0.3 mg/kg SC) and buprenorphine (Temvet; Troy Laboratory, New South Wales, Australia; 0.03 mg/kg SC) for pain relief by the primary care veterinarian. The case was referred to a board-certified small animal veterinary surgeon (A.S.L.), who in-turn recommended surgery to repair the fractures. Due to financial constraints, there was a delay in repair of the fracture for 2 weeks.

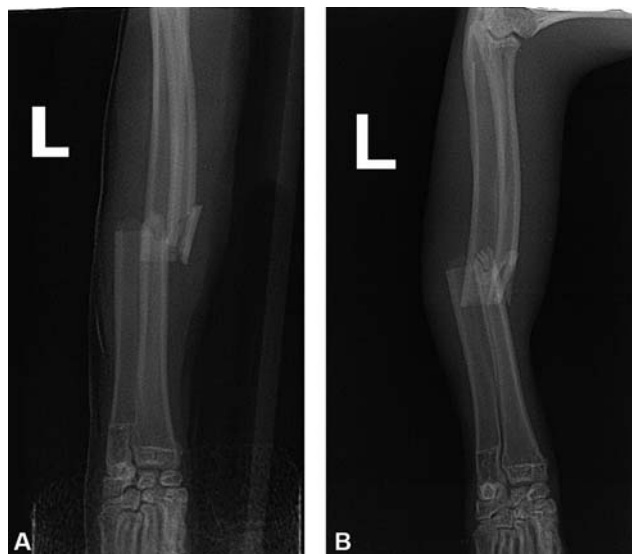


Fig. 1 (A) Preoperative craniocaudal radiograph of the left forelimb. (B) Preoperative mediolateral radiograph of the left forelimb.

Methods

The rabbit was premedicated using glycopyrrolate (Glycopyrrolate; 0.02 mg/kg SC) and induced with ketamine (Ketamil; 7 mg/kg IM) and fentanyl citrate (Fentanyl; 0.15 mg/kg IM). Intraoperative procaine penicillin (Propericillin; Ilium, New South Wales, Australia; 40 mg/kg SC) and cephazolin sodium (Cefazolin; Hospira Inc., Illinois, United States; 22 mg/kg intravenously) were administered. The rabbit was then intubated and maintained at 2.5% isoflurane (Isoflo, Zoetis Australia Pty Ltd, Rhodes NSW, Australia) in oxygen throughout the procedure and was monitored through a Surgivet anaesthetic monitor (Advisor 3 Parameter Vital Signs Monitor; Smiths-Medical, Ohio, United States) using capnography, pulse oximetry, blood pressure. The rabbit was positioned in dorsal recumbency and prepped for surgery with a hanging limb. A craniomedial incision was made in the skin with a no 15 blade extending from 2 cm distal to the elbow joint to 0.5 cm proximal to the carpal joint. Dissection was continued through the subcutaneous tissue to expose the musculature superficial to the cranial surface of the radius. The extensor carpi radialis and other extensor muscles were retracted laterally. Soft tissue was removed from the cranial surface of the radial diaphysis via combination sharp and blunt dissection. Haemorrhage was controlled with electrocautery. A comminuted fracture of the radial diaphysis with caudal–proximal displacement of the distal fragment was identified; significant fibrous tissue was noted. The fractured radial and ulna segments were identified and ends were osteotomized 1 to 3 mm each side with the sagittal saw to aid in precise reduction in a transverse bone. No gross evidence of bone pathology was appreciated. The bone segments were held in reduction, while a 1.5 mm 12 holes LAP (DT AP 1.512; Veterinary Orthopedic Implants Inc., Florida, United States, Veterinary Orthopaedic Implants. 1.5 mm double threaded locking adaptation plates-12 hole [<https://vetimplants.com/1-5mm-double-threaded-locking-adaption-plate-12-hole/>]) was cut to size (7 holes) and applied to the cranial surface of the radius. A locking drill guide and a brand new 1.1 mm drill bit were used to drill into the radius. Six screws were inserted into the radius to fixate the plate. The most distal cortical screw hole was filled first to compress the plate to the bone; then most proximal cortical screw, followed by the cortical screw hole distal to the fracture site then proximal to the fracture site and finally the locking screws. The middle hole was left open as it was too close to the fracture site. Another 1.5 mm 12 holes LAP (DT AP 1.512; Veterinary Orthopedic Implants, Inc., Florida, United States) was cut to size (five holes). A locking drill guide and a 1.1 mm drill bit were used to drill into the ulna. The plate was placed at an angle to the first plate to utilize the concept of orthogonal plate fixation. Four screws were inserted into the ulna (two cortical and two locking) to fixate the plate in a like-wise manner. The surgical site was lavaged with sterile saline. The joints were palpated through a complete range of motion and the elbow and carpus were free of crepitus. Limb and joint alignment appeared appropriate. Closure of the skin was done using 4/0 nylon ford interlocking.⁵

Results

Postoperative Evaluation

A splinted bandage was applied from the most distal aspect of the left forelimb to above the elbow postoperatively. Buprenorphine (Temvet; 0.03 mg/kg SC) and meloxicam (Metacam Solution for Injection; 0.3 mg/kg SC) were administered as postoperative pain relief. The rabbit recovered from anaesthesia uneventfully, was given hay, water and monitored overnight until normal eating habits returned. The rabbit was kept on soft, clean bedding and kept caged confined. Weight bearing on the splinted limb resumed the following day the patient was discharged on meloxicam (Metacam Oral Suspension; Boehringer Ingelheim, Missouri, United States; 1 mg/kg per os) for 7 days and procaine penicillin (Propercillin; 40 mg/kg SC) for 5 days.³

Follow-Up Evaluation

At follow-up evaluation with the general practice 7 days postoperatively, the splint was removed and the limb was rebandaged in a modified Robert Jones dressing. The bandage was changed at weekly intervals for a total of 3 weeks before removal, during which time the owners reported that limping had ceased. During the follow-up period, the rabbit was under strict cage confinement for a total of 6 weeks with follow-up X-rays performed at week 8 postoperatively.

Radiographic Evaluation

Postoperative lateral and craniocaudal radiographs of the left radius and ulna confirmed appropriate fracture reduction, alignment, apposition and implant placement (► Fig. 2).

Follow-up craniocaudal and mediolateral radiographs of the left radius and ulna of the rabbit were obtained at 8 weeks postoperatively. Radiographs depicted complete osseous union of the fracture and no implant complications on

both views (► Fig. 3). Subjectively, based on the scoring system previously described by Pozzi et al, where grade 1 is complete healing of the fracture line with no callus formation and grade 5 is nonunion with no signs of healing, the fracture was graded 1.¹⁸

Discussion

Successful fixation of plates to the radius and ulna of a domestic rabbit was demonstrated using 1.5 mm LAPs.

In this report both the radius and ulna were plated that may be an important step in the outcome of rabbit radius–ulna fracture repair. The reasons for this are twofold. First, the diameter of the rabbit ulna appears equal to or larger than the radius in size. Failure to plate the ulna may lead to overload of the radial plate if the ulna forms a non-union. Additionally, plating the ulna protects the radial implant from overload and vice versa. Second, having two plates at angles to one another protects either plate from deleterious bending forces similar to orthogonal plating.^{19,20} Orthogonal plating is fixating a plate such that the bending forces are aligned against the width of the plate rather than the depth as is seen in parallel plating. This method uses the principle of area moment of inertia to determine the optimal angle at which the plate is fixated to increase overall structural strength of the repair.¹⁶

An open screw hole was left on both the radial and ulnar fracture repairs near the fracture site. Although this is not ideal, this arose due to the small size of the bones being repaired. Open screw holes can cause a stress-riser at the plate and can lead to plate breakage. We speculate that this did not occur for three reasons. First, the radial and ulna plates were orthogonal and protective of one-another, second a degree of load sharing was achieved through bone contact by osteotomy and reduction and third good patient aftercare.

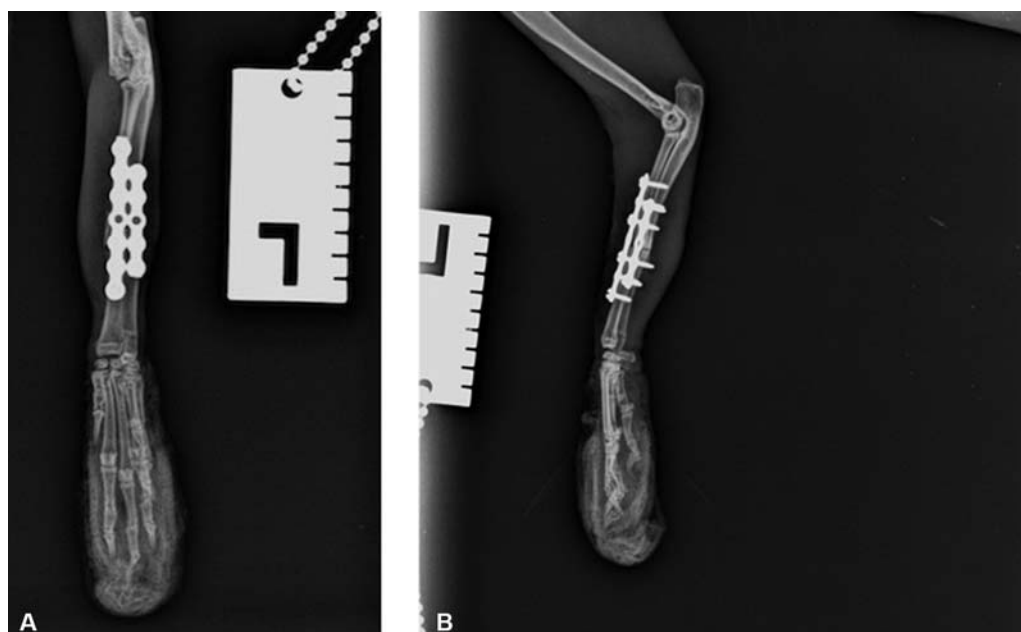


Fig. 2 (A) Immediate postoperative craniocaudal radiograph of the left forelimb. (B) Immediate postoperative mediolateral radiograph of the left forelimb.

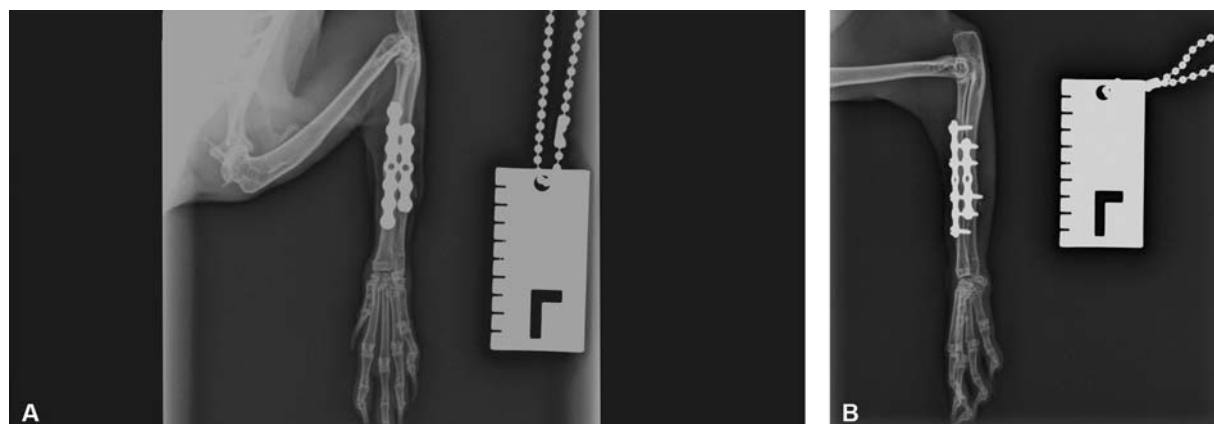

Fig. 3 (A) Craniocaudal radiograph of the left forelimb 8 weeks postoperatively. (B) Mediolateral radiograph of the left forelimb 8 weeks postoperatively.

The bone ends of both the radius and ulna were osteotomized in this present report. This likely aided in both bone healing and bone remodeling as it allowed for complete and perfect reduction without undue force. Furthermore, allowing the bone cortices to meet and thus enabling a degree of load-sharing are vital in early progression of bone healing and protecting the implant from over-loading.¹ An additional advantage of osteotomizing the bone ends was that it opened the medullary cavity (blood supply) of the bones which had been sealed with fibrous tissue due to the delay in time between injury and repair. We felt that the limb shortening caused by doing this was not clinically significant. An investigation into what length of the radius can be osteotomized before locomotion is affected should be evaluated.

Two locking and four cortical screws were used to fixate the radial plate, and two locking and two cortical screws were used to fixate the ulna plate. The cortical screws were placed first the reasons for this are threefold²¹: (1) to compress the plate to the bone thereby optimizing construct strength, (2) to maintain compression of the fracture site and (3) to maintain positioning of the plate on the bone before application of the locking screws. Additionally, this sequence avoids stripping of the cortical screws. Given that the radius and ulna are effectively operating as one functional unit, we therefore had three cortical and two locking screws on each side of the fracture which was sufficient for stability.²²

In this report, the authors applied a splinted bandage to the repaired limb. Currently, the literature is unclear on the use of bandaging after internal fixation of distal limb fractures and thus bandaging is regularly left to surgeons' preference. The authors have found anecdotally that postoperative caudal splinting, using fiberglass or similar, in radius–ulna fractures in toy breed dogs leads to low rate of complications in our hands. However, we submit that there are publications showing the potential deleterious effects of bandaging. In one study, bandage use in toy and miniature-breed dogs, after bone plate fixation of radius–ulna fractures, led to a large proportion of the minor complications encountered postoperatively.²³ Furthermore, when casts were used in distal limb orthopaedic conditions in dogs and cats, it was found, in another study, that 63% developed soft tissue injuries with a higher prevalence in

sighthounds.²⁴ Although this may be the case, it is not known whether bandaging, splinted or otherwise, contributed to the success in this report.

A few limitations are apparent in this report. First, as this was a referral case, which was managed postoperatively by the primary care veterinarian, frequent follow-up examinations to thoroughly assess fracture healing radiographically were not possible. Second, the relatively higher cost of 1.5 mm LAPs and screws may be prohibitive to widespread use in clinical cases. Third, the applicability of this technique to inexperienced veterinarians may be low due to the technical skill and equipment required to implant such plates without complications. Finally, this report only reports success in a single rabbit.

In conclusion, this is the first clinical report where 1.5 mm LAPs have successfully been used to repair a fracture of the radius and ulna in a rabbit. Future studies should investigate the complication rate of placing 1.5 mm LAPs in a larger rabbit sample size, and whether plating both the radius and ulna or only radius is necessary for success.

Authors' Contributions

A.M. wrote and submitted the manuscript. A.S.L. performed the surgery and revised the manuscript.

Conflict of Interest

None declared.

Acknowledgments

The authors would like to thank Summer Hill Village Vet for providing the figures that depict the preoperative (–Fig. 1), postoperative (–Fig. 2) and 8-week postoperative radiographs (–Fig. 3).

References

- Zehnder A, Kapatkin AS. Orthopedics in Small Mammals. In: Carpenter J, Ferrets, Rabbits, and Rodents. Elsevier; 2012:472–484
- Sasai H, Fujita D, Tagami Y, et al. Characteristics of bone fractures and usefulness of micro-computed tomography for fracture detection in rabbits: 210 cases (2007–2013). *J Am Vet Med Assoc* 2015;246(12):1339–1344

- 3 Garcia-Pertierra S, Ryan J, Richardson J, et al. Presentation, treatment and outcome of long-bone fractures in pet rabbits (*Oryctolagus cuniculus*). *J Small Anim Pract* 2020;61(01):46–50
- 4 Ciwko E, Sadar MJ, Bennett K, Linn K. Transfixation pin splinting as an alternative external coaptation method in domestic rabbit (*Oryctolagus cuniculus*) long bone fractures. *J Small Anim Pract* 2018;27(04):31–37
- 5 Rich GA. Rabbit orthopedic surgery. *Vet Clin North Am Exot Anim Pract* 2002;5(01):157–168, vii
- 6 Terjesen T, Benum P. Mechanical effects of metal plate fixation. In vitro investigation on intact and osteotomized human and rabbit tibiae. *Acta Orthop Scand* 1983;54(02):256–262
- 7 Massie AM, Kapatkin AS, Garcia TC, Guzman DS-M, Chou P-Y, Stover SM. Effects of hole diameter on torsional mechanical properties of the rabbit femur. *Vet Comp Orthop Traumatol* 2019;32(01):51–58
- 8 Sasai H, Fujita D, Seto E, et al. Outcome of limb fracture repair in rabbits: 139 cases (2007–2015). *J Am Vet Med Assoc* 2018;252(04):457–463
- 9 Terjesen T. Bone healing after metal plate fixation and external fixation of the osteotomized rabbit tibia. *Acta Orthop Scand* 1984; 55(01):69–77
- 10 Gibert S, Ragetly GR, Boudrieau RJ. Locking compression plate stabilization of 20 distal radial and ulnar fractures in toy and miniature breed dogs. *Vet Comp Orthop Traumatol* 2015;28(06): 441–447
- 11 Fulkerson E, Egol KA, Kubiak EN, Liporace F, Kummer FJ, Koval KJ. Fixation of diaphyseal fractures with a segmental defect: a biomechanical comparison of locked and conventional plating techniques. *J Trauma* 2006;60(04):830–835
- 12 Frigg R. Locking compression plate (LCP). An osteosynthesis plate based on the dynamic compression plate and the point contact fixator (PC-Fix). *Injury* 2001;32(Suppl 2):63–66
- 13 Wagner M. General principles for the clinical use of the LCP. *Injury* 2003;34(Suppl 2):B31–B42
- 14 Takizawa H, Honnami M, Sakai T, Sasaki A, Sakamoto A, Mochizuki M. A biomechanical comparison of three miniature locking plate systems in a rabbit radial and ulnar fracture model. *Vet Comp Orthop Traumatol* 2019;32(04):297–304
- 15 Preston TJ, Glyde M, Hosgood G, Day RE. Dual bone fixation: a biomechanical comparison of 3 implant constructs in a mid-diaphyseal fracture model of the feline radius and ulna. *Vet Surg* 2016;45(03):289–294
- 16 Craig A, Witte PG, Moody T, Harris K, Scott HW. Management of feline tibial diaphyseal fractures using orthogonal plates performed via minimally invasive plate osteosynthesis. *J Feline Med Surg* 2018;20(01):6–14
- 17 Alza Salvatierra DN, Witte PG, Scott HW, Catchpole C. Pantarsal arthrodesis in cats using orthogonal plating. *J Feline Med Surg* 2018;20(01):45–54
- 18 Pozzi A, Risselada M, Winter MD. Assessment of fracture healing after minimally invasive plate osteosynthesis or open reduction and internal fixation of coexisting radius and ulna fractures in dogs via ultrasonography and radiography. *J Am Vet Med Assoc* 2012;241(06):744–753
- 19 Lenz M, Stoffel K, Gueorguiev B, Klos K, Kielstein H, Hofmann GO. Enhancing fixation strength in periprosthetic femur fractures by orthogonal plating—a biomechanical study. *J Orthop Res* 2016;34(04):591–596
- 20 Labus KM, Sutherland C, Notaros BM, et al. Direct electromagnetic coupling for non-invasive measurements of stability in simulated fracture healing. *J Orthop Res* 2019;37(05):1164–1171
- 21 Johnson AL, Houlton JEF, Vannini R. *AO Principles of Fracture Management in the Dog and Cat*. AO Pub; 2005
- 22 Palierne S, Froidefond B, Swider P, Autefage A. Biomechanical comparison of two locking plate constructs under cyclic loading in four-point bending in a fracture gap model: two screws versus three screws per fragment. *Vet Comp Orthop Traumatol* 2019;32(01):59–66
- 23 De Arburn Parent R, Benamou J, Gatineau M, Clerfond P, Planté J. Open reduction and cranial bone plate fixation of fractures involving the distal aspect of the radius and ulna in miniature- and toy-breed dogs: 102 cases (2008–2015). *J Am Vet Med Assoc* 2017;250(12):1419–1426
- 24 Meeson RL, Davidson C, Arthurs GI. Soft-tissue injuries associated with cast application for distal limb orthopaedic conditions. A retrospective study of sixty dogs and cats. *Vet Comp Orthop Traumatol* 2011;24(02):126–131