

# Early Endoscopic Intervention in Pancreaticopleural Fistula: A Single-Center Experience

Vinay Balasaheb Pawar<sup>1</sup> Pravin Rathi<sup>1</sup> Ravi Thanage<sup>1</sup> Prasanta Debnath<sup>1,✉</sup> Sujit Nair<sup>1</sup>  
Qais Contractor<sup>1</sup>

<sup>1</sup>Department of Gastroenterology, Topiwala National Medical College and B.Y.L. Nair Ch. Hospital, Mumbai, Maharashtra, India

**Address for correspondence** Vinay Balasaheb Pawar, DM, Department of Gastroenterology, Topiwala National Medical College and B.Y.L. Nair Ch. Hospital, Mumbai, Maharashtra 400008, India (e-mail: docvinu@gmail.com).

J Digest Endosc:2020;11:263–269

## Abstract

### Keywords

- ▶ pancreaticopleural fistula
- ▶ early endoscopic management of pancreaticopleural fistula
- ▶ pancreaticopleural fistula in chronic pancreatitis
- ▶ rare cause of pleural effusion: pancreaticopleural fistula

**Background** Pancreaticopleural fistulas are among the rarest complications of chronic pancreatitis. The main objective of the research, conducted on a total of seven patients, was to evaluate the effectiveness of early endoscopic management of pancreaticopleural fistula.

**Methods** The diagnosis of fistula was reached when fistulous tract was demonstrated on imaging studies and/or pleural fluid amylase level was greater than 2,000 U/L. The data were retrospectively analyzed from the records.

**Results** The prototype patient in our series was a chronic alcoholic male with median age of 45 years. Computed tomography scan was performed in all the seven patients but could diagnose leak only in four patients. Magnetic resonance cholangiopancreatography was better in the remaining three patients for diagnosing fistula. Endoscopic retrograde cholangiopancreatography was the most sensitive test that diagnosed fistula in all the seven patients. Pancreatic duct (PD) cannulation was successful and pancreatic sphincterotomy with PD stenting was performed in all the seven patients. We could avoid surgical intervention in our patients.

**Conclusions** We advise early endoscopic treatment within 7 days of symptom onset as opposed to 3 weeks, which was proposed previously. Medical therapies should be complimentary to PD stenting.

## Introduction

Pancreatitis can be caused by various insults that result in pancreatic necrosis. Infected necrosis or disrupted pancreatic ductal epithelium by the inflammatory process leading to ductal leak may present as either worsening symptoms or lack of improvement.<sup>1–4</sup> Pancreatic trauma as well as acute and chronic pancreatitis can result in pancreatic duct (PD) leak. In chronic pancreatitis, ductal leak is the result of either intraductal stone, inflammatory strictures, or an overlapping episode of acute pancreatitis. Pancreatic ductal leaks can be

classified as internal and external fistulas.<sup>3,5</sup> External fistulas present as cutaneous fistulas and are mostly iatrogenic. Internal leaks can present as ascites, pleural effusions, and pseudocysts.<sup>4</sup> Pancreaticopleural fistulas are among the rare complications of chronic pancreatitis. They occur in around 0.4% patients presenting as pancreatitis.<sup>6</sup> Pleural effusions associated with chronic pancreatitis are large and often recurrent as compared with small pleural effusions seen in acute pancreatitis.<sup>7</sup> The treatment depends largely on the clinical manifestations.

DOI <https://doi.org/10.1055/s-0040-1721655>  
ISSN 0976-5042.

©2020. Society of Gastrointestinal Endoscopy of India.

This is an open access article published by Thieme under the terms of the Creative Commons Attribution-NonDerivative-NonCommercial-License, permitting copying and reproduction so long as the original work is given appropriate credit. Contents may not be used for commercial purposes, or adapted, remixed, transformed or built upon. (<https://creativecommons.org/licenses/by-nc-nd/4.0/>).

Thieme Medical and Scientific Publishers Pvt. Ltd. A-12, 2nd Floor, Sector 2, Noida-201301 UP, India

The need for surgery has been significantly reduced in the setting of PD leak due to the recent advances in therapeutic endoscopic retrograde cholangiopancreatography (ERCP). The condition is rarer, lacks a uniform approach, and there is dearth of data in the literature regarding the outcomes of endoscopic management of pancreaticopleural fistula. The purpose of this study was to evaluate the efficacy of early endoscopic treatment in pancreaticopleural fistula.

The conservative medical management is advisable till 3 weeks and persistence of pleural effusion beyond that period should be considered its failure and be offered endoscopic treatment or surgery. We defined early endoscopic treatment as treatment offered to the patient within 7 days of presentation.

### Study Plan

The data were collected retrospectively from prospectively managed database of patients with pancreaticopleural fistula. The study was interventional study and the patients were admitted in a tertiary care hospital from western India.

The data were collected from the records of patients who were referred to the Gastroenterology department between January 2015 and December 2019. The patients who were fulfilling the inclusion criteria were included in the analysis.

### Inclusion Criteria

Patients diagnosed with pancreaticopleural fistula were included in the study. The diagnosis was made on the basis of history, clinical examination, and imaging studies like chest X-ray, abdominal sonography, and contrast-enhanced computed tomography (CECT) of chest and abdomen or magnetic resonance cholangiopancreatography (MRCP). These patients also underwent pancreatic fluid analysis with estimation of pleural fluid amylase levels. Ascitic fluid analysis was considered whenever present. Besides these specific investigations, all the routine investigations were performed that included complete blood count, renal function tests, liver function tests, and serum electrolytes. The diagnosis of pancreaticopleural fistula was reached when fistulous tract was demonstrated on imaging studies and/or pleural fluid amylase level was greater than 2,000 U/L. Interventions included ERCP-guided PD stenting or surgery.

### Exclusion Criteria

Subjects under 18 years of age were excluded.

### Treatment Protocol

After diagnosing the pancreaticopleural fistula, standard medical treatment was offered to all the patients, which included antibiotics, intravenous fluids, and nutritional care. They received tube feeding through nasojejunal tube. Thoracentesis was considered in a chronic alcoholic patient with massive, recurrent, or rapidly filling pleural effusion. Chest tube drainage was considered whenever patient had pulmonary compromise. We received two of our patients from chest department with chest tube already in situ. Octreotide, which is a long-acting analogue of somatostatin,

was given to all the patients to suppress the pancreatic secretions and promote closure of pancreaticopleural fistulas. Our patients received at least 7 days of injectable octreotide before the index procedure in a dose of 100 microgram three times per day. The PD drainage was planned for all the patients after obtaining the anatomical roadmap by CECT and/or MRCP. Pancreatic sphincterotomy with plastic PD stenting at ERCP was the primary treatment modality accepted for all the patients. At ERCP, pancreatic ductal anatomy was delineated, leak was demonstrated, and the therapeutic procedure was performed. Size of PD stent was decided during pancreaticography performed at ERCP. Wilson Cook PD stents were used (5–7 Fr diameter, 5–10 cm length). Repeat chest X-rays were performed at 4 weeks and at 3 months after ERCP; CECT abdomen and/or MRCP were performed whenever required after the primary procedure. Stent removal was planned after 3 months. Stent removal was considered appropriate when patient had no symptoms, chest X-ray was normal, and there was no contrast leak at pancreaticography performed during ERCP done for stent removal. We assumed that we will do stent exchange if these criteria are not met, and reevaluate the patients after 3 months but none of our patients had to undergo repeat PD stenting.

Fortunately, surgery was not required for our patients with pancreaticopleural fistula as ERCP was successful in all of them.

### Outcome Measures

Primary outcome measure of the study was asymptomatic subject with normalization of chest X-ray, and absent contrast leak on pancreatogram during the follow-up ERCP.

Secondary outcome measures were mortality during hospital stay or after discharge within 3 months, due to complications of pancreaticopleural fistula, and requirement of repeat PD stenting or exchange after 3 months.

### Statistical Analysis

Categorical variables are presented as frequencies (percentages) and continuous variables as median with range. All statistical analyses were performed using Statistical Package for the Social Sciences, version 22.0, statistical software (IBM, Armonk, NY, USA).

### Results

The data were collected from the records of patients who were referred to the Gastroenterology department between January 2015 and December 2019.

There were 127 patients of chronic pancreatitis who were treated in the department of Gastroenterology during this period. There was no record of patients following with Pediatric, Surgery, and Endocrine departments. We studied seven patients with pancreaticopleural fistula. All the patients underwent ERCP, and PD stent was placed in all of them. None of the patients required any surgical management. **Table 1** shows the baseline characteristics and outcome of patients undergoing ERCP.

**Table 1** Baseline characteristics and outcome of patients undergoing endoscopic retrograde cholangiopancreatography

Sr. N	Age (y)	Gender	Etiology	Clinical features Chest X-ray	Pleural fluid amylase (IU/L)	CT scan	MRCP	ERCP	Primary outcome achieved (yes/no)
1	49	Male	Alcohol	Dyspnea and abdominal pain	Left pleural effusion	22,704	1) Left pleural effusion 2) Atrophic pancreas 3) Dilated PD with no e/o any PD calculi or stricture; PD leak noted in head region	Not performed	1) Dilated PD 2) No PD calculi or stricture 3) PD leak in head 4) Pancreatic sphincterotomy with PD stenting 5) Bridged the leak Yes
2	34	Male	Alcohol	Cough, fever and abdominal pain	Left pleural effusion	2,450	1) Left pleural effusion 2) Atrophic pancreas with parenchymal calcification 3) Dilated PD with no e/o any PD calculi or stricture; PD leak noted in head region	Not performed	1) Dilated PD 2) No PD calculi or stricture 3) PD leak in head 4) Pancreatic sphincterotomy with PD stenting 5) Bridged the leak Yes
3	43	Male	Alcohol	Dyspnea	Left pleural effusion	9,612	1) Left pleural effusion 2) Atrophic pancreas with parenchymal calcification 3) Dilated PD with no e/o any PD calculi or stricture; PD leak noted in proximal body region	Not performed	1) Dilated PD 2) No PD calculi or stricture 3) PD leak in proximal body 4) Pancreatic sphincterotomy with PD stenting 5) Bridged the leak Yes
4	37	Male	Alcohol	Dyspnea	Left pleural effusion	5,420	1) Left pleural effusion 2) Atrophic pancreas 3) Dilated PD with no e/o any PD calculi or stricture; PD leak noted in proximal body region	Not performed	1) Dilated PD 2) No PD calculi or stricture 3) PD leak in proximal body 4) Pancreatic sphincterotomy with PD stenting 5) Bridged the leak Yes
5	55	Male	Alcohol	Dyspnea and abdominal pain	Bilateral pleural effusion	56,674	1) Bilateral pleural effusion 2) Atrophic pancreas 3) Dilated PD with no e/o ductal calcification or stricture; no obvious PD leak detected. 4) Moderate ascites	1) Atrophic pancreas with dilated PD; no e/o ductal stricture or calcification 2) PD leak noted in the head region 3) Moderate ascites	1) Dilated PD 2) No PD calculi or stricture 3) PD leak in head 4) Pancreatic sphincterotomy with PD stenting 5) Bridged the leak Yes
6	45	Male	Alcohol	Dyspnea	Right pleural effusion	10,144	1) Right pleural effusion 2) Atrophic pancreas with parenchymal calcification 3) Dilated PD with ductal calcification; no obvious stricture or PD leak detected.	1) Atrophic pancreas with dilated PD; no e/o ductal stricture; ductal calcification noted 2) PD leak noted in the distal body region	1) Dilated PD 2) No PD calculi or stricture 3) PD leak in distal body 4) Pancreatic sphincterotomy with PD stenting 5) Not bridged the leak Yes
7	52	Male	Alcohol	Dyspnea	Left pleural effusion	46,208	1) Left pleural effusion 2) Atrophic pancreas with parenchymal calcification 3) Dilated PD with ductal calcification; no obvious stricture or PD leak detected.	1) Atrophic pancreas with dilated PD; no e/o ductal stricture; ductal calcification noted 2) PD leak noted in the distal body region	1) Dilated PD 2) No PD calculi or stricture 3) PD leak in distal body 4) Pancreatic sphincterotomy with PD stenting 5) Not bridged the leak Yes

Abbreviations: CT, computed tomography; ERCP, endoscopic retrograde cholangiopancreatography; MRCP, magnetic resonance cholangiopancreatography; PD, pancreatic duct.

All the patients were males and median age of presentation was 45 years (range: 34–55 years). The sole etiology in our series for chronic pancreatitis was chronic alcoholism.

The principal presenting feature in our patients was breathlessness in six (85.71%) out of seven patients. One of our patients had history of cough and fever. Out of seven patients, three had additional complaint of abdominal pain.

All the patients underwent chest X-ray and computed tomography (CT) scan of abdomen and chest. In three patients, CT scan did not show the leak and they underwent MRCP, which demonstrated the leak.

Majority of our patients had left-sided pleural effusion (five out of seven, 71.42%; ►Fig. 1C). One patient had isolated right-sided pleural effusion (►Fig. 1A) and one of our patients had bilateral pleural effusion (►Fig. 1B).

Pleural fluid amylase was elevated in all the patients. The lowest value of pleural fluid amylase in our series was 2,450 IU/L while highest value was 56,674 IU/L, median being 10,144 IU/L. One patient had concomitant ascites with pancreaticopleural fistula and pleural effusion.

Abdominal and chest CT scan was performed as the primary diagnostic procedure as it is easily available in our institute, affordable over MRCP, and does not require patient cooperation. Pleural effusion could be detected in all our patients by CT scan but it was poor in detecting the site of PD leak. Site of leak could be diagnosed accurately in only four patients out of seven. Two patients had leak in head region while two had leak in the body. CT scan diagnosed other features of chronic pancreatitis like atrophic pancreas, parenchymal calcification, and

dilated irregular PD with pancreatic ductal calcifications. None of our patients had PD strictures.

In three patients, MRCP was performed as the pancreaticopleural fistula was not demonstrable on CT scan. Leak was present in head in one patient and in body of pancreas in the remaining two patients. Changes in chronic pancreatitis— atrophic pancreas, pancreatic calcifications, and dilated PD with ductal calcifications—were seen on MRCP. No patient had stricture on MRCP.

ERCP demonstrated the fistula in all the cases. Three patients had communication in the head (►Fig. 2B), two in the proximal body (►Fig. 2A), and two in the distal body (►Fig. 2C). Dilated irregular PD was seen in all the patients but no stricture or stone causing complete obstruction could be identified. PD cannulation was successful and pancreatic sphincterotomy with PD stenting was performed in all the seven patients. Site of the leak was bridged by the PD stent in five patients while it did not in two patients who had fistulous communication in the distal body of the pancreas. Though PD leak was not bridged in two patients, primary outcome was achieved in all seven patients. None of our patients had any post-ERCP infectious complications. Patients became asymptomatic within 2 to 5 days. After 3 months, chest X-rays were normal with no evidence of pleural effusion. There was no intraprocedure or in-hospital mortality. None of our patients required repeat PD stenting. Repeat ERCP at 3 months did not demonstrate the leak in all the patients. We could avoid surgical intervention in our patients. There was no in-hospital mortality in the study population.

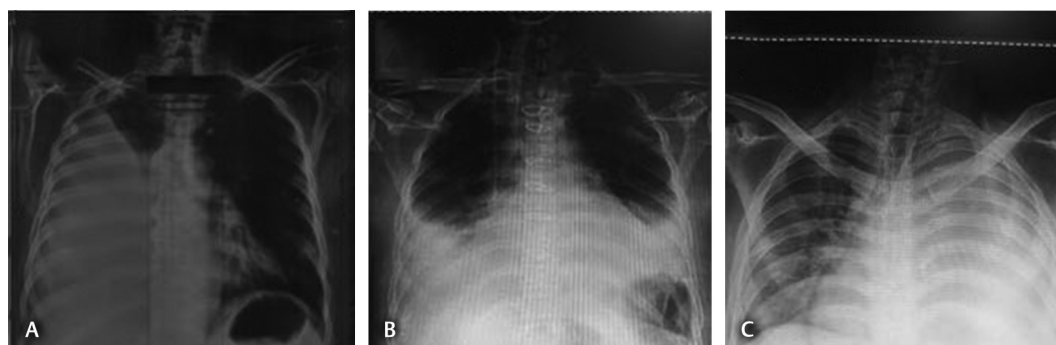


Fig. 1 Chest X-rays: (A) right-sided pleural effusion, (B) left-sided pleural effusion, and (C) bilateral pleural effusion.

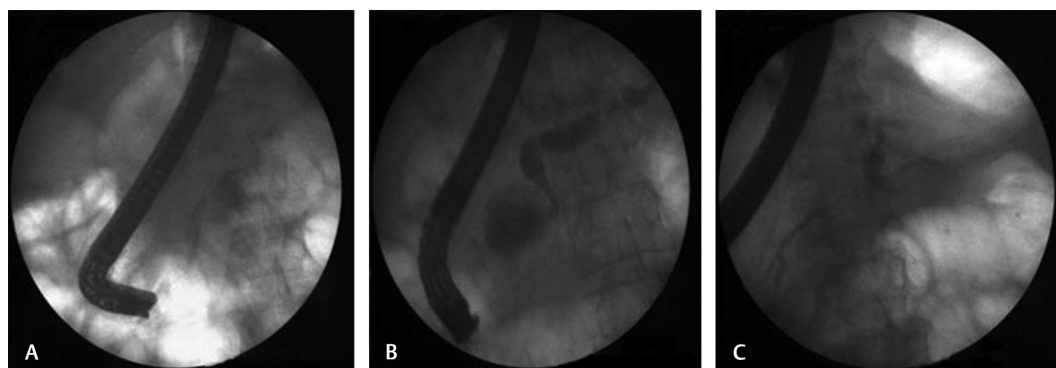


Fig. 2 Pancreatograms obtained during endoscopic retrograde cholangiopancreatography showing pancreatic duct leak at the level of (A) proximal body, (B) head, and (C) distal body.

## Discussion

Pancreaticopleural fistula is an infrequent complication of acute or chronic pancreatitis or pancreatic trauma. Fistulous involvement of pancreas with extra-abdominal organs like pleura, pericardium, bronchi, and mediastinum in the setting of pancreatitis is uncommon. Pancreaticopleural fistulas occur in 0.4% of patients who present as pancreatitis and 4.5% patients presenting with pseudocysts.<sup>6</sup> Conversely, pancreatic pseudocysts are seen in 43 to 79% of patients with pancreaticopleural fistula.<sup>8</sup> Alcohol-related chronic pancreatitis (67%) is the most common cause of pancreaticopleural fistula in adults. The other causes being abdominal trauma, gallstones, and PD anomalies.<sup>9-11</sup> In our series, alcohol was the sole etiology.

Due to its digestive property, pancreatic juice dissects through fascial planes either anteriorly to form pancreaticoperitoneal communication or posteriorly into the retroperitoneum. Pancreaticopleural fistula occurs due to the formation of a posterior pathway of communication between the PD and the pleura or, more frequently, after the formation of a pseudocyst that communicates with the pleural cavity. The fluid flows through the retroperitoneum usually through the esophageal hiatus to the pleural cavity. The fluid flows to pleural cavity because it is the plane of least resistance.<sup>12</sup> The fistulous tract drains the amylase-rich pancreatic fluid into the pleural space. Left-sided (76%) pleural effusion is more common than the right-sided (19%) or bilateral (14%) pancreaticopleural effusion.<sup>13,14</sup> In our series, 71.42% had left-sided while 14.28% subjects had bilateral and right-sided pleural effusion each.

The most common presentation in our study was a middle-aged male patient with history of chronic alcohol intake. The predominance of male population in our series was probably due to more prevalent alcohol intake in males than in females in India. Although a past history of chronic pancreatitis was lacking in our patients, all of them showed features of chronic pancreatitis on imaging. The most common presenting feature in our patients was dyspnea (65–76%) and left-sided massive pleural effusion on chest X-ray. The other less common symptoms include abdominal pain (29%), cough (27%), chest pain (23%), and fever.<sup>9,14</sup> Since chest symptoms predominate, the diagnosis of pancreaticopleural fistula is often delayed. It should be suspected when the pleural effusion is massive, recurrent, and rapidly filling. Concomitant pancreatic ascites is seen in 20% and pericardial effusion in 5% patients with pancreaticopleural fistula.<sup>15</sup>

Although there is no threshold value for the diagnosis of pancreaticopleural fistula, one should suspect it when the values are more than 1,000 U/L.<sup>6,15,16</sup> The pleural fluid amylase levels more than 50,000 U/L is characteristically seen with pancreaticopleural fistula.<sup>6,7,16,17</sup> In our series, all the patients had elevated pancreatic fluid amylase levels least being 2,450 IU/L. The elevated pancreatic fluid amylase in the appropriate clinical scenario concludes the diagnosis of pancreaticopleural fistula.

Pancreaticopleural fistulas are usually readily diagnosed at ERCP.<sup>10,18</sup> However, ERCP has its limitations in cases with

PD stone or PD strictures or in an underfilled pancreatogram,<sup>19,20</sup> which can lead to failed cannulation and diagnostic difficulties respectively. In our case series, PD leak or a fistulous tract could be diagnosed in 100% of patients on pancreatogram performed at ERCP. ERCP should be the first step when there is high index of suspicion for pancreaticopleural fistula as it is both diagnostic and therapeutic.

CT scan has also been successful in demonstrating the fistulous tract of a pancreaticopleural fistula. It had a sensitivity of 43% as compared with 79% for ERCP.<sup>9</sup> In our series, PD leak was observed in 57.14% (four out of seven) subjects on CT scan. CT scan is the investigation of choice to diagnose the pleural effusion.<sup>21</sup> For massive unilateral effusions, it is preferable to do CT scan of the chest as it gives better idea of benign versus malignant pleural thickening and is better in diagnosing masses. CT allows assessment of the underlying lung parenchyma, mediastinal structures, and associated liver and upper abdominal pathology.<sup>22</sup> Besides delineating the fistulous tract, CT scan is able to diagnose pancreatic parenchymal changes, ductal dilatation, and pseudocysts.<sup>12,14,23</sup>

Though ultrasound examination of abdomen has been reported to make the diagnosis of pancreaticopleural fistula,<sup>24</sup> the presence of bowel gas, body habitus, and the interobserver variation may miss the findings. In our series, ultrasound was good at detecting pleural effusion but poor at diagnosing the fistulous tract. None of our patients had leak on ultrasonogram.

MRCP has been shown to be effective in visualizing the fistulous tract<sup>19,20,25</sup> and is a noninvasive method as well as avoids radiation. The main drawback of MRCP is that it does not offer therapeutic intervention although it provides an anatomical roadmap before ERCP. In our series, we had used MRCP only when CT scan failed to diagnose the ductal leak. MRCP was performed in three patients. We used CT/MRCP as the first imaging modality to diagnose the leak.

Once pancreaticopleural fistula is suspected, ERCP should be the next step in its management. ERCP not only helps in making the diagnosis but also offers a nonsurgical therapeutic option. Pancreatic stent placement for pancreaticopleural fistula and complete resolution was first reported by Saeed et al in 1993.<sup>26</sup> PD stenting helps in alleviating the symptoms by two mechanisms: it provides the path of least resistance and drains the pancreatic fluid into the duodenum, or it bridges the ductal leak and provides time to heal. Furthermore, ERCP offers other treatment modalities like pancreatic sphincterotomy, PD stricture dilatation, and stone removal. These maneuvers and/or PD stenting help in reestablishing the flow of pancreatic fluid normally through the PD and assist in healing the fistulous tract. The intraductal pressure is also reduced. Large PD stones that are not amenable for balloon extraction, or nonnegotiable stones, can be treated with extracorporeal shock wave lithotripsy (ESWL). ESWL with or without PD stenting has been shown to facilitate the pancreaticopleural fistula closure.<sup>27</sup> The endoscopic procedures are associated with complications and need expertise in anatomic variations and difficult cannulation. Endoscopic ultrasound-guided rendezvous ERCP is an alternative in difficult cases.<sup>28,29</sup> The duration for which PD stent should be kept

remains a controversial issue. Dhebri and Ferran<sup>21</sup> suggested doing ERCP at 6-weekly intervals to assess closure of fistula but different authors have advised doing repeat ERCP from 4 weeks to 12 weeks. We performed chest X-ray at 4 weeks and repeat ERCP at 12 weeks, which avoided radiation exposure due to repeated ERCPs. The success rate of PD stenting has been variable, from 55% to 100%.<sup>30-32</sup> The reasons for low success rate were failed cannulation, nonnegotiable strictures, intraductal obstruction, failure to bridge the leak site, and anatomical variations.<sup>32</sup> The success rate of ERCP in diagnosing and treating PD leak in our case series was 100%. The high success rate seen in our patients may be because none of our patients had PD obstruction, like stricture and/or stones. It will be interesting to see the effects of pancreatic sphincterotomy without PD stenting in such cases where there is no ductal obstruction.

It is usually not necessary to do follow-up ERCP if the patient is asymptomatic and chest X-ray shows no evidence of pleural effusion. We performed repeat ERCP after 3 months as there were discrepancies in imaging features of PD and pancreatograms taken at ERCP, which might be due to under-filled pancreatograms or poor-quality fluoroscopic images. Furthermore, two patients had PD leak in distal body region, which were not negotiated with the PD stent, and nonnegotiable PD leaks are one of the reasons for failure of endoscopic therapy. In the ideal scenario, we do not recommend doing repeat ERCP at 3 months. Asymptomatic patient with normal chest X-ray is sufficient for stent removal.

There have been reports of resolution of fistulas with the placement of nasopancreatic drain.<sup>26,33</sup> These drains decrease the intraductal pressures and help healing. Major advantage of nasopancreatic drains is that pancreatograms can be obtained and fistula closure can be demonstrated without performing further ERCPs. The drawback of nasopancreatic drain, which precludes its use, is that it is not well tolerated by the patients, is cumbersome to maintain in position, and may require hospital admission when the drain is in place.

Conservative management has a low success rate of 0 to 33%, and it may include total parental nutrition (TPN) and/or octreotide and/or placement of chest tube drain.<sup>9</sup> This shows that maintaining anatomical continuity is more important. Octreotide and/or nasojejunal feeding and/or TPN should be an add-on treatment with ERCP with pancreatic ductal stenting, as this combination not only bridges the leak but also reduces the pancreatic secretions.

We advocate placing chest tube drains only when there is respiratory compromise for symptomatic improvement. Chest tube drains were inserted in only two patients in our series, the reason being tachypnea and respiratory fatigue. The retained secretions may dissect through lung parenchyma into the bronchus and form pancreaticobronchial fistula.<sup>34</sup> If chest tube drain has to be placed before performing ERCP, the downstream stricture or stone should be ruled out by performing MRCP as the tube provides track for least resistance and the chances of persistent external fistula.

The major question remains as to how much should we wait before deciding on endoscopic or surgical interventions.

Persistence of pancreatic effusion or its complications may suggest failure of conservative medical management. A maximum period of 3 weeks is advised by Rockey and Cello.<sup>6</sup> Lipsett and Cameron in their series suggested that more than 80% complications developed in pancreaticopleural fistulas when managed conservatively for more than 3 weeks.<sup>35</sup> Conservative management thus should not be continued as the sole management option after 3 weeks. In our series, we offered conservative treatment for 7 days. Wronski et al<sup>15</sup> observed that normal to mildly dilated ducts on MRCP respond best to conservative treatment while those with ductal obstruction are poor candidates for conservative treatment and should be offered early endoscopic or primary surgical treatment.

None of our patients who underwent PD stenting required any operative intervention, as compared with 69% in a review by Rockey and Cello<sup>6</sup> and 52% in a review by Oh et al.<sup>9</sup> This may reflect increased use of PD stenting to treat pancreaticopleural fistulas as opposed to surgical intervention. Surgery should be considered in patients who fail to respond to conservative medical management or endoscopic treatment or have failed ERCP cannulation. The primary surgery has minimal complications and short period of recovery.<sup>14</sup> Complete duct obstruction proximal to fistula site and pancreatic ductal leak in the tail region can be best managed with primary surgery. The most common procedures performed were distal pancreatectomy and pancreaticojejunostomy.<sup>36-38</sup> King et al described performing primary surgery in all the patients with pancreaticopleural fistula.<sup>14</sup> The patients treated surgically after prior medical/endoscopic procedure had longer hospital stay and postoperative recovery and higher chances of having complications.

Pancreaticopleural fistula is among the rarer complications of pancreatitis and was previously treated surgically. The surgical measures are rarely used nowadays with advent of ERCP. The first imaging study performed in pancreaticopleural fistulas is CT but it misses almost more than 50% of the cases. Often the first investigation when a pancreaticopleural fistula is suspected is MRCP. It is noninvasive and can provide an anatomical roadmap to perform ERCP. It can also prognosticate cases into those who will respond to ERCP or primary surgery. An invasive but sensitive test to diagnose the fistulas and offer therapeutic interventions is ERCP.

## Conclusion

We advise early endoscopic treatment that is within 7 days of symptom onset as opposed to 3 weeks, which was proposed previously. Medical therapies should be complimentary to PD stenting.

### Funding

Nil.

### Conflict of Interest

None declared.

## References

- 1 Lau ST, Simchuk EJ, Kozarek RA, Traverso LW. A pancreatic ductal leak should be sought to direct treatment in patients with acute pancreatitis. *Am J Surg* 2001;181(5):411–415
- 2 Pelaez-Luna M, Vege SS, Petersen BT, et al. Disconnected pancreatic duct syndrome in severe acute pancreatitis: clinical and imaging characteristics and outcomes in a cohort of 31 cases. *Gastrointest Endosc* 2008;68(1):91–97
- 3 Mergener K, Kozarek RA. Therapeutic pancreatic endoscopy. *Endoscopy* 2005;37(3):201–207
- 4 Baron TH. Endoscopic drainage of pancreatic pseudocysts. *J Gastrointest Surg* 2008;12(2):369–372
- 5 Kozarek RA, Traverso LW. Pancreatic fistulas and ascites. In: Brandt JL, ed. *Textbook of Clinical Gastroenterology*. Philadelphia: Current Medicine; 1998:1175–1181
- 6 Rockey DC, Cello JP. Pancreaticopleural fistula. Report of 7 patients and review of the literature. *Medicine (Baltimore)* 1990;69(6):332–344
- 7 Ondrejka P, Faller J, Siket F, et al. Isolated massive pleural effusion caused by pancreatico-pleural fistula. *Z Gastroenterol* 2000;38(7):583–585
- 8 Safadi BY, Marks JM. Pancreatic-pleural fistula: the role of ERCP in diagnosis and treatment. *Gastrointest Endosc* 2000;51(2):213–215
- 9 Oh YS, Edmondowicz SA, Jonnalagadda SS, Azar RR. Pancreaticopleural fistula: report of two cases and review of the literature. *Dig Dis Sci* 2006;51(1):1–6
- 10 Wypych K, Serafin Z, Gałazka P, et al. Pancreaticopleural fistulas of different origin: report of two cases and a review of literature. *Pol J Radiol* 2011;76(2):56–60
- 11 Hastier P, Rouquier P, Buckley M, Simler JM, Dumas R, Delmont JP. Endoscopic treatment of wirsungo-cysto-pleural fistula. *Eur J Gastroenterol Hepatol* 1998;10(6):527–529
- 12 Uchiyama T, Suzuki T, Adachi A, Hiraki S, Iizuka N. Pancreatic pleural effusion: case report and review of 113 cases in Japan. *Am J Gastroenterol* 1992;87(3):387–391
- 13 Sut M, Gray R, Ramachandran M, Diamond T. Pancreaticopleural fistula: a rare complication of ERCP-induced pancreatitis. *Ulster Med J* 2009;78(3):185–186
- 14 King JC, Reber HA, Shiraga S, Hines OJ. Pancreatic-pleural fistula is best managed by early operative intervention. *Surgery* 2010;147(1):154–159
- 15 Wronski M, Slodkowski M, Cebulski W, Moronczyk D, Krasnodebski IW. Optimizing management of pancreaticopleural fistulas. *World J Gastroenterol* 2011;17(42):4696–4703
- 16 Ali T, Srinivasan N, Le V, Chimpiri AR, Tierney WM. Pancreaticopleural fistula. *Pancreas* 2009;38(1):e26–e31
- 17 Sonoda S, Taniguchi M, Sato T, et al. Bilateral pleural fluid caused by a pancreaticopleural fistula requiring surgical treatment. *Intern Med* 2012;51(18):2655–2661
- 18 Tajima Y, Fukuda K, Tsuneoka N, et al. Demonstration of a pancreaticopleural fistula with magnetic resonance cholangiopancreatography. *Am J Surg* 2004;187(6):741–742
- 19 Shibasaki S, Yamaguchi H, Nanashima A, et al. Surgical treatment for right pleural effusions caused by pancreaticopleural fistula. *Hepatogastroenterology* 2003;50(53):1678–1680
- 20 Materne R, Vranckx P, Pauls C, Coche EE, Deprez P, Van Beers BE. Pancreaticopleural fistula: diagnosis with magnetic resonance pancreatography. *Chest* 2000;117(3):912–914
- 21 Dhebri AR, Ferran N. Nonsurgical management of pancreaticopleural fistula. *JOP* 2005;6(2):152–161
- 22 Maskell NA, Butland RJ; Pleural Diseases Group, Standards of Care Committee, British Thoracic Society. BTS guidelines for the investigation of a unilateral pleural effusion in adults. *Thorax* 2003;58(Suppl 2):ii8–ii17
- 23 Vyas S, Gogoi D, Sinha SK, Singh P, Yadav TD, Khandelwal N. Pancreaticopleural fistula: an unusual complication of pancreatitis diagnosed with magnetic resonance cholangiopancreatography. *JOP* 2009;10(6):671–673
- 24 Duchmann JC, Joly JP, Brazier F, Delcenserie R, Capron JP. Pancreaticopleural fistula diagnosed sonographically. *AJR Am J Roentgenol* 1995;165(6):1551–1551
- 25 Akahane T, Kuriyama S, Matsumoto M, et al. Pancreatic pleural effusion with a pancreaticopleural fistula diagnosed by magnetic resonance cholangiopancreatography and cured by somatostatin analogue treatment. *Abdom Imaging* 2003;28(1):92–95
- 26 Saeed ZA, Ramirez FC, Hepps KS. Endoscopic stent placement for internal and external pancreatic fistulas. *Gastroenterology* 1993;105(4):1213–1217
- 27 Miyachi A, Kikuyama M, Matsubayashi Y, Kageyama F, Sumiyoshi S, Kobayashi Y. Successful treatment of pancreaticopleural fistula by nasopancreatic drainage and endoscopic removal of pancreatic duct calculi: a case report. *Gastrointest Endosc* 2004;59(3):454–457
- 28 Will U, Meyer F, Manger T, Wanzar I. Endoscopic ultrasound-assisted rendezvous maneuver to achieve pancreatic duct drainage in obstructive chronic pancreatitis. *Endoscopy* 2005;37(2):171–173
- 29 Mallery S, Matlock J, Freeman ML. EUS-guided rendezvous drainage of obstructed biliary and pancreatic ducts: report of 6 cases. *Gastrointest Endosc* 2004;59(1):100–107
- 30 Khan AZ, Ching R, Morris-Stiff G, England R, Sherridan MB, Smith AM. Pleuropancreatic fistulae: specialist center management. *J Gastrointest Surg* 2009;13(2):354–358
- 31 Pai CG, Suvarna D, Bhat G. Endoscopic treatment as first-line therapy for pancreatic ascites and pleural effusion. *J Gastroenterol Hepatol* 2009;24(7):1198–1202
- 32 Varadarajulu S, Noone TC, Tutuian R, Hawes RH, Cotton PB. Predictors of outcome in pancreatic duct disruption managed by endoscopic transpapillary stent placement. *Gastrointest Endosc* 2005;61(4):568–575
- 33 Neher JR, Brady PG, Pinkas H, Ramos M. Pancreaticopleural fistula in chronic pancreatitis: resolution with endoscopic therapy. *Gastrointest Endosc* 2000;52(3):416–418
- 34 Salih A. Massive pleural effusion. *Postgrad Med J* 2001;77(910):536–546–547
- 35 Lipsett PA, Cameron JL. Internal pancreatic fistula. *Am J Surg* 1992;163(2):216–220
- 36 Williams SG, Bhupalan A, Zureikat N, et al. Pleural effusions associated with pancreaticopleural fistula. *Thorax* 1993;48(8):867–868
- 37 Simons MP, Hoitsma HF, Geraedts AA, Schipper ME. Bilateral pancreaticopleural fistulae treated by distal pancreatectomy. *Br J Surg* 1992;79(7):670–671
- 38 Iglesias JL, Cobb J. Recurrent left pleural effusion. *Chest* 2009;10(6):671–673