



# Measuring Acetabular Version after Total Hip Arthroplasty: A Comparison of Two Radiographic Methods\*

## *Medição da versão acetabular após artroplastia total do quadril: comparação de dois métodos radiográficos*

Afonso Cardoso<sup>1</sup> Mafalda Duarte<sup>2</sup> Rui Viegas<sup>1</sup> Filipe Oliveira<sup>1</sup> Pedro Pinto<sup>1</sup> Paulo Rego<sup>1</sup>

<sup>1</sup>Department of Orthopedics and Traumatology, Hospital Beatriz Ângelo, Loures, Portugal

<sup>2</sup>Faculty of Medicine, University of Lisboa, Lisboa, Portugal

Address for correspondence Afonso Nobre Pinto Cardoso, MD, Department of Orthopedics and Traumatology, Hospital Beatriz Ângelo, Av. Carlos Teixeira, 514, 2674, Loures, Portugal (e-mail: afonso.cardoso@hbeatrizangelo.pt).

Rev Bras Ortop 2021;56(4):513–516.

### Abstract

**Objective** The objective of the present work was to compare the measurement of acetabular component version on anteroposterior (AP) and on cross-table radiographs after total hip arthroplasty (THA).

**Methods** Radiographs of 60 hips with a primary THA were selected. Version was calculated on the AP radiograph using the Lewinnek method and, on the cross-table, using the Woo and Morrey direct method.

**Results** Mean and standard deviation (SD) were different on both radiographs, being  $9.7^\circ \pm 5.5^\circ$  on the AP, whereas in the cross-table the measurements were  $20.6^\circ \pm 8.4^\circ$  ( $p < 0.001$ ). Missing our aim of  $10^\circ$ , the cross-table measurements were statistically different from it ( $p < 0.001$ ), while the AP measurement did not differ ( $p = 0.716$ ).

**Conclusion** The present study showed that the best way to correctly evaluate the acetabular component positioning following a THA is by measuring anteversion and abduction on an AP radiograph after confirming, in a cross-table radiograph, that the component is not retroverted.

### Keywords

- ▶ arthroplasty, replacement, hip
- ▶ acetabulum
- ▶ radiography

### Resumo

**Objetivo** O objetivo do presente trabalho foi comparar a medição da versão do componente acetabular em radiografias em incidência anteroposterior (AP) e *cross-table* após artroplastia total do quadril (ATQ).

**Métodos** Foram selecionadas radiografias de 60 quadris com ATQ primário. A versão foi calculada na radiografia AP usando o método de Lewinnek e, na *cross-table*, usando o método direto do Woo e Morrey.

\* Work developed at the Department of Orthopedics and Traumatology, Hospital Beatriz Ângelo, Loures, Portugal.

received  
March 10, 2020  
accepted  
September 16, 2020  
published online  
March 22, 2021

DOI <https://doi.org/10.1055/s-0040-1721360>.  
ISSN 0102-3616.

© 2021. Sociedade Brasileira de Ortopedia e Traumatologia. All rights reserved.

This is an open access article published by Thieme under the terms of the Creative Commons Attribution-NonDerivative-NonCommercial-License, permitting copying and reproduction so long as the original work is given appropriate credit. Contents may not be used for commercial purposes, or adapted, remixed, transformed or built upon. (<https://creativecommons.org/licenses/by-nc-nd/4.0/>)

Thieme Revinter Publicações Ltda., Rua do Matoso 170, Rio de Janeiro, RJ, CEP 20270-135, Brazil

**Resultados** A média e o desvio padrão (DP) foram diferentes em ambas as radiografias, sendo  $9,7^\circ \pm 5,5^\circ$  no AP, enquanto na *cross-table* foram  $20,6^\circ \pm 8,4^\circ$  ( $p < 0,001$ ). Considerando nosso objetivo de  $10^\circ$ , as medidas da *cross-table* foram estatisticamente diferentes dele ( $p < 0,001$ ), enquanto a medição AP não diferiu ( $p = 0,716$ ).

**Palavras-chave**

- ▶ artroplastia de quadril
- ▶ acetábulo
- ▶ radiografia

**Conclusão** O presente estudo mostrou que a melhor maneira de avaliar corretamente o posicionamento do componente acetabular após uma ATQ é medindo a anteversão e a abdução em uma radiografia AP após confirmar, em uma radiografia *cross-table*, que o componente não é retrovertido.

## Introduction

Stability is one of the most important factors and objectives in a total hip arthroplasty (THA) and, to achieve it, correct component placement is of paramount importance.<sup>1</sup> An important cause of dislocation has been shown to be poor acetabular component positioning, which also leads to a limited range of motion and increased polyethylene wear.<sup>2-4</sup> Acetabular position is defined by its abduction and its version.<sup>5</sup> Abduction is defined as the angle between the face of the cup and the transverse axis, whereas version is defined as the angle between the axis of the component and the coronal plane.<sup>5</sup> The importance of these parameters lie in the recognition that subtle orientation differences can lead to a higher rate of dislocations.<sup>6</sup> Lewinnek et al. have suggest that an ideal cup should have an abduction of  $40^\circ$  and an anteversion of  $15^\circ$ .<sup>7</sup> While acetabular abduction is relatively easy to measure on anteroposterior (AP) radiographs, the same is not true for version. Numerous studies have focused on different methods to measure version on radiographs, although not all have been shown to be consistent and accurate.<sup>5,7-12</sup> An ideal method should be accurate, reproducible, and feasible within a day-to-day practice. To measure abduction, a pelvis AP radiograph is used, whereas to measure version, the methods consist of different mathematical equations that use AP radiographs or a direct measure on a cross-table radiograph.<sup>5,7-12</sup> Although it is true that the measurement of version is made simple with cross-table radiographs, these radiographs are often dependent on good quality images, which can be compromised by contralateral hip joint stiffness.<sup>13</sup>

The objective of the present work was to compare the measure of acetabular component version on an AP radiograph using the Lewinnek method and the direct measure on a cross-table radiograph. Our hypothesis is that the cross-table radiograph is more influenced by patient positioning, what could lead to an incorrect measure of acetabular version.

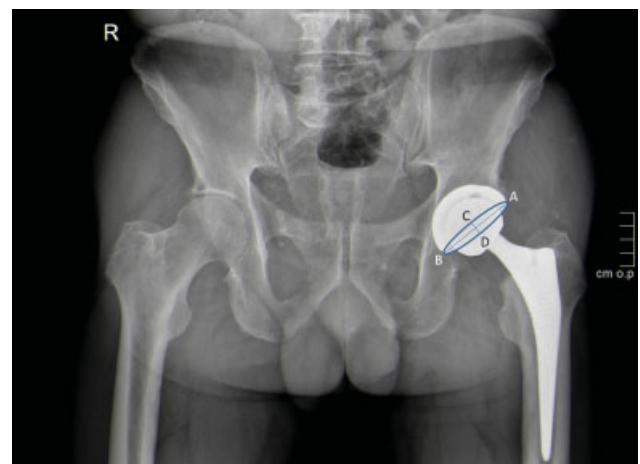
## Material and Methods

Between June 2018 and July 2018, patients who attended our hospital were screened for inclusion in the present study. The inclusion criteria were previously primary THA for primary coxarthrosis done at our institution. Patients with a history of

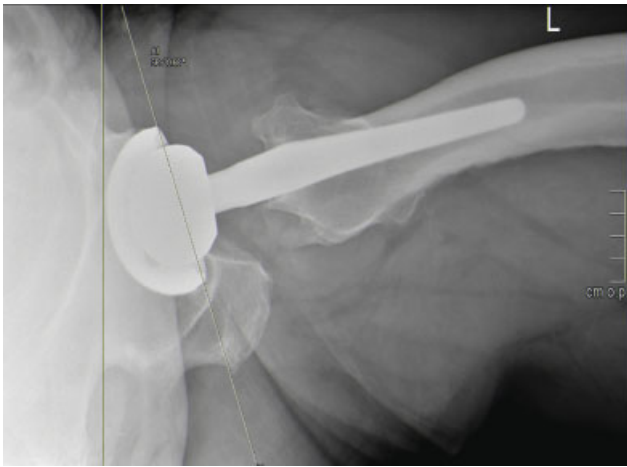
instrumented spine surgery were excluded. Selected patients underwent a pelvic AP and a cross-table radiograph. The present study was approved by the institution's ethics committee and informed consent was obtained from all patients. In all patients, the same acetabular component was used (Epifit, Smith & Nephew, London, United Kingdom). We use the alignment guide, according to the surgical technique, to place the acetabular component in  $10^\circ$  of anteversion.

All radiographs were taken in the same radiology department according to a standard protocol. Pelvic AP radiographs were done in the supine position, with both hips extended, with a source-image distance of 100 cm from the film, perpendicular to the patient, centered on the superior aspect of the pubic symphysis. Cross-table lateral radiographs were taken with the contralateral hip flexed as much as possible up to  $90^\circ$ , with the central ray angled perpendicularly to the long axis of the neck of the femur ( $45^\circ$  cephalad), parallel to the examination table. All images were acquired, and all measurements were made using the Picture Archiving and Communication System (PACS) software (syngo.plaza, Siemens Healthineers, Erlangen, Germany).

Version was calculated on the AP radiograph using the Lewinnek method.<sup>7</sup> In this method, the ellipse formed by the acetabular component is used so that version =  $\sin^{-1}$  (short axis/long axis) (►Fig. 1) On the cross-table radiograph, version was the measured angle between a line perpendicular to the examination table and a tangential line to the



**Fig. 1** Representation of the Lewinnek method: version =  $\sin^{-1}$  (AB / CD).



**Fig. 2** Representation of the Woo and Morrey method: version = angle between a perpendicular line and a tangential line to the opening face of the acetabular component.

opening face of the acetabular component as described by Woo et al.<sup>4</sup> (► **Fig. 2**). Cross-table radiographs were also analyzed with the objective of excluding retroversion, which would be undetectable in the AP radiographs.

The normality of the data was tested with the Kolmogorov-Smirnov test. The data were compared and analyzed using the Student *t*-test for one and dependent samples, and the Mann-Whitney or the Wilcoxon test, according to the normality of the data. The correlation of data was analyzed with the Pearson or Spearman correlation coefficient according to its normality. Nominal variables were compared using the chi-squared test. *P*-values < 0.05 were considered significant. Dedicated statistical software (IBM SPSS Statistics for Windows, Version 21, IBM Corp., Armonk, NY, USA) was used.

## Results

We identified and included 54 patients (60 hips). There were 36 men and 18 women and the average age of the patients at surgery was 68,5 years old. No differences were found between the measurements and age or gender. The mean follow-up was of 45.3 months (24–71 months).

For the anteversion measure by the Lewinnek method on AP radiographs, the mean and standard deviation (SD) were  $9.7^\circ \pm 5.5^\circ$  ( $2^\circ$ – $21^\circ$ ). For the anteversion measure on cross-table radiographs, it was  $20.6^\circ \pm 8.4^\circ$  ( $0^\circ$ – $40^\circ$ ). As such, no cases of retroversion were present. There was a positive correlation between both methods ( $n = 60$ ,  $r = 0.642$ ,  $p < 0.0001$ ). However, both measures gave statistically different results ( $p < 0.001$ ). The mean and SD for the difference of both methods was  $10.8^\circ \pm 6.6^\circ$  ( $-13^\circ$ – $29^\circ$ ). Minding our aim of  $10^\circ$  of anteversion, we tested both measurements against that value and found the cross-table measurement to be statistically different from it ( $p < 0.0001$ ), while the AP measurement did not differ ( $p = 0.716$ ).

## Discussion

Following THA, there are several imagological exams that can be performed to assess the status of the arthroplasty and

evaluate the position of the components. Although those exams, such as computed tomography (CT) scans, can be more accurate, they represent increased costs and radiation for the patient. Therefore, traditional radiography continues to be the most important exam in the follow-up of arthroplasties.

Component positioning is essential for its stability, function and longevity.<sup>2,3,7</sup> However, how to achieve it, namely, how much acetabular anteversion to give, remains controversial. Various authors recommend between  $0^\circ$  and  $30^\circ$  of anteversion.<sup>1,14,15</sup> At our center, we aim for an anteversion of  $10^\circ$ . While the Lewinnek concept of safe zone has guided acetabular component positioning for many years, there is evidence that an important proportion of THAs dislocate within that safe zone<sup>16,17</sup> Furthermore, acetabular anteversion should not be analyzed on its own, as combined femoral and acetabular anteversion might better predict dislocation risk.<sup>18</sup> On the other hand, other authors try to place the acetabular component in an anatomic position according to specific patient anatomic references (such as the transverse acetabular ligament).<sup>19,20</sup> Which of the two methods produce better results, however, is still a matter of debate. Surgeons should keep in mind that the stability of a THA is an interplay between specific patient anatomy and component positioning, and is also dependent on proper restoration of soft tissue tension and balance.

While it is easy to measure acetabular abduction, the same is not true for anteversion. Nho et al. studied various methods and concluded that the Lewinnek, Hassan and Liaw methods, based on AP radiographs, were similar to measurements made on CT scans.<sup>10</sup> In their study, they also included the Woo et al. method for cross-table radiographs, which also gave similar results.<sup>10</sup> However, another study by Arai et al. found a difference of  $5^\circ$  between AP and cross-table measurements.<sup>13</sup> Furthermore, and perhaps more clinically relevant, they also found a correlation between a contralateral stiff hip and the measurement of acetabular version on the cross-table radiograph due to pelvic tilting.<sup>13</sup>

In our study, we found a mean acetabular anteversion of  $9.7^\circ \pm 5.5^\circ$  while using the Lewinnek method on an AP radiograph, which is not significantly different from our aim of  $10^\circ$ . On the other hand, using the cross-table radiograph, we measured an anteversion of  $20.6^\circ \pm 8.4^\circ$  which significantly differs from our surgical target. Both measurements were statistically different from one another. We also note a wider range of measurements in the cross-table radiographs ( $40^\circ$  versus  $19^\circ$ ). We found a moderate correlation between both methods, which is below expectations when measuring the same parameter.

Cross-table radiographs, when proper positioning is stressed, have been shown to accurately determine acetabular anteversion.<sup>21</sup> However, given the results of the present study, we believe that this method is prone to inaccuracy, due to poor positioning, probably related to contralateral hip or lumbar stiffness. Additionally, it is our opinion that pelvic tilt is harder to detect on cross-table radiographs than on AP incidences, which precludes negligent errors in the later, but not in the former radiographs. Notwithstanding, AP radiographs have some limitations because retroversion cannot be detected, and

the apex of the ellipse is somewhat difficult to identify when a metal liner is used.

Regarding the limitations of our study, a measurement standard, such as a CT scan, could further strengthen our conclusions.

## Conclusion

The present study showed that the best way to correctly evaluate the acetabular component positioning following a THA is by measuring anteversion and abduction on an AP radiograph after confirming, in a cross-table radiograph, that the component is not retroverted.

### Financial Support

There was no financial support from public, commercial, or non-profit sources.

### Conflict of Interests

The authors have no conflict of interests to declare.

## References

- Charnley J. Total hip replacement by low-friction arthroplasty. *Clin Orthop Relat Res* 1970;72(72):7-21
- Del Schutte H Jr, Lipman AJ, Bannar SM, Livermore JT, Ilstrup D, Morrey BF. Effects of acetabular abduction on cup wear rates in total hip arthroplasty. *J Arthroplasty* 1998;13(06):621-626
- Widmer KH, Zurfluh B. Compliant positioning of total hip components for optimal range of motion. *J Orthop Res* 2004;22(04):815-821
- Woo RY, Morrey BF. Dislocations after total hip arthroplasty. *J Bone Joint Surg Am* 1982;64(09):1295-1306
- Murray DW. The definition and measurement of acetabular orientation. *J Bone Joint Surg Br* 1993;75(02):228-232
- Biedermann R, Tonin A, Krismer M, Rachbauer F, Eibl G, Stöckl B. Reducing the risk of dislocation after total hip arthroplasty: the effect of orientation of the acetabular component. *J Bone Joint Surg Br* 2005;87(06):762-769
- Lewinnek GE, Lewis JL, Tarr R, Compere CL, Zimmerman JR. Dislocations after total hip-replacement arthroplasties. *J Bone Joint Surg Am* 1978;60(02):217-220
- Ackland MK, Bourne WB, Uhthoff HK. Anteversion of the acetabular cup. Measurement of angle after total hip replacement. *J Bone Joint Surg Br* 1986;68(03):409-413
- Müller O, Reize P, Trappmann D, Wülker N. Measuring anatomical acetabular cup orientation with a new X-ray technique. *Comput Aided Surg* 2006;11(02):69-75
- Nho JH, Lee YK, Kim HJ, Ha YC, Suh YS, Koo KH. Reliability and validity of measuring version of the acetabular component. *J Bone Joint Surg Br* 2012;94(01):32-36
- Visser JD, Konings JG. A new method for measuring angles after total hip arthroplasty. A study of the acetabular cup and femoral component. *J Bone Joint Surg Br* 1981;63B(04):556-559
- Widmer KH. A simplified method to determine acetabular cup anteversion from plain radiographs. *J Arthroplasty* 2004;19(03):387-390
- Arai N, Nakamura S, Matsushita T. Difference between 2 measurement methods of version angles of the acetabular component. *J Arthroplasty* 2007;22(05):715-720
- Coventry MB. Late dislocations in patients with Charnley total hip arthroplasty. *J Bone Joint Surg Am* 1985;67(06):832-841
- Seki M, Yuasa N, Ohkuni K. Analysis of optimal range of socket orientations in total hip arthroplasty with use of computer-aided design simulation. *J Orthop Res* 1998;16(04):513-517
- Abdel MP, von Roth P, Jennings MT, Hanssen AD, Pagnano MW. What Safe Zone? The Vast Majority of Dislocated THAs Are Within the Lewinnek Safe Zone for Acetabular Component Position. *Clin Orthop Relat Res* 2016;474(02):386-391
- Esposito CI, Gladnick BP, Lee YY, et al. Cup position alone does not predict risk of dislocation after hip arthroplasty. *J Arthroplasty* 2015;30(01):109-113
- Jolles BM, Zangger P, Leyvraz PF. Factors predisposing to dislocation after primary total hip arthroplasty: a multivariate analysis. *J Arthroplasty* 2002;17(03):282-288
- Ha YC, Yoo JJ, Lee YK, Kim JY, Koo KH. Acetabular component positioning using anatomic landmarks of the acetabulum. *Clin Orthop Relat Res* 2012;470(12):3515-3523
- Bhaskar D, Rajpura A, Board T. Current Concepts in Acetabular Positioning in Total Hip Arthroplasty. *Indian J Orthop* 2017;51(04):386-396
- McArthur B, Cross M, Geatrakas C, Mayman D, Ghelman B. Measuring acetabular component version after THA: CT or plain radiograph? *Clin Orthop Relat Res* 2012;470(10):2810-2818