

# Intradiskal Injection of Methylene Blue for Discogenic Back Pain: A Meta-Analysis of Randomized Controlled Trials

Ming Deng<sup>1,#</sup> Hui Huang<sup>2,#</sup> Yong-gang Ma<sup>1</sup> Yan Zhou<sup>1</sup> Qing Chen<sup>1</sup> Ping Xie<sup>3</sup>

<sup>1</sup>Department of Orthopedics, Renmin Hospital of Wuhan University, Wuhan, Hubei Province, P. R. China

<sup>2</sup>Department of Orthopedics, Hainan Provincial People's Hospital, Haikou, Hainan, P. R. China

<sup>3</sup>Department of Chinese Traditional Medicine, Tongren Hospital of Wuhan University, Wuhan, Hubei Province, P. R. China

Address for correspondence Ping Xie, MD, Department of Chinese Traditional Medicine, Tongren Hospital of Wuhan University, No. 241, Peng Liu Yang Road, Wuchang District, Wuhan, Hubei Province, P. R. China (e-mail: 395460475@qq.com).

J Neurol Surg A 2021;82:161–165.

## Abstract

**Introduction** Intradiskal injection of methylene blue has some potential in alleviating discogenic back pain. This meta-analysis aims to explore the impact of intradiskal injection of methylene blue for discogenic back pain.

**Methods** Several databases such as PubMed, Embase, Web of Science, EBSCO, and Cochrane Library databases have been searched through November 2019, and randomized controlled trials (RCTs) assessing the effect of intradiskal injection of methylene blue for discogenic back pain are included.

**Results** Three RCTs are included in the meta-analysis. Overall, compared with control group for discogenic back pain, intradiskal injection of methylene blue remarkably decreased pain scores at 3 months (mean difference [MD] = -0.71; 95% confidence interval [CI] = -0.96 to -0.46;  $p < 0.00001$ ) and 6 months (MD = -13.92; 95% CI = -22.31 to -5.54;  $p = 0.001$ ) and Oswestry Disability Index (ODI) at 4 to 6 weeks (MD = -10.39; 95% CI = -16.95 to -3.83;  $p = 0.002$ ) and 3 months (MD = -3.66; 95% CI = -4.85 to -2.48;  $p < 0.00001$ ), but demonstrated no obvious effect on ODI at 6 months (MD = -11.76; 95% CI = -33.33 to 9.80;  $p = 0.28$ ).

**Conclusions** Intradiskal injection of methylene blue can substantially decrease pain scores and improve function for discogenic back pain.

## Keywords

- ▶ methylene blue
- ▶ intradiskal injection
- ▶ discogenic back pain
- ▶ randomized controlled trials
- ▶ meta-analysis

## Introduction

Discogenic back pain is one of the most common types of low back pain, accounting for 28 to 43% of the patients with low back pain.<sup>1–3</sup> Discogenic back pain is mainly caused by internal disk disruption and vascularized granulation tissue containing nociceptive nerves.<sup>4–6</sup> Reduction of inflammation and/or ablation of the nociceptive nerves in the outer

annulus are beneficial to alleviate discogenic back pain.<sup>7,8</sup> Current treatment methods include anti-inflammation strategy and invasive procedures.<sup>9</sup>

Methylene blue is a low-molecular weight, partially liposoluble vital dye.<sup>10,11</sup> It is widely used for destruction of free nociceptive nerve endings for the relief of pain, inhibition of nitric oxide synthesis, and neuroprotective effect.<sup>10,12–15</sup> Its promotion to pain control is derived from inhibition of free radical generation, deactivation of xanthine oxidase, and inhibition of the production of nitric oxide.<sup>16</sup>

# These two authors contributed equally.

received

July 2, 2019

accepted after revision

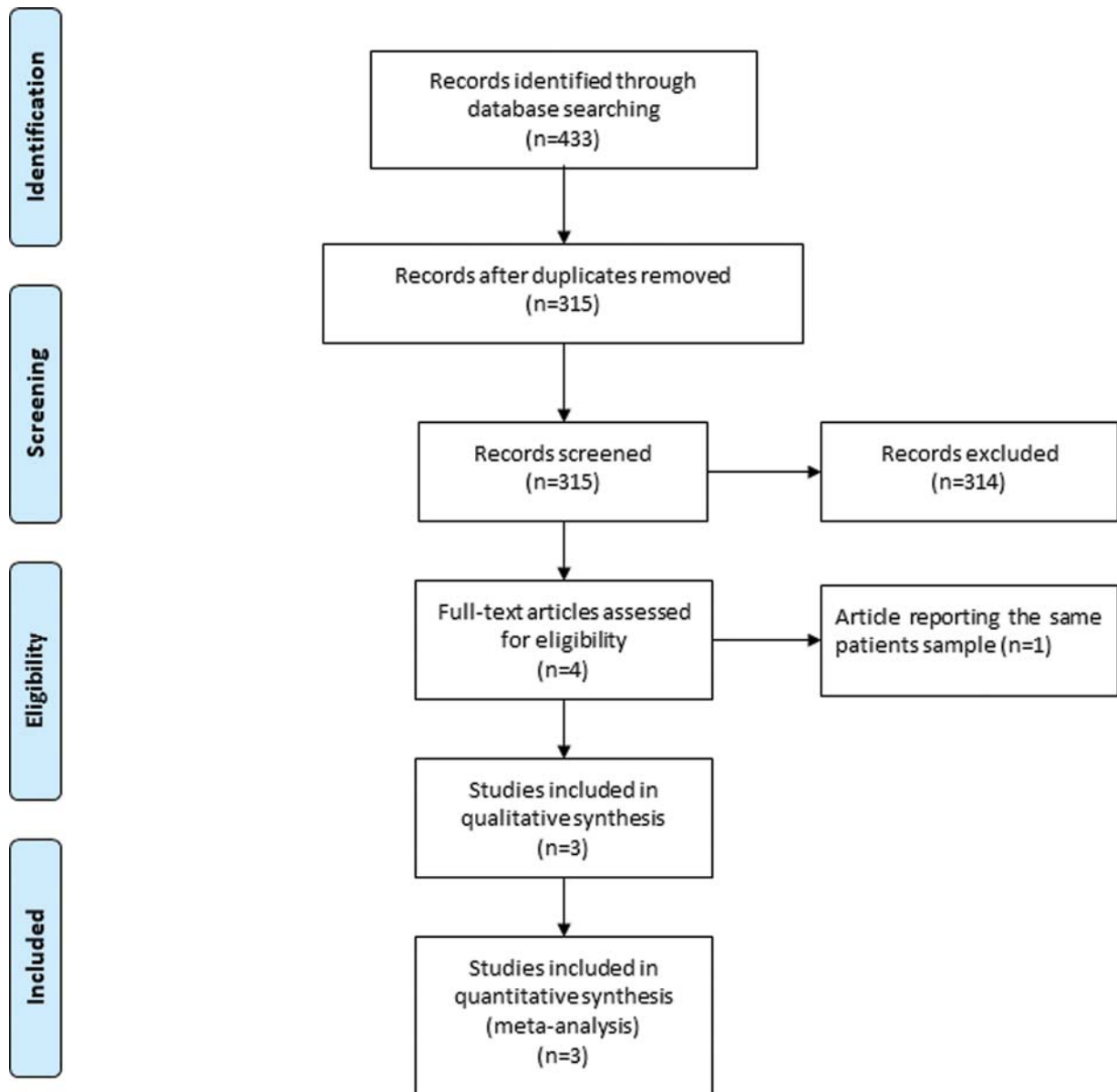
April 7, 2020

published online

January 21, 2021

© 2021, Thieme. All rights reserved.  
Georg Thieme Verlag KG,  
Rüdigerstraße 14,  
70469 Stuttgart, Germany

DOI <https://doi.org/10.1055/s-0040-1721015>  
ISSN 2193-6315.



**Fig. 1** Flow diagram of study searching and selection process.

Several studies have documented the potential of intradiscal injection of methylene blue for discogenic back pain, but there were some conflicting results.<sup>17–19</sup> This meta-analysis aims to investigate intradiscal injection of methylene blue for pain control in patients with discogenic back pain.

## Materials and Methods

This was a systematic review and meta-analysis of previously published studies, and no ethical approval and patient consent were required. This meta-analysis was performed based on Preferred Reporting Items for Systematic Reviews and Meta-Analyses (PRISMA).<sup>20</sup>

### Search Strategy and Study Selection

Two investigators searched the following databases (inception to November 2019): PubMed, EMBase, Web of Science,

EBSCO, and Cochrane Library databases. The keywords for electronic search strategy were discogenic back pain, and methylene blue. The inclusive selection criteria were as follows: (1) study design was randomized controlled trial (RCT); (2) patients were diagnosed with discogenic back pain; (3) intervention treatments were intradiscal injection of methylene blue versus placebo (or ozone ablation).

### Data Extraction and Outcome Measures

We have extracted the following information: author, number of patients, age, male, pain duration, and detail methods in each group, etc. Data have been extracted independently by two investigators, and discrepancies are resolved by consensus. We also contacted the corresponding author to obtain the data when necessary.

The primary outcomes are pain scores at 3 and 6 months. Secondary outcomes include Oswestry Disability Index (ODI) at 4 to 6 weeks, 3 months, and 6 months.

**Table 1** Characteristics of included studies

No.	Author	Methylene blue group					Control group					Jada scores
		No.	Age (y)	Male (n)	Pain duration (y)	Methods	No.	Age (y)	Male (n)	Pain duration (y)	Methods	
1	Kallewaard et al 2019	40	41.2 (9.6)	11	10.2 (8.8)	a mixture of 1-mL methylene blue (10 mg/mL), 0.5-mL lidocaine hydrochloride 2%, and 0.5-mL contrast dye was injected into the disk	41	42.6 (10.2)	12	8.5 (7.1)	placebo	5
2	Zhang 2018	55	38.45 (4.96)	34	3.91 (1.45)	1 ml of methylene blue solution at a concentration of 1% for disk injection	55	38.52 (4.93)	33	3.95 (1.46)	ozone ablation	4
3	Peng et al 2010	36	42.06 (13.74)	21	3.5 (1.6)	1 ml of 1% methylene blue (10 mg) was injected into the discogram-proven diseased disk	36	41.28 (12.84)	20	3.2 (1.7)	placebo	4

### Quality Assessment in Individual Studies

Modified Jadad scale was used to assess the methodological quality of the included studies.<sup>21,22</sup> There were three items for Jadad scale: randomization (0–2 points), blinding (0–2 points), and dropouts and withdrawals (0–1 points). The score of Jadad scale varied from 0 to 5 points. Jadad score  $\geq 3$  indicated high quality, while Jadad score  $\leq 2$  suggested low quality.<sup>23</sup>

### Statistical Analysis

We estimate the standard mean difference (MD) with 95% confidence interval (CI) for all continuous outcomes. The random-effects model is used regardless of heterogeneity. Heterogeneity was reported using the  $I^2$  statistic, and  $I^2 > 50\%$  indicated significant heterogeneity.<sup>24</sup> We searched for potential sources of heterogeneity via omitting one study in turn when encountering significant heterogeneity. Publication bias was not evaluated because of the limited number (<10) of included studies. All statistical analyses were performed using Review Manager Version 5.3 (the Cochrane Collaboration, Software Update, Oxford, UK).

## Results

### Literature Search, Study Characteristics, and Quality Assessment

► **Fig. 1** demonstrates the flowchart of the search and selection result. Four hundred and thirty-three potentially relevant articles were identified initially, and three RCTs were finally included in the meta-analysis.<sup>17–19</sup>

The baseline characteristics of the three eligible RCTs in the meta-analysis are summarized in ► **Table 1**. The three studies were published between 2010 and 2019, and the total sample size was 263. Two RCTs compared methylene blue with placebo,<sup>17,19</sup> and the remaining RCT compared methylene blue with ozone ablation.<sup>18</sup> One RCT was published in Chinese.

Among the three studies included here, two studies reported pain scores at 3 months,<sup>17,18</sup> three studies reported pain scores at 6 months,<sup>17–19</sup> two studies reported ODI at 4 to 6 weeks and at 3 months,<sup>17,19</sup> and three studies reported ODI at 6 months.<sup>17–19</sup> Jadad scores of the three included studies varied from 4 to 5, and all three studies had high quality.

### Primary Outcomes: Pain Scores at 3 and 6 Months

The random-effects model was used, and compared with the control group for discogenic back pain, methylene blue injection substantially decreased pain scores at 3 months (MD = -0.71; 95% CI = -0.96 to -0.46;  $p < 0.00001$ ), with no heterogeneity among the studies ( $I^2 = 0\%$ , heterogeneity  $p = 0.62$ ; ► **Fig. 2**), and 6 months (MD = -13.92; 95% CI = -22.31 to -5.54;  $p = 0.01$ ) with significant heterogeneity among the studies ( $I^2 = 100\%$ , heterogeneity  $p < 0.00001$ ; ► **Fig. 3**).

### Sensitivity Analysis

Significant heterogeneity was observed for pain scores at 6 months. After excluding the study conducted by Peng,<sup>18</sup> no heterogeneity remained ( $I^2 = 0\%$ , heterogeneity  $p = 0.94$ ). Methylene blue injection still resulted in the decrease in pain scores at 6 months compared with the control group.

### Secondary Outcomes

Methylene blue injection significantly reduced ODI at 4 to 6 weeks (MD = -10.39; 95% CI = -16.95 to -3.83;  $p = 0.002$ ; ► **Fig. 4**) and ODI at 3 months (MD = -3.66; 95% CI = -4.85 to -2.48;  $p < 0.00001$ ; ► **Fig. 5**) compared with control intervention for discogenic back pain, but not ODI at 6 months (MD = -11.76; 95% CI = -33.33 to 9.80;  $p = 0.28$ ; ► **Fig. 6**).

## Discussion

Methylene blue is a potent reversible inhibitor of monoamine oxidase A, and has some association with 5-

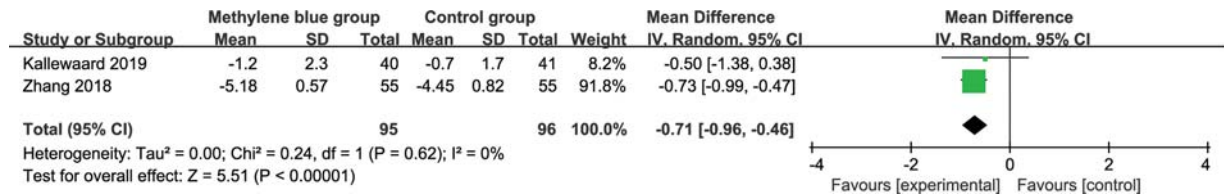


Fig. 2 Forest plot for the meta-analysis of pain scores at 3 months.

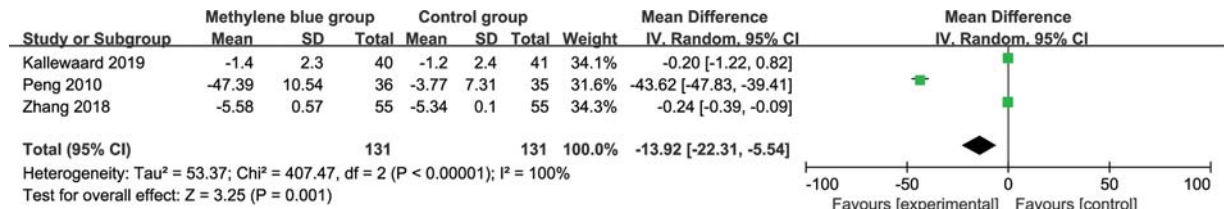


Fig. 3 Forest plot for the meta-analysis of pain scores at 6 months.

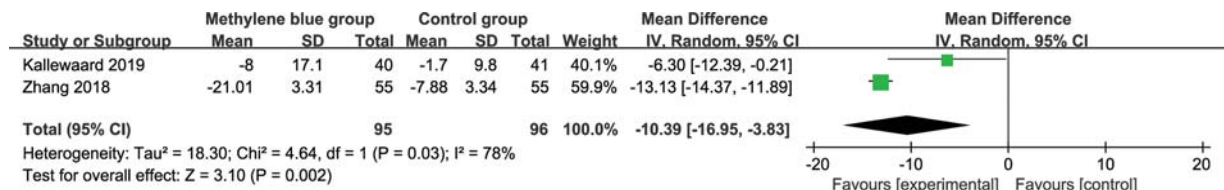


Fig. 4 Forest plot for the meta-analysis of Oswestry Disability Index (ODI) at 4 to 6 weeks.

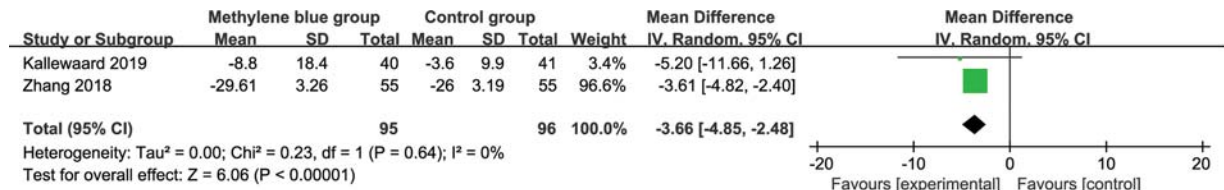


Fig. 5 Forest plot for the meta-analysis of Oswestry Disability Index (ODI) at 3 months.

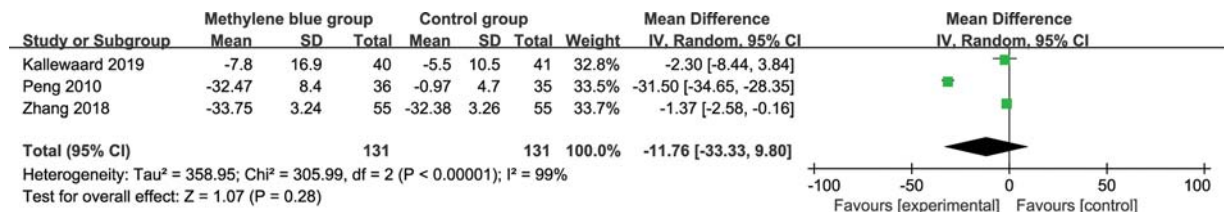


Fig. 6 Forest plot for the meta-analysis of Oswestry Disability Index (ODI) at 6 months.

hydroxytryptamine (5-HT or serotonin) levels.<sup>25</sup> Serotonin (5-HT) may produce some analgesic effects and modulation in the central nervous system depending on the site of action and the receptor subtype.<sup>26,27</sup> Methylene blue shows the neurolytic effect and benefits to various painful conditions and idiopathic pruritus ani.<sup>28</sup> In patients with open lumbar discectomy, the anti-inflammatory method proved to reduce the low back pain after the surgery.<sup>29</sup>

With the anti-inflammatory effect, methylene blue was reported to significantly decrease low back pain and

radicular pain, as well as improve functional outcomes.<sup>19,30</sup> The follow-up of 2 to 3 months is important to evaluate the safety and efficacy of methylene blue for postoperative pain, and 6 months may be sufficient to assess the pain. Intradiskal methylene blue injection was found to relieve at least 30% of pain in 40% of the patients with discogenic low back pain at 6 months.<sup>31</sup> However, another trial revealed no significant pain relief at 6 months after intradiskal methylene blue injection for discogenic low back pain.<sup>32</sup>

This meta-analysis concludes that intradiscal methylene blue injection is associated with substantially reduced pain scores at 3 and 6 months, ODI at 4 to 6 weeks and 3 months compared to control intervention in patients with discogenic low back pain, but there is no statistical difference of ODI at 6 months. There is significant heterogeneity for pain scores at 6 months, and this heterogeneity may be caused by different combination of drugs, control intervention, and patient populations.

Injection of methylene blue into the disk is widely accepted as a safe and effective method for the treatment of discogenic low back pain.<sup>17,19</sup> Several potential limitations may exist in this meta-analysis. First, our analysis is based on only three RCTs and two of them have a relatively small sample size ( $n < 100$ ). There is significant heterogeneity, which may be caused by different combination of drugs, control intervention, and patient populations, all of which may have an influence on the pooling results. Finally, some unpublished and missing data may lead to some bias.

## Conclusion

Intradiscal methylene blue injection has beneficial effects on pain alleviation and functional improvement in patients with discogenic low back pain.

### Conflict of Interest

None declared.

## References

- Luo L, Zhang C, Zhou Q, et al. Effectiveness of transpedicular dynamic stabilization in treating discogenic low back pain. *World Neurosurg* 2018;111:e192–e198
- Schwarzer AC, Aprill CN, Derby R, Fortin J, Kine G, Bogduk N. The prevalence and clinical features of internal disc disruption in patients with chronic low back pain. *Spine* 1995;20(17):1878–1883
- Zhou Y, Abdi S. Diagnosis and minimally invasive treatment of lumbar discogenic pain: a review of the literature. *Clin J Pain* 2006;22(05):468–481
- Simon J, McAuliffe M, Shamim F, Vuong N, Tahaei A. Discogenic low back pain. *Phys Med Rehabil Clin N Am* 2014;25(02):305–317
- Bogduk N, Aprill C, Derby R. Lumbar discogenic pain: state-of-the-art review. *Pain Med* 2013;14(06):813–836
- Buirski G, Silberstein M. The symptomatic lumbar disc in patients with low-back pain. Magnetic resonance imaging appearances in both a symptomatic and control population. *Spine* 1993;18(13):1808–1811
- Duan B, Cheng L, Ma Q. Spinal circuits transmitting mechanical pain and itch. *Neurosci Bull* 2018;34(01):186–193
- Peng B, Wu W, Hou S, Li P, Zhang C, Yang Y. The pathogenesis of discogenic low back pain. *J Bone Joint Surg Br* 2005;87(01):62–67
- Bertagnoli R, Yue JJ, Shah RV, et al. The treatment of disabling multilevel lumbar discogenic low back pain with total disc arthroplasty utilizing the ProDisc prosthesis: a prospective study with 2-year minimum follow-up. *Spine* 2005;30(19):2192–2199
- Wainwright M, Crossley KB. Methylene blue: a therapeutic dye for all seasons? *J Chemother* 2002;14(05):431–443
- Zhang L, Liu Y, Huang Z, et al. Toxicity effects of methylene blue on rat intervertebral disc annulus fibrosus cells. *Pain Physician* 2019;22(02):155–164
- Tan KY, Seow-Choen F. Methylene blue injection reduces pain after lateral anal sphincterotomy. *Tech Coloproctol* 2007;11(01):68–69
- Vaccaro A, Patten SA, Ciura S, et al. Methylene blue protects against TDP-43 and FUS neuronal toxicity in *C. elegans* and *D. rerio*. *PLoS One* 2012;7(07):e42117
- Volke V, Wegener G, Vasar E, Rosenberg R. Methylene blue inhibits hippocampal nitric oxide synthase activity in vivo. *Brain Res* 1999;826(02):303–305
- Aneese AM, Ghaith G, Cannon ME, Manuballa V, Cappell MS. EUS-guided methylene blue injection to facilitate endoscopic cannulation of an obscured pancreatic duct orifice after ampullectomy. *Am J Gastroenterol* 2018;113(05):782–783
- Cohen SP, Williams KA, Kurihara C, et al. Multicenter, randomized, comparative cost-effectiveness study comparing 0, 1, and 2 diagnostic medial branch (facet joint nerve) block treatment paradigms before lumbar facet radiofrequency denervation. *Anesthesiology* 2010;113(02):395–405
- Kallewaard JW, Wintraecken VM, Geurts JW, et al. A multicenter randomized controlled trial on the efficacy of intradiscal methylene blue injection for chronic discogenic low back pain: the IMBI study. *Pain* 2019;160(04):945–953
- Zhang L. Effect of methylene blue injection on lumbar function and pain in patients with discogenic low back pain. *J Nat Med* 2018;3:312–313
- Peng B, Pang X, Wu Y, Zhao C, Song X. A randomized placebo-controlled trial of intradiscal methylene blue injection for the treatment of chronic discogenic low back pain. *Pain* 2010;149(01):124–129
- Moher D, Liberati A, Tetzlaff J, Altman DG, PRISMA Group. Preferred reporting items for systematic reviews and meta-analyses: the PRISMA statement. *J Clin Epidemiol* 2009;62(10):1006–1012
- Jadad AR, Moore RA, Carroll D, et al. Assessing the quality of reports of randomized clinical trials: is blinding necessary? *Control Clin Trials* 1996;17(01):1–12
- Zhao J, Huang W, Zhang S, et al. Efficacy of glutathione for patients with cystic fibrosis: a meta-analysis of randomized-controlled studies. *Am J Rhinol Allergy* 2020;34(01):115–121
- Kjaergard LL, Villumsen J, Gluud C. Reported methodologic quality and discrepancies between large and small randomized trials in meta-analyses. *Ann Intern Med* 2001;135(11):982–989
- Higgins JP, Thompson SG. Quantifying heterogeneity in a meta-analysis. *Stat Med* 2002;21(11):1539–1558
- Delpont A, Harvey BH, Petzer A, Petzer JP. Methylene blue analogues with marginal monoamine oxidase inhibition retain antidepressant-like activity. *ACS Chem Neurosci* 2018;9(12):2917–2928
- Eide PK, Hole K. The role of 5-hydroxytryptamine (5-HT) receptor subtypes and plasticity in the 5-HT systems in the regulation of nociceptive sensitivity. *Cephalalgia* 1993;13(02):75–85
- Yaksh TL, Wilson PR. Spinal serotonin terminal system mediates antinociception. *J Pharmacol Exp Ther* 1979;208(03):446–453
- Mentes BB, Akin M, Leventoglu S, Gultekin FA, Oguz M. Intradermal methylene blue injection for the treatment of intractable idiopathic pruritus ani: results of 30 cases. *Tech Coloproctol* 2004;8(01):11–14
- Farrokhi MR, Lotfi M, Masoudi MS, Gholami M. Effects of methylene blue on postoperative low-back pain and functional outcomes after lumbar open discectomy: a triple-blind, randomized placebo-controlled trial. *J Neurosurg Spine* 2016;24(01):7–15
- Peng B, Zhang Y, Hou S, Wu W, Fu X. Intradiscal methylene blue injection for the treatment of chronic discogenic low back pain. *Eur Spine J* 2007;16(01):33–38
- Kallewaard JW, Geurts JW, Kessels A, Willems P, van Santbrink H, van Kleef M. Efficacy, safety, and predictors of intradiscal methylene blue injection for discogenic low back pain: results of a multicenter prospective clinical series. *Pain Pract* 2016;16(04):405–412
- Levi DS, Horn S, Walko E. Intradiscal methylene blue treatment for diskogenic low back pain. *PM R* 2014;6(11):1030–1037