



Effectiveness of Fluoroscopy-Guided Percutaneous Vertebral Biopsy*

Eficácia da biópsia vertebral percutânea guiada por fluoroscopia

José Nicolás Mireles-Cano¹ Alejandro Miranda Gonzalez² Oscar Guillermo García-González³
Ricardo Martínez Pérez⁴

¹ Spine Surgery, Neurosurgery Department, Hospital Regional de Alta Especialidad del Bajío, Universidad de Guanajuato, León, Guanajuato, México

² Neurosurgery Department, Hospital Regional de Alta Especialidad del Bajío, Universidad de Guanajuato, León, Guanajuato, México

³ Pediatric Neurosurgery, Neurosurgery Department, Hospital Regional de Alta Especialidad del Bajío, Universidad de Guanajuato, León, Guanajuato, México

⁴ Orthopedic Surgery, Orthopedics and Trauma Surgery Department, Centenario Hospital Miguel Hidalgo, Aguascalientes, Aguascalientes, México

Address for correspondence José Nicolás Mireles Cano, Apolo XI, 418, Col. Futurama Monterrey, León, Guanajuato, 37180, México (e-mail: drmirelescano@hotmail.com).

Rev Bras Ortop 2021;56(4):453–458.

Abstract

Objective To define the effectiveness of fluoroscopy-guided percutaneous vertebral biopsy.

Methods Prospective study of patients with vertebral destruction syndrome at one institution. Percutaneous transpedicular vertebral biopsies guided by fluoroscopy were performed, and bony tissue and intervertebral disc tissue were extracted; histopathology and microbiology studies were also performed. Age, sex, vertebral segment, neurologic status, and biopsy and culture results were analyzed.

Results The average age of the patients was 53.8 years (range: 2 to 83 years), and the main spine segment was the lumbar segment in 62% of the cases. According to the impairment scale of the American Spinal Injury Association (ASIA), preoperatively, 49% of the patients were classified as Asia E, and 100% had pain. Definitive etiology was identified in 83% of the sample. The etiology was grouped into three categories: infectious, neoplasia, and degenerative (osteoporotic). The infectious group was composed of 36% of the patients, in whom *Staphylococcus aureus* was the most common agent identified; in 34.9% the sample, the etiology was neoplastic, most commonly multiple myeloma and metastatic disease due to prostate cancer; 21.7% of the patients had osteoporosis. The average surgical time was of 47.5 minutes, the average blood loss was of 10 mL. No complications were reported.

Keywords

- ▶ spine
- ▶ lumbar vertebrae
- ▶ biopsy
- ▶ spinal neoplasms

* Work developed at Hospital Regional de Alta Especialidad del Bajío, Universidad de Guanajuato, Guanajuato, Mexico.

received
March 19, 2020
accepted
July 6, 2020

DOI <https://doi.org/10.1055/s-0040-1718950>.
ISSN 0102-3616.

© 2021. Sociedade Brasileira de Ortopedia e Traumatologia. All rights reserved.

This is an open access article published by Thieme under the terms of the Creative Commons Attribution-NonDerivative-NonCommercial-License, permitting copying and reproduction so long as the original work is given appropriate credit. Contents may not be used for commercial purposes, or adapted, remixed, transformed or built upon. (<https://creativecommons.org/licenses/by-nc-nd/4.0/>)

Thieme Revinter Publicações Ltda., Rua do Matoso 170, Rio de Janeiro, RJ, CEP 20270-135, Brazil

Resumo

Conclusion Transpedicular percutaneous biopsy guided by fluoroscopy had an effectiveness of 83% for the etiological diagnosis of vertebral destruction syndrome in the present series. It should be considered a useful minimally-invasive procedure, which is easy, economical, and reproducible, with low risk of short- and long-term complications.

Objetivo Definir a eficácia da biópsia vertebral percutânea guiada por fluoroscopia. **Métodos** Este é um estudo prospectivo de pacientes com síndrome de destruição vertebral em uma instituição. Os pacientes foram submetidos a biópsias vertebrais transpediculares percutâneas guiadas por fluoroscopia, com obtenção de tecido ósseo e tecido do disco intervertebral, para estudo histopatológico e microbiológico. Idade, sexo, segmento vertebral, estado neurológico, e resultados de biópsia e de cultura foram analisados.

Resultados A idade média dos pacientes foi de 53,8 anos (gama: 2 a 83 anos), e o principal local acometido da coluna foi a segmento lombar, em 62% dos casos. Segundo a escala de disfunção da American Spinal Injury Association (ASIA), no pré-operatório, 49% dos pacientes foram classificados como ASIA E, e 100% apresentavam dor. A etiologia definitiva foi identificada em 83% dos pacientes. A etiologia foi agrupada em três categorias: infecciosa, neoplásica, e degenerativa (osteoporótica). O grupo infeccioso era composto por 36% dos pacientes da amostra, e *Staphylococcus aureus* foi o agente mais comumente identificado; em 34,9% dos casos, a etiologia era neoplásica, principalmente mieloma múltiplo e doença metastática por câncer de próstata; 21,7% dos pacientes apresentavam osteoporose. O tempo cirúrgico médio foi de 47,5 minutos, e a perda média de sangue foi de 10 mL. Nenhuma complicação foi relatada.

Palavras-chave

- ▶ coluna vertebral
- ▶ vértebras lombares
- ▶ biópsia
- ▶ neoplasias da coluna vertebral

Conclusão Nesta série, a biópsia percutânea transpedicular guiada por fluoroscopia teve 83% de eficácia no diagnóstico etiológico da síndrome de destruição vertebral. Este procedimento minimamente invasivo deve ser considerado bom, fácil, barato e reprodutível, com baixo risco de complicações em curto e longo prazos.

Introduction

Vertebral biopsy is essential in the diagnosis and planning of the definitive management of vertebral destruction syndrome.^{1,2} The etiology spectrum for this disabling condition can be divided into neoplastic, infectious or metabolic (osteoporosis) causes. Robertson and Ball³ were the first to report the use of percutaneous vertebral biopsy, Ottolenghi⁴ and Valls et al.⁵ performed aspiration biopsy of the vertebral body, and, finally, Craig,⁶ in 1956, developed a trephine for biopsy. Subsequently, the use of open biopsy has progressively decreased over time.

Percutaneous biopsy is a minimally-invasive, fast, low-cost, and minimally-complicated technique that enables vertebral bony and soft tissue to be obtained for histopathology and microbiology analyses. There are series that were able to identify an infectious causative agent in 60% of spine infections with this technique; in other papers, a histopathological conclusive diagnosis was obtained in 55% to 90% of the cases;⁷ these results raise doubts about its diagnostic utility.

The use of transpedicular instrumentation systems as well as kyphoplasty and percutaneous instrumentation have made the vertebral biopsy technique a practical method

for the spine specialist. At our hospital, since the establishment of the Spine Surgery Department, 11 years ago, percutaneous vertebral biopsy guided by fluoroscopy has been performed in patients with vertebral destruction syndrome; the present study assesses the effectiveness of this technique.

The objective of the present paper is to define the effectiveness of fluoroscopy-guided percutaneous vertebral biopsy in the diagnostic approach of vertebral destruction syndrome.

Patients and Methods

A prospective study was performed in a single reference center, from January 2008 to March 2012, in a cohort of 100 patients chosen through the convenience method. All patients were sent from secondary-care hospitals from 7 different states in the country to be evaluated by the Spine Surgery Department as outpatients, and they were admitted until a procedure was scheduled or as needed. Those patients who presented vertebral destruction syndrome, without a definitive diagnosis, who accepted the percutaneous biopsy procedure and signed the informed consent were included; patients who had a history of prior surgery, who already had

a diagnosis of primary disease directly related to vertebral destruction syndrome were excluded. Moreover, those with medical restrictions regarding being placed in a ventral position (hemodynamically decompensated chronic obstructive pulmonary disease, pregnancy, morbid obesity) were also excluded. All patients underwent a preset study protocol with basic laboratory exams such as blood count, blood chemistry, serum electrolytes, coagulation times, and special serum analysis, such as the rate of erythrocyte sedimentation, febrile reactions, Bence Jones protein, among others. Anteroposterior and lateral simple radiographs, computed tomography, both simple and contrasted, nuclear magnetic resonance, and bone scans were also obtained.

Biopsy Technique

After anesthesia, the patients were placed on ventral recumbency position on the pectoral and iliac regions in a conventional surgical bed, with the thoracic limbs directed upwards in the soldier position. Under the arc of fluoroscopy in a C-model Arcadis Orbis (Siemens, Munich, Germany), the area to undergo the biopsy was located and marked on the skin, and submitted to asepsis and antisepsis, and to the placement of sterile fields. The anteroposterior fluoroscopic image corroborated the the affected segment, and the pedicle was located. A 5-mm skin incision was made for the passage of the trocar. The tissues inside the trocar were discarded. An 11G caliber Jamshidi (CareFusion, San Diego, CA, US) biopsy needle was inserted in the pedicle, and the fluoroscopic image was altered to the profile view as needed. The needle was introduced in the pedicle and in 80% of the vertebral body. Two samples were obtained: one by aspiration, and the other through bone puncture (►Fig. 1). The needle was removed, as well as the bone-tissue cylinder, which was immediately sent to the pathology and microbiology service. The trocar was extracted, and the surgical technique was performed again to obtain another sample with the same pedicle entry site, but trying another path toward the

vertebral body. After hemostasis and washing, the wound was closed according to the Sarnoff technique with 3/0 nylon thread, an covered with a sterile patch. After the end of the surgical procedure, the patients were placed on supine on a transfer stretcher. After anesthetic reversal and removal of the orotracheal tube, all patients were sent to a conventional recovery area.

Statistics

Descriptive statistics were performed to determine the average and standard or median deviations and percentiles for the numerical variables according to their distribution, as well as the frequencies for the nominal variables. The sensitivity and specificity of the fever in every etiologic group were analyzed. Finally, the effectiveness of the test was determined.

Results

Among the 100 patients included, 57 of them were men (57%), while 43 patients were women (43%), aged between 2 and 83 years (average of 53.85 years; standard deviation: 17.5). The age distribution was mainly patients between the ages of 51 and 60 years, with 29 cases (29%), followed by patients aged between 61 and 70, with 28 cases (28%), and the groups aged between 41 and 50 years, and between 71 and 80 years, both with 12 patients (12%) each. The location of the vertebral destructive lesion had the following distribution; cervical in 2 patients (2%), thoracic in 35 patients (35%), lumbar in 56 patients (56%), thoracolumbar in 2 patients (2%), lumbosacral in 4 patients (4%), and sacral in 1 patient (1%) (►Table 1). Upon admission to the study, a spinal neurological examination was performed to classify the patients according to the American Spinal Injury Association (ASIA scale); the most common classification was ASIA E (49%), followed by ASIA D (27%), and ASIA A (12%). Regarding the sensitivity below the injury, 12 patients

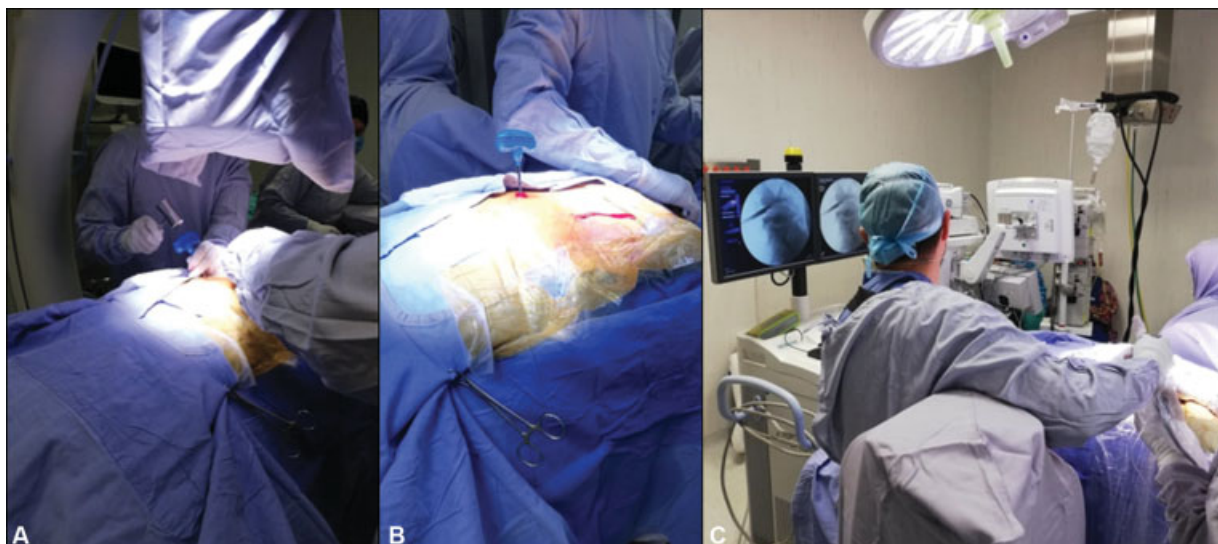


Fig. 1 Biopsy technique. (A) Insertion of the biopsy needle (Jamshidi), fluoroscopy in anteroposterior position; (B) fluoroscopy in lateral position to confirm the correct needle placement; (C) collection of bone and intervertebral disc cylindrical samples.

Table 1 Patient description and results

CASE	SEX	AGE	SEGMENT	ASIA	FEVER	REPORT	ETIOLOGY	CASE	SEX	AGE	SEGMENT	ASIA	FEVER	REPORT	ETIOLOGY
1	F	64	L	C	YES	NSI	I	51	F	63	L	C	NONE	NSI	I
2	F	51	L	E	NONE	OT	M	52	M	56	L	E	NONE	NM	I
3	M	48	T	A	NONE	M	N	53	M	65	T	L	YES	NSI	I
4	F	42	T	E	NONE	M	N	54	F	75	L	E	NONE	NSI	-
5	M	69	T	D	NONE	PN	N	55	F	69	T	C	NONE	PN	N
6	M	45	L	D	YES	M	N	56	M	65	L	C	NONE	PN	N
7	M	58	T	D	NONE	NSI	-	57	F	53	T	A	NONE	PN	N
8	F	58	L	D	NONE	OT	M	58	M	56	T	A	NONE	NSI	I
9	M	59	T	C	NONE	NSI	-	59	M	2	T	E	NONE	GR	I
10	M	63	L	D	NONE	TB	I	60	M	49	T	D	NONE	NSI	-
11	M	37	L	D	YES	NSI	-	61	F	64	L	E	NONE	OT	M
12	F	57	L	E	NONE	OT	M	62	F	59	LS	D	NONE	NSI	I
13	M	67	T	E	NONE	OT	M	63	M	46	L	E	NONE	NSI	I
14	F	51	C	E	NONE	M	N	64	M	46	L	E	NONE	NSI	I
15	M	71	L	E	NONE	NSI	-	65	M	75	L	D	NONE	NSI	I
16	M	55	L	E	YES	NSI	I	66	M	74	T	E	NONE	OT	M
17	F	34	T	E	NONE	GR	I	67	M	74	T	A	NONE	NSI	-
18	M	60	T	E	NONE	M	N	68	F	16	L	E	NONE	NSI	I
19	F	40	T	B	NONE	M	N	69	M	18	T	E	NONE	TB	I
20	M	15	L	A	NONE	PN	N	70	M	28	L	E	NONE	NSI	I
21	F	44	C	D	NONE	M	N	71	M	65	L	E	NONE	NSI	I
22	M	58	L	D	YES	NSI	I	72	M	59	L	D	NONE	NSI	I
23	M	16	T	E	NONE	NSI	I	73	M	68	L	C	NONE	NSI	I
24	M	18	T	E	NONE	GR	I	74	F	62	S	E	NONE	NSI	-
25	F	58	T	B	NONE	NSI	-	75	M	49	T	A	NONE	PN	N
26	M	64	L	D	YES	NSI	I	76	M	64	L	E	NONE	PN	N
27	M	64	T	E	NONE	M	N	77	F	23	LS	E	YES	NSI	I
28	F	31	TL	D	NONE	NSI	-	78	F	71	LS	E	YES	NSI	I
29	M	18	L	D	YES	GR	I	79	F	67	L	E	NONE	OT	M
30	M	67	L	D	YES	NSI	I	80	M	24	L	D	NONE	NSI	I
31	M	59	T	A	NONE	GR	I	81	F	65	T	A	NONE	NSI	I
32	F	63	L	E	NONE	GR	I	82	M	54	L	E	NONE	NSI	-
33	M	83	T	D	NONE	PN	N	83	F	67	L	E	NONE	NSI	-
34	M	54	L	D	NONE	PN	N	84	F	67	L	E	NONE	OT	M
35	F	13	L	D	NONE	PN	N	85	F	61	L	E	NONE	OT	M
36	M	57	L	C	NONE	NSI	I	86	M	56	L	D	NONE	PN	N
37	M	57	T	A	NONE	M	N	87	F	71	L	E	NONE	OT	M
38	M	10	L	A	NONE	PN	N	88	M	41	L	E	NONE	M	N
39	F	79	L	E	NONE	OT	M	89	F	71	L	E	NONE	OT	M
40	F	40	T	A	NONE	NSI	-	90	F	64	L	E	NONE	NSI	I
41	F	70	L	E	NONE	OT	M	91	F	54	L	E	NONE	NSI	-
42	M	53	L	D	NONE	OT	M	92	M	44	LS	E	NONE	NSI	-
43	M	55	L	D	NONE	OT	M	93	F	59	L	C	NONE	NSI	I
44	F	47	L	D	NONE	NSI	I	94	F	78	L	E	NONE	OT	M
45	F	51	T	E	NONE	M	N	95	M	71	T	A	NONE	M	N
46	M	54	T	D	NONE	PN	N	96	M	69	T	D	NONE	PN	N
47	M	70	L	E	NONE	NSI	-	97	F	67	L	E	NONE	PN	N
48	M	25	TL	E	NONE	GR	I	98	F	67	L	D	NONE	PN	N
49	M	54	T	C	NONE	GR	I	99	F	57	T	E	NONE	OT	M
50	M	43	T	C	NONE	M	N	100	F	78	L	E	NONE	OT	M

Abbreviations: ASIA, American Spinal Injury Association; C, cervical; F, female; GR, granulomatous reaction; I, infectious; L, lumbar; LS, lumbosacral; M, male; M, metabolic; M, metastasis; N, neoplastic; NM, negative to malignancy; NSI, non-specific inflammation; OT, osteoporotic tissue; PN, primary neoplasm; TB, tuberculoma; T, thoracic; TL, thoracolumbar.

(12%) were found with anesthesia. Pain was the predominant symptom in 98 (98%) patients. Fever was only present in 11 (11%) patients. After defining the etiology, an analysis of in the infectious group showed 22.2% of sensitivity and 95.3% of specificity. Of these, 10 patients (10%) developed a causative agent in the cultures: 7 (7%) with *Staphylococcus aureus*, 1 (1%) with *Brucella abortus*, and 2 (2%) with microbiota agents. The Bence Jones protein was positive in 3 patients (3%), all of them with a definitive diagnosis of multiple myeloma.

The definitive diagnosis was obtained in 83 out of 100 patients, obtaining an effectiveness of 83% (→ **Table 2**).

Overall, 36 patients (36%), presented a conclusive diagnosis with positive cultures, with the isolation of *S. aureus* in 17 patients (17%) followed by *B. abortus* in 10 patients (10%), and *M. tuberculosis* in 9 patients (9%).

In total, 29 patients (29%) presented a disease with a neoplastic etiology confirmed on the histopathological analysis; the most common primary tumor was multiple myeloma, with 9 cases (9%), followed by 2 patients (2%) with plasmacytoma, 2 (2%) with Ewing tumor, 1 case (1%) of neuroblastoma, 1 case (1%) of giant-cell tumor, and 1 case (1%) of chondroma. Regarding tumors of metastatic origin, prostate-cancer metastasis was diagnosed in 4 patients (4%),

Table 2 Distribution of etiologic groups, microbial agents, and histopathology conclusion

ETIOLOGIC GROUP	CASES	N
INFECTIOUS	43.37%	36
<i>Staphylococcus aureus</i>	38.63%	17
<i>Brucella abortus</i>	22.72%	10
<i>Mycobacterium tuberculosis</i>	20.45%	9
<i>Escherichia coli</i>	2.27%	1
NEOPLASTIC	34.94%	29
PRIMARY TUMOR	55.1%	16
MULTIPLE MYELOMA	31.03%	9
PLASMACYTOMA	6.89%	2
EWING TUMOR	6.89%	2
NEUROBLASTOMA	3.44%	1
GIANT-CELL TUMOR	3.44%	1
CHONDROMA	3.44%	1
METASTASIS	44.82%	13
PROSTATE	13.79%	4
LUNG	10.34%	3
ESOPHAGUS	6.89%	2
BREAST	3.44%	1
OVARY	3.44%	1
BILLIARY TRACT	3.44%	1
SKIN (BASOCELLULAR CANCER)	3.44%	1
METABOLIC	21.69%	18
OSTEOPOROSIS	100%	18

as well as lung cancer metastasis in 3 cases (3%); the remaining tumors found were breast, ovarian, and esophageal cancers, and basal-cell and bile-duct carcinomas.

In total, 18 patients (18%) were included in the osteoporosis etiology group due to the absence of microbiological development in the cultures and findings compatible with chronic degenerative changes, such as significant trabecular decrease in the histopathological study.

Overall, the average surgical time was of 47.5 minutes, with an average transoperative bleeding of 10 mL.

The patients with infectious etiology received antibiotics prescribed by the hospital's infectiology service. The patients with vertebral osteoporosis were submitted to kyphoplasty, and those in the neoplasm group were classified according to the Tokuhashi score to decide whether the surgery should be performed or not, and they were sent to the oncology service to undergo chemotherapy or radiotherapy.

Discussion

The use of higher-definition imaging studies, such as computed tomography and magnetic resonance as well as the use of nuclear medicine, has allowed the spine specialist to detect with much more sensitivity smaller lesions that occur in patients with specific symptoms, enabling the performance of less invasive surgical approaches, such as percutaneous biopsy, instead of open biopsy. Even though open biopsies are associated with a longer surgical time, greater risk of bleeding, higher number of complications, and sometimes it is not possible to obtain an adequate biopsy by a traditional posterior access to the vertebral body, they are still considered the "gold standard." With the improvement in the different types of vertebral instrumentation, the increasing use of transpedicular systems, and, lately, of the percutaneous transpedicular instrumentation make the technique of percutaneous vertebral biopsy an option that can be easily used by the spinal surgeon. Since there are more morphometric reports about the strength, structure, and anatomical situation with respect to the spinal level, it is known that a pedicle larger than 3 mm is able to safely house a needle for vertebral biopsy.⁸

B. Marré reported that, in 22 patients, he obtained 95% of diagnostic effectiveness, and microbiological identification in 50% of the cases. Rosales-Olivares et al.⁷ reported diagnosis in only 55% of the cases studied by histopathology, and they concluded that, given the poor percentage obtained in their series of only 20 patients, "percutaneous fluoroscopy-guided biopsy is not a useful method in our environment"; this discrepancy with other works may be due to the small sample of patients, and although the methodology followed is not specified, it remains an operator-dependent technique. In general, the methodology of the study is not enough to rule out this technique. On the other hand, in the present series of 100 cases, a definitive etiological diagnosis was obtained in 83 patients (83%), which positions this modality of percutaneous biopsy technique as an effective tool within the vertebral destruction syndrome study protocol, given its wide availability and reproducibility.

Currently, there are works describing other imaging techniques used, such as tomography, with a reported effectiveness of 90.4%⁹ to 94.4% for the histopathological analysis.¹⁰ However, in our environment, even today, the availability of the tomography equipment for surgical procedures continues to be complicated given the number of other diagnostic procedures performed in imaging services. Thus, alternative methods, such as fluoroscopy, which has greater accessibility, continue to be part of our diagnostic arsenal for the diagnosis of patients with vertebral destruction syndrome. However, such methods should be compared to other minimally-invasive techniques.

Although the present series has considerable sample of patients in a prospective design, a comparative analysis of at least two different biopsy techniques is necessary to sustain stronger evidence-based recommendations.

Conclusion

Percutaneous transpedicular fluoroscopy-guided biopsy is an effective method (83%) for the etiological diagnosis of vertebral destructive syndrome. It is a minimally-invasive procedure, with little intraoperative bleeding, minimal surgical time, short hospital stays, cheap, and feasible to the surgeon at any hospital with an image intensifier C arm.

Financial Support

There was no financial support from public, commercial, or non-profit sources.

Conflict of Interests

The authors have no conflict of interests to declared.

References

- 1 Alpízar-Aguirre A, Elías-Escobedo A, Rosales-Olivares LM, Miramontes-Martínez V, Reyes-Sánchez A. Síndrome de destrucción vertebral. Sistemas de evaluación en su diagnóstico *Cir Cir* 2008; 76(03):205-211
- 2 Metzger CS, Johnson DW, Donaldson WF III. Percutaneous biopsy in the anterior thoracic spine. *Spine (Phila Pa 1976)* 1993;18(03):374-378
- 3 Robertson RC, Ball RP. Destructive spinal lesions: diagnosis by needle biopsy. *J Bone Joint Surg* 1935;17:749-758
- 4 Ottolenghi CE. Aspiration biopsy of the spine. Technique for the thoracic spine and results of twenty-eight biopsies in this region and over-all results of 1050 biopsies of other spinal segments. *J Bone Joint Surg Am* 1969;51(08):1531-1544
- 5 Valls J, Ottolenghi CE, Schajowicz F. Aspiration biopsy in diagnosis of lesions of vertebral bodies. *J Am Med Assoc* 1948;136(06): 376-382
- 6 Craig FS. Vertebral-body biopsy. *J Bone Joint Surg Am* 1956;38-A (01):93-102
- 7 Rosales-Olivares LM, Valle-Cerna I, Alpízar-Aguirre A, Miramontes-Martínez V, Arenas-Sordo MdeL, Reyes-Sánchez A. Evaluación de la biopsia percutánea en el diagnóstico del síndrome de destrucción vertebral tóraco y lumbar. *Cir Cir* 2007;75(06): 459-463
- 8 Misenhimer GR, Peek RD, Wiltse LL, Rothman SL, Widell EH Jr. Anatomic analysis of pedicle cortical and cancellous diameter as related to screw size. *Spine (Phila Pa 1976)* 1989;14(04): 367-372
- 9 Rosales Olivarez LM, Nieto Sandoval HR, Alpízar Aguirre A, Zárate Kalfopulos B, Sánchez Bringas MG, Reyes Sánchez AA. Evaluación de la biopsia transpedicular guiada por TAC. *Coluna/Columna* 2012;11(03):209-213
- 10 Rehm J, Veith S, Akbar M, Kauczor HU, Weber MA. CT-Guided Percutaneous Spine Biopsy in Suspected Infection or Malignancy: A Study of 214 Patients. *Rofo* 2016;188(12): 1156-1162