

# Modified Circumcostal Suture Stabilization of Scapular Avulsion in a Maine Coon Cat

Victoria J. Roberts<sup>1</sup> Oliver Gilman<sup>2</sup> Matt Matiasovic<sup>3</sup>  Ricardo De Sousa<sup>4</sup>

<sup>1</sup>Pride Veterinary Centre, Riverside Road, Derby, United Kingdom

<sup>2</sup>Highcroft Veterinary Referrals, Whitchurch, Bristol, United Kingdom

<sup>3</sup>IVC Evidensia Netherlands Dierenziekenhuis Hart van Brabant, Waalwijk, the Netherlands

<sup>4</sup>Hamilton Specialist Referrals, Buckinghamshire, United Kingdom

Address for correspondence: Victoria Roberts, BSc, BVSc, PGDip (VCP), Pride Veterinary Centre, Riverside Road, Derby, DE24 8HX, United Kingdom (e-mail: vjroberts@rvc.ac.uk).

VCOT Open 2020;3:e140–e145.

## Abstract

This study describes the surgical management of a traumatic scapular avulsion including complications and clinical outcome in a 3-year-old Maine Coon cat. Traumatic scapular avulsion was diagnosed clinically and confirmed on a computed tomography scan, alongside severe scapula displacement. The scapula was stabilized surgically by the placement of two circumcostal sutures, through paired bone tunnels drilled both cranial and caudal to the base of the scapular spine, and two sutures passing through bone tunnels in the dorsal border of the scapula bone secured to the serratus ventralis muscle. The cat was able to bear weight on the affected limb within 48 hours of surgery; however, limb function subsequently deteriorated at home. Revision surgery was required 14 days postoperatively to replace failed polydioxanone suture with ultra-high molecular weight polyethylene suture (Fiberwire). Following revision surgery, the cat had a very acceptable functional outcome, with scapular stability and only intermittent lameness/stiffness noted in the medium-term follow-up. The present case report demonstrates that the described modified surgical technique may be used successfully in the treatment of scapular avulsion in cats and restores acceptable function to the affected limb.

## Keywords

- ▶ feline
- ▶ scapula
- ▶ luxation
- ▶ traumatic
- ▶ surgery

## Introduction

Traumatic scapular avulsion, also known as scapular luxation, is an uncommon injury in dogs and cats.<sup>1–5</sup> The scapular joint is a synsarcosis in which the thoracic limb supports the trunk during weight-bearing by muscular attachments alone and no direct bony articulation.<sup>1,6</sup> The primary muscles responsible for scapular stability are the serratus ventralis, rhomboideus and trapezius which insert onto the cranial angle and dorsal border of the scapula, as well as the teres major and latissimus dorsi.<sup>1,6</sup> If these muscles are disrupted, the scapula becomes unstable and will displace dorsally during attempted weight-bearing. A recent report has been published describing the clinical presentation, modified surgical technique and functional outcome in a series of three dogs.<sup>7</sup> However, there is no published literature

reporting the use of this modified surgical technique in cats and only limited published literature describing scapular avulsion in cats, with significant concomitant injuries being present.<sup>3,8</sup> Herein, we describe the clinical presentation and use of a modified surgical technique to stabilize a scapular avulsion in a cat.

## Case Report

### Clinical Findings

A 3-year-old, 7 kg, male-entire, Maine Coon cat was referred for the assessment of left thoracic limb lameness. The cat was presented with a 9-day history of a suspected traumatic, non-weight-bearing, left thoracic limb lameness, which was refractory to conservative management. A mandibular symphyseal fracture was sustained at the same time as the onset

received  
March 31, 2020  
accepted  
August 24, 2020

DOI <https://doi.org/10.1055/s-0040-1717105>.  
ISSN 2625-2325.

© 2020 Georg Thieme Verlag KG  
Stuttgart · New York

License terms



of lameness, and had been stabilized prior to referral. An empirical antibiotic medication course of amoxicillin/clavulanate (Synuclav; MiPet, CVS, Norfolk, United Kingdom) (14 mg/kg orally twice daily) had also been started prior to referral. On presentation, general physical examination was unremarkable. Orthopaedic examination revealed a non-weight-bearing gait on the left thoracic limb with caudodorsal and lateral displacement of the scapula on limb adduction and marked discomfort on flexion and extension of the limb. The remainder of the orthopaedic and neurological examination was unremarkable.

### Diagnostic Imaging

Computed tomography was performed (Somatom Scope; Siemens Healthcare GmbH, Erlangen, Germany) with the cat placed in sternal recumbency. The thoracic limbs were positioned cranially in extension without physical restraint.

Results showed the left scapula to be avulsed and rotated on the long axis such that the supraspinous fossa was facing dorsomedially towards the left thoracic wall and the subscapular fossa was facing ventrolaterally towards the skin surface (► Fig. 1). The shoulder joint remained intact. There was marked disruption of the extrinsic muscles of the omothoracic junction including the deep pectoral, trapezius, rhomboideus and serratus ventralis muscles. At the caudal subscapular fossa, the serratus ventralis cervicis insertion was thickened and there was discontinuation of this muscle in the mid-section.

### Examination

Examination under sedation revealed that the scapula was displaced caudally and dorsally. Palpation and manipulation

revealed instability in the craniocaudal, ventrodorsal and mediolateral planes.

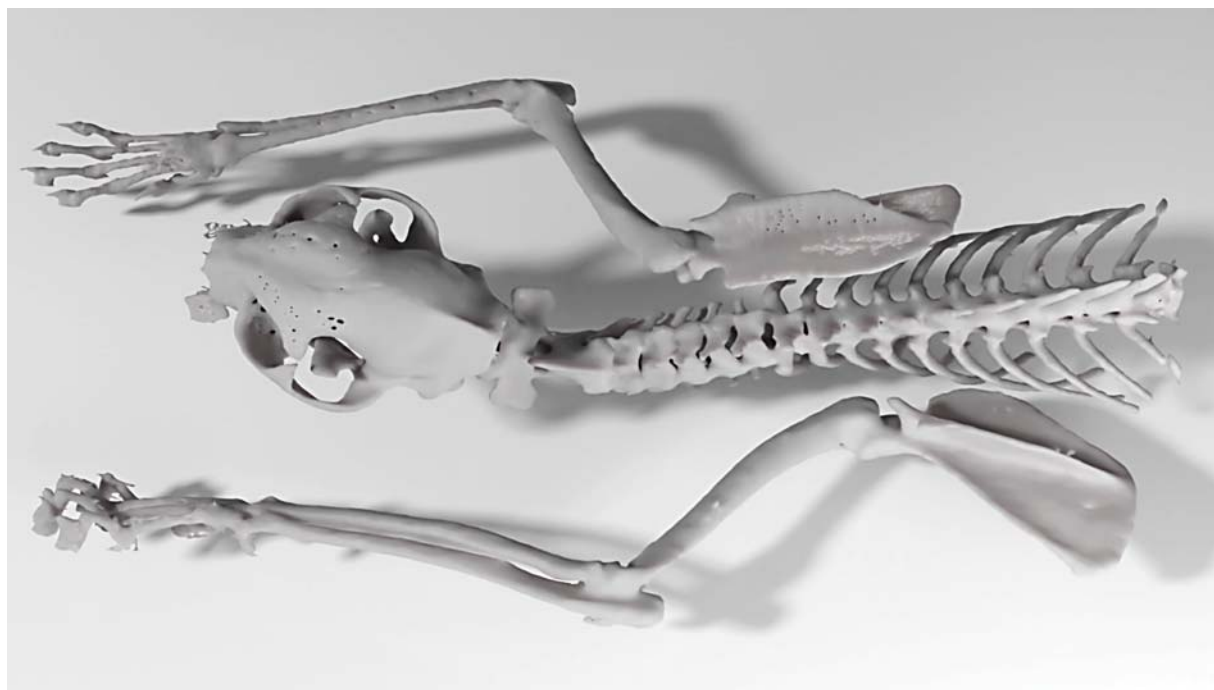### Preoperative Preparation

The cat was sedated with methadone hydrochloride (Comfortan; Dechra, Shrewsbury, United Kingdom) (0.3 mg/kg, intravenously [IV]) and dexmedetomidine (Dexdomitor; Vetoquinol, Towcester, United Kingdom) (0.003 mg/kg, IV). General anaesthesia was induced with propofol (Propofol Lipuro Vet; Braun, Germany) (2.9 mg/kg, IV) and maintained with isoflurane (Isocare; Animalcare, York, United Kingdom) in oxygen. Cefuroxime (Zinacef; GSK, London, United Kingdom) (20 mg/kg, IV) was administered ~30 minutes prior to surgery and repeated at 90-minute intervals. Meloxicam (Metacam; Boehringer Ingelheim, Bracknell, United Kingdom) (0.2 mg/kg, subcutaneously) was administered ~30 minutes prior to surgery.

### Surgical Procedure

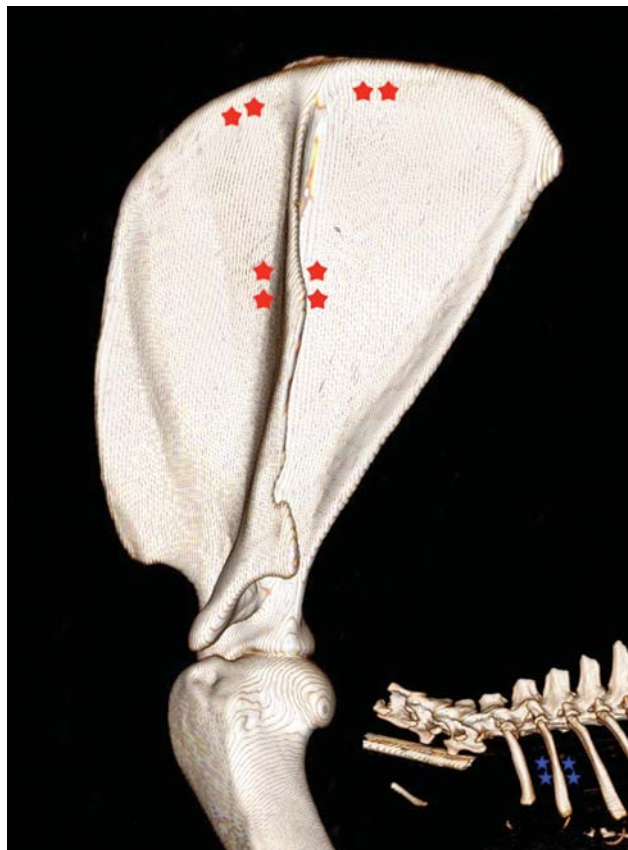
In theatre, the cat was positioned in right lateral recumbency. A lateral surgical approach to the left scapula was made via a dorsal-to-ventral incision, centred directly over the spine of the scapula. The skin and subcutaneous fascia were incised and retracted in a combination of sharp and blunt dissection. A partial myotomy was made of the trapezius muscle to improve visualization of the dorsal scapular border. Inspection revealed a partial avulsion of the rhomboideus muscle and complete avulsion of the serratus ventralis muscle.

At the level of the mid-body of the scapular spine, two parallel 2 cm incisions were made through the deep fascia, one cranial and the other caudal to the scapular spine, to enable elevation of the supraspinatus and infraspinatus



**Fig. 1** Three-dimensional computed tomography reconstruction showing complete left scapular avulsion with rotation on the long axis such that the supraspinous fossa is facing dorsomedially towards the left thoracic wall and the subscapular fossa is facing ventrolaterally towards the skin surface. The shoulder joint remains intact; hence, there is an abnormal angulation of the lower limb.

muscles from the scapular body. A 1.8 mm drill bit was then used to create a pair of bone tunnels both cranial and caudal to the base of the scapular spine, 1 cm apart proximodistally and angled  $\sim 45$  degrees towards the base of the spine of the scapula to maximize the length of the bone tunnel ( $\rightarrow$ Fig. 2). Two circumcostal polydioxanone sutures (PDS II 1 USP; Ethicon, Johnson & Johnson Medical Ltd, Wokingham, United Kingdom) were placed around the second rib (mid-shaft) with the swaged needle passed in a reverse direction ( $\rightarrow$ Fig. 3). The suture ends were then passed mediolaterally through the paired bone tunnels cranial and caudal to the scapular spine, using a hypodermic needle as a cannulated guide. Two further pairs of bone tunnels were created through small linear incisions in the supraspinatus and infraspinatus muscle fibres parallel to the dorsal border of the scapula ( $\rightarrow$ Fig. 2). Two polydioxanone sutures were then pre-placed lateromedially through these bone tunnels, passed through the serratus ventralis muscle and then passed mediolaterally through the respective adjacent bone tunnel, using a horizontal mattress suture pattern ( $\rightarrow$ Fig. 3). The scapula was held in adduction against the thoracic wall, and all the pre-placed sutures were sequentially secured using multiple squared knots. Closure was routine with the rhomboideus and trapezius muscles being reconstructed using polydioxanone suture, and the subcuta-



**Fig. 2** Three-dimensional computed tomography reconstruction showing the left scapula with red stars used to demonstrate the location of the paired bone tunnels drilled through the body of the scapula. Image inset in the bottom right shows the ribs with blue stars used to demonstrate the location of the circumcostal sutures.

neous tissues and intradermal layer with poliglecaprone 25 suture (Monocryl 3-0 USP; Ethicon, Johnson & Johnson Medical Ltd, Wokingham, United Kingdom). A sterile conformable adhesive dressing (Primapore; Smith + Nephew, Warwick, United Kingdom) was placed over the wound at the end of the procedure.

### Postoperative Care

Postoperative analgesia consisted of methadone hydrochloride (Comfortan; Dechra, Shrewsbury, United Kingdom) (0.2mg/kg IV every 4 hours) administered for the first 12 hours, after which buprenorphine (Buprecare; Animalcare, York, United Kingdom) (0.02 mg/kg IV every 6–8 hours) was administered. Meloxicam (Meloxid; MiPet, Norfolk, United Kingdom) (0.05 mg/kg orally every 24 hours) was administered for 3 weeks. The cat was discharged for continued care at home after 48 hours. The owners were instructed to confine the cat to a crate and restrict the activity to short periods of time out of the crate under direct supervision only for a period of 6 weeks postoperatively. No external coaptation was used.

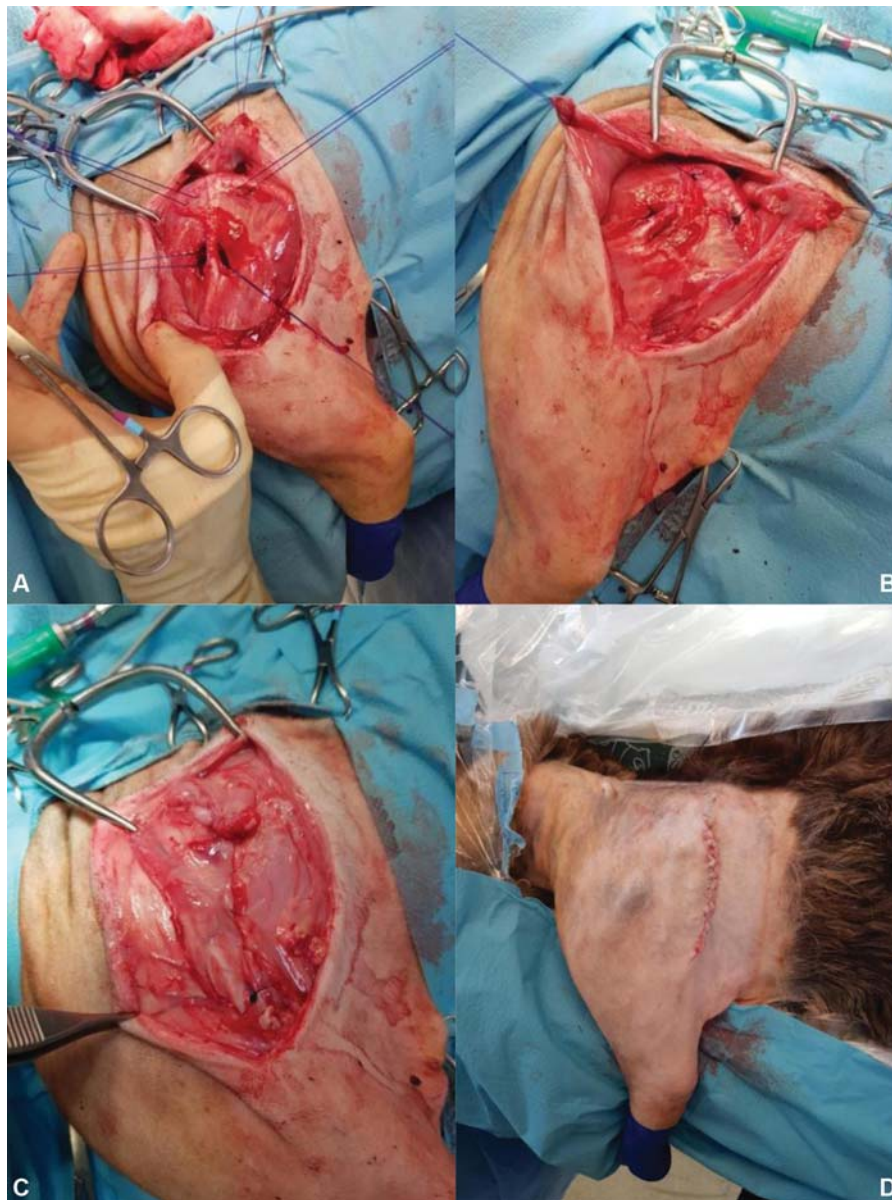### Initial Follow-up

The cat was returned for re-examination 2 weeks postoperatively due to a reluctance to bear weight on the left thoracic limb. Examination revealed a non-weight-bearing gait of the left thoracic limb with caudodorsal displacement of the scapula on manipulation. Marked discomfort was elicited on flexion and extension of the limb. The loss of scapula stability raised concerns for implant failure. Following discussion with the owners, the decision was made to surgically explore the previous repair. The cat was taken into theatre and surgical exploration revealed that the previous surgery had failed due to breakage of the suture material placed through the bone tunnels cranial and caudal to the base of the scapular spine and through the dorsal border of the scapula. The failed suture material was removed. Multi-stranded long chain ultra-high molecular weight polyethylene (UHMWPE) suture (Fiberwire; Arthrex GmbH, Germany) was placed through the paired bone tunnels both cranial and caudal to the base of the scapular spine. Polydioxanone suture was placed through the paired bone tunnels at the dorsal border of the scapula. Closure was performed as previously described. Postoperative care was as previously described and the cat was discharged 48 hours after the procedure.

### Final Follow-up

Final clinical follow-up was obtained at 37 weeks postoperatively. The cat was reported to show a mild intermittent lameness at home with occasional stiffness after rest. The cat had returned to normal activity including jumping, running and stretching to use a scratching post with no indication of pain. A 'Feline Musculoskeletal Pain Index' questionnaire<sup>9</sup> was completed by the owner. This gave a score of 9/68 (0 = no signs of pain/impairment and 68 = signs of severe pain/impairment).

On clinical examination in the practice, no lameness was evident. A mild reduction in the range of motion of the left



**Fig. 3** Intraoperative view; a partial myotomy has been performed of the trapezius muscle and the cut muscle ends are tagged with stay sutures. (A) Pre-placement of all sutures prior to tying. There are four sutures in total; one cranial and the other caudal to the scapular spine which pass through paired bone tunnels in the body of the scapula and subsequently pass circumcostally around the second rib; two sutures in the dorsal cranial and caudal border of the scapula, passing through paired bone tunnels and through the serratus ventralis muscle. The scapula is held adducted to the thoracic wall in preparation for sequential suture tying from ventral to dorsal. (B) Position of the scapula, held in adduction by the tied sutures. (C) Muscular reconstruction. (D) Skin closure.

scapula against the thoracic wall was evident during walking and on manipulation compared with the right side; however, palpation and manipulation elicited no pain response. The left scapula was stable and could not be displaced on manipulation.

## Discussion

Scapular avulsion is a rare cause of thoracic limb lameness in companion animals and is reported to be more common in cats than dogs, with no age or sex predilection.<sup>10</sup> Scapular avulsion is caused by traumatic disruption of the primary muscular stabilisers including the serratus ventralis, rhomboideus, and

trapezius muscles.<sup>2,3,11</sup> Concomitant scapular fractures, among other injuries, have also been reported.<sup>3,4,10</sup>

In the present case report the serratus ventralis was the only muscle found to be fully avulsed, with the rhomboideus muscle being only partially avulsed. This is similar to the study by Jones and Colleagues,<sup>4</sup> where the serratus ventralis was the only muscle affected in all three dogs reported. These findings suggest that the serratus ventralis muscle might be the primary contributor to scapular stability, with avulsion of this muscle alone responsible for scapular instability.<sup>4</sup> However, damage to the rhomboideus and/or trapezius muscles is a common sequelae<sup>4</sup> and may contribute to the degree of scapular displacement seen.

Conservative management of scapular avulsion through exercise restriction and placement of a Velpeau sling has been described in cats, and weight-bearing has been demonstrated in a cat with ongoing scapular displacement without any treatment.<sup>1,5,8,10</sup> Nevertheless, surgical intervention has been advocated for a more reliable, functional and cosmetic outcome<sup>1,10</sup> and for cases in which conservative treatment has failed to improve the clinical signs. In the two most recent case reports of surgically managed scapular avulsion in cats, muscular reconstruction alone was performed with good clinical outcomes being reported.<sup>3,11</sup> While the authors of these studies acknowledge that this repair may be sufficient for partial scapular instability, it is recognized that this does not provide sufficient stability for all cases of scapular avulsion.<sup>12</sup> Due to the severity of the scapular instability and displacement seen in the present case, it was felt that circumcostal sutures would be required to provide a stronger repair and quicker recovery time.

We utilized a modified surgical technique which has been recently described in a case series of three dogs.<sup>4</sup> To our knowledge, this is the first publication of this modified technique being performed in a cat. Previously described techniques of circumcostal suture placement<sup>1,2,5,10,12</sup> fix the scapula in a caudal position, potentially resulting in a longer lever arm on the fixation point, thus causing more scapular motion in healing and greater strain on the sutures.<sup>4</sup> In the modified technique utilized here the second rib was used as the circumcostal anchor point and the suture ends were passed through paired bone tunnels both cranial and caudal to the base of the scapular spine at a 45-degree angle. As a result, the bone tunnels are made through denser bone providing more bone stock and are located closer to the centre of rotation of the scapula thus increasing the support and protection of the repaired serratus ventralis muscle.<sup>4</sup>

Another modification of the surgical technique utilized here was the suture material used. Previously described techniques report using 18 to 22 gauge orthopaedic wire to stabilize the scapular body to the thoracic wall.<sup>1,2,5,10,12</sup> Orthopaedic stainless steel wire has been associated with several complications including cutting into the bone, foreign-body induced wound infection, aseptic loosening and implant failure over time with cyclical loading of the wire.<sup>13–15</sup> As such, orthopaedic wire may require removal if any of these complications occur. Based on recent studies, polydioxanone is a reported alternative to orthopaedic stainless-steel wire for other procedures<sup>15,16</sup> and was considered likely to provide adequate tensile strength for the weight of the cat. Therefore, we elected to use polydioxanone suture in the first instance; however, this proved to be insufficient to withstand the forces generated through the thoracic limb postoperatively in this cat. This may have resulted from inappropriate suture selection and/or failure to adequately restrict activity levels postoperatively. At the revision surgery, the sutures at the base of the scapular spine and at the dorsal border of the scapula were found to have broken and remnants of the suture material were embedded within fibrous tissue at the level of the second rib and serratus ventralis. This suggests that failure occurred due to excessive load passing through the scapular body and not at the level of

anchorage around the second rib or fascial plane of the serratus ventralis. Revision surgery was successfully performed. UHMWPE sutures were placed through the bone tunnels at the base of the scapular spine and passed circumcostally. New polydioxanone suture was placed through the bone tunnels in the dorsal scapular border and passed through the serratus ventralis muscle. Different suture materials were deliberately used for the different suture locations due to their different functional requirements. The sutures at the base of the scapular spine act as the pivot point for scapular rotation and as such were considered to be the main weight-bearing supporters. Therefore, UHMWPE was selected for these sutures. The dorsal border sutures were primarily placed to provide mediolateral stability rather than load sharing through the thoracic wall and scapula. Therefore, in spite of the previous suture failure, polydioxanone was felt sufficient for the dorsal border sutures. Monofilament nylon leader line has also been described as an alternative to UHMWPE for the sutures at the base of the scapular spine.<sup>4</sup> When the mechanical properties of these two materials have been compared, UHMWPE (Fiberwire) has been shown to have superior tensile strength without elongation, ultimate tensile strength, stiffness at failure and greater resistance to cyclic elongation.<sup>17</sup> However, as a polyblend, non-absorbable suture material, UHMWPE is more prone to infection. Based on the small number of cases published, either of these suture materials could be considered for surgical stabilization of scapular avulsions and the decision should be made according to specific patient factors. Further studies would be helpful to identify risk factors for complications and subsequently formulate suture material recommendations for this surgical procedure.

A modified Velpeau sling could have been used for additional protection during the immediate postoperative period.<sup>5</sup> However, due to the potential risks associated with bandages in cats<sup>18</sup> and the reports of successful surgical outcomes in cases treated in the absence of such external coaptation,<sup>3</sup> the authors decided not use one. The subsequent successful outcome after revision surgery suggests that external coaptation may not be required for cases treated with this modified surgical technique.<sup>3</sup>

Median-term follow-up demonstrated good scapular stability with no indication of pain on clinical examination. Furthermore, an owner questionnaire completed at this time demonstrated a low Feline Musculoskeletal Pain Index score, a previously published and validated clinical metrology instrument,<sup>9,19,20</sup> suggesting acceptable functional limb use at home. Further biomechanical or cadaveric studies comparing the rate of failure of different suture materials or the influence of the location of suture placement may be of benefit. The present case report demonstrates that the described modified surgical technique may be used successfully in the treatment of scapular avulsion in cats and restores acceptable function to the affected limb.

## Conclusion

The present case report details the presentation, management, follow-up and subsequent revision surgery for a

case of scapular avulsion in a cat. A modified circumcostal suture stabilization technique was utilized and, after revision surgery, the cat achieved a very acceptable limb function.

#### Conflict of Interest

None declared.

#### Acknowledgments

The authors would like to thank Darren Roper, Dan Ogden and Lizzie Reeve for their assistance in reporting the computed tomography and preparing the images included in this report.

#### References

- DeCamp C, Johnston SA, Dejardin LM, Schaefer SL. The shoulder joint. In: Brinker, Piermattei, and Flo's Handbook of Small Animal Orthopedics and Fracture Repair. 5th edition. St. Louis, Missouri, USA: Elsevier; 2006:260–297
- Hoerlein BF, Evans LE, Davis JM. Upward luxation of the canine scapula—a case report. *J Am Vet Med Assoc* 1960;136:258–259
- Perry KL, Lam R, Rutherford L, Arthurs GI. A case of scapular avulsion with concomitant scapular fracture in a cat. *J Feline Med Surg* 2012;14(12):946–951
- Jones SC, Tinga S, Porter EG, Lewis D. Surgical management of dorsal scapular luxation in three dogs. *Vet Comp Orthop Traumatol* 2017;30(01):75–80
- Voss K, Langley-Hobbs SJ, Montavon PM. Scapula. In: Montavon PM, Voss K, Langley-Hobbs SJ, eds. *Feline Orthopaedic Surgery and Musculoskeletal Disease*. Edinburgh: Saunders Elsevier; 2009:329–336
- Butterworth S, Cook J. The shoulder. In: Houlton J, Cook J, Innes J, eds. *BSAVA Manual of Canine and Feline Musculoskeletal Disorders*. Gloucester, UK: British Small Animal Veterinary Association; 2006:212–248
- Jones C, Brooker B, Genon M. Comparison of open and closed staff-assisted glove donning on the nature of surgical glove cuff contamination. *ANZ J Surg* 2010;80(03):174–177
- Kano WT, Rahal SC, Mesquita LdosR, Agostinho FS, de Faria LG. Gait analysis in a cat with scapular luxation and contralateral forelimb amputation. *Can Vet J* 2013;54(10):990–991
- Lancelles DX. Feline Musculoskeletal Pain Index. Secondary Feline Musculoskeletal Pain Index 2015. Available at: <https://painfree-cats.org/pain-scale/>. Accessed September 24, 2020
- Schultz S. Diseases of the joints. In: Fossum T, ed. *Small Animal Surgery*. 4th edition St Louis, Missouri, USA: Elsevier Mosby; 2013:1246–37
- Ozsoy S, Güzel O. Dorsal luxation of the scapula in a cat. *Turk J Vet Anim Sci* 2013;37:618–620
- Peck J, Scapula, Tobias K, Johnson S, eds. *Veterinary Surgery: Small Animal*. 2nd edition St Louis, Missouri, USA: Saunders Elsevier; 2018:690–691
- Lewis DD, Milthorpe BK, Bellenger CR. Mechanical comparison of materials used for extra-capsular stabilisation of the stifle joint in dogs. *Aust Vet J* 1997;75(12):890–896
- Störk CK, Gibson NR, Owen MR, et al. Radiographic features of a lateral extracapsular wire suture in the canine cranial cruciate deficient stifle. *J Small Anim Pract* 2001;42(10):487–490
- Gines JA, Friend EJ, Vives MA, Browne WJ, Tarlton JF, Chanoit G. Mechanical comparison of median sternotomy closure in dogs using polydioxanone and wire sutures. *J Small Anim Pract* 2011; 52(11):582–586
- Shimizu N, Tarlton J, Friend E, Doran I, Parsons K. Tensile comparison of polydioxanone, polyglyconate, and barbed glycolide-trimethylene carbonate suture in canine cadaveric tensor fascia lata. *Vet Surg* 2017;46(01):89–94
- Rose ND, Goerke D, Evans RB, Conzemius MG. Mechanical testing of orthopedic suture material used for extra-articular stabilization of canine cruciate ligament-deficient stifles. *Vet Surg* 2012; 41(02):266–272
- Anderson DM, White RA. Ischemic bandage injuries: a case series and review of the literature. *Vet Surg* 2000;29(06):488–498
- Stadig S, Lascelles BDX, Nyman G, Bergh A. Evaluation and comparison of pain questionnaires for clinical screening of osteoarthritis in cats. *Vet Rec* 2019;185(24):757
- Benito J, Depuy V, Hardie E, et al. Reliability and discriminatory testing of a client-based metrology instrument, feline musculoskeletal pain index (FMPI) for the evaluation of degenerative joint disease-associated pain in cats. *Vet J* 2013;196(03):368–373