



Treatment of Chondral Knee Lesions with Autologous Chondrocytes Embedded in a Fibrin Scaffold. Clinical and Functional Assessment*

Tratamento de lesões condrais no joelho com condrócitos autólogos embebidos em arcabouço de fibrina. Avaliação clínica e funcional

Eduardo Alvarez-Lozano¹ Herminia Martinez-Rodriguez² Francisco Forriol³

¹Department of Orthopedic Surgery, Hospital Jose E Gonzalez, Universidad Autónoma de Nuevo Leon, Monterrey, Mexico

²Department of Biochemistry, Universidad Autónoma de Nuevo Leon, Monterrey, Mexico

³Facultad de Medicina, Universidade San Pablo CEU, IMMA, Boadilla del Monte, Madrid, Spain

Address for correspondence Francisco Forriol, MD, PhD, Universidade San Pablo CEU, Campus Montepríncipe, Boadilla del Monte, Madrid, 28668, Spain (e-mail: fforriol@gmail.com).

Rev Bras Ortop 2021;56(4):470–477.

Abstract

Objective The aim of our study is to analyze the clinical and functional results obtained using autologous chondrocytes embedded in a fibrin scaffold in knee joint injuries.

Methods We included 56 patients, 36 men and 20 women, with a mean age 36 years. Six of the patients were professional athletes, with single knee injuries that were either chondral or osteochondral (43 chondral, 9 osteochondral, 2 cases of osteochondritis dissecans and 2 osteochondral fractures), 2 to 10 cm² in size and ≤ 10 mm deep, with no signs of osteoarthritis. The location of the injury was in the patella (8), the medial femoral condyle (40) and lateral femoral condyle (7) and one in the trochlea. The mean follow-up was 3 (range: 1–6) years. The clinical course was assessed using the Cincinnati and Knee Injury and Osteoarthritis Outcome (KOOS) scores, 6 and 12 months after surgery. The paired Student t-test was used to compare pre-and postoperative results.

Results Six months after the implant, patients resumed their everyday activities. On the assessment scores, their condition was improving in comparison with their presurgical state ($p < 0.05$). They were also able to carry out their sporting activities more easily than prior to surgery ($p < 0.05$).

Conclusion The seeding of chondrocytes in fibrin may provide a favorable micro-environment for the synthesis of extracellular matrix and improved the clinical condition and activity of the patients 1 year after surgery.

Keywords

- ▶ cartilage
- ▶ knee
- ▶ scaphoid bone
- ▶ chondrocytes
- ▶ fibrin

* Work developed at the CEU-San Pablo University School of Medicine, IMMA, Boadilla del Monte, Madrid, Spain.

received
January 5, 2020
accepted
July 6, 2020
published online
October 29, 2020

DOI <https://doi.org/10.1055/s-0040-1716764>.
ISSN 0102-3616.

© 2020. Sociedade Brasileira de Ortopedia e Traumatologia. All rights reserved.

This is an open access article published by Thieme under the terms of the Creative Commons Attribution-NonDerivative-NonCommercial-License, permitting copying and reproduction so long as the original work is given appropriate credit. Contents may not be used for commercial purposes, or adapted, remixed, transformed or built upon. (<https://creativecommons.org/licenses/by-nc-nd/4.0/>)

Thieme Revinter Publicações Ltda., Rua do Matoso 170, Rio de Janeiro, RJ, CEP 20270-135, Brazil

Resumo

Objetivo O objetivo do nosso estudo é analisar os resultados clínicos e funcionais do tratamento de lesões nas articulações do joelho com condrócitos autólogos embebidos em arcabouço de fibrina.

Métodos O estudo foi realizado com 56 pacientes (36 homens e 20 mulheres) com idade média de 36 anos; 6 indivíduos eram atletas profissionais. Os pacientes apresentavam lesões únicas, condrais ou osteocondrais (43 condrais, nove osteocondrais, 2 casos de osteocondrite dissecante e duas fraturas osteocondrais) no joelho, com 2 a 10 cm² de tamanho e ≤ 10 mm de profundidade, sem sinais de osteoartrite. As lesões estavam localizadas na patela (8), no côndilo femoral medial (40), no côndilo femoral lateral (7) e na tróclea (1). O período médio de acompanhamento foi de 3 anos (faixa de 1–6 anos). A evolução clínica foi avaliada pelos escores de Cincinnati e *Knee Injury and Osteoarthritis Outcome* (KOOS), 6 e 12 meses após a cirurgia. O teste t de Student pareado foi utilizado para comparação dos achados pré e pós-operatórios.

Resultados Os pacientes retomaram suas atividades diárias 6 meses após o implante. Os escores avaliados demonstraram a melhora em comparação ao estado pré-cirúrgico ($p < 0,05$). Além disso, os pacientes conseguiram realizar suas atividades esportivas com mais facilidade do que antes da cirurgia ($p < 0,05$).

Conclusão A cultura de condrócitos em fibrina pode proporcionar um microambiente favorável para a síntese de matriz extracelular e melhorar a condição clínica e a atividade dos pacientes 1 ano após a cirurgia

Palavras-chave

- ▶ cartilagem
- ▶ joelho
- ▶ osso escafoide
- ▶ condrócitos
- ▶ fibrina

Introduction

Chondral and osteochondral joint injuries lead to degeneration of the joint, which may ultimately require a prosthesis.¹ Cartilage is a tissue of low cellular density, which needs some support to achieve repair or regeneration.^{2,3} To this end, surgical approaches based on regenerative techniques make use of bioengineering to develop new hyaline cartilage tissue (autologous chondrocyte implant [ACI], mesenchymal stem cells [MSCs] chondrocytes in different scaffolds [MACI])² and can be performed through open surgery, mini-arthrotomies, or arthroscopy.

Autologous chondrocyte implantation (ACI) has developed from the implantation of cultured cells in the lesion itself, as a cellular suspension,⁴ to the inclusion of cultured cells in biodegradable scaffolds,^{5,6} which permit synthesis of extracellular matrix and cell differentiation. Although the number of cells is homogeneous across publications, the type of matrix used varies greatly.

A further aspect to consider in this type of treatment is that during cell growth, under certain conditions, the cells may change their morphology and phenotype, expressing transcription factors, such as the gene Sox9, and producing col2 or synthesis of col1, col3, or col10, which synthesize an extracellular matrix with poor biomechanical conditions,⁷ and are differentiated into a tissue that is also of low quality to perform the function of the hyaline cartilage.⁸ But if the chondrocytes are seeded in a chondrotropic environment, they can redifferentiate to develop hyaline cartilaginous tissue.⁹

Regenerative techniques are associated with high economic costs and high morbidity and have not always been

found to obtain better results in the long term.^{10,11} The aim of our study is to analyze the clinical results obtained in patients with chondral injuries treated with cultured autologous chondrocytes seeded in a fibrin scaffold.

Material and Methodology

A prospective study of 56 patients, 36 men and 20 women, operated on between April 2014 and October 2017, on the grounds of pain, joint lock, and functional limitations in the knee. Their mean age was 36 years (SD: 13; range: 16–64), and they had a mean follow-up of 27 (standard deviation [SD]: 16; range: 12–72) months. There were 32 injuries to the left knee and 24 to the right. The lesions were located as follows: 43 chondral, 9 osteochondral, 2 cases of osteochondritis dissecans and 2 osteochondral traumatism. The location of the lesions were 8 cases in the patella, the distal femur, 40 cases in the medial femoral condyle and 7 cases in the lateral femoral condyle and, finally, 1 case in the trochlea. Forty-three of the patients took part actively in sporting activities, and 6 were professional athletes.

The inclusion criteria were: patients aged between 16 and 65 years with no signs of osteoarthritis or rheumatic disease, being operated on for the 1st time with single lesions, either chondral or osteochondral, between 2 and 10 cm² in size, in which the bone lesion was ≤ 10 mm deep. The exclusion criteria are patients with osteoarthritis grade II or above in the Kellgren–Lawrence scale, with morbid obesity (BMI > 40) and patients with valgus or varum deformity > 10°.

The operation was performed from 1 to 6 years after symptoms appeared, although in most cases this period was

2 to 4 years. On 5 occasions, the cartilage injury was associated with a meniscus or anterior cruciate ligament torn; this was repaired in the same operation. The mechanical axis was studied in the lower limbs looking for valgus or varum deformation. No corrective osteotomy was performed.

We evaluated the patients using the Cincinnati and Knee Injury and Osteoarthritis Outcome (KOOS) knee scores, during the preoperative period and 6 and 12 months after the operation. We measured the range of mobility and the presence of crepitation and took anterior-posterior and sagittal standing X-rays, and MRI of the knee at each assessment. We evaluated the range of mobility in the pre and postoperative periods separately of the two scales.

Cartilage Obtaining Procedure

The specimen of cartilage was obtained from the intercondylar fossa by an arthroscopic procedure using an osteochondral autologous transplantation system (OATS), (Artrix, Karisfeld, Germany), 8 mm in diameter. The extracted cartilage was stored in physiological saline solution supplemented with 0.05 mg gentamicin. In our tissue engineering laboratory, we expanded and maintained the chondrocytes *in vitro*, according with the recommendations from the bone and bank tissue.

Chondrocyte Culture

This was performed using a modified version of the technique devised by Visna et al.⁶ We sectioned the joint cartilage obtained into small cubes sized 1 to 3 mm³ in a class II laminar flow bell. The cartilage fragments were treated with trypsin (GIBCO-BRL Life Technologies, Grand Island, NY, USA). For digestion of the chondral matrix, they were treated with type II collagenase (GIBCO-BRL Life Technologies). The chondrocytes obtained were inoculated into 75 cm² culture flasks

(NUNC Creek Drive, Rochester, NY, USA) for *in vitro* growth. The medium used was Opti-MEM (GIBCO-BRL Life Technologies), supplemented with 10% autologous human serum (AHS) and gentamicin. The cultures were kept in a controlled atmosphere with 5% CO₂ and a relative humidity of 100%. When the monolayer cultures reached between 70 and 80% confluence, the cells were detached and incubated in trypsin-EDTA (GIBCO-BRL Life Technologies).

To seed the chondrocytes in a three-dimensional scaffold, we used a fibrin-based glue. We followed the manufacturer's instructions, and before the fibrinogen and thrombin provided in the container were mixed, we added the chondrocytes so that they would be suspended in the fibrin. When 80% confluence was estimated, the cells were lifted with 0.25% trypsin-EDTA, counted in a Neubauer chamber using the trypan blue method, and subcultured in three fractions to encourage cell propagation and allow new cultures to be established, until 15 million cells were obtained. Microbiological tests were performed to ensure that the cultures contained no contamination. This number of chondrocytes was obtained in 26 days and in 15 × 75 cm² culture flasks. Subsequently, the cells were seeded in the three-dimensional fibrin scaffold, which was placed in a mold and set in for 5 minutes.

Surgical Technique (→ Fig. 1)

Surgery was performed the day after the cells were seeded. An arthrotomy was performed and the injured area was exposed. Then, the loose osteochondral fragments were removed and the scar tissue in the bed of the lesion was curetted. One mm was removed from the edges of the joint cartilage surrounding the lesion, and small perforations were made in the subchondral bone plaque, without removing it, so that the biological glue would facilitate the anchoring of the bone implant.

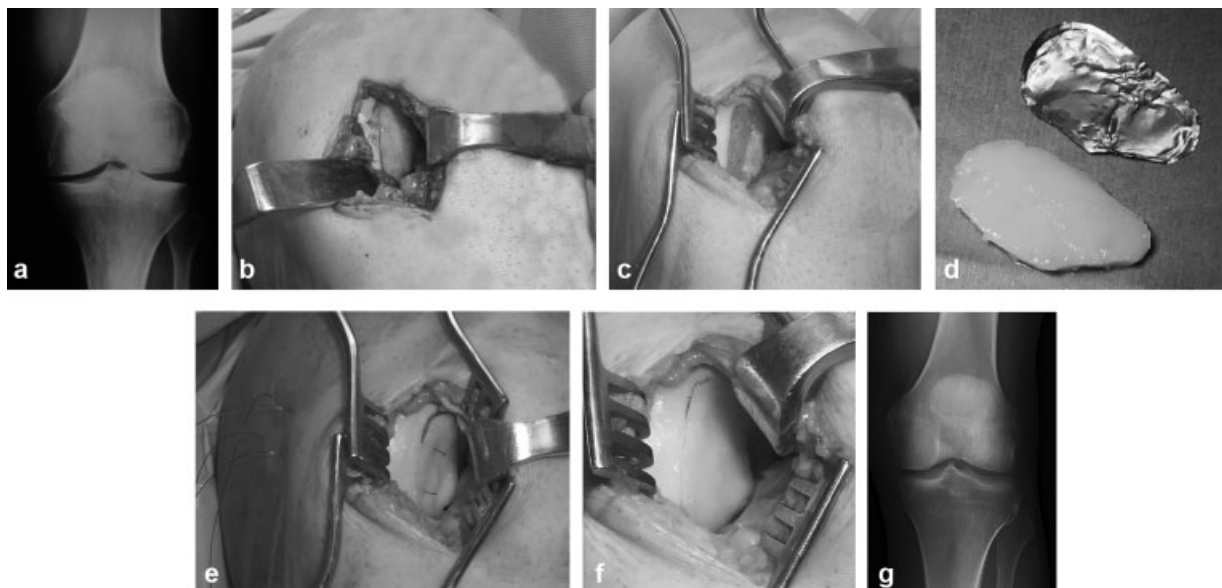


Fig. 1 (a) Preoperative X-ray, (b) An arthrotomy was performed and the injured area was exposed. (c) Loose osteochondral fragments were removed and the scar tissue in the bed of the lesion was curetted and small perforations were made in the subchondral bone plaque, without removing it, so that the biological glue would facilitate the anchoring of the bone implant. (d) An aluminum template to build a mold of the same morphology as the injury was used, (e) sutures were switched for re-absorbable sutures. (f) Once the implant had been placed, the transosseous sutures were removed, and a layer of fibrin glue was injected on the joint surface of the graft, (g) 12 months control X-ray.

We used an aluminum template to build a mold of the same morphology as the injury, and we designed the size and shape of the implant, ensuring that the edges were in contact with those of the recipient bone defect. We inserted 2.4 mm titanium surgical anchors (MiniFasTak®, Arthrex, Naples, Flo, U.S.A) at the edges of the lesion, switching the sutures for PDS II [polydioxanone] sutures with re-absorbable threads (Ethicon Inc., Sommerville, NJ, USA). When we inserted the anchors at the edges of the defect, we threaded the suture through the implant itself (Condrograft®, Banco de Huesos, UANL, Monterrey Mexico), which was in contact with the subchondral bone, and then again through its superior aspect, making sure that it was close to the other side of the hole. We made a transosseous tunnel toward the free side of the condyle. Through this tunnel we inserted the thread used to suture the implant. Once the anchors had been positioned and the thread had been inserted through the transosseous tunnel, we identified the suture threads to knot them, which we did without exerting pressure, until the next stage of fixation was completed.

To achieve full integration of the fibrin graft, we used Tissucol biological fibrin glue (Baxter Biosciences, Vienna, Austria), which formed a stable clot without affecting the seeded cells and encouraged their integration into the healthy cartilaginous tissue and the migration of the cells in the graft.

When we applied the Tissucol, a layer formed on the defect, and, immediately after this, we inserted the graft, keeping it in position using the trans-osseous sutures, lowering it and positioning it manually while pulling on the transosseous sutures so that the edges of the graft were in contact with the sides of the defect. Once the Condrograft had been placed in its definitive position inside the lesion, we proceeded to remove the transosseous sutures, without excessive force, in the direction of the free aspect of the femoral condyle. Finally, we put a layer of glue on the joint surface of the graft and in the place where it joined the normal cartilage.

After closing the wound by planes, we locked the knee joint in extension for 8 hours, to allow the Tissucol to set completely.

Postoperative Care

Passive mobility was allowed 8 hours after the surgery, and active mobility at 48 hours. After 10 days, partial walking was permitted, using crutches, and with progressive load-bearing. After 6 weeks, we allowed plantigrade locomotion bearing 75% of the body weight. The physiotherapy protocol

concluded 18 weeks after the operation, when the crutches were removed, and the patient could bear full weight.

Magnetic Resonance Imaging Data Acquisition

Magnetic resonance images were acquired using a 1.5-Tesla GE (General Electric Healthcare, Milwaukee, WI, USA). Three clinically appropriate scans (3D FS FGRE, dual echo spin echo [FSE] and two-dimensional fast spin echo [2D FSE]) were acquired for each study participant. All images were reviewed by an experienced radiologist to confirm the absence of pathology.

Two imaging sequences were used. Two-dimensional dual-echo images were acquired to calculate, pixel-wise, T2 relaxation maps, proton density (PD). The 3D FS FSPGR images were segmented using a semi-automated atlas-based method (QMetrics, Inc., Rochester, NY, USA). Images were segmented, as previously described, into bone, cartilage, and cartilage sub-regions using eight atlases. This approach produced eight separate segmentations that were compared on a voxel-by-voxel basis to create one segmentation map. Cartilage segmentations were obtained for the medial weight-bearing and lateral weight-bearing regions of the femur, and medial and lateral tibial cartilage. Cartilage segmentation maps were used to determine the volume (mm³) and mean thickness (mm) of each region of interest. This method yielded test-retest precision of cartilage thickness values of 0.014mm (0.6%) at the femur in images obtained with a 1.5T MRI¹² (► Fig. 2).

Statistical Analysis

A descriptive statistical analysis was performed, and we used the paired Student t-test to compare the pre and postoperative scores.

Results

Prior to surgery, most patients reported pain and inflammation that stopped them from being able to carry out their normal activities.

During the postoperative period, the patients performed normal daily life and work activities as well as light exercise, and one third of them felt that their knee was normal and that they could perform demanding exercises and tasks. An improvement was observed in the perception of symptoms after the surgery, although the difference was not significant. The patients' overall scores on the Cincinnati and KOOS

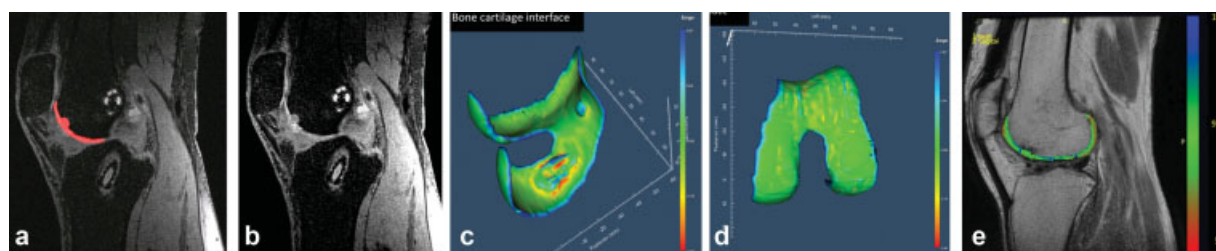


Fig. 2 (a,b) Preoperative sagittal view of femoral condyle cartilage 3D FS FGRE, (c,d) 3D rendering of surface curvature. The bone cartilage interface shows the extension of the chondral lesion. The articular surface shows smooth cartilage. (e) Sagittal view of T2 mapping cartilage estimated from 2D FSE (dual echo spin echo). Normal cartilage T2 range from 20 to 100 milliseconds.

Table 1 Cincinnati and Knee Injury and Osteoarthritis Outcome scores follow-up development

Follow-up (months) Postoperative	Cincinnati X (SD) range	KOOS X (SD) range
Preoperative	53.2 (16.96) 10–79	56.04 (15.29) 22.6–76.19
< 6	88.69 (13.03) 42–100	86.57 (11.46) 52.38–97.6
7–14	85 (16.54) 55–100	87.47 (16.17) 40.48–98.8
15–24	82.38 (16.16) 46–100	89.85 (8.47) 66.07–98.8

Abbreviations: KOOS, Knee Injury and Osteoarthritis Outcome; SD, standard deviation.

(►Table 1) showed an improvement over time, although no further differences were detected after the first 6 months (►Fig. 3a). The mobility varied after the treatment, being considered normal after 6 months postsurgery.

The functional assessment of everyday activities before surgery showed that 50% of the patients could walk less than 1 block and had limitations when it came to climbing upstairs or crouching. In the postoperative period, after 6 months had passed, 75% of patients were able to carry out their daily activities normally. We observed a clinical improvement in walking, going upstairs, sitting and kneeling 6 months after surgery ($p < 0.05$) (►Table 2) (►Table 3). As far as sports activities were concerned, we observed a clear improvement in the patients' capacities in the postoperative period as compared with the preoperative tests ($p < 0.05$) (►Fig. 3b).

There was no difference in the clinical scores between women and men during follow-up (►Table 2) on any of the scales. The osteochondral lesions were found to have better results than the chondral lesions in the last check-up at 24 months (►Table 2) (►Table 3). Perhaps the osteochondral lesions have better results than the chondral ones because the chondral lesions have more subchondral sclerosis making more deformity in the implantation site. Furthermore, the osteochondral lesions have migrations of bone marrow

cells, ensuring a more complete fixation of the bioimplant matrix in the bone.

Of the 43 patients who took part in sports activities, 15 (34.88%) continue with this. Of the 6 professional athletes, 5 continued and 1 had to give up sports.

We found 6 complications (10.71%), half of which were related to the arthrotomy. There were three cases of arthrofibrosis, one of which was accompanied by a complex regional pain syndrome. The arthrofibrosis was treated with arthroscopic arthrolysis and mobilization under anesthesia. The patient with the complex regional pain syndrome had an interconsultation with the pain medicine department and was treated by them, without improvement. The patient ended receiving a unicompartmental knee prosthesis. Three other patients with the graft in the medial condyle still had pain, and after a second look, we observed, in two cases, total delamination of the graft, while in the other there was complete loss of the implant. Since the wound was open, we implanted a fresh osteochondral allograft from the bone bank in the three cases.

According to the patient satisfaction score, 16 (28.6%) were very satisfied, 30 (53.6%) satisfied and would recommend the operation, 8 (14.3%) were unsatisfied, and 2 (3.5%) were disappointed. These last two patients were the ones with the severest complications: one with arthrofibrosis and the other with delamination of the graft.

Discussion

The MACI technique is well-documented for the repair of chondral lesions, and a second indication, when other treatment fails, for use in 2 to 10 cm² lesions in well-aligned legs of young, active patients.

The most widely used algorithms are based on the location, size and depth of the lesion, and the patient's level of activity.^{13,14} The size of the lesion and the patient's level of activity are the most important factors when determining the correct course of treatment. The criteria for ensuring good results are as follows: patients should be young, not obese, non-smokers, with no previous surgery in the area, with defects in the femoral condyle or trochlea without signs of degeneration.¹¹ The lesion should be ≤ 10 cm² in size.

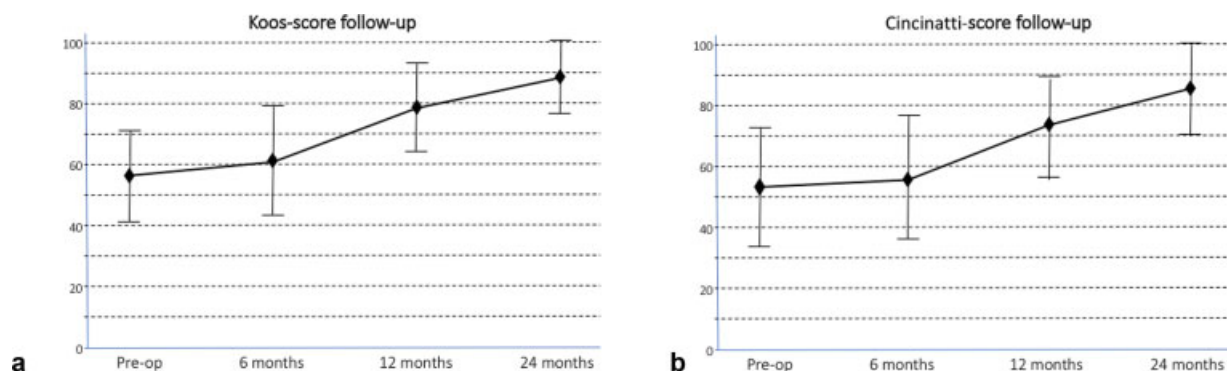


Fig. 3 (a) The Knee Injury and Osteoarthritis Outcome score and (b) the Cincinnati score showed an improvement over time, although no further differences were detected after the first 6 months.

Table 2 Knee Injury and Osteoarthritis Outcome score development for the general population, by gender (women and men) and type of injury (chondral or osteochondral)

	Preoperative X (SD) range	6 months X (SD) range	12 months X (SD) range	24 months X (SD) range
General	56.04 (15.29) 22.6–76.19	62.52 (18.62) 30.3–94.59	78.63 (14.43) 35.12–96.43	88.11 (12.23) 40.48–98.8
Women	58.27 (15.29) 25–75.59	67.99 (18.09) 36.9–92.26	78.78 (15.27) 39.88–95.27	87.33 (17.13) 98.8–50.59
Men	54.8 (15.37) 22.6–76.19	59.48 (18.46) 30.3–94.59	78.55 (14.17) 35.12–96.43	88.54 (12.32) 40.48–98.8
Cartilage injury				
Chondral	55.93 (14.36) 25–76.19	63.51 (17.19) 30.3–92.2	78.89 (13.12) 39.88–96.43	88.73 (9.99) 50.6–98.8
Osteochondral	59.97 (20.44) 22.6–75	63.82 (22.7) 36.9–94.59	84.22 (11.67) 59.52–94.59	93.36 (4.39) 85.71–98.8

Abbreviation: SD, standard deviation.

Table 3 Cincinnati score development for the general population, by gender (women and men) and type of injury (chondral or osteochondral)

	Preoperative X (SD) range	6 months X (SD) range	12 months X (SD) range	24 months X (SD) range
General	53.2 (16.96) 10–79	56.4 (19.30) 19–86	74.75 (16.85) 19–93	85.07 (15.41) 42–100
Women	50.9 (18.9) 10–71	59 (19.5) 19–84	71.75 (21.4) 19–93	81.7 (18.55) 46–100
Men	54.5 (15.93) 10–79	54.94 (19.33) 19–93	76.42 (13.75) 38–93	86.94 (13.27) 42–100
Cartilage injury				
Chondral	53.35 (16.98) 10–78	56.7 (19.36) 19–86	75.3 (16.97) 19–93	84.93 (14.35) 46–100
Osteochondral	53.11 (20.25) 10–79	59 (20.1) 34–80	78.56 (10) 60–93	92.78 (5.65) 82–100

Abbreviation: SD, standard deviation.

Natural polymer and synthetic biodegradable scaffolds have been used, with high porosity, a large cell contact surface, a stable structure, three-dimensional shape and biocompatible composition. Different types of materials have been proposed, such as collagen-1,³ hyaluronic acid,⁵ collagen-3,¹⁵ or fibrin.⁶ Fibrin scaffolds are formed when two components derived from blood plasma come together (thrombin and fibrinogen) to build a specific matrix that offers a good environment for chondrocytes to proliferate.^{8,16,17}

Injuries to the medial femoral condyle generally obtained better results, after a 3-year follow up, than those in the lateral condyle, but not than those in the patella.¹⁸ In our study, we had results similar to those in the literature. We think that these results are due to the characteristics of the location of the lesions. The medial femoral condyle is the anatomical site that carries more load, when compared with other sites, making the lesions a reflect of the load. The bicondylar lesions show an arthropathy of the two compartments, making the postoperative evolution less successful.

The femoropatellar articulation is not a direct load site. The main function of this articulation is a pulley mechanism, which makes flexoextension movements of the knee easy to perform. Furthermore, the patella is intimately associated with the trochlear groove of the femur, facilitating the implantation of the Chondrograft.

Age is a factor that may be related to the degenerative process or may have a negative impact on the joint.¹⁹ The best results are obtained with patients under the age of 30.^{20,21} Although, the majority of the studies shows the age of the patients as an important factor for the prognostic of the procedure, we didn't find any relation in our study. With our results, the viability of the chondrocytes and the conditions of the patients were the two major factors for the treatment success, more than age.

The waiting time before surgery has also been found to have an influence on the outcome,^{18,19} although other factors influence the final result, such as the stability of the knee joint, the state of the menisci and ligaments, the patient's

weight (the best results are obtained when BMI < 30), and the alignment of the lower extremity.

In our study, we modified the technique developed by Visna et al.,⁶ performing 1 or 2 passes to obtain 15×10^6 cells, in 26 days, ensuring that the chondrocytes preserved their capacity for redifferentiation when they were seeded in the scaffold. We cultured the chondrocytes in the patient's own serum to reduce the risk of hypersensitivity to bovine products and to infection. Our aim was to achieve regeneration of the joint surface through regeneration of the hyaline cartilage, which is translated clinically into elimination of pain and inflammation, and functional improvement.

In a multi-center study, Micheli et al.²² found that 94% of grafts survived 3 years after surgery, in 50 patients with a mean age of 36 years and an average lesion of 4.2 cm². Moseley et al.²³ confirmed that after 10 years, 69% of operations had improved results, with a failure rate of 17% and 12.5% who remained unchanged.

In the series described by Marcacci et al.⁵ of patients receiving MACI and arthroscopic follow-up, they found that four patients had fibrocartilage and six had fibrous-hyaline cartilage. The presence of hyaline cartilage was evident in 11 patients. Of the 23 patients followed by Roberts et al.,²⁴ 7 had fibrocartilage and only 5 patients had regenerated hyaline cartilage after a long follow-up period. In their other cases, they observed fibro-hyaline-type cartilage covering the lesion. Tins et al.²⁵ presented similar results: 12 months after surgery, they found fibrocartilage in 25 out of 39 cases, while 10 had hyaline-fibrous tissue and only 4 had hyaline cartilage.

We have not performed biopsies to our patients, but we sustain that chondrocyte go through a process of redifferentiation over prolonged periods of time, and to prevent this, we recommend storing chondrocytes in viscous media so that the cells are kept suspended apart.

Even though two studies compared the initial technique, the autologous chondrocyte culture implant (ACI), with the second generation of MACI, but found no significant differences,^{26,27} it seems to us that the original technique has to be in disuse because it is more aggressive and the evolution is more uncertain.

Furthermore, the MACI has decreased the complications of the ACI, although Bartlett et al.²⁶ performed a prospective, randomized study comparing MACI and ACI in 91 patients. Both groups were found to have similar results 2 years after surgery, and both techniques resulted in an improvement 1 year after surgery. The incidence of hypertrophy was low, only 9% (4/44) in the ACI group, and 6% (3/47) in the MACI group, while 9% of the patients had to have a second operation. Areas of fibrocartilage were also found when using MACI, possibly due to the low cellular density and poor proliferative capacity.

It is possible to question the advisability of using such techniques based on biotechnology, which are more expensive and demanding than simpler techniques, such as microfractures. Knutsen et al.,²¹ in a study of 40 patients, found no biological or histological differences after 2 years between patients treated with microfractures and those treated using ACI. After 5 years, the results were similar, but there were

early signs of degeneration in 30% of the patients who had been treated with microfractures.¹⁰ Saris et al.^{19,28} also compared microfractures with ACI, with a follow-up period of 36 months, in 118 randomized patients. The general KOOS score was similar in both groups, although the results for pain and quality of life were better in the ACI group. The histological evaluation was also better in the ACI group, and the subchondral bone reaction was also worse in the group treated with microfractures. After longer follow-up, the KOOS score was found to be more positive in the ACI group. Similarly, Basad et al.,²⁹ in a 2-year randomized study, observed better results with MACI than with microfractures.

Our results were better with the osteochondral lesions than with the chondral ones; this is because the chondral lesions have more subchondral sclerosis, thus presenting more deformity in the implantation site. Furthermore, the osteochondral lesions have migrations of bone marrow cells, ensuring a more complete fixation of the bioimplant matrix in the bone.

As far as complications are concerned, Vascellari et al.³⁰ found no complications in 30 patients after a 70-month follow-up. In our study, we used fibrin glue to anchor the cells adequately,⁶ distributing them homogeneously and keeping them at all levels within the graft. This technique is currently classified as third generation and offers a favorable chondrogenic environment. Six months after the implant, most patients had resumed their everyday activities and were able to work and practice normal-to-moderate exercise. One third of the patients took part in sports activities, and 83% of the patients described their operated knee as normal. Currently, 75% of the patients indicated that they could walk, go upstairs, and kneel normally, without any kind of problem.

One limitation of the present study is the lack of biopsy and magnetic resonance imaging data. We have focused on the clinical aspects of this condition, and on the state of the patients and their everyday life. Although the follow-up period was long enough, it would be useful to have studies with a longer follow-up timeframe to find out how many of these patients needed further operations or joint replacements.

Seeding chondrocytes in a fibrin scaffold can provide a favorable micro-environment for synthesizing extracellular matrix and allows us to halt the advance of disease, so that joint mobility can be restored, and pain reduced, and the patient can resume the daily activities at an early stage.

Financial Support

There was no financial support from public, commercial, or non-profit sources.

Conflict of Interests

The authors declare that there is no conflict of interests.

References

- 1 Wakitani S, Kawaguchi A, Tokuhara Y, Takaoka K. Present status of and future direction for articular cartilage repair. *J Bone Miner Metab* 2008;26(02):115–122

- 2 Forriol F. Growth factors in cartilage and meniscus repair. *Injury* 2009;40(Suppl 3):S12–S16
- 3 Ochi M, Uchio Y, Kawasaki K, Wakitani S, Iwasa J. Transplantation of cartilage-like tissue made by tissue engineering in the treatment of cartilage defects of the knee. *J Bone Joint Surg Br* 2002;84(04):571–578
- 4 Brittberg M, Peterson L, Sjögren-Jansson E, Tallheden T, Lindahl A. Articular cartilage engineering with autologous chondrocyte transplantation. A review of recent developments. *J Bone Joint Surg Am* 2003;85(Suppl 3):109–115
- 5 Marcacci M, Berruto M, Brocchetta D, et al. Articular cartilage engineering with Hyalograft C: 3-year clinical results. *Clin Orthop Relat Res* 2005;(435):96–105
- 6 Visna P, Pasa L, Hart R, Kocis J, Cizmár I, Adler J. [Treatment of deep chondral defects of the knee using autologous chondrocytes cultured on a support—results after one year]. *Acta Chir Orthop Traumatol Cech* 2003;70(06):356–362
- 7 Murphy CL, Polak JM. Control of human articular chondrocyte differentiation by reduced oxygen tension. *J Cell Physiol* 2004;199(03):451–459
- 8 Brodtkin KR, García AJ, Levenston ME. Chondrocyte phenotypes on different extracellular matrix monolayers. *Biomaterials* 2004;25(28):5929–5938
- 9 da Cunha Cavalcanti FM, Doca D, Cohen M, Ferretti M. Updating on diagnosis and treatment of chondral lesion of the knee. *Rev Bras Ortop* 2015;47(01):12–20
- 10 Knutsen G, Drogset JO, Engebretsen L, et al. A randomized trial comparing autologous chondrocyte implantation with microfracture. Findings at five years. *J Bone Joint Surg Am* 2007;89(10):2105–2112
- 11 Bentley G, Bhamra JS, Gikas PD, Skinner JA, Carrington R, Briggs TW. Repair of osteochondral defects in joints—how to achieve success. *Injury* 2013;44(Suppl 1):S3–S10
- 12 Tamez-Peña JG, Farber J, González PC, Schreyer E, Schneider E, Totterman S. Unsupervised segmentation and quantification of anatomical knee features: data from the Osteoarthritis Initiative. *IEEE Trans Biomed Eng* 2012;59(04):1177–1186
- 13 Cole BJ, Pascual-Garrido C, Grumet RC. Surgical management of articular cartilage defects in the knee. *J Bone Joint Surg Am* 2009;91(07):1778–1790
- 14 Vaquero J, Forriol F. Knee chondral injuries: clinical treatment strategies and experimental models. *Injury* 2012;43(06):694–705
- 15 Gomoll AH, Probst C, Farr J, Cole BJ, Minas T. Use of a type I/III bilayer collagen membrane decreases reoperation rates for symptomatic hypertrophy after autologous chondrocyte implantation. *Am J Sports Med* 2009;37(Suppl 1):20S–23S
- 16 Bolliger-Stucki B, Baillod P, Mäder W, Furlan M. Biochemical properties of the fibrinogen component of a fibrin glue before and after severe dry heat treatment. *J Biomed Mater Res* 2000;53(05):577–583
- 17 Perka C, Spitzer RS, Lindenhayn K, Sittinger M, Schultz O. Matrix-mixed culture: new methodology for chondrocyte culture and preparation of cartilage transplants. *J Biomed Mater Res* 2000;49(03):305–311
- 18 de Windt TS, Bekkers JE, Creemers LB, Dhert WJ, Saris DB. Patient profiling in cartilage regeneration: prognostic factors determining success of treatment for cartilage defects. *Am J Sports Med* 2009;37(Suppl 1):58S–62S
- 19 Saris DB, Vanlauwe J, Victor J, et al. Characterized chondrocyte implantation results in better structural repair when treating symptomatic cartilage defects of the knee in a randomized controlled trial versus microfracture. *Am J Sports Med* 2008;36(02):235–246
- 20 Bekkers JE, Inklaar M, Saris DB. Treatment selection in articular cartilage lesions of the knee: a systematic review. *Am J Sports Med* 2009;37(Suppl 1):148S–155S
- 21 Knutsen G, Engebretsen L, Ludvigsen TC, et al. Autologous chondrocyte implantation compared with microfracture in the knee. A randomized trial. *J Bone Joint Surg Am* 2004;86(03):455–464
- 22 Micheli LJ, Moseley JB, Anderson AF, et al. Articular cartilage defects of the distal femur in children and adolescents: treatment with autologous chondrocyte implantation. *J Pediatr Orthop* 2006;26(04):455–460
- 23 Moseley JB Jr, Anderson AF, Browne JE, et al. Long-term durability of autologous chondrocyte implantation: a multicenter, observational study in US patients. *Am J Sports Med* 2010;38(02):238–246
- 24 Roberts S, McCall IW, Darby AJ, et al. Autologous chondrocyte implantation for cartilage repair: monitoring its success by magnetic resonance imaging and histology. *Arthritis Res Ther* 2003;5(01):R60–R73
- 25 Tins BJ, McCall IW, Takahashi T, et al. Autologous chondrocyte implantation in knee joint: MR imaging and histologic features at 1-year follow-up. *Radiology* 2005;234(02):501–508
- 26 Bartlett W, Skinner JA, Gooding CR, et al. Autologous chondrocyte implantation versus matrix-induced autologous chondrocyte implantation for osteochondral defects of the knee: a prospective, randomised study. *J Bone Joint Surg Br* 2005;87(05):640–645
- 27 Manfredini M, Zerbinati F, Gildone A, Faccini R. Autologous chondrocyte implantation: a comparison between an open periosteal-covered and an arthroscopic matrix-guided technique. *Acta Orthop Belg* 2007;73(02):207–218
- 28 Saris DB, Vanlauwe J, Victor J, et al; TIG/ACT/01/2000&EXT Study Group. Treatment of symptomatic cartilage defects of the knee: characterized chondrocyte implantation results in better clinical outcome at 36 months in a randomized trial compared to microfracture. *Am J Sports Med* 2009;37(Suppl 1):10S–19S
- 29 Basad E, Ishaque B, Bachmann G, Stürz H, Steinmeyer J. Matrix-induced autologous chondrocyte implantation versus microfracture in the treatment of cartilage defects of the knee: a 2-year randomised study. *Knee Surg Sports Traumatol Arthrosc* 2010;18(04):519–527
- 30 Vascellari A, Rebuzzi E, Schiavetti S, Coletti N. Implantation of matrix-induced autologous chondrocyte (MACI®) grafts using carbon dioxide insufflation arthroscopy. *Knee Surg Sports Traumatol Arthrosc* 2014;22(01):219–225