



# Minimally Invasive Osteosynthesis of Transtrochanteric Fractures with Dynamic Hip Screw (DHS)\*

## *Osteossíntese minimamente invasiva de fraturas transtrocantéricas com Dynamic Hip Screw (DHS)*

José André Melo Barreto Guimarães<sup>1</sup> Marcos Cezar Feitosa de Paula Machado<sup>2</sup>  
 Pauliana Valéria Machado Galvão<sup>2</sup> Jéssika Cristina de Lima<sup>2</sup> Lucas Dos Santos Gomes<sup>2</sup>  
 Pedro Ferreira Barreto Guimarães<sup>3</sup>

<sup>1</sup> Hospital São Vicente, Serra Talhada, PE, Brazil

<sup>2</sup> Medical School, Universidade de Pernambuco (Campus Serra Talhada), Serra Talhada, PE, Brazil

<sup>3</sup> Faculdade de Medicina de Olinda (FMO), Olinda, PE, Brazil  
 Rev Bras Ortop 2021;56(1):109–113.

Address for correspondence Pauliana Valéria Machado Galvão, PhD, Professora Assistente, Universidade de Pernambuco, Faculdade de Medicina, Campus Serra Talhada, Avenida Gregório Ferraz Nogueira, s/n, Estação Experimental Lauro Bezerra, Serra Talhada, PE, 56909535, Brazil (e-mail: pauliana.galvao@upe.br).

### Abstract

The method presented here consists of a minimally invasive surgical technique for osteosynthesis of transtrochanteric fractures with *Dynamic Hip Screw* (DHS) 135°. It is indicated in the treatment of 31-A1 and 31-A2 fractures (Arbeitsgemeinschaft für Osteosynthesefragen Classification - AO) that meet the prerequisites required for using DHS. The surgery is performed, preferably, before 48 hours after the fracture. With the use of the same instruments as the traditional surgical technique and the aid of the Garm, a closed reduction of the fracture and implantation of the DHS is performed by a 2-cm surgical incision, through dissection of the underlying tissues, with minimal bleeding and damage to the soft parts. In the immediate postoperative period, the patient is encouraged to orthostatism and walk with full load, which anticipates hospital discharge and favors early functional rehabilitation. Outpatient return is scheduled at 2, 6, 12 and 24 weeks postoperatively, with radiographic evaluation to assess fracture healing.

### Keywords

- ▶ femoral fractures
- ▶ hip fractures
- ▶ minimally invasive surgical procedures

### Resumo

O método aqui apresentado consiste em técnica cirúrgica minimamente invasiva para osteossíntese de fraturas transtrocantéricas com *Dynamic Hip Screw* (DHS) 135°. Esta técnica é indicada no tratamento de fraturas 31-A1 e 31-A2 (Classificação Arbeitsgemeinschaft für Osteosynthesefragen - AO) que cumpram os pré-requisitos exigidos para o uso do DHS. A cirurgia é realizada, preferencialmente, antes de 48 horas após o acometimento da fratura. Com a utilização do mesmo instrumental da técnica cirúrgica tradicional e auxílio do arco-C, realiza-se redução incruenta da fratura e implantação do DHS por incisão cirúrgica com 2 cm, através de dissecação dos tecidos subjacentes, com mínimo sangramento e agressão às partes moles. No pós-operatório imediato, o paciente é estimulado ao ortostatismo e à deambulação com carga total, o que antecipa a alta hospitalar e favorece a reabilitação funcional precoce. O retorno ambulatorial é agendado com 2, 6, 12 e 24 semanas de pós-operatório, com avaliação radiográfica, a fim de avaliar a consolidação da fratura.

### Palavras-chave

- ▶ fraturas do fêmur
- ▶ fraturas do quadril
- ▶ procedimentos cirúrgicos minimamente invasivos

\* Work developed at the Hospital São Vicente, Serra Talhada, PE, Brazil.

received  
 May 14, 2020  
 accepted  
 July 6, 2020  
 published online  
 September 25, 2020

DOI <https://doi.org/10.1055/s-0040-1716758>.  
 ISSN 0102-3616.

© 2020. Sociedade Brasileira de Ortopedia e Traumatologia. All rights reserved.  
 This is an open access article published by Thieme under the terms of the Creative Commons Attribution-NonDerivative-NonCommercial-License, permitting copying and reproduction so long as the original work is given appropriate credit. Contents may not be used for commercial purposes, or adapted, remixed, transformed or built upon. (<https://creativecommons.org/licenses/by-nc-nd/4.0/>)  
 Thieme Revinter Publicações Ltda., Rua do Matoso 170, Rio de Janeiro, RJ, CEP 20270-135, Brazil

## Introduction

Transtrochanteric fracture is a type of injury that occurs in the proximal region of the femur, mainly affects the elderly, and has high rates of morbidity and mortality. Its treatment is surgical in most cases and must be performed within 48 hours after the trauma to reduce the risk of secondary injuries. Otherwise, there is a considerable increase in the risk of mortality.<sup>1</sup>

Three aspects call attention in the management of the elderly with this diagnosis: the aging of the Brazilian population, the traditional technique widely used (since it does not allow immediate functional recovery, causing many complications in an already fragile organism) and the high costs for the public and private health systems in the treatment of such conditions.<sup>2-4</sup>

The main argument of those who advocate the use of locked intramedullary nailing in the treatment of transtrochanteric fractures is the size of the surgical incision, which would decrease surgical trauma and postoperative pain, with better functional recovery for elderly patients. In this sense, this treatment has assumed a leading role given the aggressiveness of more traditional surgical approaches.<sup>4</sup>

A great surgical trauma is harmful to the target population of these fractures, since large incisions and great tissue damage are the cause of infections, delayed consolidation and long periods of immobility.<sup>4,5</sup> It should also be considered that in the elderly population there is a high prevalence of comorbidities and significant functional deficit,<sup>1</sup> and that a less traumatic technique is required for osteosynthesis of these fractures. The method presented here is a minimally invasive technique for implanting of the *Dynamic Hip Screw* (DHS) in transtrochanteric osteosynthesis.

## Surgical Technique

The indications of the technique presented here coincide with the techniques proper to the DHS-135°, that is, transtrochanteric fractures classified as 31-A1 and 31-A2 (Arbeitsgemein-

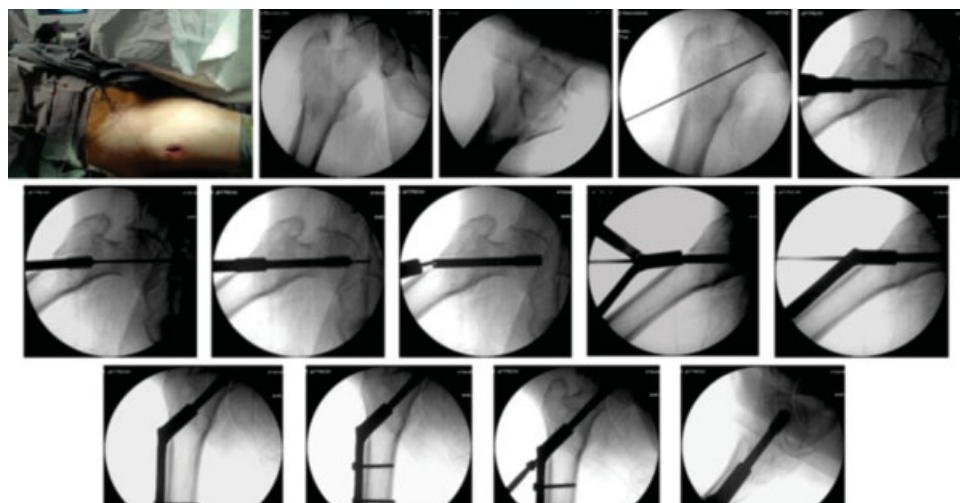
schaft für Osteosynthesefragen Classification - AO) that respect the criteria for the use of DHS: lateral cortex  $\geq 20.5\text{mm}$ .<sup>6</sup> The technique is contraindicated in unstable fractures, classified as 31-A3 (AO), with an oblique-reverse line, and with an affected lateral wall.<sup>2,4</sup> In conventional DHS instruments, the large size guide requires large incisions. They were abandoned and replaced by a transparency (template) that, when placed over the image of the C-arm, determines the angle of 135° required by the implant. Tube plates of three holes are used, fixed only in 4 cortices, through the first and third holes of the plate. Other items used in osteosynthesis are part of the standard instruments, not being modified or adapted for the application of this technique (► **Figure 1**).

In the operating room, after isobaric spinal anesthesia, the patient is placed on the orthopedic table with the affected limb extended and the contralateral limb flexed, giving access to the surgical arch in the lateral view (► **Figure 2A**). Satisfactory fracture reduction should be required in both the frontal and sagittal planes, and this search for the best reduction is considered the most important point of the procedure (► **Figures 2B** and **2C**).

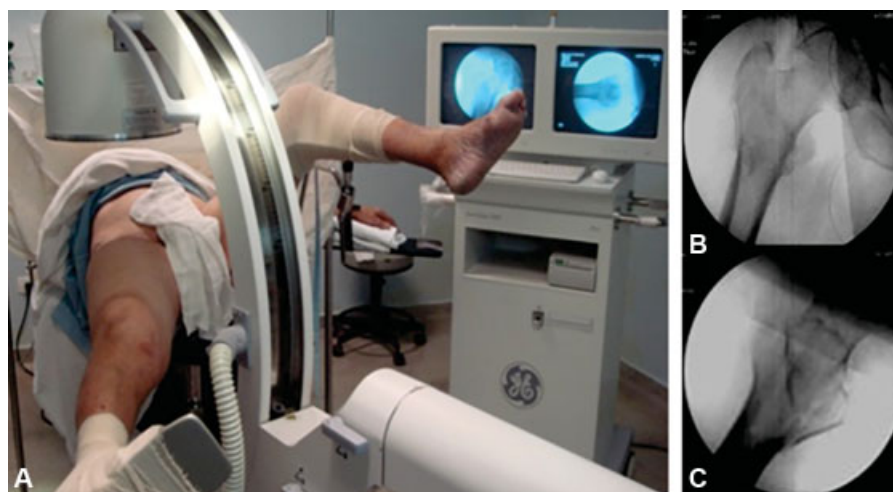Initially, the skin incision is located on the lateral side of the proximal thigh, achieved by positioning a Kirschner wire over the skin of the anterior hip (► **Figure 3A**), verifying its position in the anteroposterior (AP) view, which should be centralized in the femoral neck (► **Figure 3B**). The projection of this wire on the side of the thigh determines the position of the incision to be made. At this point, the wire is introduced into the skin until contact with the lateral cortex of the femur, in order to determine the height of the incision, in the sagittal plane, which must be in the center of the diaphysis.

A 2-cm incision is made, using a scalpel, and involving the skin, subcutaneous tissue, and the fascia lata. The vastus lateralis muscle of the thigh will be divulsed with scissors, opening a submuscular space, both towards the greater trochanter and towards the femoral diaphysis.

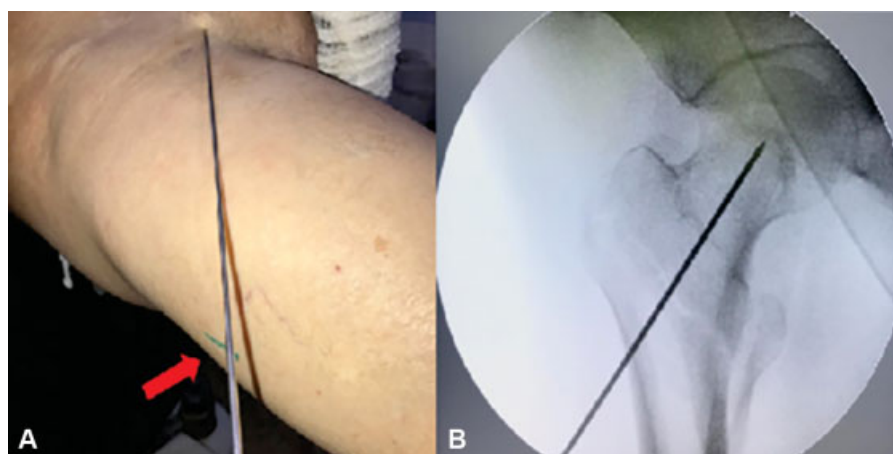
Subsequently, the guidewire is introduced through the lateral cortex towards the neck of the femur. When the guidewire touches the lateral cortex, an AP image is made, and a



**Fig. 1** Radioscopic sequence of transtrochanteric osteosynthesis. It draws attention to the size of the necessary incision.



**Fig. 2** Positioning the patient on an orthopedic table. Anteroposterior and profile views of the fracture reduction.



**Fig. 3** In A, projection of the anterior wire on the lateral face determines the location of the incision (red arrow). In B, radioscopic view of the centralized position of this wire in the femoral neck.

transparency applied to the surgical arch monitor will determine a cervico-diaphyseal angle of  $135^\circ$  (► **Figures 4A** and **4B**). When the wire and the template's marking are coincident, the wire is introduced to the subchondral bone of the femoral head. To assess the position of this guidewire introduced in the sagittal plane, the lateral view should be performed. The guidewire should be centered on the neck and femoral head in the AP (► **Figure 4C**) and profile views (► **Figure 4D**). This will determine the quality of osteosynthesis.

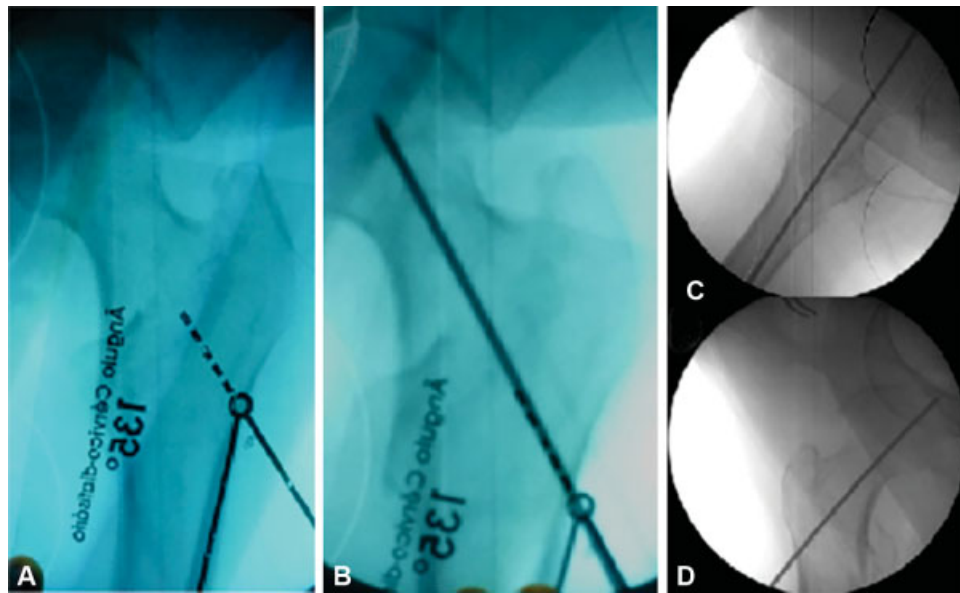
The size of the sliding screw is determined using another wire, of the same length, subtracting with the extra bony part of the inserted wire. Next, the chosen sliding screw is milled and placed, which must reach 10 mm from the hip joint space. After that, remove the guidewire. In sequence, the tube-plate is placed in the skin incision in an inverted manner, that is, with the tube pointing outwards from the patient (► **Figure 5A**) and the plaque sliding into the sub-muscular space opened at the beginning of the surgery (► **Figure 5B**). With the help of the sliding screw extender, it is easily made a  $180^\circ$  turn on the plate, in the longitudinal axis, leaving it in the position of adaptation to the sliding

screw, which will be completed with the aid of the plate impactor (► **Figure 5C**). The holes in the femur are made to place the cortical screws and the fracture is compressed with the introduction of the compression screw. The incision is closed with a mononylon 2-0 thread, with a stitch on the fascia lata and two on the skin (► **Figure 5D**).

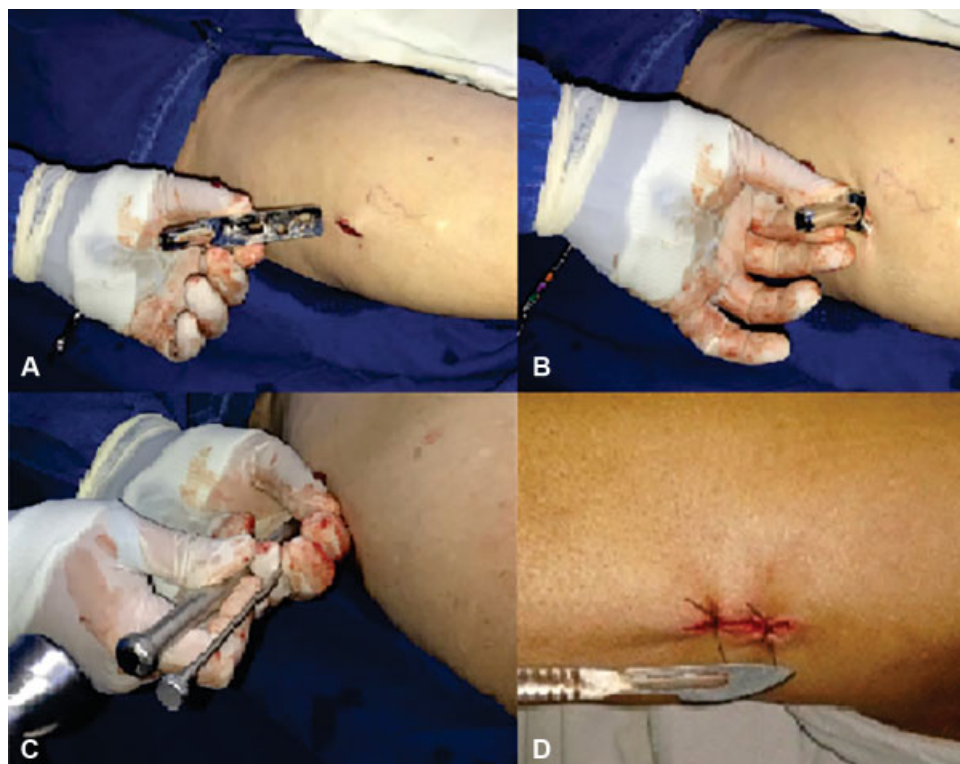In the immediate postoperative period, 12 hours, orthostatism and walking at full load are encouraged, with assistance. Hospital discharge occurs on the first day after surgery and outpatient visits are scheduled at 2, 6, 12 and 24 weeks postoperatively. The consolidation criteria are radiological and consist of trabecular reform or bridged bone callus around the trochanteric region. Consolidation delay was defined as no radiological signs of consolidation at 6 months postoperatively and pseudarthrosis is diagnosed at 9 months postoperatively.

### Final Comments

Osteosynthesis of the transtrochanteric fracture using the conventional technique (open reduction and internal fixation with DHS- $135^\circ$ ) uses an incision that varies from 10 to 14 cm,



**Fig. 4** In A, note the apposition of the template on the C-arm monitor; In B, guidewire introduced respecting the template's marking; In C and D, final position of the guidewire in profile and anteroposterior views, respectively.



**Fig. 5** In A and B, the plate is inserted in the inverted position; in C, on the sliding screw extension, the plate is impacted; in D, surgical wound suture.

which determines the long duration of the surgery, high aggression to the soft tissues and massive blood loss.<sup>3,7,8</sup> Minimally invasive techniques, in turn, bring several benefits to orthopedics, such as: less soft tissue injury and blood loss, as well as reduced risk of infections and duration of surgery. In addition, they allow early rehabilitation, with a consequent decrease in the risk of postoperative complications.<sup>5</sup>

The patient operated by the technique described evolves with less pain in the immediate postoperative period, with orthotatism and gait at full load being stimulated 12 hours after the procedure. It is a technique with easy execution and high reproducibility that can contribute to help in the epidemic of fractures of the proximal femur expected in the coming decades, due to the aging of the population.



**Conflict of Interests**

The authors have no conflict of interests to declare.

**References**

- 1 Bottle A, Aylin P. Mortality associated with delay in operation after hip fracture: observational study. *BMJ* 2006;332(7547):947–951
- 2 Matre K, Havelin LI, Gjertsen JE, Vinje T, Espehaug B, Fevang JM. Sliding hip screw versus IM nail in reverse oblique trochanteric and subtrochanteric fractures. A study of 2716 patients in the Norwegian Hip Fracture Register. *Injury* 2013;44(06):735–742
- 3 Kellam JF. Tratamento cirúrgico de fraturas intertrocantéricas. In: Sledge CB. *Quadril*. Rio de Janeiro: Revinter; 2005:109–128
- 4 Shen J, Hu C, Yu S, Huang K, Xie Z. A meta-analysis of percutaneous compression plate versus intramedullary nail for treatment of intertrochanteric HIP fractures. *Int J Surg* 2016;29:151–158
- 5 Thaeter M, Kobbe P, Verhaven E, Pape HC. Minimally Invasive Techniques in Orthopedic Trauma. *Curr Trauma Rep* 2016;2(04):232–237
- 6 Hsu CE, Shih CM, Wang CC, Huang KC. Lateral femoral wall thickness. A reliable predictor of post-operative lateral wall fracture in intertrochanteric fractures. *Bone Joint J* 2013;95-B(08):1134–1138
- 7 Sledge CB. *Quadril – Master Techniques in Orthopaedic Surgery*. Rio de Janeiro: Revinter; 2005
- 8 Sawaia RN, Belangero WD. Sistema MINUS® - Técnica Minimamente Invasiva para o tratamento das Fraturas Transtrochanterianas do Fêmur. *Rev Bras Ortop* 2012;47(01):113–117