

Endoluminal Vacuum Therapy for Iatrogenic Perforation of the Proximal Esophagus—Case Report of a Patient with Esophageal Involvement in Pemphigus Vulgaris

Sabine Wächter¹ Leif Schiffmann² Ulrike W. Denzer³

¹Department of Visceral, Thoracic- and Vascular Surgery, Philipps-University Marburg, Baldingerstraße, Marburg, Germany

²Department of General, Thoracic, Vascular and Transplantation Surgery, University of Rostock, Rostock, Germany

³Department of Gastroenterology, University Hospital Marburg, Marburg, Germany

Address for correspondence Sabine Wächter, MD, Department of Visceral, Thoracic and Vascular Surgery, Philipps-University Marburg, Baldingerstraße, 35043 Marburg, Germany (e-mail: seckhard@med.uni-marburg.de).

J Digest Endosc:2020;11:287–289

Abstract

Keywords

- case report
- pemphigus vulgaris
- esophageal involvement
- endoluminal vacuum therapy
- esophageal perforation

Pemphigus vulgaris (PV) is a rare autoimmune disease affecting the skin and mucous membranes. Recent studies have shown a relatively high incidence of esophageal involvement in PV. To distinguish between the esophageal involvement of PV and other pathologies, early endoscopic evaluation is essential to obtain tissue for histological analysis. Here, we present the first case of endoluminal vacuum therapy (EVT) for a patient with esophageal involvement in PV and with associated iatrogenic perforation of the proximal esophagus. In comparison to classical treatment options for perforations of the proximal esophagus consisting of either stent insertion or surgical intervention, EVT seems to be a promising alternative with a good clinical outcome.

Introduction

Pemphigus vulgaris (PV) is a rare autoimmune disease affecting the skin and mucous membranes. Although mucosal involvement in PV is mainly observed in the oral cavity, pharyngoesophageal involvement of PV is also found, but rarely described in literature.¹ Recent studies have shown a relatively high incidence (46–87%) of esophageal involvement in PV that is often associated with a high fragility of the esophageal mucosa.² To our knowledge, here, we present the first case of endoluminal vacuum therapy (EVT) for a patient with esophageal involvement in PV and with associated iatrogenic perforation of the proximal esophagus.

Case History

A 67-year-old woman presented to our gastroenterology clinic with progressive severe dysphagia and odynophagia for the last 1 year. Her known medical history consisted of a

PV, which was diagnosed 13 years ago and had been treated with two cycles of immunoadsorption 10 and 11 years ago. Moreover, she had received mycophenolate-mofetil for about 3 years and current treatment consisted of prednisolone 5 mg once a day. Furthermore, she suffered from a chronic lymphatic leukemia (Binet stage A) and an atrial fibrillation under anticoagulation with apixaban.

The patient was admitted to our institution for esophagogastroduodenoscopy (EGD) to evaluate the esophageal involvement of PV. During the initial endoscopic intubation, an esophageal perforation reaching the muscularis layer of ~4 cm length directly below the upper esophageal sphincter happened accidentally. This may be due to the esophageal involvement of PV showing a stenotic esophagus with fragile mucosa and probably a medium experienced endoscopist. Immediate endoscopic defect closure by applying a hemoclip suture was undertaken by an experienced endoscopist in the same investigation (►Fig. 1A, B). Additionally, we placed a nasogastric feeding tube for enteral

DOI <https://doi.org/10.1055/s-0040-1716629>
ISSN 0976-5042.

© 2020. Society of Gastrointestinal Endoscopy of India.
This is an open access article published by Thieme under the terms of the Creative Commons Attribution-NonDerivative-NonCommercial-License, permitting copying and reproduction so long as the original work is given appropriate credit. Contents may not be used for commercial purposes, or adapted, remixed, transformed or built upon. (<https://creativecommons.org/licenses/by-nc-nd/4.0/>).
Thieme Medical and Scientific Publishers Pvt. Ltd. A-12, 2nd Floor, Sector 2, Noida-201301 UP, India

feeding and started a calculated antibiotic therapy with meropenem (3 g over 24 hours) to prevent a mediastinitis.

One day later, inflammation parameters increased and a subsequently performed computed tomography (CT) scan of the neck and the thorax showed a leakage in the proximal esophagus with proof of air and suspicion of contrast media in the mediastinum (►Fig. 2A, B). According to an interdisciplinary consent, the clips were endoscopically removed at the same day and a vacuum-assisted closure (VAC) sponge (Esosponge Braun Melsungen, Germany) was applied after debridement of the wound cavity in the same session (►Fig. 3A, B). The VAC sponge is a large-pore polyurethane foam on a gastric tube, which was in this case inserted intraluminally using negative pressure of 125 mm Hg with continuous suction for drainage and inducing wound healing.³

For better clinical observation, the patient was transferred to intensive care unit for 24 hours.

In the further clinical course, inflammatory parameters declined and endoluminal vacuum therapy (EVT) achieved an excellent granulation of the wound. The first endoscopic sponge change was performed 2 days later and a smaller sponge was inserted (►Fig. 4A). Five days later, the leak in

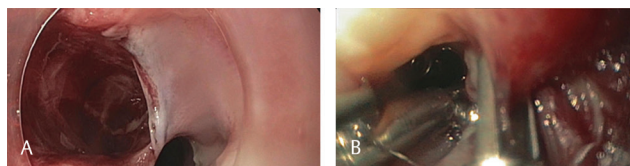


Fig. 1 (A) During the endoscopic intubation, an esophageal perforation reaching the muscularis layer directly below the upper esophageal sphincter happened accidentally. (B) Immediate endoscopic defect closure by applying a hemoclip suture was undertaken.

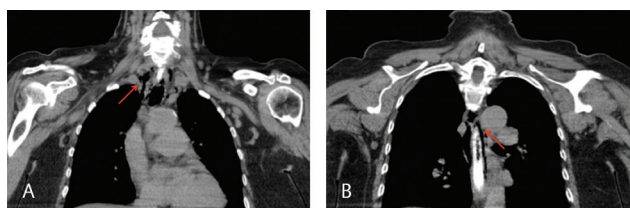


Fig. 2 (A, B) One day after the perforation, CT showed a leakage in the proximal esophagus with proof of air and suspicion of contrast media in the mediastinum.

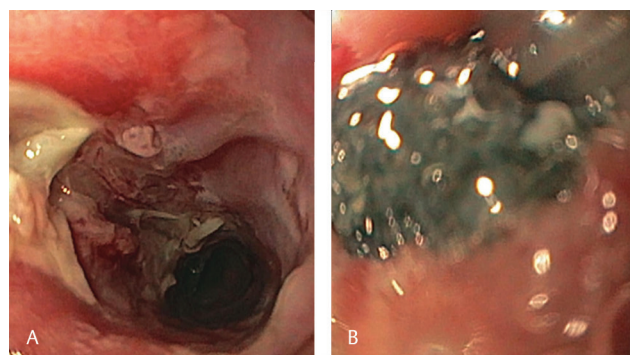


Fig. 3 (A, B) As a consequence of the CT the clips were endoscopically removed and a vacuum-assisted closure (VAC) sponge was applied after debridement of the wound cavity.

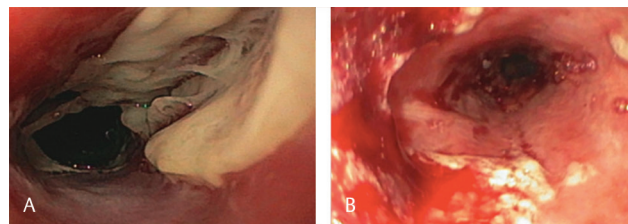


Fig. 4 (A) Endoscopic vacuum therapy (EVT) achieved an excellent granulation of the wound within two days of treatment. (B) Seven days after the perforation the leak in the upper esophageal sphincter showed a sufficient granulation and complete closure, so that EVT was finished.

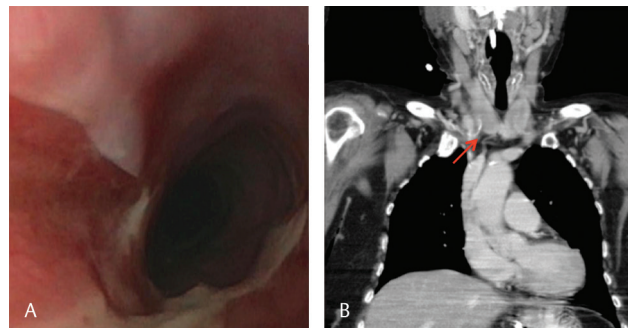


Fig. 5 (A, B) A control EGD and a CT scan, which was performed 11 days after perforation confirmed closure of the leak with complete release of pneumomediastinum 11 days after perforation.

the upper esophageal sphincter showed a sufficient granulation and complete closure and EVT was finished after a total treatment period of 7 days (►Fig. 4B). During EVT, we continued the enteral nutrition via feeding tube. After termination of the VAC therapy, both a control EGD and a CT scan, which was performed 11 days after perforation, confirmed closure of the leak with complete release of pneumomediastinum (►Fig. 5A, B). The patient recovered and oral nutrition was readministered. Furthermore, the endoscopic examination of the esophagus was completed and revealed an ulcerated esophagus with multiple erosions and friable linings. The histological examination of endoscopic taken biopsies confirmed the esophageal PV and excluded other differential diagnoses. The patient was referred to dermatology and a therapy with rituximab was initiated leading to resolving dysphagia symptoms with no need for a control EGD since then.

Discussion

EVT has been proven to be an effective tool for treating post-operative leakages after esophageal or colorectal surgery.⁴⁻⁶ Reported success rates of defect closing range between 85 and 95%.^{7,8} Alternative endoscopic therapy consists of insertion of a fully covered metal stent and recently closure of the perforation site using an over-the-scope-clip (OTSC). Several studies compared EVT versus self-expandable stents (SEMS) for the treatment of anastomotic leaks and demonstrated that the rate of successful wound closure was higher after EVT than after insertion of stents.^{4,9,10} EVT was associated with a shorter treatment duration, lower major complication, and in-hospital mortality rate compared with SEMS.¹¹

One main advantage of EVT is that the sponge can be placed intraluminally and intracavitary. SEMS seals the perforation and can therefore only be applied in acute perforations without placing an additional drainage extraluminally. In older perforations with accompanying abscesses, SEMS treatment alone would make an additional drainage or surgical intervention necessary.¹²

Recently positive results of EVT have also been published for the treatment of acute esophageal perforations.^{13,14} In this regard, Loske et al demonstrated on a series with 10 patients with acute perforations of the upper gastrointestinal tract a successful treatment of all patients within a median time of 5 (3–7) days.¹³

In principle, the OTSC system (OVESCO Endoscopy AG, Tübingen, Germany) would be a good alternative for acute endoscopy-associated perforations—in this case, however, it would be difficult to use due to the length of the perforation and the close relationship to the upper esophageal sphincter.

If a sponge is inserted intraluminally as in our patient, it mostly can keep its original size. In case of intracavitary placing, it has to be adapted to the estimated extent of the defect. Sponge changes take place usually twice a week depending on the patients' condition with a new adjustment of sponge size according to the wound defect.

In general, EVT is a safe and easy to use procedure. The most frequent adverse events mentioned in literature are dislocation of the sponge, bleeding, and anastomotic strictures; therefore, EVT should be avoided in patients with defects close to major vessels. Moreover, introduction of EVT near the upper esophageal sphincter may be challenging due to short distance to the glottis.⁵

Conclusion

EVT might be considered as a promising method of treatment in the early course of esophageal perforations and can be an alternative to surgery or stent insertion in these cases.

Conflict of Interest

None.

References

- 1 Palleschi GM, Cipollini EM, Lotti T. Development of oesophageal involvement in a subject with pemphigus vulgaris: a

- case report and review of the literature. *J Eur Acad Dermatol Venereol* 2002;16(4):405–408
- 2 Okamura A, Nakamura R, Yamagami J, et al. Evaluation of pharyngo-oesophageal involvement in pemphigus vulgaris and its correlation with disease activity. *Br J Dermatol* 2017;176(1):224–226
- 3 Loske G. Endoscopic negative pressure therapy of the upper gastrointestinal tract. *Chirurg* 2019;90(Suppl 1):1–6
- 4 Brangewitz M, Voigtländer T, Helfritz FA, et al. Endoscopic closure of esophageal intrathoracic leaks: stent versus endoscopic vacuum-assisted closure, a retrospective analysis. *Endoscopy* 2013;45(6):433–438
- 5 de Moura DTH, de Moura BFH, Manfredi MA, et al. Role of endoscopic vacuum therapy in the management of gastrointestinal transmural defects. *World J Gastrointest Endosc* 2019;11(5):329–344
- 6 Borstlap WAA, Musters GD, Stassen LPS, et al. Vacuum-assisted early transanal closure of leaking low colorectal anastomoses: the CLEAN study. *Surg Endosc* 2018;32(1):315–327
- 7 Weidenhagen R, Gruetzner KU, Wiecken T, Spelsberg F, Jauch K-W. Endoscopic vacuum-assisted closure of anastomotic leakage following anterior resection of the rectum: a new method. *Surg Endosc* 2008;22(8):1818–1825
- 8 Weidenhagen R, Hartl WH, Gruetzner KU, Eichhorn ME, Spelsberg F, Jauch KW. Anastomotic leakage after esophageal resection: new treatment options by endoluminal vacuum therapy. *Ann Thorac Surg* 2010;90(5):1674–1681
- 9 Schniewind B, Schafmayer C, Voehrs G, et al. Endoscopic endoluminal vacuum therapy is superior to other regimens in managing anastomotic leakage after esophagectomy: a comparative retrospective study. *Surg Endosc* 2013;27(10):3883–3890
- 10 Kuehn F, Loske G, Schifmann L, Gock M, Klar E. Endoscopic vacuum therapy for various defects of the upper gastrointestinal tract. *Surg Endosc* 2017;31(9):3449–3458
- 11 Rausa E, Asti E, Aiolfi A, Bianco F, Bonitta G, Bonavina L. Comparison of endoscopic vacuum therapy versus endoscopic stenting for esophageal leaks: systematic review and meta-analysis. *Dis Esophagus* 2018;31(11)
- 12 Mennigen R, Senninger N, Laukoetter MG. Novel treatment options for perforations of the upper gastrointestinal tract: endoscopic vacuum therapy and over-the-scope clips. *World J Gastroenterol* 2014;20(24):7767–7776
- 13 Loske G, Schorsch T, Dahm C, Martens E, Müller C. Iatrogenic perforation of esophagus successfully treated with endoscopic vacuum therapy (EVT) *Endosc Int Open* 2015;3(6):E547–E551
- 14 Heits N, Stapel L, Reichert B, et al. Endoscopic endoluminal vacuum therapy in esophageal perforation. *Ann Thorac Surg* 2014;97(3):1029–1035