



# Neonate Brain Abscess by *Cronobacter spp*: A Powdered Infant Formula's Opportunistic Pathogen

## *Abscesso cerebral neonatal por Cronobacter spp: Um patógeno oportunista de fórmula láctea infantil*

Bárbara Albuquerque Morais<sup>1</sup> Djalma Felipe Da Silva Menendez<sup>2</sup> Iuri Santana Neville Ribeiro<sup>2</sup>  
Cibeli Ribeiro Borsetto<sup>3</sup> Fernando De Sousa Nascimento<sup>3</sup> Manoel Jacobsen Teixeira<sup>2</sup>

<sup>1</sup> Department of Pediatric Neurosurgery, Universidade de São Paulo, São Paulo, SP, Brazil

<sup>2</sup> Department of Neurosurgery, Universidade de São Paulo, São Paulo, SP, Brazil

<sup>3</sup> Department of Pediatrics, Hospital e Maternidade Victoria, São Paulo, SP, Brazil

Address for correspondence Bárbara Albuquerque Morais, MD, Departamento de Neurocirurgia Pediátrica, Universidade de São Paulo, Rua Enéas de Carvalho, 155, Pinheiros, São Paulo, SP, 05409010, Brazil (e-mail: b.morais@hc.fm.usp.br).

Arq Bras Neurocir 2022;41(3):e245–e248.

### Abstract

*Cronobacter spp* is an opportunistic pathogen that can cause severe neonatal infections, including septicemia, meningitis, and necrotizing enterocolitis. Over 90% of these infections outbreaks are associated with the increased consumption of powdered infant formula (PIF). We report the case of a male neonate born at term with adequate weight for gestational age, fed by breast milk and PIF. He was admitted to the ICU at 22 days old due to fever, irritability, impaired consciousness, and food intolerance. Investigation revealed an extensive abscess in the right frontoparietal region, that was surgically drained. The culture of the purulent material showed the growth of *Cronobacter spp*. Guided antibiotic was kept for 21 days. The patient presented a good clinical outcome, without neurological deficits. The microbiological powdered formula contamination by *Enterobacter sakazakii* (*Cronobacter spp*) can lead to a higher risk of severe infections in infants. Children may present sepsis, sensory alteration, and refractory seizures. An early brain image should be considered for symptomatic infants. The mortality rate ranges from 40 to 80%, and 74% of survivors have an adverse neurological outcome. From 1997–2013, there were reports of 6 outbreaks of *E. sakazakii* disease in Brazil. According to the World Health Organization (WHO), this disease is undernotified, and active foodborne surveillance systems are less than ideal. To better address this problem, in some countries, the notification is mandatory, and the adoption of stricter sanitary measures by regulatory agencies are proposed.

### Keywords

- ▶ enterobacter sakazakii
- ▶ cronobacter spp.
- ▶ brain abscess
- ▶ powdered infant formula
- ▶ neonatal sepsis

### Resumo

O *Cronobacter spp* é um patógeno oportunista que pode causar infecções neonatais graves, incluindo septicemia, meningite e enterocolite necrosante. Mais de 90% dessas infecções estão associadas ao aumento do consumo de fórmula infantil em pó (FIP). Relatamos o caso

received  
December 20, 2019  
accepted  
July 7, 2020

DOI <https://doi.org/10.1055/s-0040-1716563>.  
ISSN 0103-5355.

© 2022. Sociedade Brasileira de Neurocirurgia. All rights reserved. This is an open access article published by Thieme under the terms of the Creative Commons Attribution-NonDerivative-NonCommercial-License, permitting copying and reproduction so long as the original work is given appropriate credit. Contents may not be used for commercial purposes, or adapted, remixed, transformed or built upon. (<https://creativecommons.org/licenses/by-nc-nd/4.0/>)  
Thieme Revinter Publicações Ltda., Rua do Matoso 170, Rio de Janeiro, RJ, CEP 20270-135, Brazil

**Palavras-chave**

- ▶ enterobacter sakazakii
- ▶ cronobacter spp.
- ▶ abscesso cerebral
- ▶ fórmula láctea infantil em pó
- ▶ sepse neonatal

de um recém-nascido do sexo masculino, nascido a termo, com peso adequado para a idade gestacional, alimentado com leite materno e FIP. Ele foi internado na UTI com 22 dias de idade devido a febre, irritabilidade, comprometimento da consciência e intolerância alimentar. A investigação revelou abscesso extenso na região frontoparietal direita, que foi drenada cirurgicamente. A cultura do material purulento mostrou o crescimento de *Cronobacter spp*. Antibiótico guiado foi mantido por 21 dias. O paciente apresentou bom resultado clínico, sem déficits neurológicos. A contaminação microbiológica da fórmula em pó pela *Enterobacter sakazakii* (*Cronobacter spp*) pode levar a um risco aumentado de infecções graves neonatais. As crianças podem apresentar sepse, alterações sensoriais e crise convulsiva refratária. Uma imagem cerebral precoce deve ser considerada nestes pacientes. A taxa de mortalidade varia de 40 a 80%, e 74% dos sobreviventes têm um quadro neurológico sequelar. Entre 1997 e 2013, houve relatos de 6 surtos de *E. sakazakii* no Brasil. De acordo com a Organização Mundial de Saúde (OMS), esta doença está subnotificada e os sistemas de vigilância alimentar são insuficientes. Para resolver esse problema, em alguns países, a notificação é obrigatória e a adoção de medidas sanitárias mais rigorosas é exigida pelas agências reguladoras.

**Introduction**

Nowadays, the use of powdered infant formula (PIF) as a substitute to feed newborns is increasingly frequent. Although breastfeeding is the primary recommendation for adequate infantile nutrition, it is not always possible. The PIF is easily accessible; nevertheless, issues with the production and distribution of the formula have been associated with a higher risk of its contamination, and therefore of life-threatening foodborne diseases in infants.<sup>1,2</sup>

The first documented case of neonatal meningitis by the *Cronobacter* (previously named *Enterobacter sakazakii*) was in 1958.<sup>3</sup> But it was only in 1987 that the association of this bacteria as an important contaminator of commercial powdered formula was identified and emphasized.<sup>4</sup>

After that, many outbreaks happened around the world, and this pathogen emerged as a serious public health issue for the government and industries.<sup>5-8</sup> Since then, the World Health Organization (WHO) has published guidelines and promoted international conferences to address this issue and propose solutions.<sup>7</sup> Alongside with that, industries have invested their budget in developing ways to detect and prevent the contamination. In Brazil, some cases of *Cronobacter* infections were reported from 1997 to 2017, in different states, but the data on these cases is limited.<sup>9,10</sup>

These gram-negative bacteria are well-known for causing necrotizing enterocolitis, neonatal sepsis, and meningitis. In the central nervous system, besides meningitis, it can result in abscess formation, ventricle dilatation, and infarcts.<sup>11</sup> In addition, *Cronobacter* meningitis is the main cause of lethality, ~42% of infected newborns.<sup>12</sup>

Here we report a case of a neonate fed by PIF that evolved with a *Cronobacter* abscess, to highlight this issue for the neurosurgery community.

**Case Report**

Neonate, male, born at term with adequate weight for gestational age. The child used PIF as a complement to breastfeed-

ing. He presented with fever and irritability when he was 22 days old and was admitted to the intensive care unit (ICU). The diagnosis of late-onset sepsis was established. He was treated with broad-spectrum antibiotics with an initial clinical improvement.

After 2 days, he presented again with fever, irritability, impaired consciousness, and food intolerance. Cerebrospinal fluid (CSF) analysis (▶ **Table 1**) revealed a neutrophilic pleocytosis consistent with meningitis. Further investigation with transcranial ultrasound (▶ **Fig. 1**) and brain magnetic resonance imaging (MRI) (▶ **Fig. 2**) revealed an extensive expansive lesion in the right fronto-parieto-occipital region suggestive of a brain abscess.

It was opted for surgical drainage and the material was sent to analysis. The culture of the purulent material (▶ **Fig. 3**) revealed the growth of *Cronobacter spp*. Guided antibiotic therapy was kept for 21 days, with ampicillin and gentamicin. The patient presented a good clinical outcome, without neurological deficits.

**Discussion**

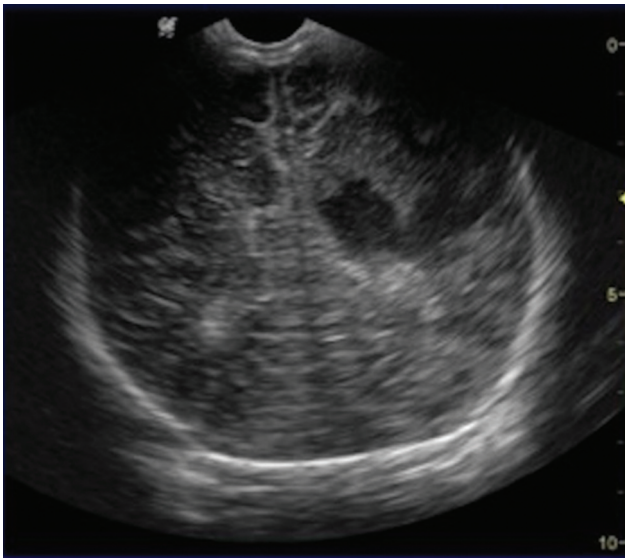
Formulas are well-accepted alternatives for infant feeding when breastmilk is insufficient. However, microbiological powdered formulae contamination by the *Cronobacter spp* (formerly *Enterobacter sakazakii*) leading to a higher risk of severe infections in infants constitutes a major health issue, already alerted by the WHO.<sup>7,9,11</sup>

Although infection by the *Cronobacter spp* can affect all ages,<sup>13</sup> the population at higher risk for invasive and

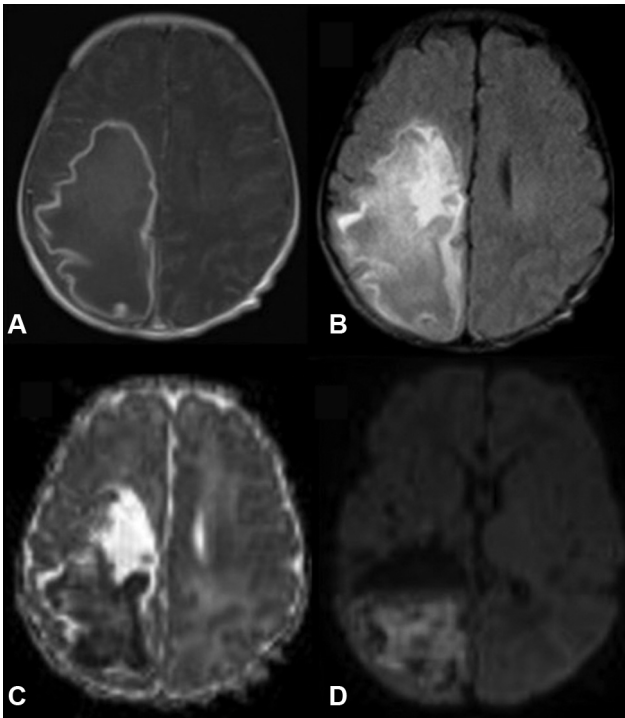
**Table 1** Cerebrospinal Fluid Results

WBC 2900/mm <sup>3</sup>	Neutrophils 70%
RBC 0/mm <sup>3</sup>	Lymphocytes 20%
Protein 200mg/dl	Lactate 64mg/dl
Glucose 10mg/dl	Culture negative

Abbreviations: RBC, red blood cells; WBC, white blood cells.

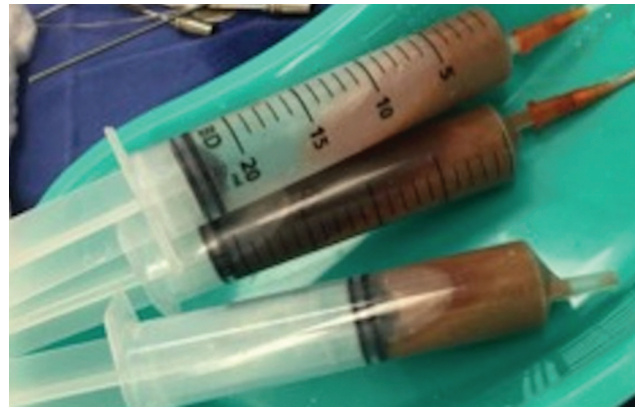

**Fig. 1** Transfontanellar ultrasound with a coronal view showing a hypoechoic area at the right cerebral hemisphere.



**Fig. 2** MRI axial view: A. T1-weighted gadolinium enhanced B. Fluid-attenuated inversion recovery (FLAIR) C. Apparent diffusion coefficient (ADC) D. Diffusion weighted imaging (DWI) revealing an extensive right fronto-parieto-occipital abscess.

life-threatening infections are low-birthweight infants, premature, immunodeficient and long-term hospitalizations.<sup>11,14</sup> These risk factors are supposed to be associated with an immature immune system and a low density of intestinal microflora predisposing the individual to more severe infections.<sup>15</sup> The pathogenesis of this infection is still poorly understood, nevertheless recently researchers proved the *C. sakazakii* can survive and multiply within the brain capillary endothelial cells in rats<sup>16</sup> and in human microglial



**Fig. 3** Macroscopic aspect of purulent material surgically drained.

cells, and also, translocate through the human brain microvascular endothelial cells.<sup>17,18</sup> This invasive process influences cytokine secretion and induces a severe brain inflammatory state.

Children may present typical signs of sepsis, sensory alteration, and refractory seizures. An early brain image should be considered for symptomatic infants. The mortality rate ranges from 40 to 80% of infected infants,<sup>14,19</sup> and 74% of survivors have an adverse neurological outcome.

From 1997 to 2013, there were reports of 6 outbreaks of *E. sakazakii* disease in Brazil. However, according to the WHO, this disease is underreported and active foodborne surveillance systems are less than ideal. To better address this problem in some countries, the notification is mandatory and the adoption of stricter sanitary measures by regulatory agencies are proposed.

Powdered infant formula is not sterile, and contamination by opportunistic pathogens is a health issue. The formula contamination can happen in any sequence of the process: during the production, at the micronutrients addition after the pasteurization, and during the preparation of the formula.<sup>20</sup>

Prevention campaign for the divulgation of Food and Agriculture Organization (FAO)/WHO guidelines for hospitals and parents regarding PIF preparation should be done, especially to the vulnerable population (infants < 2 months old). Alongside that, modern procedures associated with technological innovations have been implemented to the continuous surveillance of the production of the formula.<sup>21</sup>

## Conclusion

*Cronobacter* spp. is responsible for a severe infection of the central nervous system (CNS) of newborns. It frequently evolves to brain abscess and requires neurosurgical treatment. The main source for this infection is an infected infant powdered formula. It is crucial for the neurosurgeons, mostly the ones treating infants, to know the existence of this entity.

## Conflict of Interests

The authors have no conflict of interests to declare.

## References

- 1 Drudy D, Mullane NR, Quinn T, Wall PG, Fanning S. *Enterobacter sakazakii*: an emerging pathogen in powdered infant formula. *Clin Infect Dis* 2006;42(07):996–1002
- 2 Akineden Ö, Heinrich V, Gross M, Usleber E. Reassessment of *Cronobacter* spp. originally isolated as *Enterobacter sakazakii* from infant food. *Food Microbiol* 2017;65:44–50
- 3 Farmer JJ III. My 40-year history with *Cronobacter* / *Enterobacter sakazakii* – lessons learned, myths debunked, and recommendations. *Front Pediatr* 2015;3:84
- 4 Muytjens HL, Kollée LA. *Enterobacter sakazakii* meningitis in neonates: causative role of formula? *Pediatr Infect Dis J* 1990;9(05):372–373
- 5 Patrick ME, Mahon BE, Greene SA, et al. Incidence of *Cronobacter* spp. infections, United States, 2003–2009. *Emerg Infect Dis* 2014;20(09):1520–1523
- 6 Zeng H, Lei T, He W, et al. Novel Multidrug-Resistant *Cronobacter sakazakii* Causing Meningitis in Neonate, China, 2015. *Emerg Infect Dis* 2018;24(11):2121–2124
- 7 Food and Agriculture Organization of the United States. *Enterobacter sakazakii* (*Cronobacter* spp.) in powdered follow-up formulae. In: World Health Organization; 2008:1–27
- 8 Bar-Oz B, Preminger A, Peleg O, Block C, Arad I. *Enterobacter sakazakii* infection in the newborn. *Acta Paediatr* 2001;90(03):356–358
- 9 Brandao MLL, Umeda NS, De Filippis I. *Cronobacter* spp.: infections, occurrence and food regulations – a review in Brazil. *Braz J Food Technol* 2018;21:1–9
- 10 Chaves CEV, Brandão MLL, Lacerda MLGG, et al. Fatal *Cronobacter sakazakii* Sequence Type 494 Meningitis in a Newborn, Brazil. *Emerg Infect Dis* 2018;24(10):1948–1950
- 11 Hunter CJ, Petrosyan M, Ford HR, Prasadarao NV. *Enterobacter sakazakii*: an emerging pathogen in infants and neonates. *Surg Infect (Larchmt)* 2008;9(05):533–539
- 12 Friedemann M. Epidemiology of invasive neonatal *Cronobacter* (*Enterobacter sakazakii*) infections. *Eur J Clin Microbiol Infect Dis* 2009;28(11):1297–1304
- 13 Lai KK. *Enterobacter sakazakii* infections among neonates, infants, children, and adults. Case reports and a review of the literature. *Medicine (Baltimore)* 2001;80(02):113–122
- 14 Giovannini M, Verduci E, Ghisleni D, Salvatici E, Riva E, Agostoni C. *Enterobacter sakazakii*: an emerging problem in paediatric nutrition. *J Int Med Res* 2008;36(03):394–399
- 15 Holý O, Forsythe S. *Cronobacter* spp. as emerging causes of healthcare-associated infection. *J Hosp Infect* 2014;86(03):169–177
- 16 Townsend SM, Hurrell E, Gonzalez-Gomez I, et al. *Enterobacter sakazakii* invades brain capillary endothelial cells, persists in human macrophages influencing cytokine secretion and induces severe brain pathology in the neonatal rat. *Microbiology* 2007;153(Pt 10):3538–3547
- 17 Almajed FS, Forsythe SJ. *Cronobacter sakazakii* clinical isolates overcome host barriers and evade the immune response. *Microb Pathog* 2016;90:55–63. Doi: 10.1016/j.micpath.2015.11.014
- 18 Giri CP, Shima K, Tall BD, et al. *Cronobacter* spp. (previously *Enterobacter sakazakii*) invade and translocate across both cultured human intestinal epithelial cells and human brain microvascular endothelial cells. *Microb Pathog* 2012;52(02):140–147. Doi: 10.1016/j.micpath.2011.10.003
- 19 Bowen AB, Braden CR. Invasive *Enterobacter sakazakii* disease in infants. *Emerg Infect Dis* 2006;12(08):1185–1189
- 20 Rosas JC, Alberto C, Aldapa G, Vargas ER. *Cronobacter sakazakii*. 1980:1–45
- 21 Torres-Chavolla E, Ramírez-Cerda E, Gutiérrez-Rojo R. Isolation and identification of *Enterobacter sakazakii* in infant milk formulas. *Foodborne Pathog Dis* 2007;4(02):164–168