

Internal Fixation of a Complicated Mandibular Fracture in a Filly Using a String-of-Pearls Locking Plate Assisted by a 3D Printed Model

Sophie Boorman¹  Kara Lascola¹ Mariano Mora-Pereira¹ Serena Ceriotti¹ Lindsey Boone¹

¹Department of Clinical Sciences, Auburn University–College of Veterinary Medicine, JT Vaughan Large Animal Teaching Hospital, Auburn, Alabama, United States

Address for correspondence Lindsey Boone, DVM, PhD, DACVS-LA, Department of Clinical Sciences, Auburn University–College of Veterinary Medicine, JT Vaughan Large Animal Teaching Hospital, Auburn, Alabama, United States (e-mail: lhb0021@auburn.edu).

VCOT Open 2020;3:e90–e95.

Abstract

Objective The aim of this study was to describe the successful surgical treatment of a complicated mandibular fracture with a 3.5 mm string-of-pearls (SOP) locking plate in a 5-month-old Appaloosa filly presenting with neurological signs.

Study Design This is a case report.

Results The neurological signs were due to severe head trauma and stabilized with medical treatment. Financial concerns initially prevented advanced imaging; radiographs identified a mandibular symphysis fracture, a fracture of the left vertical ramus that originated at the junction between the horizontal and vertical ramus and extended toward the coronoid process and rostral maxillary fractures. Following intra-dental wiring of the symphysis fracture, a lateral malocclusion developed. Computed tomography additionally identified fractures of the right wing of the basisphenoid bone, right zygomatic arch, left paracondylar process and the lateral body of the mandible. The vertical ramus fracture was repaired utilizing a 20-hole 3.5 mm SOP plate contoured to the ventral aspect of the angle of the mandible. A scaled (1:4) three-dimensional printed model aided pre- and intra-operative surgical planning. The filly was comfortable and eating well at the 4-week recheck. Radiographs showed good callus formation at the maxilla, healing of the mandibular symphysis and ramus. Just prior to the 10-week recheck, the filly suffered severe enterocolitis and was euthanized.

Conclusion The locking function of the SOP plate provided adequate stability for the fracture to heal without the expense of locking screws. The three-dimensional printed model aided in navigation of the complex fracture without the availability of fluoroscopy.

Keywords

- ▶ CT
- ▶ fracture fixation
- ▶ locking plates

Introduction

Fractures of the equine vertical ramus of the mandible are rare.¹ Osteosynthesis with a compression plate is likely the most stable form of repair, enabling rapid return to mastication and amelioration of pain.^{2,3} This is despite the positioning of the plate on the compression surface of the mandible; though this is

biomechanically inferior, the tension surface is inaccessible as the approach would necessitate considerable disruption to the oral cavity and likely result in surgical site infection. Compression across the fracture line is seldom achieved as the bone in this area is very thin and the plate is utilized for immobilization alone. The locking compression plate (LCP) is the preferred construct.² *In vitro* testing indicates superior strength under

received
March 1, 2020
accepted after revision
July 25, 2020

DOI <https://doi.org/10.1055/s-0040-1716351>.
ISSN 2625-2325.

© 2020 Georg Thieme Verlag KG
Stuttgart · New York

License terms



cyclic loading⁴; the mandible is subjected to cyclic loading as the horse masticates; therefore, the strength afforded by the LCP is advantageous for successful fracture repair. Repair with an LCP does not require precise contouring of the plate to the fracture, which is advantageous in an area where the topography is complex.⁵ Finally, the LCP combi-hole can accept both cortical or locking-head screws, allowing the surgeon to utilize both the interfragmentary compression afforded by conventional compression plating and stability provided by the locking mechanism.⁶

There are some disadvantages to use of the LCP. Though absolute contouring to the bone surface is not necessary, significant bending is still required to match the plate to the steep angle of the mandible. *In vitro* experimentation has determined that contouring an angle greater than 10 degrees significantly reduces load to failure at the LCP screw–plate interface.^{7,8} If the bending disrupts the integrity of the plate thread in the plate hole, there is consequent loss of the locking function.⁹ If the surgeon over-estimates the angle and has to reverse bend the LCP, the resultant deformation of the constituent metal decreases the stiffness and strength of the implant and plate failure becomes more likely.^{10,11} Finally, but perhaps most fatefully, the use of multiple locking screws quickly becomes expensive and may deter owners from pursuing repair.

The string-of-pearls (SOP) implant is a locking plate system consisting of an alternating pattern of spherical plate holes (pearls) and a cylindrical internode.¹² The SOP can be contoured in three planes (medial to lateral, rostral to caudal and torsion) without loss of its locking capability or much of its stiffness, preserving its strength.^{9,12,13} The SOP plate sizes currently available (2.0 mm, 2.7 mm and 3.5 mm) have limited their use in weight-bearing fracture repair in the horse; however, in areas of decreased loading their multi-planar bending may offer a distinct advantage over the LCP. Notably, the SOP plate only accepts cortical bone screws while providing a locking function (the screws lock into the threaded pearls), sparing the expense of locking screws while maintaining the stability of a fixed-angle construct. The use of SOP plates to reconstruct the mandibular symphysis of a filly following rostral mandibulectomy has been reported¹⁴ however, there are no published accounts of their use in more complicated mandibular fractures.

The following case report describes the successful surgical treatment of a complicated mandibular fracture with a 3.5 mm SOP in a filly.

Case Report

A 5-month-old Appaloosa filly presented to the Vaughan Large Animal Teaching Hospital at the Auburn University College of Veterinary Medicine for neurological signs and a suspected mandibular fracture. Earlier that day, the filly was found recumbent in the stall demonstrating seizure-like activity. The owner speculated that the filly had been kicked by another horse. Once standing, the filly persistently circled and had a consistent head tilt. The filly presented to the hospital without referral by a primary care veterinarian.

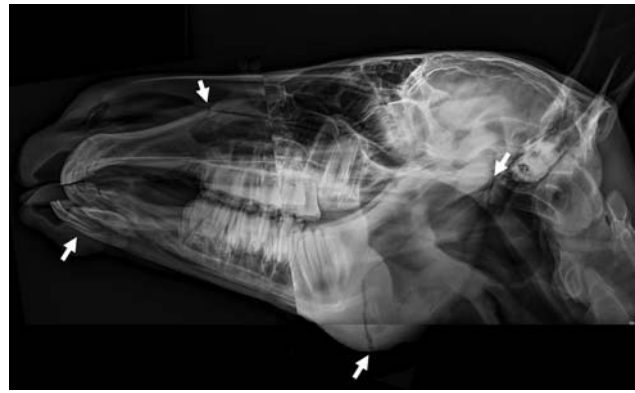


Fig. 1 Composite lateral radiograph several mandibular and maxillary fractures in a 5-month-old filly. From left to right, the white arrows indicate the mandibular symphyseal fracture, rostral maxillary fracture, cranioventral and caudal–ventral aspects of a displaced mandibular fracture.

On presentation, the filly was dull but responsive. She demonstrated consistent circling to the left throughout the examination. Examination revealed tachycardia (heart rate 80 beats per minute), tachypnoea (respiratory rate was 28 breaths per minute) and pyrexia (rectal temperature 39.2°C). There was significant swelling of the left mandible, with reduced airflow from the left nostril and a minor laceration to the lower lip. Brief oral examination identified a mandibular symphysis fracture. The filly had a significant head tilt, left ear drooping and ptosis of the left eye, suggestive of damage to the left facial and vestibulocochlear nerves. Haematology revealed a neutrophilia (7.7×10^3 cells/ μ L) and hyperfibrinogenaemia (600 mg/dL), serum biochemistry identified hypocalcaemia (calcium 9.0 mg/gL) and hypokalaemia (potassium 3.1 mmol/L).

Radiographic examination confirmed the presence of a unilateral symphysis fracture and identified a non-displaced fracture of the left vertical ramus, with a fracture line identified that appeared to extend to the temporomandibular joint (**► Fig. 1**). Bilateral rostral maxillary fractures were also identified at this time.

The filly was diagnosed with multiple skull fractures and resulting central nervous system disruption (facial nerve paralysis and vestibular syndrome). The filly was stabilized with intravenous (IV) fluid therapy (Lactated Ringer's solution, 120 mL/kg/day) and administered dimethyl sulfoxide (0.5 g/kg IV as 5% solution once), flunixin meglumine (1.1 mg/kg q.12 hours), dexamethasone (0.1 mg/kg IV q. 24 hours) in an attempt to reduce the significant swelling of the mandible. Antimicrobial therapy was initiated, due to the concern of a petrous temporal bone fracture and secondary meningitis (ceftiofur, 4.4 mg/kg IV q. 12 hours). Nutritional support in the form of IV glucose (2 mg/kg/minute), calcium (1.45 mEq/kg/day) and potassium (0.5 mEq/kg/hour) was provided, as the filly was unable to eat.

Over the subsequent 2 days, the filly improved significantly, the neurological signs resolved and she was able to eat soft grain mashes. Subsequently, the dexamethasone and IV fluids/nutrition were discontinued and she began prophylactic treatment with omeprazole (2 mg/kg per os q. 24 hours).

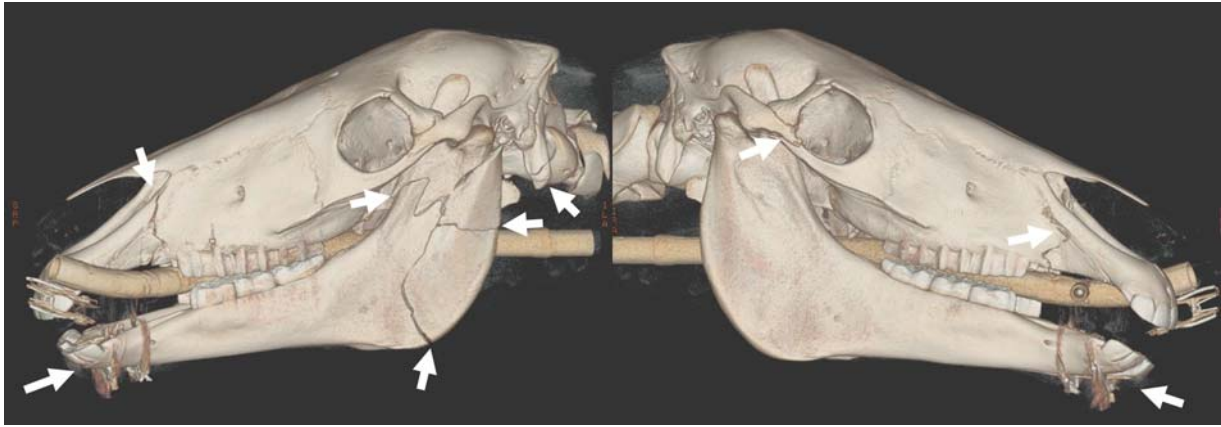


Fig. 2 Computed tomographic three-dimensional surface render of the skull. From left to right, the white arrows indicate the repaired mandibular symphyseal fracture, left maxilla fracture, comminution and displacement of the left mandibular fracture, left paracondylar process fracture, right zygomatic arch fracture, right maxilla fracture. Not pictured = left basisphenoid fracture.

Surgery to address the mandibular symphysis fracture was discussed with the owner. At this time, multiple fractures of the mandible and potentially of the temporohyoid joint were suspected, thus a computed tomographic (CT) examination of the skull was recommended. The examination was declined by the owner and intra-dental wiring of the symphysis fracture with cerclage wire and pin anchorage without prior advanced imaging was performed at day 4 of hospitalization. The repair was routine, but after recovery from general anaesthesia the filly's discomfort increased. A lateral malocclusion between the maxilla and the mandible was identified, further increasing suspicion of disruption to the temporomandibular joint or the presence of an unstable, comminuted mandibular fracture. At this time, the owner reconsidered the offer of a CT examination, and it was pursued under general anaesthesia.

The CT examination identified a fracture of the right wing of the basisphenoid bone, comminuted fracture of the left vertical ramus, minimally-displaced fractures of the left and right rostral maxilla, the right zygomatic arch and displaced fractures of the left paracondylar process, the lateral cortices of the mandible and the previously repaired symphysis

fracture (►**Fig. 2**). The temporomandibular joints appeared intact, thus the reason for the lateral malocclusion was determined to be the unstable fractures of the vertical ramus and the left paracondylar process. To further aid in the surgical planning of the repair, a scaled (1:4) three-dimensional (3D) printed model based on the CT reconstruction was made and was available during surgery (►**Fig. 3**).

The filly was administered flunixin meglumine (1.1 mg/kg IV), gentamicin (6.6 mg/kg IV) and potassium penicillin (22,000 IU/kg IV). For induction of general anaesthesia, the filly received xylazine (1 mg/kg IV), ketamine (2.2 mg/kg IV) and midazolam (0.04 mg/kg IV). General anaesthesia was maintained with isoflurane (minimum alveolar concentration 1.0). After induction of anaesthesia, the filly was positioned in right lateral recumbency and the left mandible and throat latch area were prepped and draped for surgery. To desensitize the right mandibular nerve, a 20 gauge 6" spinal needle was inserted at the medial aspect of the angle of the mandible and advanced to the approximate location of the mandibular foramen prior to deposition of 0.3 mg/kg 2% mepivacaine.

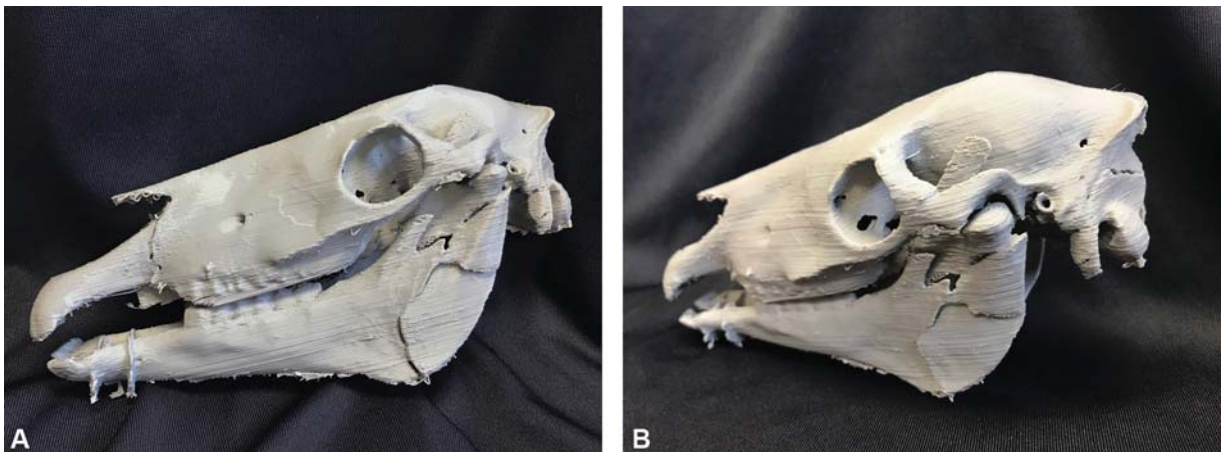


Fig. 3 (A) Three-dimensional (3D) model of the computed tomographic 3D surface render of the skull. The model was utilized pre- and intra-operative to aid in comprehension of the fracture, aid surgical planning, surgical resident training and for client education. (B) Close up of the 3D model highlighting the vertical ramus fracture.

A 20 cm curved incision was made over the caudal and ventral aspect of the mandible, from the mandibular condyle to ~1" caudal to the vascular notch of the horizontal ramus. Care was taken to avoid the parotid salivary duct. Elevation of the caudal ventral edge of the masseter provided good exposure of the multiple fracture lines without disruption of the periosteum. The fracture was reduced and bone reduction forceps positioned at the post rostral and caudal aspects of the fracture utilizing the printed model as a guide. A 20-hole 3.5 mm SOP plate was truncated to 18 holes, contoured and positioned along the caudal margin of the vertical ramus. The plate was secured using 3.5 mm self-tapping cortical bone screws. Intra-operative radiographs assisted screw placement, to prevent engagement of the dental tissues. The most dorsally located screw was angled to engage the paracondylar process. The extremely narrow width of the vertical ramus was the limiting factor in the number of screws used to secure the plate, with a total of 11 placed. The soft tissues were closed with 2–0 poliglecaprone 25 in a simple continuous pattern, the subcutaneous tissues with 2–0 poliglecaprone 25 in a continuous vertical mattress pattern and the skin with surgical staples. A sterile towel was secured to the mandible as a stent to provide compression and covered with an iodophor impregnated dressing (3M Ioban Antimicrobial Incise drape, 3M Healthcare, St. Paul, Minnesota, United States) to protect the incision during recovery. The intra-dental symphyseal cerclage wire was replaced, as repair of the mandible had disrupted the more rostral repair site. The filly was hand-recovered from general anaesthesia.

Postoperative radiographs showed appropriate positioning of the plate and good reduction of the mandibular fracture lines. The filly continued to receive flunixin meglumine, gentamicin and potassium penicillin for 3 days postoperatively. She was comfortable and able to eat soft mashes immediately after surgery and the previously noted malocclusion was resolved. Her heart rate, respiratory rate and rectal temperature were within normal limits. The filly was transitioned to oral antibiotic medications (trimethoprim-sulfamethoxazole, 30 mg/kg q. 12 hours for 10 days), and oral anti-inflammatories (flunixin meglumine, 1.1 mg/kg q. 24 hours for 5 days), and then discharged at day 5 postoperatively. There was mild swelling of the mandibular incision and a moderate amount of discharge was apparent at the symphysis repair site at the time of discharge. The owner was instructed to clean the rostral mandible once a day with a dilute chlorhexidine solution. The filly was confined to a stall and provided with soft mashes, picked grass and soaked hay with instructions not to allow grazing until a 4-week recheck of the maxilla fractures.

The surgical staples were removed by the referring veterinarian 2 weeks after surgery, at which time the mild swelling of the mandibular incision had resolved. The filly maintained an excellent appetite. The filly was re-presented at 4 weeks postoperatively and radiographic examination revealed callus formation at the previously identified maxilla fractures. The mandibular fractures appeared to be healing well (► Fig. 4). There was peripheral sclerosis and periosteal reaction of the rostral right mandible associated with the symphyseal wire, indicative of focal osteomyelitis (► Fig. 5).

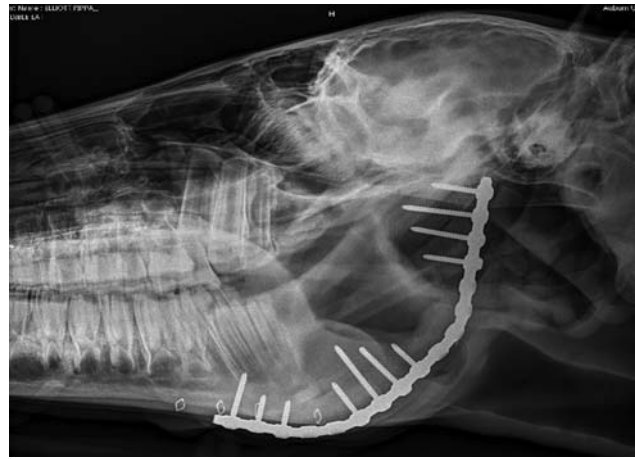


Fig. 4 Lateral radiograph of the caudal skull obtained 4 weeks postoperatively. The fracture is well reduced and healing appears appropriate.

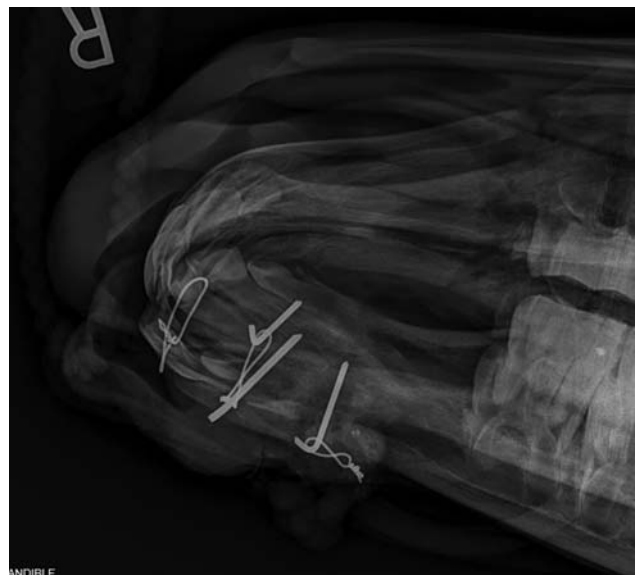

Fig. 5 Lateral ventral–medial dorsal oblique radiograph of the rostral skull 4 weeks postoperatively. There is abundant callus formation. The most caudal wire is associated with periosteal reaction, sclerosis and soft tissue proliferation.

The intra-dental wires were removed under standing sedation and the filly discharged.

Unfortunately, a few days prior to the scheduled 10-week recheck, the filly developed severe enterocolitis and was euthanized. She had been eating well, with no signs of discomfort prior to this. No necropsy was performed.

Discussion

Fractures of the equine skull are relatively common injuries¹⁵ however, fractures of the vertical ramus of the mandibula are comparatively rare.^{1,2,16} These injuries are invariably due to trauma. In this case, the filly was found in the stall with her injuries and it was unclear how they were sustained, though it was speculated that the filly had been kicked by another horse. Initially the filly was affected by neurological symptoms,

including depressed mentation and clinical signs of dysfunction of the facial and vestibulocochlear nerves. These two cranial nerves are intimately anatomically associated, coursing through the internal acoustic meatus of the temporal bone together before the facial nerve exits the skull at the stylomastoid foramen and the vestibulocochlear nerve remains within the inner ear.¹⁷ Dysfunction of both nerves, therefore, suggested a more central lesion such as a temporal bone fracture,^{18,19} rather than if she had presented with signs of peripheral facial nerve dysfunction, such as muzzle deviation, alone.²⁰ After CT eventually ruled out disruption to the temporohyoid articulation and the neurological signs resolved with anti-inflammatory medications and supportive care, it was deemed likely that the trauma sustained which had fractured the filly's skull had also caused a minor injury to her brain.²¹

Initially bilateral rostral maxillary fractures, fracture of the left mandibular ramus and the mandibular symphysis were the radiographically identified injuries. Since the mandibular symphysis fracture was unstable and prevented the filly from eating, it was repaired with intra-dental wiring.²² The instability due to the symphysis fracture prohibited determination of the instability of the vertical ramus fracture. Conservative management of fractures of the mandibular ramus is described and can be elected if the injury is stable or minimally dislocated, as they are adequately stabilized by the contralateral mandible and surrounding musculature.¹⁶ However, after the symphysis fracture was repaired, a severe lateral malocclusion and increase in the filly's discomfort raised suspicion that the ramus fracture was unstable or potentially extended into the temporomandibular joint. It is very likely that the manipulation necessary for the symphysis fracture repair further destabilized or distracted the ramus fracture. When an unstable and painful mandibular ramus fracture is diagnosed, surgical treatment is recommended.¹

The CT examination was performed to evaluate the filly's injuries more completely and to determine if there was disruption to the temporomandibular joint, which would have reduced the prognosis considerably.²³ The value of CT in pre-surgical planning in the repair of maxillofacial injuries is well established²⁴; the cranium is anatomically complex and the precise position and extent of fracture lines are difficult to infer from radiographs. However, even a reconstructed CT is a 2D representation of a 3D structure, which limits the complete understanding of spatial relationships and may impair decision making.²⁵ Recently, 3D printing has been utilized in small animal practice to aid in surgical planning for oral and maxillofacial surgery, as well as for enhancing resident training and for client education.²⁶ In this case, the availability of the 3D model during surgery helped the surgery team to fully appreciate the fracture margins and aided reduction without the need to pause the surgery to assess the CT. A 1:4 scaled model was utilized to cut back on production time; if a full size model had been produced, it would have had the added benefit of allowing for pre-contouring of the plate.

Techniques of surgical repair of the vertical ramus of the mandible described include external²⁷ and internal fixation, with internal fixation using an LCP considered ideal.^{1,2} However, the use of a LCP in this area is not without some important

limitations: considerable bending of the plate is required to match the angle of the mandible with subsequent weakening of the construct,⁷ if the surgeon accidentally bends the plate across the plate hole, the locking function is lost,⁹ if the plate is over-bent, any attempt at reverse bending likely further compromises the repair quality^{10,11} and the locking screws are expensive. The use of the SOP system in this case helped to overcome some of these limitations. The ability to more readily contour the SOP made alignment to the curvature of the mandible relatively simple, theoretically without loss of the stiffness or strength of the construct.⁹ Ness evaluated the mechanical consequences of contouring the SOP plate and found that they remained as stiff and as strong as uncountoured dynamic compression plates of the same size.⁹ Though each locking screw must be placed perfectly perpendicular to the SOP plate as with the LCP,²⁸ the unique ability of the SOP to angle each individual plate hole (pearl) means that each screw can be angled optimally to the bone. This was particularly useful where the mandible was narrowest and for avoidance of dental structures, although for these reasons some plate holes had to be left empty. Finally, the SOP plate requires regular cortical bone screws, which saves the considerable expense of locking screws and means the system can be added to the repertoire of the surgery suite without need for additional equipment.

This report details the partially successful repair of a complicated fracture of the vertical ramus of the mandible in a filly with an SOP plate. The ability to contour each plate hole in multiple directions may make the use of the SOP favourable to that of an LCP with regard to craniomaxillofacial fracture fixation and warrants further investigation.

Authors' Contributions

S. Boorman and L. Boone were responsible for study conception. All authors were responsible for study design, acquisition of data, data analysis and interpretation, revising of the manuscript and are publicly accountable for relevant content. All authors gave final approval of the submitted manuscript.

Conflict of Interest

None declared.

Acknowledgments

The authors thank the staff and veterinary students responsible for the care of this patient. Thanks are given to Dr. Jack Hamersky for the 3D printed model and to Dr. Daniel Weldon for his judicious postoperative care.

References

- 1 Fürst AE, Auer JA. Craniomaxillofacial disorders. In: Auer JA, Stick JA, ed. *Equine Surgery*. Fifth edition. Philadelphia: W.B. Saunders Co.; 2018:1794–1829
- 2 Kummerle JM, Kummer M, Auer JA, Nitzl D, Fürst AE. Locking compression plate osteosynthesis of complicated mandibular fractures in six horses. *Vet Comp Orthop Traumatol* 2009;22(01):54–58
- 3 Peavey CL, Edwards RB III, Escarcega AJ, Vanderby R Jr, Markel MD. Fixation technique influences the monotonic properties of equine mandibular fracture constructs. *Vet Surg* 2003;32(04):350–358

- 4 Gardner MJ, Brophy RH, Campbell D, et al. . The mechanical behavior of locking compression plates compared with dynamic compression plates in a cadaver radius model. *J Orthop Trauma* 2005;19(09):597–603
- 5 Levine DG, Richardson DW. Clinical use of the locking compression plate (LCP) in horses: a retrospective study of 31 cases (2004-2006). *Equine Vet J* 2007;39(05):401–406
- 6 Richardson DW. Application of the locking compression plate (LCP). In: Nixon AJ, ed. . *Equine Fracture Repair*. Second edition. Hoboken: John Wiley and Sons Inc.; 2019:156–162
- 7 Gallagher B, Silva MJ, Ricci WM. Effect of off-axis screw insertion, insertion torque, and plate contouring on locked screw strength. *J Orthop Trauma* 2014;28(07):427–432
- 8 Boulton CL, Kim H, Shah SB, et al. . Do locking screws work in plates bent at holes? *J Orthop Trauma* 2014;28(04):189–194
- 9 Ness MG. The effect of bending and twisting on the stiffness and strength of the 3.5 SOP implant. *Vet Comp Orthop Traumatol* 2009;22(02):132–136
- 10 DePuy Synthes. Small fragment locking compression plate (LCP) system surgical technique guide. West Chester, PA; 2013
- 11 Lin ASP, Fechter CM, Magill M, Wipf F, Moore T, Guldberg RE. The effect of contouring on fatigue resistance of three types of fracture fixation plates. *J Orthop Surg Res* 2016;11(01):107
- 12 Orthomed: SOP™ interlocking plate system. Standard Operating Procedure. West Yorkshire, UK; 2015
- 13 Rutherford S, Demianiuk RM, Benamou J, Beckett C, Ness MG, Déjardin LM. Effect of intramedullary rod diameter on a string of pearls plate-rod construct in mediolateral bending: an in vitro mechanical study. *Vet Surg* 2015;44(06):737–743
- 14 Ogden NKE, Jukic CC, Zedler ST. Management of an extensive equine juvenile ossifying fibroma by rostral mandibulectomy and reconstruction of the mandibular symphysis using string of pearls plates with cortical and cancellous bone autografts. *Vet Surg* 2019;48(01):105–111
- 15 Donati B, Fürst AE, Hässig M, Jackson MA. Epidemiology of fractures: the role of kick injuries in equine fractures. *Equine Vet J* 2018;50(05):580–586
- 16 Jansson N. Conservative management of unilateral fractures of the mandibular rami in horses. *Vet Surg* 2016;45(08):1063–1065
- 17 Gonçalves R, Malalana F, McConnell JF, Maddox T. Anatomical study of cranial nerve emergence and skull foramina in the horse using magnetic resonance imaging and computed tomography. *Vet Radiol Ultrasound* 2015;56(04):391–397
- 18 Tanner J, Spriet M, Espinosa-Mur P, Estell KE, Aleman M. The prevalence of temporal bone fractures is high in horses with severe temporohyoid osteoarthropathy. *Vet Radiol Ultrasound* 2019;60(02):159–166
- 19 Walker AM, Sellon DC, Cornelisse CJ, et al. . Temporohyoid osteoarthropathy in 33 horses (1993-2000). *J Vet Intern Med* 2002;16(06):697–703
- 20 Boorman S, Scherrer NM, Stefanovski D, Johnson AL. Facial nerve paralysis in 64 equids: clinical variables, diagnosis, and outcome. *J Vet Intern Med* 2020;34(03):1308–1320
- 21 Feary DJ, Magdesian KG, Aleman MA, Rhodes DM. Traumatic brain injury in horses: 34 cases (1994-2004). *J Am Vet Med Assoc* 2007;231(02):259–266
- 22 Rizk A, Hamed M. The use of cerclage wire for surgical repair of unilateral rostral mandibular fracture in horses. *Majallah-i Tahqiqat-i Dampizishki-i Iran* 2018;19(02):123–127
- 23 Devine DV, Moll HD, Bahr RJ. Fracture, luxation, and chronic septic arthritis of the temporomandibular joint in a juvenile horse. *J Vet Dent* 2005;22(02):96–99
- 24 Bar-Am Y, Pollard RE, Kass PH, Verstraete FJM. The diagnostic yield of conventional radiographs and computed tomography in dogs and cats with maxillofacial trauma. *Vet Surg* 2008;37(03):294–299
- 25 Chae MP, Rozen WM, McMenamin PG, Findlay MW, Spychal RT, Hunter-Smith DJ. Emerging applications of bedside 3D printing in plastic surgery. *Front Surg* 2015;2:25
- 26 Winer JN, Verstraete FJM, Cissell DD, Lucero S, Athanasiou KA, Arzi B. The application of 3-dimensional printing for preoperative planning in oral and maxillofacial surgery in dogs and cats. *Vet Surg* 2017;46(07):942–951
- 27 Belsito KA, Fischer AT. External skeletal fixation in the management of equine mandibular fractures: 16 cases (1988-1998). *Equine Vet J* 2001;33(02):176–183
- 28 Käab MJ, Frenk A, Schmeling A, Schaser K, Schütz M, Haas NP. Locked internal fixator: sensitivity of screw/plate stability to the correct insertion angle of the screw. *J Orthop Trauma* 2004;18(08):483–487