



Bone Integration and Prevalence of Radiolucent Lines around the Pegs of Minimally Cemented Glenoid Components in Total Shoulder Arthroplasty*

Integração óssea e prevalência de linhas radiotransparentes ao redor dos pinos de componentes glenoidais minimamente cimentados na artroplastia total de ombro

Márcio Schiefer^{1,2} Gláucio Siqueira² Alan Figueira² Patrícia Martins Souza³
Martim Teixeira Monteiro² Geraldo Motta Filho²

¹Department of Orthopedics, School of Medicine, Universidade Federal do Rio de Janeiro (UFRJ), Rio de Janeiro, RJ, Brazil

²Department of Orthopedics, Instituto Nacional de Ortopedia e Traumatologia (INTO), Rio de Janeiro, RJ, Brazil

³Department of Radiology, Instituto Nacional de Ortopedia e Traumatologia (INTO), Rio de Janeiro, RJ, Brazil

Address for correspondence Márcio Schiefer MD, MSc, PhD, Rua Nóbrega, 62, Apartamento 602, Niterói, RJ, 24220-320, Brazil (e-mail: marcioschiefer@hotmail.com).

Rev Bras Ortop 2022;57(1):120–127.

Abstract

Objectives Glenoid component failure is the main cause of total shoulder arthroplasty (TSA) revision, and component design seems to influence the failure rate. The aim of the present study was to clinically and radiographically (through X-rays and computed tomography scan) evaluate the results of TSA using a minimally cemented glenoid component.

Methods Total shoulder arthroplasties performed using the minimally cemented Anchor Peg (DuPuy Synthes, Warsaw, IN, USA) glenoid component between 2008 and 2013 were evaluated. University of California at Los Angeles (UCLA) scores were calculated, and standardized plain film and computed tomography images were obtained, at a minimum follow-up of 24 months. The presence of bone between the fins of the central component peg, which indicates its integration, was assessed on the images, as well the presence of radiolucent lines around the glenoid component.

Results Nineteen shoulders in 17 patients were available for evaluation. According to the UCLA score, clinical results were satisfactory in 74% of cases and fair in 21% of cases. One patient had a poor result. Component integration was found in 58% of patients (total in 42% and partial in 16%). Radiolucent lines were observed in 52% of cases. No relationship was detected between component integration and clinical results.

Keywords

- ▶ arthroplasty, replacement
- ▶ shoulder
- ▶ tomography
- ▶ radiography, digital
- ▶ prosthesis failure

* Research was conducted at Instituto Nacional de Traumatologia e Ortopedia (INTO), Rio de Janeiro, RJ, Brazil.

received
February 17, 2020
accepted
June 1, 2020
published online
September 25, 2020

DOI <https://doi.org/10.1055/s-0040-1715509>.
ISSN 0102-3616.

© 2020. Sociedade Brasileira de Ortopedia e Traumatologia. All rights reserved.

This is an open access article published by Thieme under the terms of the Creative Commons Attribution-NonDerivative-NonCommercial-License, permitting copying and reproduction so long as the original work is given appropriate credit. Contents may not be used for commercial purposes, or adapted, remixed, transformed or built upon. (<https://creativecommons.org/licenses/by-nc-nd/4.0/>)

Thieme Revinter Publicações Ltda., Rua do Matoso 170, Rio de Janeiro, RJ, CEP 20270-135, Brazil

Conclusion Satisfactory clinical results were achieved in most patients undergoing TSA using a minimally cemented glenoid component. Radiolucent lines around the glenoid component are common, but do not interfere with the clinical results.

Level of evidence IV; Case series. Treatment study.

Resumo

Objetivos A falha do componente glenoidal é a principal causa de revisão da artroplastia total do ombro (ATO) e sua frequência parece ser influenciada pelo *design* do componente. O objetivo deste estudo foi a avaliação clínica e radiográfica (através de raios X e tomografia computadorizada) dos resultados da ATO com componente glenoidal minimamente cimentado.

Métodos O presente trabalho analisou ATOs realizadas com componente glenoidal Anchor Peg (DuPuy Synthes, Warsaw, IN, EUA) minimamente cimentado entre 2008 e 2013. Por um período mínimo de acompanhamento de 24 meses, escores segundo critérios da *University of California at Los Angeles* (UCLA) e imagens padronizadas de radiografia simples e tomografia computadorizada foram analisadas. A presença de osso entre as aletas do pino do componente central, que é um indicador de sua integração, foi avaliada nas imagens, bem como a presença de linhas radiotransparentes ao redor do componente glenoidal.

Resultados Dezenove ombros de 17 pacientes foram avaliados. De acordo com o escore da UCLA, os resultados clínicos foram satisfatórios em 74% dos casos e moderados em 21% dos casos. O resultado foi ruim em um paciente. A integração de componentes foi observada em 58% dos pacientes, sendo total em 42% e parcial em 16% dos casos. Linhas radiotransparentes foram observadas em 52% dos pacientes. Nenhuma relação entre a integração de componentes e os resultados clínicos foi detectada.

Conclusão A maioria dos pacientes submetidos à ATO com componente glenoidal minimamente cimentado apresentou resultados clínicos satisfatórios. Linhas radiotransparentes ao redor do componente glenoidal são comuns, mas não interferem nos resultados clínicos

Nível de evidência IV; Série de caso; Estudo terapêutico.

Palavras-chave

- ▶ artroplastia de substituição
- ▶ ombro
- ▶ tomografia
- ▶ radiografia digital
- ▶ falha da prótese

Introduction

Shoulder arthroplasty is recognized as an efficient treatment for degenerative conditions of this joint, leading to satisfactory outcomes.¹⁻⁴ Consequently, the number of primary shoulder replacements has risen significantly.^{5,6} Forty-seven thousand shoulder arthroplasties were performed in 2008 in the USA, approximately two and a half times the 19,000 performed in 1998.⁶ Jain and Yamaguchi⁵ observed an increase in the number of primary shoulder replacements in the USA from 52,397 to 67,184 between 2009 and 2011. The most common indication was osteoarthritis.^{5,7}

Satisfactory results may be obtained with hemiarthroplasty and total shoulder arthroplasty (TSA),^{8,9} but the latter is associated with better outcomes in terms of general health, recovery of function, patient satisfaction, and pain relief.^{10,11} In addition, hemiarthroplasty is associated with a higher reoperation rate due to progressive erosion of the glenoid.¹⁰ Even so, TSA is not free of complications, and surgeons must concern themselves with glenoid component loosening, which is the most common cause of reoperation following this procedure.¹² Throckmorton et al.² found no clinical or radiological difference in the outcomes of TSA with the use of

pegged and keeled glenoid components, but most other studies have shown that the peg variant is associated with better radiological outcomes¹⁰ and lower reoperation rates.¹³ The medial surface of the glenoid component also deserves attention. Convex-backed implants have led to more favorable outcomes than have flat-backed components, and metal-backed components have been reported to increase the risk of complications from loosening and disconnection between the metallic base and the polyethylene surface.¹⁰

In 2001, Wirth et al.¹⁴ used a canine model to test a newly designed polyethylene glenoid component (Anchor Peg [DePuy Synthes; Warsaw, IN, USA]) composed of minimally cemented peripheral pegs surrounding a long central press-fit peg with radial flanges. The spaces between the central peg's flanges are filled with bone graft removed from the resected humeral head, promoting integration and interdigitation between the peg and the native bone.¹⁵ This form of fixation may be more effective and longer lasting, avoiding loosening and early TSA failure.¹⁴ Subsequent studies have shown encouraging results with this component design.^{3,15}

The objective of this study was to evaluate osteointegration between the strands of the central peg of the minimally cemented glenoid component using computed tomography

(CT) and roentgenograms. Secondary objectives were to identify the distribution of radiolucent areas and compare them with the obtained clinical results.

Materials and Methods

Patients, Study Design, and Ethical Considerations

Twenty-three patients underwent TSA using the Anchor Peg (DePuy Synthes) glenoid component between July 2008 and August 2013. This retrospective, transversal, and interventional study was devised between September 2014 and March 2015. After approval was obtained from the institution's ethics committee, 23 patients were contacted and summoned for clinical and radiographical evaluation. Six patients could not be reached (one was deceased, two could not be found, and three lived in other states). The sample, thus, comprised 19 shoulders in 17 patients (5 male and 12 female) with a mean age of 65 (range, 42–80) years.

The inclusion criteria were primary or secondary osteoarthritis, having performed TSA using an Anchor Peg Glenoid (DePuy Synthes), and minimum follow-up period of 24 months. Patients with associated rotator cuff tears and those undergoing hemiarthroplasty or receiving other models of shoulder prosthesis were excluded.

Surgical Technique

All patients were operated on under general anesthesia and a brachial plexus block while in the “beach chair” position. The affected upper limb was scrubbed and draped in a way that allowed free mobilization during surgery. The deltopectoral approach was used in all cases. Initially, the tendon of the long head of the biceps was identified, and tenodesis was performed by suture to the pectoralis major tendon. After subscapularis tendon peeling, the humeral head was exposed and osteotomized using an intramedullary guide. After preparation of the humeral diaphysis, the glenoid was exposed, and anterior, inferior, and superior capsulotomy was performed. Circumferential excision of the labrum aided identification of the exact limits of the articular rim. The center of the glenoid was then identified for the insertion of a guide wire and posterior drilling of the central hole (►Fig. 1A). A circular ream was then used to remove the cartilage, with care taken to avoid damage to the subchondral bone (►Fig. 1B). Eccentric reaming was performed in cases in which correction of the glenoid version was necessary, usually with the removal of more bone anteriorly than posteriorly. Using the appropriate guide, the three peripheral holes were drilled (►Fig. 1C). After adequate control of bleeding, bone cement was inserted into these holes using a syringe. Bone graft removed from the head was inserted between the flanges of the central peg of the polyethylene glenoid component (►Fig. 1D), which was then inserted (►Fig. 1E). Direct pressure was applied with a glenoid pusher to ensure the achievement of a perfect fit to the reamed glenoid surface. On the humeral side, the metallic cementless stem and head were then inserted into the reamed canal. The subscapularis tendon was then repaired with Orthocord transosseous non-absorbable sutures (DePuy Synthes).

Soft-tissue balance is then tested by performing stability tests and measuring anterior and posterior translation.

Clinical Evaluation

All patients underwent clinical evaluation, including an interview and specific physical examination of the shoulder. They were asked about eventual symptoms and the capacity to perform daily activities. Physical examination was performed to evaluate muscle trophism, active and passive ranges of motion, and strength. Shoulder function was classified according to the University of California at Los Angeles (UCLA) scale.¹⁶

Radiological Evaluation

Simple roentgenograms were taken in the anteroposterior, outlet, and axillary views. Computed tomography was performed in all patients as part of the institution's protocol using a Brilliance 64 scanner (Philips Medical Systems, Cleveland, OH, USA), with axial plane acquisitions with the patient in dorsal decubitus and 1 to 2-mm thick reconstruction in the sagittal and coronal planes.

Two observers (a radiologist with vast experience in the musculoskeletal field and a fellowship-trained shoulder and elbow surgeon, with more than ten years in practice) evaluated the images separately and reached consensus on the results recorded for each case. On both image types, the presence, location, and extension of radiolucent lines in the glenoid compartment was assessed, as suggested by Vidil et al.³ The spaces between the flanges of the central peg were examined to determine the presence of bone trabeculae suggesting ingrowth. An implant was considered to be totally integrated when bone trabeculae were found in all spaces (►Fig. 2), partially integrated when ingrowth was observed in only some spaces (►Fig. 3), and non-integrated when no trabecula was observed (►Fig. 4).

Statistical Analysis

The data was stored and analyzed with the SPSS Statistics for Windows 20.0. software (IBM Corp. Armonk, NY, USA). A Freeman-Halton extension of the Fisher exact test was applied to evaluate the distribution of radiolucent lines among the different areas of the glenoid component. And a Spearman test was used to identify correlations between the presence of these lines on radiologic exams and the clinical results measured mainly by the UCLA shoulder score.

Results

The data obtained in the present study are shown in ►Table 1. Osteointegration of the central peg was observed in 58% of cases; it was partial in 16% and total in 42% of cases. The remaining 42% of cases showed no osteointegration.

Radiolucent lines were found in 10 (52%) cases, in areas 4, 5, and 8 (►Table 1). Area 5, around the central peg, was the most common site of radiolucent lines ($p = 0.008$). The lines were longer than 1.5 mm in only one case. They were more common in cases without osteointegration of the central peg, although this difference was not significant.

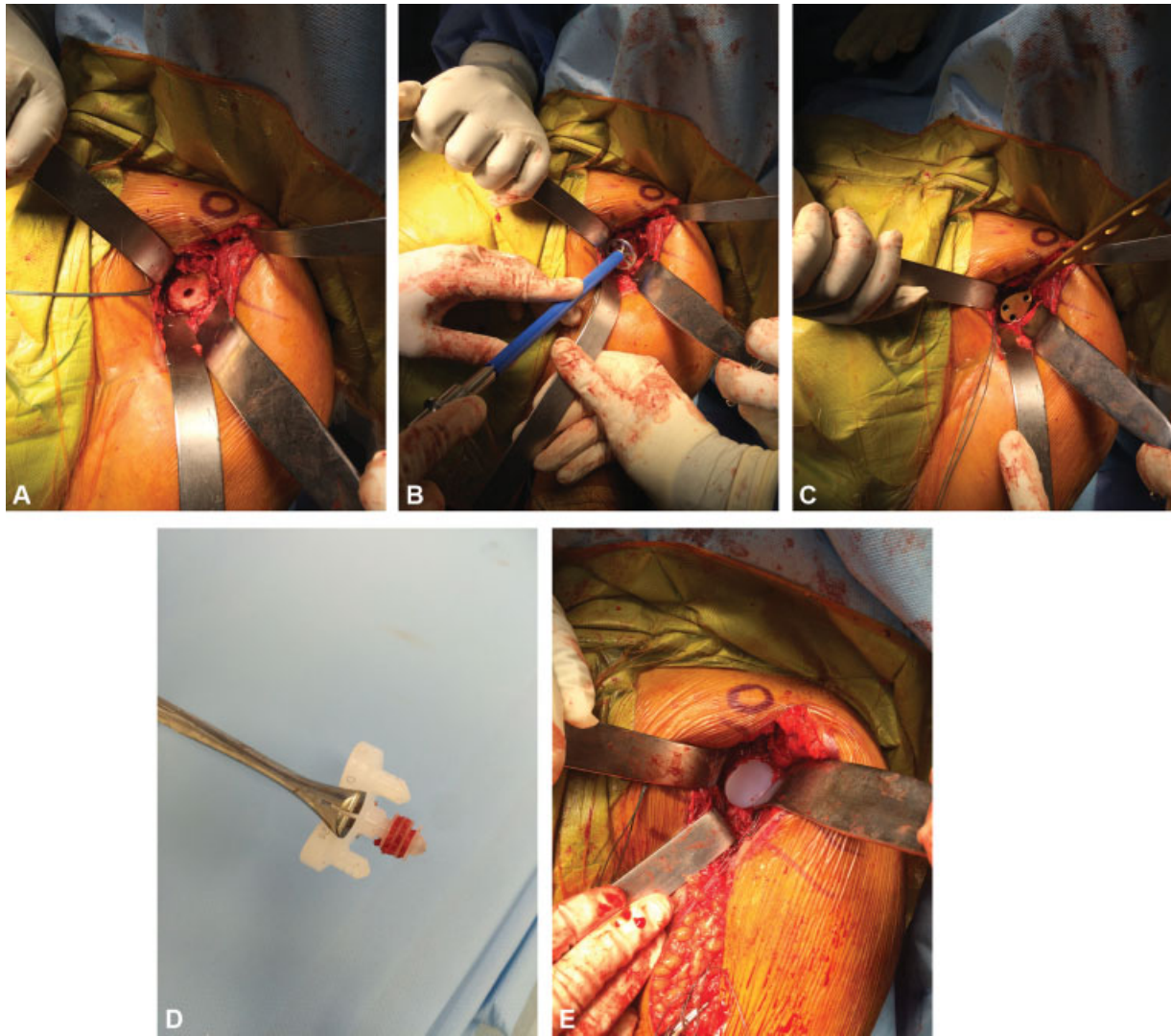


Fig. 1 Deltopectoral approach in a left shoulder showing: (A) glenoid central hole; (B) glenoid reaming; (C) positioning of the drilling guide to make peripheral holes; (D) autologous bone graft between central peg fins; (E) final aspect of implanted glenoid component.

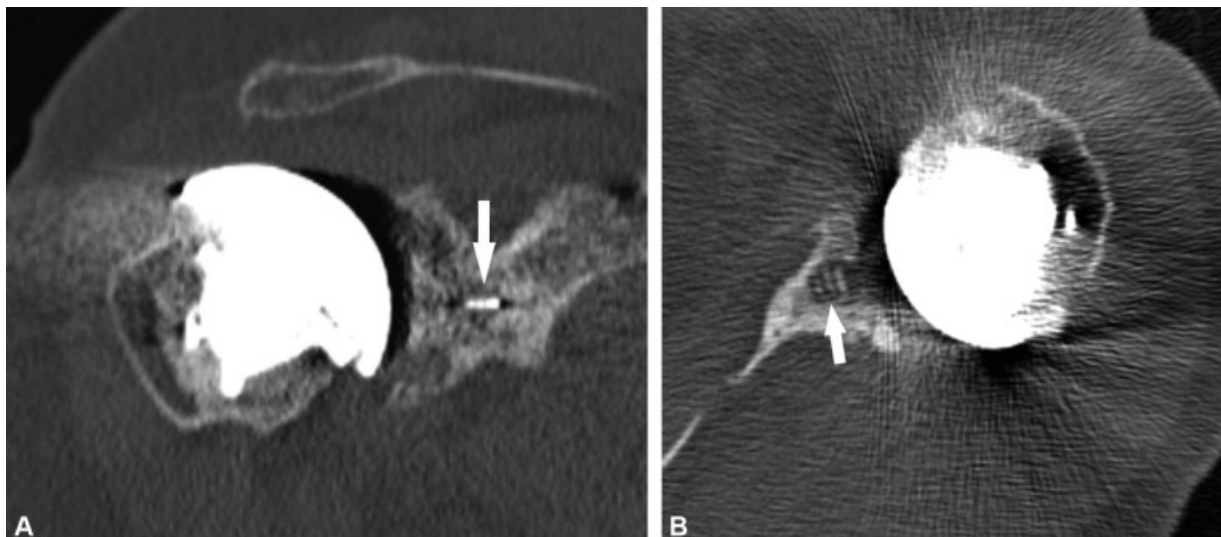


Fig. 2 Computed tomography images showing complete osteointegration of the central peg. Note the presence of bone in all spaces between the fins of the central peg (arrows), in coronal (A) and axial (B) views.

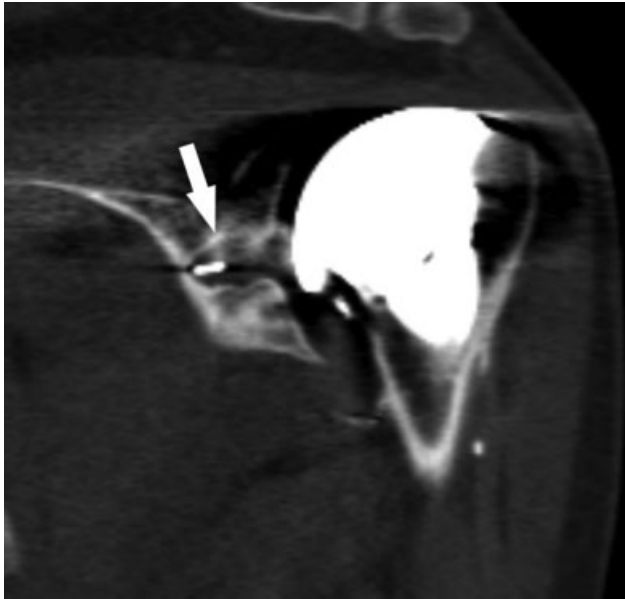


Fig. 3 Coronal computed tomography image of a left shoulder showing partial osteointegration of the central peg. Note the presence of bone in some spaces between the fins of the central peg (arrow).

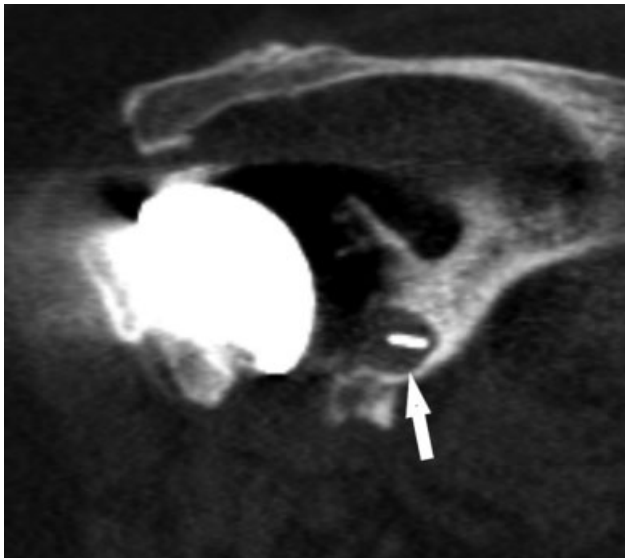


Fig. 4 Coronal computed tomography image of a right shoulder showing the absence of osteointegration of the central peg. No bone is seen between the fins of the central peg (arrow).

Seventy-nine percent of cases underwent surgery because of primary osteoarthritis, and 21% underwent surgery because of secondary osteoarthritis, all due to trauma sequelae. Three of these cases had closed fractures and one was caused by a firearm. No significant association was found between fracture etiology and the presence of radiolucent lines, although radiolucent lines were absent in the four cases of secondary osteoarthritis.

According to the UCLA functional scale,¹⁶ the results were satisfactory in 73.69% of cases, regular in 21%, and poor in one (5.3%) case (–Table 2). No correlation was found between age, the duration of symptoms before surgery, or the

presence of osteointegration or radiolucent lines and the clinical results according to the UCLA scale (–Table 3). During the follow-up period, no patient presented any complication, related or unrelated to the surgery.

Discussion

Although humeral component survival rates remain high,¹ problems with the glenoid, many of which are difficult to solve, remain the main cause for revision TSA.^{10,17} Bonneville et al.¹⁸ demonstrated a high rate of loosening recurrence after revision TSA. In search of a more durable design, Wirth et al.¹⁴ tested a new glenoid component composed of a central and three peripheral pegs in dogs. Only the peripheral pegs are cemented; the central peg is inserted under pressure, in the attempt to avoid the deleterious effects of cement on the glenoid bone stock¹⁹ and increase fixation to the native bone, as the spaces between the central peg's flanges allow bony ingrowth.

Few studies analyzed the osteointegration of the Anchor Peg glenoid component in patients who have undergone TSA. Although ~ 33,000 of these components have been implanted worldwide since 2011,¹⁵ few studies have reported on the outcomes obtained. This fact corroborates the fact that only 5% of all shoulder arthroplasties are the object of scientific publication.⁷

The radiographic results described in studies of the cementless finned, central pegged glenoid component and other component designs are heterogeneous, with radiolucent lines reported in 0 to 94% of cases.²⁰ In a simple roentgenogram study of patients who received Anchor Peg components, Churchill et al.²¹ reported osteointegration in 85% of cases and a 25% incidence of radiolucent lines. In contrast, Groh²² reported osteointegration in 24 of 83 (29%) patients in another simple roentgenogram study. Arnold et al.²³ assessed CT images, as in the present study, and reported osteointegration in 23 of 35 (65%) cases and radiolucent lines in 11 (31%) cases. Wirth et al.¹⁵ evaluated the presence of radiolucent lines around the glenoid component on simple roentgenograms and reported an incidence of 68% (30 of 44 cases). Vidil et al.³ reported the presence of osteointegration in 21 of 26 (80%) operated cases, based on CT assessment. Wijeratna et al.²⁴ reported osteointegration in 68 out of 83 shoulders with the Anchor Peg glenoid and 78 patients had no radiolucent lines in CT scans. Kilian et al.¹⁷ and Merolla et al.²⁵ reported lower rates of bone ingrowth, 25% and 23%, respectively. Progressive radiolucency lines were seen in 28 out of 30 glenoid components in the latter. In our study, osteointegration was observed in 11 of 19 (58%) patients; this rate is average among the previous studies.

We believe that the variation in the reported incidence of radiolucent lines is due to several factors. Some studies involved the assessment of roentgenograms only,^{15,21,22} whereas others used CT images.^{3,23} Even among studies employing the same radiological method, different evaluation protocols may have been used. The susceptibility of imaging studies of the glenoid component to errors, especially when simple roentgenograms are assessed, is well documented;

Table 1 Overall results

Patient	Sex	Age (years)	Dominant limb	OA etiology	Follow-up (months)	OI	RL	Vidil zone of RL	UCLA score
1	M	73	No	Primary	57	Absent	Y	5	34
2	F	75	No	Primary	46	Complete	N	0	29
3	F	78	No	Primary	13	Complete	Y	5	32
4	F	76	Yes	Primary	45	Partial	Y	5	32
5	F	80	Yes	Primary	14	Complete	N	0	22
6	M	42	Yes	Primary	16	Partial	Y	5	25
7	F	59	Yes	Primary	12	Absent	N	0	33
8	F	59	No	Primary	48	Complete	N	0	34
9	F	58	No	Secondary	27	Complete	N	0	25
10	F	64	No	Primary	55	Absent	N	0	28
11	F	73	Yes	Primary	68	Absent	Y	8	28
12	F	70	Yes	Primary	27	Complete	N	0	30
13	F	70	No	Primary	48	Absent	Y	5	31
14	F	59	Yes	Primary	53	Absent	Y	5	32
15	M	51	No	Secondary	55	Complete	Y	4	17
16	F	77	Yes	Primary	71	Absent	Y	5	32
17	M	60	No	Secondary	35	Partial	N	0	32
18	F	67	Yes	Secondary	17	Complete	N	0	28
19	M	53	Yes	Primary	19	Absent	Y	5	27

Abbreviations: F, female; L, left; M, male; N, no; OA, osteoarthritis; OI, osteointegration; R, right; RL, radiolucent lines; UCLA, University of California at Los Angeles; Y, yes.

Table 2 Distribution of UCLA scores

UCLA score	Number of patients (%)
Excellent (34–35)	2 (10.53)
Good (28–33)	12 (63.16)
Fair (21–27)	4 (21.05)
Poor (< 20)	1 (5.26)

Abbreviation: UCLA, University of California at Los Angeles.

Table 3 Correlations among patient age, follow-up duration, and UCLA score (n = 19)

		Follow-up duration	UCLA score
Age	r	0.093	0.266
	p	0.704	0.272
Follow-up duration	r		0.163
	p		0.506

Abbreviation: UCLA, University of California at Los Angeles.

interpretation based on CT images is more accurate.^{24,26,27} Another important factor is the duration of follow-up, as the prevalence of radiolucent lines is known to increase with time.¹⁵ Finally, a single experienced surgeon performed all operations in some, but not all, studies. Lazarus et al.²⁰ reported better radiological results of glenoid component

implantation performed by the most experienced surgeon, and this factor could contribute to the discrepancy among reports. The influence of the cementation technique on the incidence of radiolucent lines around the glenoid component has been described.^{28,29} Thus, the application of a better cementation technique, usually by a more experienced surgeon, could prevent the appearance of these radiolucent signs. This factor may partially explain the absence of radiolucent lines in cases of secondary osteoarthritis in this study, although these cases are technically more demanding and adequate glenoid component positioning is more difficult to obtain than in cases of primary osteoarthritis. The senior surgeons at our institution performed these surgeries, a factor that we believe explains these results.

The exact implication of the presence of radiolucent lines around the glenoid component is not known. They occur in up to 94% of cases,²⁰ and their presence seems to have no effect on the clinical results.^{1,21,24,25} In this study, we found no influence of this variable on the UCLA score. In addition, the definition of component loosening varies significantly among studies.^{1,20,30} Most authors have considered the thickness of a radiolucent line and its extension along different regions of the component. In the present study, no patient fulfilled any criteria for component loosening. Only one patient presented a radiolucent line longer than 1.5 mm, which was located exclusively around the central peg. According to the UCLA scale, a good clinical result was

obtained in this patient. Our study revealed poor correlation between clinical and radiographic findings, although a longer follow-up period may be necessary. Age, duration of symptoms, presence of osteointegration and radiolucent lines did not influence the clinical results. Similar findings were reported by Wijeratna et al.²⁴ However, a recent study showed that patients whose glenoid components had radiolucent lines demonstrated lower improvements of forward elevation and all patient-reported outcomes.³¹

Although the absence of osteointegration has not been proven to have clinical consequence,²⁴ the achievement of osteointegration in all patients is considered to be desirable. Using radiostereometric analysis, Nuttal et al.³² evaluated the movement of the Anchor Peg glenoid component in 11 patients who underwent TSA. They divided the subjects into two groups according to the results: one group presented early component movement and no osteointegration at the 12-month follow-up evaluation, and the other group demonstrated no movement and evolved with osteointegration. Merolla et al.²⁵ showed that patients who had bone ingrowth to the central peg were less likely to have radiolucent lines. However, as also occurred in the present study, Churchill et al.²¹ and Arnold et al.²³ found no relationship between osteointegration and clinical results, as measured by the Constant scale and simple shoulder test.

Although the present study has its strengths, it has several limitations. First, our sample was small, due in part to the strict and careful selection of patients for TSA at our institution, as well as the exclusion of procedures performed with other types of glenoid component. Another reason for the small sample is related to the worldwide trend toward the reduction of the ratio of anatomic to reverse shoulder arthroplasties performed,⁵ which is reflected significantly at our institution. Another limitation is that postoperative roentgenograms and CT images were not readily available for all patients, preventing us from identifying all patients who presented radiolucent lines immediately after surgery, which would reflect an inadequate implantation of glenoid component.

To our knowledge, the present study is the first conducted in our country to compare clinical and radiographic results of patients who underwent TSA with the Anchor Peg Glenoid component. The use of CT images permitted more accurate analysis of osteointegration on the central peg, and identification of radiolucent lines. Another advantage was that surgeries were performed by surgeons with different levels of expertise. We believe that this factor favors reproducibility, in contrast to results obtained in other series, in which the most experienced surgeon of the group operated on all patients.^{15,23} In addition, the same researcher evaluated all patients, reducing measurement bias. Finally, consensual analysis of the images by two professionals, one of whom was a radiologist with extensive experience in the musculoskeletal field, was a strong aspect of the study. We agree with Arnold et al.²³ that inter and intraobserver agreement evaluation is not needed, as Yian et al.³³ demonstrated excellent agreement rates in their study, especially with the use of CT.

Conclusion

Although central peg osteointegration was observed in slightly more than half of the cases, satisfactory clinical results were obtained in most patients who underwent TSA with a minimally cemented pegged glenoid component. Radiolucent lines around the glenoid component were also common but were not correlated with the clinical results.

Conflict of Interests

The authors declare that there is no conflict of interests.

References

- 1 Raiss P, Schmitt M, Bruckner T, et al. Results of cemented total shoulder replacement with a minimum follow-up of ten years. *J Bone Joint Surg Am* 2012;94(23):e1711–e10
- 2 Throckmorton TW, Zarkadas PC, Sperling JW, Cofield RH. Pegged versus keeled glenoid components in total shoulder arthroplasty. *J Shoulder Elbow Surg* 2010;19(05):726–733
- 3 Vidil A, Valenti P, Guichoux F, Barthas JH. CT scan evaluation of glenoid component fixation: a prospective study of 27 minimally cemented shoulder arthroplasties. *Eur J Orthop Surg Traumatol* 2013;23(05):521–525
- 4 De Wilde L, Dayerizadeh N, De Neve F, Basamania C, Van Tongel A. Fully uncemented glenoid component in total shoulder arthroplasty. *J Shoulder Elbow Surg* 2013;22(10):e1–e7
- 5 Jain NB, Yamaguchi K. The contribution of reverse shoulder arthroplasty to utilization of primary shoulder arthroplasty. *J Shoulder Elbow Surg* 2014;23(12):1905–1912
- 6 Kim SH, Wise BL, Zhang Y, Szabo RM. Increasing incidence of shoulder arthroplasty in the United States. *J Bone Joint Surg Am* 2011;93(24):2249–2254
- 7 Motta Filho G, Galvão MV, Monteiro M, Cohen M, Brandão B. Registro de artroplastias do ombro. *Rev Bras Ortop* 2009;44(02):125–133
- 8 Gadea F, Alami G, Pape G, Boileau P, Favard L. Shoulder hemiarthroplasty: outcomes and long-term survival analysis according to etiology. *Orthop Traumatol Surg Res* 2012;98(06):659–665
- 9 Sperling JW, Cofield RH, Rowland CM. Minimum fifteen-year follow-up of Neer hemiarthroplasty and total shoulder arthroplasty in patients aged fifty years or younger. *J Shoulder Elbow Surg* 2004;13(06):604–613
- 10 Boileau P, Sinnerton RJ, Chuinard C, Walch G. Arthroplasty of the shoulder. *J Bone Joint Surg Br* 2006;88(05):562–575
- 11 Bryant D, Litchfield R, Sandow M, Gartsman GM, Guyatt G, Kirkley A. A comparison of pain, strength, range of motion, and functional outcomes after hemiarthroplasty and total shoulder arthroplasty in patients with osteoarthritis of the shoulder. A systematic review and meta-analysis. *J Bone Joint Surg Am* 2005;87(09):1947–1956
- 12 Matsen FA 3rd, Clinton J, Lynch J, Bertelsen A, Richardson ML. Glenoid component failure in total shoulder arthroplasty. *J Bone Joint Surg Am* 2008;90(04):885–896
- 13 Vavken P, Sadoghi P, von Keudell A, Rosso C, Valderrabano V, Müller AM. Rates of radiolucency and loosening after total shoulder arthroplasty with pegged or keeled glenoid components. *J Bone Joint Surg Am* 2013;95(03):215–221
- 14 Wirth MA, Korvick DL, Basamania CJ, Toro F, Aufdemorte TB, Rockwood CA Jr. Radiologic, mechanical, and histologic evaluation of 2 glenoid prosthesis designs in a canine model. *J Shoulder Elbow Surg* 2001;10(02):140–148
- 15 Wirth MA, Loredi R, Garcia G, Rockwood CA Jr, Southworth C, Iannotti JP. Total shoulder arthroplasty with an all-polyethylene pegged bone-ingrowth glenoid component: a clinical and radiographic outcome study. *J Bone Joint Surg Am* 2012;94(03):260–267

- 16 Amstutz HC, Sew Hoy AL, Clarke IC. UCLA anatomic total shoulder arthroplasty. *Clin Orthop Relat Res* 1981;(155):7–20
- 17 Kilian CM, Morris BJ, Sochacki KR, et al. Radiographic comparison of finned, cementless central pegged glenoid component and conventional cemented pegged glenoid component in total shoulder arthroplasty: a prospective randomized study. *J Shoulder Elbow Surg* 2018;27(6S):S10–S16
- 18 Bonneville N, Melis B, Neyton L, et al. Aseptic glenoid loosening or failure in total shoulder arthroplasty: revision with glenoid reimplantation. *J Shoulder Elbow Surg* 2013;22(06):745–751
- 19 Churchill RS, Boorman RS, Fehring EV, Matsen FA III. Glenoid cementing may generate sufficient heat to endanger the surrounding bone. *Clin Orthop Relat Res* 2004;(419):76–79
- 20 Lazarus MD, Jensen KL, Southworth C, Matsen FA III. The radiographic evaluation of keeled and pegged glenoid component insertion. *J Bone Joint Surg Am* 2002;84(07):1174–1182
- 21 Churchill RS, Zellmer C, Zimmers HJ, Ruggero R. Clinical and radiographic analysis of a partially cemented glenoid implant: five-year minimum follow-up. *J Shoulder Elbow Surg* 2010;19(07):1091–1097
- 22 Groh GI. Survival and radiographic analysis of a glenoid component with a cementless fluted central peg. *J Shoulder Elbow Surg* 2010;19(08):1265–1268
- 23 Arnold RM, High RR, Grosshans KT, Walker CW, Fehring EV. Bone presence between the central peg's radial fins of a partially cemented pegged all poly glenoid component suggest few radiolucencies. *J Shoulder Elbow Surg* 2011;20(02):315–321
- 24 Wijeratna M, Taylor DM, Lee S, Hoy G, Evans MC. Clinical and radiographic results of an all-polyethylene pegged bone-ingrowth glenoid component. *J Bone Joint Surg Am* 2016;98(13):1090–1096
- 25 Merolla G, Ciaramella G, Fabbri E, Walch G, Paladini P, Porcellini G. Total shoulder replacement using a bone ingrowth central peg polyethylene glenoid component: a prospective clinical and computed tomography study with short- to mid-term follow-up. *Int Orthop* 2016;40(11):2355–2363
- 26 Gregory T, Hansen U, Khanna M, et al. A CT scan protocol for the detection of radiographic loosening of the glenoid component after total shoulder arthroplasty. *Acta Orthop* 2014;85(01):91–96
- 27 Hoenecke HR Jr, Hermida JC, Flores-Hernandez C, D'Lima DD. Accuracy of CT-based measurements of glenoid version for total shoulder arthroplasty. *J Shoulder Elbow Surg* 2010;19(02):166–171
- 28 Barwood S, Setter KJ, Blaine TA, Bigliani LU. The incidence of early radiolucencies about a pegged glenoid component using cement pressurization. *J Shoulder Elbow Surg* 2008;17(05):703–708
- 29 Choi T, Horodyski M, Struk AM, Sahajpal DT, Wright TW. Incidence of early radiolucent lines after glenoid component insertion for total shoulder arthroplasty: a radiographic study comparing pressurized and unpressurized cementing techniques. *J Shoulder Elbow Surg* 2013;22(03):403–408
- 30 Sperling JW, Cofield RH, O'Driscoll SW, Torchia ME, Rowland CM. Radiographic assessment of ingrowth total shoulder arthroplasty. *J Shoulder Elbow Surg* 2000;9(06):507–513
- 31 Schoch BS, Wright TW, Zuckerman JD, et al. Glenoid component lucencies are associated with poorer patient-reported outcomes following anatomic shoulder arthroplasty. *J Shoulder Elbow Surg* 2019;28(10):1956–1963
- 32 Nuttall D, Haines JF, Trail IA. The early migration of a partially cemented fluted pegged glenoid component using radiostereometric analysis. *J Shoulder Elbow Surg* 2012;21(09):1191–1196
- 33 Yian EH, Werner CML, Nyffeler RW, et al. Radiographic and computed tomography analysis of cemented pegged polyethylene glenoid components in total shoulder replacement. *J Bone Joint Surg Am* 2005;87(09):1928–1936