



# Evaluation of Biceps Tenotomy or Tenodesis on Fatty Infiltration of the Biceps Muscle

## *Avaliação da tenotomia ou tenodese bicapital na infiltração gordurosa do músculo bíceps*

Jair Simmer Filho<sup>1</sup>  Paulo Henrique Schmidt Lara<sup>2</sup>  Juarez Leite Júnior<sup>3</sup> Paulo Santoro Belangero<sup>2</sup>   
Benno Ejnisman<sup>2</sup> 

<sup>1</sup> Department of Orthopedics and Traumatology, Hospital Estadual de Urgência e Emergência, Vitória, ES, Brazil

<sup>2</sup> Centro de Traumatologia do Esporte, Escola Paulista de Medicina, Universidade Federal de São Paulo, São Paulo, SP, Brazil

<sup>3</sup> Department of Radiology, Multiscan Diagnóstico, Vitória, ES, Brazil

Rev Bras Ortop 2021;56(4):497–503.

Address for correspondence Paulo Henrique Schmidt Lara, MD, Rua Estado de Israel, 636, Vila Clementino, São Paulo, SP, 04022-001, Brazil (e-mail: phslara@gmail.com).

### Abstract

**Objective** The objective of the present study was to determine whether there is fatty infiltration (FI) of the biceps brachii muscle mass after tenotomy or tenodesis for the treatment of tendon injuries in the long head of the biceps and to establish a relationship between FI with changes in the length of muscle fibers.

**Methods** Clinical and imaging analysis of 2 groups of patients (biceps tenodesis [16 patients] and biceps tenotomy [15 patients]). In both groups, we compared the findings on the contralateral side of each patient (control group). All patients had undergone unilateral biceps tenodesis or tenotomy, with postoperative follow-up of > 1 year. Magnetic resonance imaging (MRI) was performed on both arms of each patient following a specific protocol. Strength of elbow flexion was measured with a manual dynamometer, and the results were subjected to statistical analysis.

**Results** The mean postoperative period before the MRI was 5 years, and no case of FI was observed in the anterior compartment of either arm of the evaluated patients. Seven patients had moderate or severe deformity in the operated arm. We found no significant relationship between arm deformity ( $p = 0.077$ ), flexion strength percentage ( $p = 0.07$ ) or pain on palpation of the bicipital groove ( $p = 0.103$ ).

**Conclusion** None of the evaluated patients had evidence of FI in the muscle mass of the anterior arm compartment after the procedures. It was not possible to establish a correlation between the discrepancy of the biceps muscle length measured by MRI and the presence of FI in the anterior compartment of the arm.

### Keywords

- ▶ biceps
- ▶ rotator cuff
- ▶ tenodesis
- ▶ tenotomy

\* The present work was developed at the Centro de Traumatologia do Esporte da Escola Paulista de Medicina, Universidade Federal de São Paulo, São Paulo, SP, Brazil.

received

December 1, 2019

accepted

June 1, 2020

published online

September 25, 2020

DOI <https://doi.org/>

10.1055/s-0040-1714231.

ISSN 0102-3616.

© 2020. Sociedade Brasileira de Ortopedia e Traumatologia. All rights reserved.

This is an open access article published by Thieme under the terms of the Creative Commons Attribution-NonDerivative-NonCommercial-License, permitting copying and reproduction so long as the original work is given appropriate credit. Contents may not be used for commercial purposes, or adapted, remixed, transformed or built upon. (<https://creativecommons.org/licenses/by-nc-nd/4.0/>)

Thieme Revinter Publicações Ltda., Rua do Matoso 170, Rio de Janeiro, RJ, CEP 20270-135, Brazil

**Resumo**

**Objetivo** O objetivo do presente estudo foi determinar a existência de infiltração gordurosa (IG) na massa muscular do bíceps braquial após a tenotomia ou tenodese para tratamento de lesão no tendão da cabeça longa do bíceps e estabelecer uma relação entre a IG e alterações no comprimento das fibras musculares.

**Métodos** Análise clínica e de imagens de 2 grupos de pacientes (submetidos à tenodese do bíceps [16 indivíduos] ou tenotomia do bíceps [15 indivíduos]). Nos dois grupos, os achados foram comparados àqueles do lado contralateral de cada indivíduo (grupo controle). Todos os pacientes foram submetidos à tenodese ou tenotomia unilateral do bíceps, com acompanhamento pós-operatório > 1 ano. Exames de ressonância magnética (RM) foram realizados em ambos os braços de cada paciente de acordo com um protocolo específico. A força de flexão do cotovelo foi medida com dinamômetro manual e os resultados foram submetidos à análise estatística.

**Resultados** O período pós-operatório médio antes da realização da RM foi de 5 anos, e nenhum caso de IG foi observado no compartimento anterior de ambos os braços dos pacientes avaliados. Sete pacientes apresentaram deformidade moderada ou grave no braço operado. Não houve relação significativa entre deformidade do braço ( $p = 0,077$ ), percentual de força de flexão ( $p = 0,07$ ) ou dor à palpação do sulco bicipital ( $p = 0,103$ ).

**Conclusão** Nenhum dos pacientes avaliados apresentou evidência de IG na massa muscular do compartimento anterior do braço após os procedimentos. Não foi possível estabelecer uma correlação entre a discrepância do comprimento do músculo bíceps, medido à RM, e a presença de IG no compartimento anterior do braço.

**Palavras-chave**

- ▶ bíceps
- ▶ manguito rotador
- ▶ tenodese
- ▶ tenotomia

**Introduction**

When the long head of the biceps tendon (LHBT) is ruptured or subjected to tenotomy or tenodesis, retraction of the muscle belly may result in changes in the strength and/or aesthetics of the arm.<sup>1</sup> However, the amount of retraction that is able of causing clinical repercussions is still not well-defined. Muscle atrophy, interstitial fibrosis and fatty infiltration (FI) are frequently associated with chronic rotator cuff injuries. These irreversible structural changes favor the loss of muscle strength and elasticity and are major obstacles to the success of surgical repair of muscles such as the subscapularis, supraspinatus and infraspinatus muscles.<sup>2</sup> Although often studied, it is not well-established whether chronic shortening of the biceps muscle mass can cause a change in the muscle belly similar to that caused by FI in the belly of the rotator cuff muscles in cases of chronic and retracted ruptures.<sup>3,4</sup>

In the mid-1900s, the LHBT was seen as the main source of shoulder pain, and treatment of that pain focused on tenotomy and tenodesis.<sup>5-7</sup> Currently, these procedures for the treatment of LHBT-related injuries are widely performed during shoulder arthroscopies.<sup>8,9</sup> There is no clear consensus regarding the best surgical treatment for LHBT injuries.<sup>10</sup> There is also no consistent method to ensure that appropriate biceps tension has been restored postoperatively.<sup>11</sup>

Our objective was to determine whether FI is present in the muscle of the biceps brachii after the treatment of LHBT injuries (tenodesis or tenotomy) and to establish a

relationship between this possible FI with changes in muscle fiber length, the presence of deformities and strength.

**Materials and Methods**

This was an observational, cross-sectional, case-control study consisting of the clinical and imaging analysis of two groups: one composed of patients undergoing biceps tenodesis in the bicipital groove with an interference screw and another composed of patients undergoing biceps tenotomy. Patients were randomly separated according to sealed envelopes that were opened before each surgery. In both groups, a comparison was made with the findings on the contralateral side of each patient (control group).

The present study was submitted to the ethics committee under the number CAAE 92179218.8.0000.5505, and all patients included in the study signed an informed consent form.

**Patient Selection**

The patients were selected based on a simple search of the medical records in the private clinic of the investigator. The inclusion criteria were: agreeing and signing the informed consent form, having undergone unilateral biceps tenotomy or tenodesis, and postoperative follow-up of > 1 year.

The exclusion criteria were the presence of rotator cuff or LHBT injury evidenced during the study.

A total of 34 patients agreed to participate in the study. There were 17 patients from the tenodesis group and 17 patients from the tenotomy group. Of these 34 patients, 3

were excluded from the study after the MRI exam (2 in the tenotomy group and 1 in the tenodesis group) because they had clinical and radiological signs of rotator cuff injury (RCI) in the contralateral shoulder, with complaint of arm pain and loss of elbow flexion strength. After exclusions, 16 patients from the tenodesis group and 15 patients from the tenotomy group were evaluated, totaling 31 patients (31 operated arms and 31 contralateral arms for control). All patients had undergone surgery for RCI treatment as the main diagnosis.

### Magnetic resonance imaging

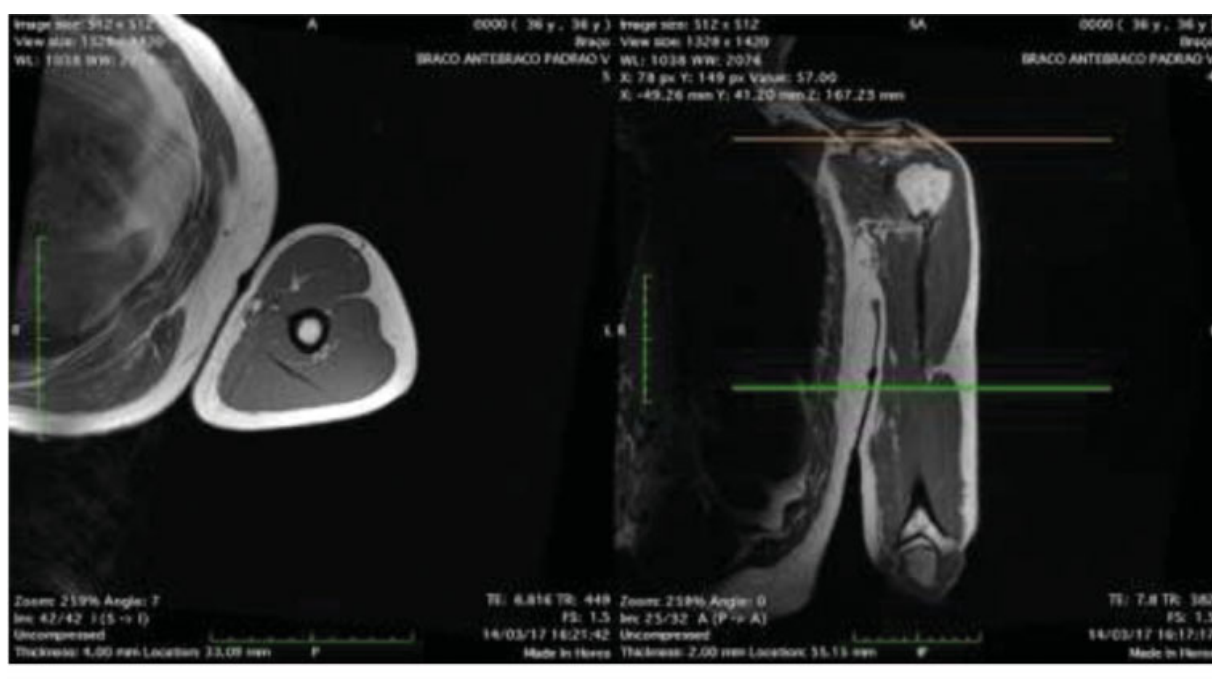
The MRI exams were all performed using a 1.5 Tesla GE Brivo 355 (General Electric, Boston, MA, USA). All patients were imaged in the supine position, with the arms positioned along the body in neutral rotation. T1-weighted coronal and axial images were obtained of both arms of each patient following a specific protocol. The T1-weighted coronal sequences were aligned with the body of the scapula with 3-mm spacing. This sequence identified the apex of the humeral head and the length of the studied humerus, and then half of the length was calculated. A double sequence of T1-weighted axial slices was started from the lower edge of the acromion, with the first sequence with 25 slices at a spacing of 3 mm followed by a second sequence with 35 more slices at a spacing of 4 mm. With this sequence, from a triangulation with the images of the coronal slices, it was possible to evaluate, with the thinner slices (3 mm), the distance between the apex of the humeral head and the first muscle fiber of the long portion of the biceps at the musculotendinous junction (AH-MTJ); that distance was compared with the contralateral side, resulting in the difference in AH-MTJ distance (► Fig. 1). In the group of patients subjected to

tenodesis, we also assessed the distance between the apex of the humeral head and the interference screw (AH-IS).

Individualizing the muscle belly of the long and short heads of the biceps and separating them from the other muscles of the anterior compartment of the arm cannot be done with MRI, as previously reported.<sup>3,4</sup> For this reason, we comparatively investigated the presence or absence of FI in the muscle mass of the anterior compartment of the arm using the T1-weighted axial section performed as close as possible to half the length of the humerus in both groups. We adapted the existing FI classification,<sup>12</sup> comparing both arms of each patient. This classification suggests 5 FI grades (grade 0: normal; grade 1: some fatty streaks present; grade 2: < 50% FI; grade 3: 50% FI; grade 4: > 50% FI),<sup>13</sup> and although this classification is not validated for use with MRI images of the biceps, it was used for this purpose in a recent study.<sup>4</sup> The images were evaluated by an experienced radiologist, trained in the musculoskeletal system and with 15 years of clinical practice.

### Clinical Evaluation

The presence of arm deformities was classified as suggested by Scheibel et al.<sup>14</sup> as none, mild, moderate and severe; to facilitate statistical analysis, we subdivided the presence of deformities into 2 groups: satisfactory (none or mild) and unsatisfactory (moderate or severe) (► Figs. 2 and 3). Elbow flexion strength was measured with a manual dynamometer (Fabrication Enterprises, White Plains, New York, USA) (Baseline Mechanical Spring Push/Pull Dynamometer-60 Pounds) in both arms of each patient. Pain on palpation of the bicipital groove was evaluated by the examiner by finger compression 5 cm distal to the anterolateral corner of the acromion with the arm in neutral rotation.



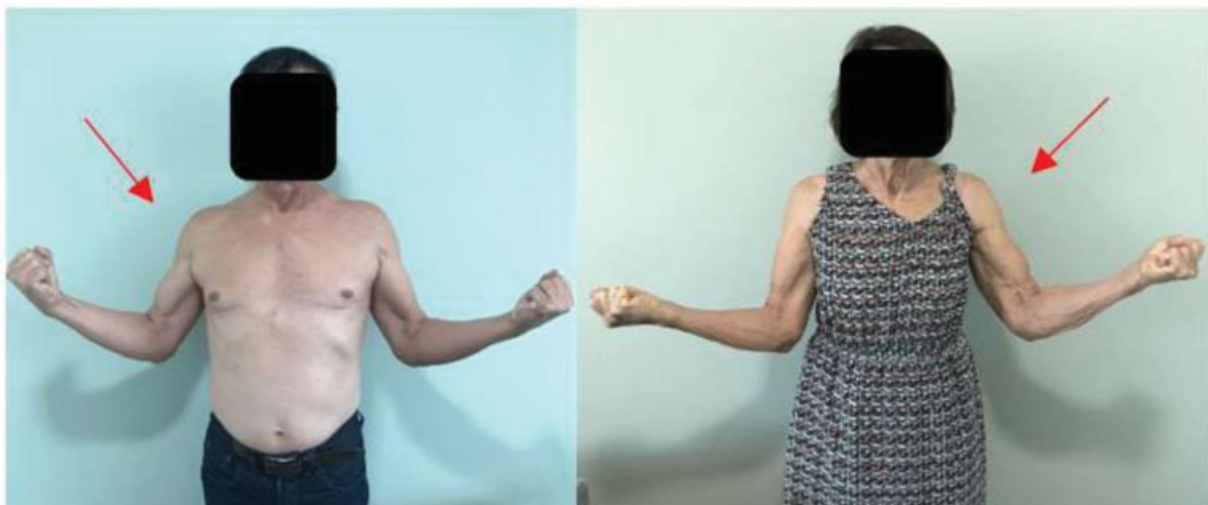Source: Author's archive.

**Fig. 1** Distance between the apex of the humeral head and the first muscle fiber of the long portion of the biceps at the musculotendinous junction.



Source: Author's archive.

**Fig. 2** Satisfactory deformity.



Source: Author's archive.

**Fig. 3** Unsatisfactory deformity.

### Statistical Analysis

A descriptive analysis of the variables was performed by constructing box plots and calculating the mean, standard error, standard deviation (SD), variance, coefficient of variation, minimum, 1st quartile, median, 3rd quartile and maximum for all study variables.

Due to the small sample size, the Fisher exact test was used to determine independence between pairs of variables. When the assumptions of a normal distribution of the mean were not met for the two samples or when one of the samples was very small (size equal to two or three), the nonparametric Mann-Whitney test of equality of means was employed for the two groups. If one of the sample sizes was smaller than four, the Mann-Whitney test for the difference of means may not be valid because very small sample sizes are not conducive to rejecting the tested hypothesis.

We calculated the respective descriptive levels (*p-value*) for all the hypothesis tests performed and rejected the hypotheses with descriptive levels lower than the level of significance

adopted, which was equal to 0.05. Data analysis was performed using Minitab v.18 (Minitab, LLC., State College, PA, USA).

### Results

For the 31 patients evaluated, the mean postoperative period at the time the MRI exam was performed was 5 years: 5.8 years (range, 2 to 11 years) for the tenotomy group and 4.2 years (range, 1 to 9 years) for the tenodesis group. The mean age of the participants was 60 years old (53 to 77 years old) for the tenotomy group and 50.8 years old (33 to 69 years old) for the tenodesis group (–Table 1).

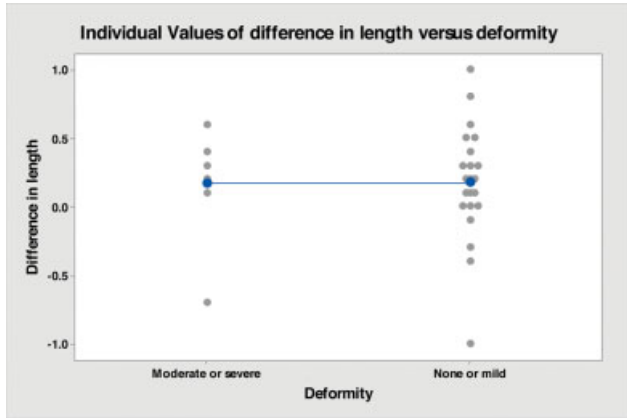
### Arm Deformity

Among all individuals studied, 7 had unsatisfactory (moderate or severe) deformities in the operated arm. The difference in AH-MTJ distance ranged from - 0.6 cm to 3.1 cm (mean of 0.34 cm). We found no significant relationship between satisfactory deformities and the difference in AH-MTJ distance

**Table 1** Sample characteristics

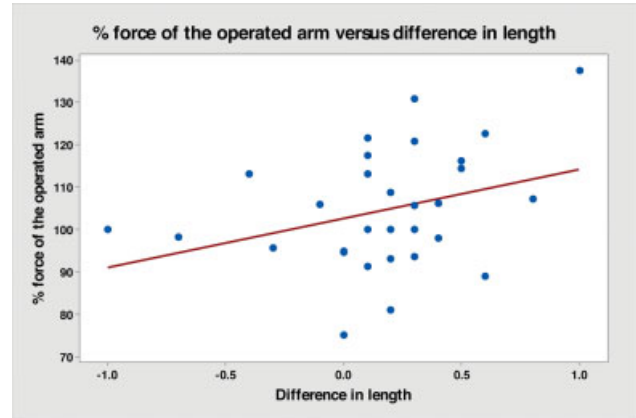
Group	Number of patients	Mean postoperative period	Indication for surgery	Mean age at surgery	Average Distance	Men	Women
Tenotomy	15	5.8 years (2–5 years)	Rotator cuff injury	63 years (53–77 years)	5	3 (20%)	12 (80%)
Tenodesis	16	4.2 years (1–9 years)	Rotator cuff injury	50.8 years (33–69 years)	1	15 (93.5%)	1 (6.5%)

Source: Prepared by the author.



Source: Prepared by the author.

**Fig. 4** Individual values of difference in length versus deformity.



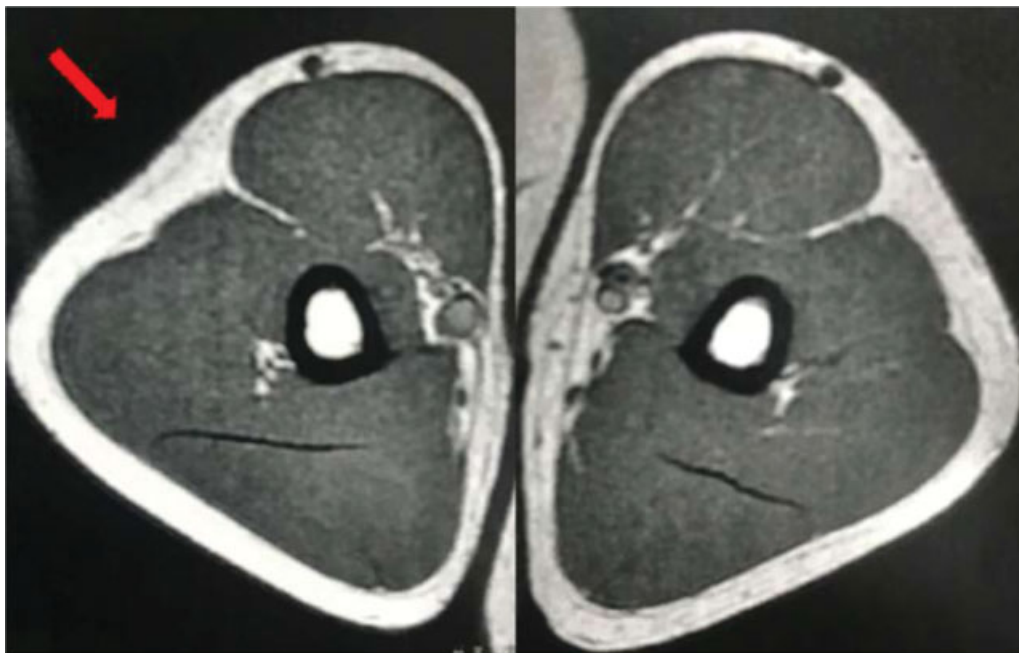
Source: Author's archive.

**Fig. 6** Percent force of the operated arm versus difference in length.

( $p = 0.124$ ) or between the incidence of unsatisfactory deformities and the difference in AH-MTJ distance ( $p = 0.077$ ). The means of the differences in the AH-MTJ distance were similar for patients who presented satisfactory (0.175 cm) and unsatisfactory (0.171 cm) deformities ( $p = 0.984$ ). Both had normal distribution (► **Fig. 4**).

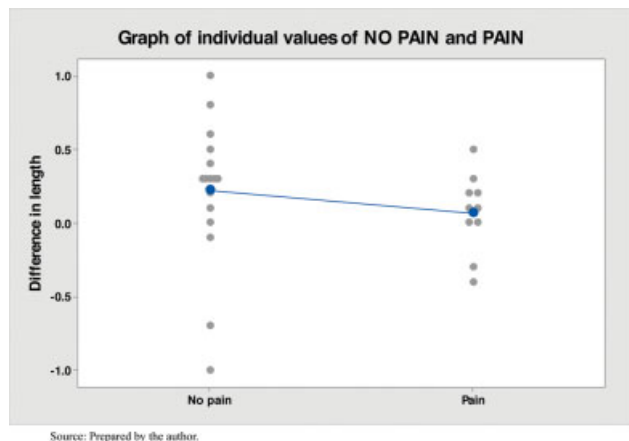
**Fatty Infiltration**

No patient in either group exhibited changes in muscle mass of the anterior compartment of the arm, and no case of FI was evident in the T1-weighted axial section at the level of half the total length of the arm. All cases were classified as grade 0. (► **Fig. 5**).



**Fig. 5** Fatty infiltration.





**Fig. 7** Graph of individual values of no pain and pain.

### Flexion Strength

The percent flexion strength of the operated arms did not follow a linear relationship with the difference in AH-MTJ distance ( $p = 0.070$ ) (► **Fig. 6**). There was no difference in the mean percent strength between the groups ( $p = 0.399$ ): 106.7% (range, 92.86 to 137.57%) in the tenodesis group and 102.4% (range, 75 to 130.77%) in the tenotomy group. Both groups presented a normal distribution.

### Pain on Palpation of the Intertubercular Groove

We did not find a significant relationship between pain on palpation of the bicipital groove and the difference in AH-MTJ distance ( $p = 0.103$ ) (► **Fig. 7**). There was no significant correlation between the incidence of pain in the bicipital groove and the mean percent elbow flexion strength of the operated arm ( $p = 0.062$ ).

## Discussion

We found no evidence of FI in the muscle mass of the anterior compartment of the arms subjected to procedures for the treatment of the LHBT injuries at a mean postoperative follow-up of 5 years. There is no difference in muscle appearance on the MRI after biceps tenotomy or tenodesis. Thus, the variations in the length of the biceps muscle mass found in the present study (difference in AH-MTJ distance) did not contribute to the onset of FI in the muscle belly. It was also not possible to establish a correlation between the discrepancy in biceps length measured on MRI images and residual pain, loss of flexion strength or arm deformity.

Our MRI images were collected from both arms and from all 31 patients, and the muscle mass on the operated side was compared with the muscle mass of the contralateral side, which was free of significant changes in the biceps and in the rotator cuff. We quantitatively investigated the retraction of the muscle belly evaluated and its possible relationship with the presence of FI.

There were seven patients with unsatisfactory (moderate or severe) deformities in the operated arm and the means of the differences in the AH-MTJ distance were similar for patients who presented satisfactory and unsatisfactory de-

formities. In conclusion, the AH-MTJ distance is not the only aspect that determines the satisfaction of the patient.

In the present study, we performed MRI examinations in both arms of the 31 patients so that we could compare the muscle mass of the anterior compartment of both arms and compare the variation in the length of the biceps muscle mass based on the difference in the AH-MTJ distance. There was no relationship between the difference in the AH-MTJ distance and FI and there was also no relationship between FI and arm deformity. Similarly, in the 31 evaluated patients, there were no signs of FI after a mean postoperative period of 5 years. This finding suggests that chronic biceps injuries can be repaired while maintaining good muscle power and function because the musculature is preserved over the years, even when there is retraction. We also did not find a correlation between FI and arm deformity.

The chronic lack of load and simple tenotomy of the rotator cuff muscles can result in FI and in a significant reduction in muscle volume.<sup>2,15</sup> The long head of the biceps originates in the supraglenoid tubercle proximally, merges with the short head and inserts distally in the tuberosity of the radius, crossing 2 joints; therefore, even if its proximal end is detached, the distal end remains inserted, generating load and activating muscle fibers.

In the case of tenotomy, residual pain may occur because some of the force generated by muscle contraction is not transmitted to a tendon attached to the bone,<sup>3</sup> and an increase in the incidence of cramping pain in the biceps has been reported.<sup>16</sup> In tenodesis, pain may occur due to the permanence of synovitis in the bicipital groove, especially if the fixation is performed at the joint margin or in the most proximal portion of the intertubercular groove.<sup>9</sup> For any technique, when there is excessive retraction of the muscle belly, eventual chronic tension in the common branch of the MCN could be a cause of pain. We did not find a significant relationship between pain on palpation of the intertubercular groove and the difference in AH-MTJ distance ( $p = 0.103$ ). Residual pain related to the biceps may be found in 19% of cases of tenotomy and in 24% of cases of tenodesis.<sup>9</sup> In our study, pain on palpation of the intertubercular groove was present in 10 of the 31 patients, 3 in the tenodesis group (18.75%) and 7 in the tenotomy group (46.6%), but this difference was not significant ( $p = 0.135$ ), possibly due to the sample size.

Our study compared percent elbow flexion strength with the difference in the AH-MTJ distance, and there was no significant relationship ( $p = 0.070$ ). It remains controversial whether there is a clinical difference in the loss of strength after tenotomy and tenodesis.<sup>9</sup> Shank et al.<sup>17</sup> found no difference in strength when comparing the postoperative period after tenodesis and tenotomy. Another study found a 20% loss of elbow flexion strength after tenotomy.<sup>16</sup> Although it was not the objective of our study, we individually compared the results of the 2 groups and found no significant difference in percent elbow flexion strength ( $p = 0.311$ ). The tenotomy group had a mean strength of 102.4% compared with the contralateral side, while the tenodesis group had a mean strength of 106.7%, which was slightly higher.

Our study has some limitations. Initially, considering that the MTJ may extend for ~8 cm,<sup>11</sup> we stipulated as the standard measure the first muscle fibers of the biceps identified in the T1-weighted axial section; however, this measure may be subject to individual anatomical variations. To minimize these effects, all MRI exams were performed on the same machine, following the same protocol, and evaluated by the same radiologist. A second limitation was not having performed a histological evaluation of the muscle fibers. Although a histological evaluation is perhaps the gold standard for assessing FI, it would be ethically impossible to perform; in addition, MRI evaluation has been widely used to investigate muscle trophism and is well-established in shoulder and elbow surgery. A third limitation is the use of a manual dynamometer, which is not the perfect tool, but it gives a good idea of the elbow flexion strength. The number of individuals may have been insufficient for some secondary analyses; however, it was absolutely sufficient for the initial and main purpose of evaluating FI of the biceps brachii muscle.

## Conclusion

At an average follow-up of 5 years, none of the evaluated patients had evidence of FI in the muscle mass of the anterior compartment of the arm after biceps tenodesis or tenotomy.

There was no difference between tenotomy and tenodesis regarding the muscle mass pattern observed by MRI.

It was not possible to establish a correlation between the biceps muscle length discrepancy measured on MRI, the presence of deformities, strength and the presence of FI in the anterior compartment of the arm.

### Financial Support

There was no financial support from public, commercial, or non-profit sources.

### Conflict of Interests

The authors have no conflict of interests to declare.

## References

- 1 Lim TK, Moon ES, Koh KH, Yoo JC. Patient-related factors and complications after arthroscopic tenotomy of the long head of the biceps tendon. *Am J Sports Med* 2011;39(04):783–789
- 2 Gerber C, Meyer DC, Flück M, et al. Muscle degeneration associated with rotator cuff tendon release and/or denervation in sheep. *Am J Sports Med* 2017;45(03):651–658
- 3 Deutch SR, Gelineck J, Johannsen HV, Sneppen O. Permanent disabilities in the displaced muscle from rupture of the long head tendon of the biceps. *Scand J Med Sci Sports* 2005;15(03):159–162
- 4 The B, Bratty M, Wang A, et al. Biceps muscle fatty infiltration and atrophy. A midterm review after arthroscopic tenotomy of the long head of the biceps. *Arthroscopy* 2015;31(03):477–481
- 5 Sanders B, Lavery KP, Pennington S, Warner JJ. Clinical success of biceps tenodesis with and without release of the transverse humeral ligament. *J Shoulder Elbow Surg* 2012;21(01):66–71
- 6 Hsu AR, Ghodadra NS, Provencher MT, Lewis PB, Bach BR. Biceps tenotomy versus tenodesis: a review of clinical outcomes and biomechanical results. *J Shoulder Elbow Surg* 2011;20(02):326–332
- 7 Neer CS II. Anterior acromioplasty for the chronic impingement syndrome in the shoulder: a preliminary report. *J Bone Joint Surg Am* 1972;54(01):41–50
- 8 Elser F, Braun S, Dewing CB, Giphart JE, Millett PJ. Anatomy, function, injuries, and treatment of the long head of the biceps brachii tendon. *Arthroscopy* 2011;27(04):581–592
- 9 Slenker NR, Lawson K, Ciccotti MG, Dodson CC, Cohen SB. Biceps tenotomy versus tenodesis: clinical outcomes. *Arthroscopy* 2012;28(04):576–582
- 10 Werner BC. Editorial commentary: how can I tenodesis the biceps tendon of the shoulder? Let me count the ways. *Arthroscopy* 2018;34(06):1762–1763
- 11 LaFrance R, Madsen W, Yaseen Z, Giordano B, Maloney M, Voloshin I. Relevant anatomic landmarks and measurements for biceps tenodesis. *Am J Sports Med* 2013;41(06):1395–1399
- 12 Fuchs B, Weishaupt D, Zanetti M, Hodler J, Gerber C. Fatty degeneration of the muscles of the rotator cuff: assessment by computed tomography versus magnetic resonance imaging. *J Shoulder Elbow Surg* 1999;8(06):599–605
- 13 Kang JR, Gupta R. Mechanisms of fatty degeneration in massive rotator cuff tears. *J Shoulder Elbow Surg* 2012;21(02):175–180
- 14 Scheibel M, Schröder RJ, Chen J, Bartsch M. Arthroscopic soft tissue tenodesis versus bony fixation anchor tenodesis of the long head of the biceps tendon. *Am J Sports Med* 2011;39(05):1046–1052
- 15 Meyer DC, Hoppeler H, von Rechenberg B, Gerber C. A pathomechanical concept explains muscle loss and fatty muscular changes following surgical tendon release. *J Orthop Res* 2004;22(05):1004–1007
- 16 Koh KH, Ahn JH, Kim SM, Yoo JC. Treatment of biceps tendon lesions in the setting of rotator cuff tears: prospective cohort study of tenotomy versus tenodesis. *Am J Sports Med* 2010;38(08):1584–1590
- 17 Shank JR, Singleton SB, Braun S, et al. A comparison of forearm supination and elbow flexion strength in patients with long head of the biceps tenotomy or tenodesis. *Arthroscopy* 2011;27(01):9–16