

Antithrombotic Therapy in Myocardial Infarction: Historic Perils and Current Challenges—A 70-Year Journey

Himawan Fernando^{1,2,3} James D. McFadyen^{1,2,4} Jathushan Palasubramaniam^{1,2,3} James Shaw^{2,3}
Xiaowei Wang^{1,2} Dion Stub^{2,3,*} Karlheinz Peter^{1,2,3,5,*}

¹Atherothrombosis and Vascular Biology Laboratory, Baker Heart and Diabetes Institute, Melbourne, Victoria, Australia

²Department of Medicine, Monash University, Melbourne, Victoria, Australia

³Department of Cardiology, The Alfred Hospital, Melbourne, Victoria, Australia

⁴Thrombosis and Haemostasis Unit, Department of Clinical Haematology, The Alfred Hospital, Melbourne, Victoria, Australia

⁵Department of Immunology, Monash University, Melbourne, Victoria, Australia

Address for correspondence Karlheinz Peter, MD, PhD, Baker Heart and Diabetes Institute, 75 Commercial Road, Melbourne, VIC 3004, Australia (e-mail: Karlheinz.Peter@baker.edu.au).

Thromb Haemost 2020;120:1352–1356.

Abstract

There have been numerous and intriguing advancements in antithrombotic therapy for myocardial infarction since it was described in the earliest issues of *Thrombosis and Haemostasis*. In this article, we revisit historical breakthroughs and describe the four most challenging contemporary themes relating to antithrombotic therapy in myocardial infarction. In all four, the challenge is to find the best balance of reducing specific levels of ischaemic risks without increasing bleeding risk. The first is the question of the optimal duration of dual antiplatelet therapy (DAPT) after percutaneous coronary intervention (PCI). This includes discussion of monotherapy after a period of DAPT. The second relates to the role of genotype and phenotype-guided individualisation of antiplatelet therapy. There is emerging evidence for a role of pheno/genotyping in identifying individuals at high risk for recurrent ischaemic events or in guiding the timing of cardiac surgery for patients on DAPT. The third addresses the increasing evidence for dual pathway inhibition, for example, with rivaroxaban in addition to aspirin in patients where high ischaemic and low bleeding risk is demonstrated. Finally the fourth highlights the challenge of the most appropriate combination of antiplatelet and anticoagulation therapy for patients with known atrial fibrillation after PCI. In most individuals, oral P₂Y₁₂ inhibitor therapy combined with a direct acting oral anticoagulant appears to be the best strategy based on the available evidence. Overall, the progress in antithrombotic therapy achieved over the last seven decades is remarkable, however, there are important issues to address and progress still to be made.

Keywords

- ▶ myocardial infarction
- ▶ combination antiplatelet anticoagulation therapy
- ▶ dual pathway inhibition
- ▶ dual antiplatelet therapy
- ▶ platelet function testing

* These senior authors contributed equally to this work.

received
December 10, 2019
accepted after revision
June 4, 2020

© 2020 Georg Thieme Verlag KG
Stuttgart · New York

DOI <https://doi.org/10.1055/s-0040-1714212>.
ISSN 0340-6245.

To mark the availability of the earliest *Thrombosis and Haemostasis* issues online, we commemorate the revolutionary changes in antithrombotic therapy for acute myocardial infarction (MI) since the inception of this journal. The paper titled “The use of anticoagulants in cardiology” published in 1958 by Prof. Peter Formijne in volume 2¹ of *Thrombosis and Haemostasis* describes the challenges of managing patients with MI prior to effective reperfusion strategies and antith-

rombotic therapy.¹ Formijne presents the unenviable dilemma of whether to treat patients with anticoagulation during acute MI, which would require transfer of unstable patients to hospitals. These were serious considerations during a time when mortality post-MI was high, as were fatal complications such as ventricular rupture. Fortunately, these complications are now rarely seen due to the remarkable development of antithrombotic agents (see ►Fig. 1), which in turn has

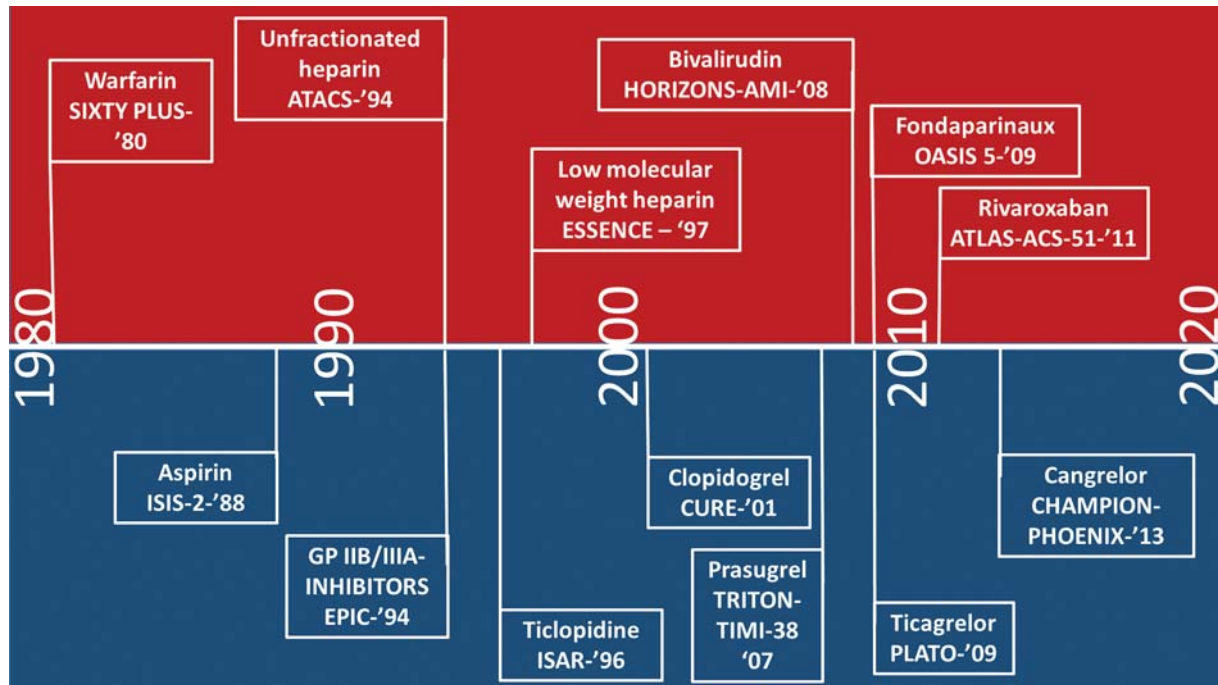


Fig. 1 Timeline of antithrombotic agents noting pivotal trials and their year of publication. Anticoagulant drugs are shown in the upper red panel, antiplatelet drugs are shown in the lower blue panel. In chronological order: *SIXTY PLUS* (a double-blind trial to assess long-term oral anticoagulant therapy in elderly patients after MI study): while warfarin has been used clinically since the 1950s, this was one of the first pivotal randomized trials of warfarin after MI. The risk of recurrent MI and cardiac death was reduced by continuing warfarin after MI compared with placebo in patients over the age of 60.³⁷ *ISIS-2* (randomized trial of intravenous streptokinase, oral aspirin, both, or neither among 17,187 cases of suspected acute MI study): absolute reduction in vascular mortality with aspirin alone and in combination with streptokinase in patients with suspected acute MI.³⁸ *ATACS* (combination antithrombotic therapy in unstable angina and non-Q-wave infarction in nonprior aspirin users: an Antithrombotic Therapy in Acute Coronary Syndromes Research Group study): the combination of aspirin and heparin given acutely followed by aspirin and warfarin in patients with unstable angina or non-Q wave MI was associated with a reduction in recurrent angina and total ischemic events compared with aspirin alone.³⁹ *EPIC* (use of a monoclonal antibody directed against the platelet glycoprotein IIb/IIIa receptor in high-risk coronary angioplasty study): in patients with severe unstable angina, evolving acute MI or high-risk coronary morphological characteristics undergoing percutaneous coronary intervention (PCI), the addition of abciximab reduced ischemic complications post-PCI compared with placebo.⁴⁰ Pivotal trials for eptifibatid and tirofiban followed shortly after. *ISAR* (a randomized comparison of antiplatelet and anticoagulant therapy after the placement of coronary-artery stents study): the combination of aspirin and ticlopidine (platelet P₂Y₁₂ inhibitor) significantly reduced the composite primary ischemic cardiac endpoint after PCI compared with anticoagulation.⁴¹ *ESSENCE* (a comparison of low-molecular-weight heparin with unfractionated heparin for unstable coronary artery disease study): a significantly lower risk of death, MI, or recurrent angina was seen in patients treated with enoxaparin compared with heparin in patients with unstable angina and non-Q-wave MI.⁴² *CURE* (effects of clopidogrel in addition to aspirin in patients with acute coronary syndromes [ACS] without ST-segment elevation study): the addition of clopidogrel to aspirin in patients with ACS without ST-segment elevation reduced a composite of cardiovascular outcomes compared with aspirin alone.⁴³ *TRITON-TIMI-38* (prasugrel versus clopidogrel in patients with ACS study): prasugrel when compared with clopidogrel in addition to aspirin in patients with ACS undergoing PCI was associated with fewer cardiovascular events offset by a small but statistically significant increased risk of life-threatening and fatal bleeding.⁴⁴ *HORIZONS-AMI* (bivalirudin during primary PCI in acute MI study): lower rates of major bleeding, reduced death from cardiac and all causes seen with bivalirudin compared with heparin plus glycoprotein IIb/IIIa inhibitors in patients with ST-elevation MI undergoing PCI. There was however an increase in risk of acute stent thrombosis within 24 hours with bivalirudin but not at 30 days.⁴⁵ *PLATO* (ticagrelor versus clopidogrel in patients with ACS study): in patients presenting with ACS, ticagrelor was superior in reducing composite cardiovascular outcomes and all-cause mortality compared with clopidogrel.⁴⁶ *OASIS 5* (comparison of fondaparinux and enoxaparin in ACS study): when fondaparinux was compared with enoxaparin in patients with ACS, the risk of major bleeding was significantly reduced which led to a small but significant reduction in death with a similar benefit in terms of reducing ischemic events.⁴⁷ *ATLAS-ACS-2-TIMI-51* (rivaroxaban in patients with a recent ACS study): rivaroxaban at low dose in addition to dual antiplatelet therapy (in the majority of patients) after recent ACS reduced the composite primary ischemic endpoint at the expense of a small but significant increased risk of intracranial hemorrhage. There was no significant increase in fatal bleeding.²⁶ *CHAMPION-PHOENIX* (effect of platelet inhibition with cangrelor during PCI on ischemic events study): cangrelor significantly reduced the primary composite ischemic endpoint including stent thrombosis compared with clopidogrel in patients undergoing urgent or elective PCI.⁴⁸ MI, myocardial infarction.

paralleled the technical advancement of percutaneous coronary intervention (PCI) as the reperfusion strategy of choice. Despite this, cardiovascular disease remains at epidemic proportions and new challenges have arisen in the utilization of antithrombotic therapy in MI. We will present four of these challenges and considerations below.

The first is finding the optimal balance between bleeding and ischemic risk in the dose, duration, and utilization of dual antiplatelet therapy (DAPT), which remains one of the main challenges clinicians face today.²⁻⁴ This has prompted creative strategies that seek to promote individualized medicine and strike a favorable balance between these factors based on patient characteristics. Results from randomized studies and a meta-analysis suggest that patients with greater procedural complexity or comorbidities such as diabetes mellitus, renal dysfunction, or peripheral vascular disease may benefit from greater than 12 months and up to 36 months of DAPT achieved by continuing oral P₂Y₁₂ inhibition, although this is invariably associated with increased bleeding risk.⁵⁻⁹ In contrast, in selected patients in the context of progressive improvement in stent design, shorter durations of DAPT followed by omitting aspirin (P₂Y₁₂ inhibitor monotherapy) after PCI are becoming increasingly adopted and supported by a growing body of evidence. The TWILIGHT study, which enrolled patients with at least one clinical and one angiographic high-risk feature (including MI) with PCI using next-generation biolimus A9-eluting stents to either ticagrelor monotherapy or DAPT after 3 months of DAPT, found reduced bleeding without an increased ischemic risk in the ticagrelor monotherapy arm.¹⁰ Similar results were seen in the TICO study presented at the American College of Cardiology (ACC) 2020 scientific sessions which enrolled an ACS-only cohort.^{11,12} The GLOBAL LEADERS study, which investigated ticagrelor monotherapy versus DAPT after only 1 month of DAPT post-PCI, revealed that this strategy is noninferior to DAPT in terms of ischemic events. However, there was no reduction in bleeding risk, which was not expected.¹³ P₂Y₁₂ monotherapy may be a feasible option after a short duration of DAPT in patients with either an increased bleeding risk or a lower predicted future ischemic risk. The use of the DAPT scoring system to guide duration of P₂Y₁₂ inhibition may assist in decision making surrounding duration of DAPT, although further improvement to this model is likely required.¹⁴ In stable coronary artery disease (CAD), the most recent ACC guideline recommends a minimum of 6 months of DAPT post-PCI, while the European Society of Cardiology (ESC) guidelines recommend 6 months.^{15,16} Both guidelines allow flexibility with shorter durations of DAPT notably with discontinuation of oral P₂Y₁₂ inhibitor for patients with a bleeding complication or at higher bleeding risk (3 months ACC, 1-3 months ESC) as well as longer DAPT durations in those with lower bleeding risk. In ACS, both guidelines recommend 12 months of DAPT noting that oral P₂Y₁₂ inhibitors may be discontinued after 6 months in patients with a bleeding event or at high bleeding risk. DAPT can also be continued for greater than 12 months in patients at

higher ischemic risk.¹⁷ Ticagrelor monotherapy does not feature in current ACC or ESC guidelines.

A second consideration is whether individualization of oral P₂Y₁₂ inhibitor therapy is achievable by utilizing platelet function testing and/or genotyping. The use of platelet function testing (phenotype-guided) to guide de-escalation of P₂Y₁₂ therapy in patients with adequate platelet inhibition to clopidogrel seems intuitive. However, without further proof, currently this cannot be recommended.^{18,19} Genomic testing to determine de-escalation to clopidogrel appears to be more consistent than the phenotypic approach, which has greater intra-individual variability. However, no added benefit of genotyping in predicting ischemic or bleeding events was seen over platelet function testing in this setting.²⁰ Current ACC and ESC guidelines do not recommend routine platelet function testing due to the lack of data from randomized studies demonstrating benefit.^{21,22} However, the ESC guideline suggests there may be a role in patients with recurrent adverse events or to guide timing of cardiac surgery in patients on DAPT where it may change patient management.

The third challenge is to find a safe and effective way of combining direct-acting oral anticoagulants (DOACs) with antiplatelet therapy denoted "dual pathway" inhibition to reduce recurrent ischemic events in high-risk individuals.²³⁻²⁵ By inhibiting factor Xa, a key component of the coagulation cascade leading to thrombin and fibrin generation, addition of DOAC therapy to antiplatelet agents is thought to be synergistic in enhancing vascular protection. The ATLAS ACS 2-TIMI 51 trial employed low-dose rivaroxaban regimens in addition to dual antiplatelet therapy. At the lowest dose of 2.5 mg twice per day, there was an overall benefit in reduction of recurrent ischemic events with a small increase in bleeding including intracranial hemorrhage, but no increase in fatal bleeding.²⁶ Furthermore, the COMPASS trial demonstrated that addition of rivaroxaban at a dose of 2.5 mg twice per day to aspirin reduced ischemic cardiac and vascular events in patients with a history of CAD or peripheral artery disease (PAD).²⁷ Finally, the VOYAGER-PAD study demonstrated that addition of rivaroxaban at a dose of 2.5 mg twice per day to aspirin for patients post lower extremity revascularization led to reduced cardiovascular complications.²⁸ In COMPASS and VOYAGER-PAD, the trade-off for ischemic benefit is an increased bleeding risk and this was also seen in the APPRAISE study, which tested apixaban at a dose of 5 mg twice per day in addition to DAPT post-ACS and was stopped prematurely due to an increased risk of bleeding complications.²⁹ As such, rivaroxaban at a low dose (2.5 mg twice per day) in addition to aspirin may play an important role in reducing recurrent cardiovascular complications in high-ischemic, low bleeding-risk patients as evidenced by its inclusion in recent ESC guidelines; however, this is not generalizable to other DOACs at this stage.¹⁶

The fourth challenge is optimal treatment of patients with atrial fibrillation and PCI. Fortunately, there is now considerable evidence, which includes data for dabigatran, rivaroxaban, apixaban, and edoxaban, indicating that the

combination of a P₂Y₁₂ inhibitor and a DOAC provides the most acceptable balance between reducing ischemic and bleeding events in the majority of patients.^{30–34} The most recent ACC atrial fibrillation guidelines reference these trials and note that dual therapy with clopidogrel and a DOAC is reasonable and reduces bleeding complications compared with triple therapy.³⁵ The guidelines also advise to switch to dual therapy after 4 to 6 weeks of triple therapy, if this is commenced initially. The ESC guidelines suggest early cessation of triple therapy (cessation of aspirin) less than 1 week after uncomplicated PCI, if bleeding risks are greater than risk of stent thrombosis. Triple therapy between 1 and 6 months post-PCI can be considered when risk of stent thrombosis outweighs bleeding risk.¹⁶ New innovative experimental approaches are successfully combining antiplatelet and anticoagulant effects in a single activated-platelet-targeted drug, which promises to avoid bleeding complications.³⁶

As portrayed in ►Fig. 1, we have seen revolutionary advancement in antithrombotic therapy over the past 70 years from vitamin K antagonism to direct oral anticoagulation, the introduction of antiplatelet drugs from aspirin to highly selective P₂Y₁₂ and GP IIb/IIIa platelet receptor inhibitors, and the development of potent fibrinolytic drugs. While it is likely that Prof. Formijne would have been very grateful to have access to the antithrombotic armamentarium available today, these advancements have brought with them significant new challenges, most importantly balancing the bleeding risk associated with all of the currently available antithrombotic drugs.

Funding

This study was funded by the National Health and Medical Research Council of Australia.

Conflict of Interest

None declared.

References

- Formijne P. The use of anticoagulants in cardiology. *Thromb Diath Haemorrh* 1958;2(5–6):505–509
- Gorog DA, Geisler T. Platelet inhibition in acute coronary syndrome and percutaneous coronary intervention: insights from the past and present. *Thromb Haemost* 2020;120(04):565–578
- McFadyen JD, Schaff M, Peter K. Current and future antiplatelet therapies: emphasis on preserving haemostasis. *Nat Rev Cardiol* 2018;15(03):181–191
- McFadyen JD, Peter K. Novel antithrombotic drugs on the horizon: the ultimate promise to prevent clotting while avoiding bleeding. *Circ Res* 2017;121(10):1133–1135
- Bonaca MP, Bhatt DL, Cohen M, et al; PEGASUS-TIMI 54 Steering Committee and Investigators. Long-term use of ticagrelor in patients with prior myocardial infarction. *N Engl J Med* 2015;372(19):1791–1800
- Helft G, Steg PG, Le Feuvre C, et al; OPTimal DUAL Antiplatelet Therapy Trial Investigators. Stopping or continuing clopidogrel 12 months after drug-eluting stent placement: the OPTIDUAL randomized trial. *Eur Heart J* 2016;37(04):365–374
- Lee CW, Ahn JM, Park DW, et al. Optimal duration of dual antiplatelet therapy after drug-eluting stent implantation: a randomized, controlled trial. *Circulation* 2014;129(03):304–312
- Mauri L, Kereiakes DJ, Yeh RW, et al; DAPT Study Investigators. Twelve or 30 months of dual antiplatelet therapy after drug-eluting stents. *N Engl J Med* 2014;371(23):2155–2166
- Udell JA, Bonaca MP, Collet JP, et al. Long-term dual antiplatelet therapy for secondary prevention of cardiovascular events in the subgroup of patients with previous myocardial infarction: a collaborative meta-analysis of randomized trials. *Eur Heart J* 2016;37(04):390–399
- Mehran R, Baber U, Sharma SK, et al. Ticagrelor with or without aspirin in high-risk patients after PCI. *N Engl J Med* 2019;381(21):2032–2042
- Kim C, Hong S-J, Shin D-H, et al. Randomized evaluation of ticagrelor monotherapy after 3-month dual-antiplatelet therapy in patients with acute coronary syndrome treated with new-generation sirolimus-eluting stents: TICO trial rationale and design. *Am Heart J* 2019;212:45–52
- Byeong-Keuk Kim. Ticagrelor with or without aspirin in acute coronary syndrome after PCI - TICO. Paper presented at: The American College of Cardiology Virtual Annual Scientific Session Together With World Congress of Cardiology (ACC 2020/WCC), March 30, 2020
- Vranckx P, Valgimigli M, Jüni P, et al; GLOBAL LEADERS Investigators. Ticagrelor plus aspirin for 1 month, followed by ticagrelor monotherapy for 23 months vs aspirin plus clopidogrel or ticagrelor for 12 months, followed by aspirin monotherapy for 12 months after implantation of a drug-eluting stent: a multi-centre, open-label, randomised superiority trial. *Lancet* 2018;392(10151):940–949
- Harada Y, Michel J, Lohaus R, et al. Validation of the DAPT score in patients randomized to 6 or 12 months clopidogrel after predominantly second-generation drug-eluting stents. *Thromb Haemost* 2017;117(10):1989–1999
- Levine GN, Bates ER, Bittl JA, et al. 2016 ACC/AHA guideline focused update on duration of dual antiplatelet therapy in patients with coronary artery disease: a report of the American College of Cardiology/American Heart Association Task Force on Clinical Practice Guidelines. *J Thorac Cardiovasc Surg* 2016;152(05):1243–1275
- Knutti J, Wijns W, Saraste A, et al; ESC Scientific Document Group. 2019 ESC guidelines for the diagnosis and management of chronic coronary syndromes. *Eur Heart J* 2020;41(03):407–477
- Valgimigli M, Bueno H, Byrne RA, et al; ESC Scientific Document Group. 2017 ESC focused update on dual antiplatelet therapy in coronary artery disease developed in collaboration with EACTS. *Eur J Cardiothorac Surg* 2018;53(01):34–78
- Angiolillo DJ. Platelet function or genetic testing for guiding de-escalation of anti-platelet therapy: the jury is still out. *Thromb Haemost* 2018;118(09):1509–1511
- Sibbing D, Aradi D, Jacobshagen C, et al; TROPICAL-ACS Investigators. Guided de-escalation of antiplatelet treatment in patients with acute coronary syndrome undergoing percutaneous coronary intervention (TROPICAL-ACS): a randomised, open-label, multicentre trial. *Lancet* 2017;390(10104):1747–1757
- Gross L, Trenk D, Jacobshagen C, et al. Genotype-phenotype association and impact on outcomes following guided de-escalation of anti-platelet treatment in acute coronary syndrome patients: The TROPICAL-ACS Genotyping Substudy. *Thromb Haemost* 2018;118(09):1656–1667
- Levine GN, Bates ER, Bittl JA, et al. 2016 ACC/AHA guideline focused update on duration of dual antiplatelet therapy in patients with coronary artery disease: a report of the American College of Cardiology/American Heart Association Task Force on Clinical Practice Guidelines. *J Am Coll Cardiol* 2016;68(10):1082–1115
- Valgimigli M, Bueno H, Byrne RA, et al; ESC Scientific Document Group; ESC Committee for Practice Guidelines (CPG); ESC National Cardiac Societies. 2017 ESC focused update on dual antiplatelet therapy in coronary artery disease developed in collaboration

- with EACTS: The Task Force for Dual Antiplatelet Therapy in Coronary Artery Disease of the European Society of Cardiology (ESC) and of the European Association for Cardio-Thoracic Surgery (EACTS). *Eur Heart J* 2018;39(03):213–260
- 23 Sumaya W, Geisler T, Kristensen SD, Storey RF. Dual antiplatelet or dual antithrombotic therapy for secondary prevention in high-risk patients with stable coronary artery disease? *Thromb Haemost* 2019;19(10):1583–1589
 - 24 Bauersachs R, Zannad F. Rivaroxaban: a new treatment paradigm in the setting of vascular protection? *Thromb Haemost* 2018;118(S 01):S12–S22
 - 25 Zeymer U, Schrage B, Westermann D. Dual pathway inhibition with low-dose direct factor Xa inhibition after acute coronary syndromes—why is it not used in clinical practice? *Thromb Haemost* 2018;118(09):1528–1534
 - 26 Mega JL, Braunwald E, Wiviott SD, et al; ATLAS ACS 2–TIMI 51 Investigators. Rivaroxaban in patients with a recent acute coronary syndrome. *N Engl J Med* 2012;366(01):9–19
 - 27 Eikelboom JW, Connolly SJ, Bosch J, et al; COMPASS Investigators. Rivaroxaban with or without aspirin in stable cardiovascular disease. *N Engl J Med* 2017;377(14):1319–1330
 - 28 Bonaca MP, Bauersachs RM, Anand SS, et al. Rivaroxaban in peripheral artery disease after revascularization. *N Engl J Med* 2020;382(21):1994–2004
 - 29 Alexander JH, Lopes RD, James S, et al; APPRAISE-2 Investigators. Apixaban with antiplatelet therapy after acute coronary syndrome. *N Engl J Med* 2011;365(08):699–708
 - 30 Cannon CP, Bhatt DL, Oldgren J, et al; RE-DUAL PCI Steering Committee and Investigators. Dual antithrombotic therapy with dabigatran after PCI in atrial fibrillation. *N Engl J Med* 2017;377(16):1513–1524
 - 31 Lopes RD, Heizer G, Aronson R, et al; AUGUSTUS Investigators. Antithrombotic therapy after acute coronary syndrome or PCI in atrial fibrillation. *N Engl J Med* 2019;380(16):1509–1524
 - 32 Gibson CM, Mehran R, Bode C, et al. Prevention of bleeding in patients with atrial fibrillation undergoing PCI. *N Engl J Med* 2016;375(25):2423–2434
 - 33 Gargiulo G, Goette A, Tijssen J, et al. Safety and efficacy outcomes of double vs. triple antithrombotic therapy in patients with atrial fibrillation following percutaneous coronary intervention: a systematic review and meta-analysis of non-vitamin K antagonist oral anticoagulant-based randomized clinical trials. *Eur Heart J* 2019;40(46):3757–3767
 - 34 Vranckx P, Valgimigli M, Eckardt L, et al. Edoxaban-based versus vitamin K antagonist-based antithrombotic regimen after successful coronary stenting in patients with atrial fibrillation (EN-TRUST-AF PCI): a randomised, open-label, phase 3b trial. *Lancet* 2019;394(10206):1335–1343
 - 35 January CT, Wann LS, Calkins H, et al. 2019 AHA/ACC/HRS focused update of the 2014 AHA/ACC/HRS guideline for the management of patients with atrial fibrillation: a report of the American College of Cardiology/American Heart Association Task Force on Clinical Practice Guidelines and the Heart Rhythm Society. *J Am Coll Cardiol* 2019;74(01):104–132
 - 36 Hanjaya-Putra D, Haller C, Wang X, et al. Platelet-targeted dual pathway antithrombotic inhibits thrombosis with preserved hemostasis. *JCI Insight* 2018;3(15):3
 - 37 A double-blind trial to assess long-term oral anticoagulant therapy in elderly patients after myocardial infarction. Report of the Sixty Plus Reinfarction Study Research Group. *Lancet* 1980;2(8202):989–994
 - 38 Randomised trial of intravenous streptokinase, oral aspirin, both, or neither among 17,187 cases of suspected acute myocardial infarction: ISIS-2. ISIS-2 (Second International Study of Infarct Survival) Collaborative Group. *Lancet* 1988;2(8607):349–360
 - 39 Cohen M, Adams PC, Parry G, et al. Combination antithrombotic therapy in unstable rest angina and non-Q-wave infarction in nonprior aspirin users. Primary end points analysis from the ATACS trial. Antithrombotic Therapy in Acute Coronary Syndromes Research Group. *Circulation* 1994;89(01):81–88
 - 40 EPIC Investigators. Use of a monoclonal antibody directed against the platelet glycoprotein IIb/IIIa receptor in high-risk coronary angioplasty. *N Engl J Med* 1994;330(14):956–961
 - 41 Schömig A, Neumann F-J, Kastrati A, et al. A randomized comparison of antiplatelet and anticoagulant therapy after the placement of coronary-artery stents. *N Engl J Med* 1996;334(17):1084–1089
 - 42 Cohen M, Demers C, Gurfinkel EP, et al; Efficacy and Safety of Subcutaneous Enoxaparin in Non-Q-Wave Coronary Events Study Group. A comparison of low-molecular-weight heparin with unfractionated heparin for unstable coronary artery disease. *N Engl J Med* 1997;337(07):447–452
 - 43 Yusuf S, Zhao F, Mehta SR, Chrolavicius S, Tognoni G, Fox KK; Clopidogrel in Unstable Angina to Prevent Recurrent Events Trial Investigators. Effects of clopidogrel in addition to aspirin in patients with acute coronary syndromes without ST-segment elevation. *N Engl J Med* 2001;345(07):494–502
 - 44 Wiviott SD, Braunwald E, McCabe CH, et al; TRITON-TIMI 38 Investigators. Prasugrel versus clopidogrel in patients with acute coronary syndromes. *N Engl J Med* 2007;357(20):2001–2015
 - 45 Stone GW, Witzenbichler B, Guagliumi G, et al; HORIZONS-AMI Trial Investigators. Bivalirudin during primary PCI in acute myocardial infarction. *N Engl J Med* 2008;358(21):2218–2230
 - 46 Wallentin L, Becker RC, Budaj A, et al; PLATO Investigators. Ticagrelor versus clopidogrel in patients with acute coronary syndromes. *N Engl J Med* 2009;361(11):1045–1057
 - 47 Yusuf S, Mehta SR, Chrolavicius S, et al; Fifth Organization to Assess Strategies in Acute Ischemic Syndromes Investigators. Comparison of fondaparinux and enoxaparin in acute coronary syndromes. *N Engl J Med* 2006;354:1464–1476
 - 48 Bhatt DL, Stone GW, Mahaffey KW, et al; CHAMPION PHOENIX Investigators. Effect of platelet inhibition with cangrelor during PCI on ischemic events. *N Engl J Med* 2013;368(14):1303–1313