







Anatomical Study of the Motor Branches of the Radial Nerve in the Forearm*

Estudo anatômico dos ramos motores do nervo radial no antebraço

Edie Benedito Caetano¹ Luiz Angelo Vieira¹ João José Sabongi Neto¹
Maurício Benedito Ferreira Caetano² Celis Piovesan Picin¹ Luiz Claudio Nascimento da Silva Júnior¹

¹ Department of Surgery, Faculdade de Ciências Médicas e da Saúde, Pontifícia Universidade Católica de São Paulo, Sorocaba, SP, Brazil

² Hand Surgery Service, Conjunto Hospitalar de Sorocaba, Sorocaba, SP, Brazil

Address for correspondence Edie Benedito Caetano, PhD, Departamento de Cirurgia, Faculdade de Ciências Médicas e da Saúde, Pontifícia Universidade Católica de São Paulo (FCMS/PUC-SP), Rua Joubert Wey, 290, Sorocaba, SP, 18030-070, Brazil (e-mail: ediecaetano@uol.com.br).

Rev Bras Ortop 2020;55(6):764–770.

Abstract

Objective To analyze the anatomical variations of the motor branches of the radial nerve in the elbow region. The origin, course, length, branches, motor points and relationships with neighboring structures were evaluated.

Materials and Methods Thirty limbs from 15 adult cadavers were dissected and prepared by intra-arterial injection of a 10% glycerin and formaldehyde solution.

Results The first branch of the radial nerve in the forearm went to the brachioradialis muscle (BR), originating proximally to the division of the radial nerve into superficial branch of the radial nerve (SBRN) and posterior interosseous nerve (PIN) in all limbs. The branches to the extensor carpi radialis longus muscle (ECRL) detached from the proximal radial nerve proximally to its division into 26 limbs, in 2, at the dividing points, in other 2, from the PIN. In six limbs, the branches to the BR and ECRL muscles originated from a common trunk. We identified the origin of the branch to the extensor carpi radialis brevis muscle (ECRB) in the PIN in 14 limbs, in the SBRN in 12, and in the radial nerve in only 4. The branch to the supinator muscle originated from the PIN in all limbs.

Conclusion Knowledge of the anatomy of the motor branches of the radial nerve is important when performing surgical procedures in the region (such as the approach of the proximal third and the head of the radius, release of compressive syndromes of the posterior interosseous nerve and radial tunnel, and distal nerve transfers) in order to understand the order of recovery of muscle function after a nerve injury.

Keywords

- ▶ forearm injuries
- ▶ median nerve
- ▶ radial nerve
- ▶ anatomical variation
- ▶ nerve transfer

Resumo

Objetivo Analisar as variações anatômicas dos ramos motores do nervo radial na região do cotovelo. Foram avaliadas a origem, curso, comprimento, ramificações, pontos motores e relações com estruturas vizinhas.

* Work developed at the Department of Surgery, Faculdade de Ciências Médicas e da Saúde, Pontifícia Universidade Católica de São Paulo, Sorocaba, SP, Brazil.

Palavras-chave

- ▶ traumatismos do antebraço
- ▶ nervo mediano
- ▶ nervo radial
- ▶ variação anatômica
- ▶ transferência de nervo

Materiais e Métodos Foram dissecados 30 membros de 15 cadáveres adultos, preparados por injeção intra-arterial de uma solução de glicerina e formol a 10%.

Resultados O primeiro ramo do nervo radial no antebraço foi para o músculo braquiorradial (BR), que se origina proximalmente à divisão do nervo radial em ramo superficial do nervo radial (RSNR) e nervo interósseo posterior (NIP) em todos os membros. Os ramos para o músculo extensor radial longo do carpo (ERLC) se desprenderam do nervo radial proximalmente à sua divisão em 26 membros, em 2, nos pontos de divisão, em outros 2, do NIP. Em seis, os ramos para os músculos BR e ERLC originavam-se de um tronco comum. Identificamos a origem do ramo para o músculo extensor radial curto do carpo (ERCC) no NIP em 14 membros, no RSNR em 12, e no nervo radial em apenas 4. O ramo para o músculo supinador originou-se do NIP em todos os membros.

Conclusão O conhecimento da anatomia dos ramos motores do nervo radial é importante quando se realizam procedimentos cirúrgicos na região, como a abordagem do terço proximal e da cabeça do rádio, a liberação das síndromes compressivas do nervo interósseo posterior e do túnel radial, as transferências nervosas distais, e para entender a ordem de recuperação da função muscular após uma lesão nervosa.

Introduction

The radial nerve (RN) is the main nerve among those originating from the posterior fascicle of the brachial plexus. It innervates all muscles in the posterior compartment of the arm and forearm. It passes from the posterior to the anterior compartments, bypassing the RN groove in the humerus. It passes through the intermuscular septum between the brachialis muscle (BM) medially, and the brachioradialis (BR) muscle laterally. It follows distally, emerging between the BR and the extensor carpi radialis longus (ECRL). It is divided into the superficial branch of the radial nerve (SBRN) and posterior interosseous nerve (PIN), which is also called the deep branch of the radial nerve (DBRN). The radial tunnel is a musculoaponeurotic structure through which the PIN progresses, extending from the lateral epicondyle of the humerus to the distal edge of the supinator muscle (SM).^{1,2} Knowledge of the anatomy of the motor branches of the RN in the forearm is important when performing surgical procedures in the region, such as the approach of the proximal third and the head of the radius, the release of compressive syndromes of the PIN and radial tunnel, and to understand the order of recovery of muscle function after a nerve injury.^{1,2} The information in the present study can also be applied in selective denervation procedures to balance muscles in spastic upper limbs.^{3,4} The branches of the RN can be transferred to restore digital flexion in cases of proximal lesion to the median nerve (MN) or lesions to the brachial plexus involving predominantly lateral and medial cords, with preservation of the posterior cord.^{5,6} The motor points of the forearm muscles are defined as the place of entry of each nerve branch into the muscular body.³ The studies consulted show that the order of motor innervation, the number of branches, the motor points, and the anatomical variations of the RN branches present controversies.³⁻¹¹ The

aim of the present study was to analyze the anatomical variations of the motor branches of the RN in the elbow region, considering origin, course, length, branches, motor points and relationships with neighboring structures.

Materials and Methods

In total, 30 limbs from 15 cadavers, all adult and male, prepared by intra-arterial injection of a solution with 10% of glycerin and formaldehyde, were dissected. Each forearm was dissected with the elbow in extension, the wrist in neutral position, and the forearm in pronation. The cadavers showed no evidence of deformities, previous surgical procedures, or traumatic injuries in the studied area. We removed the skin and fascia from the distal third of the arm, forearm and wrist. The RN was identified in the arm between the BM and BR and dissected from proximal to distal. The tendons from the BR, ECRL and extensor carpi radialis brevis (ECRB) muscles were sectioned in their distal thirds, and separated from their fibrous connections, to facilitate the identification of the nerve branches. The division of the RN into its branches, SBRN and PIN, was identified and related to the intercondylar humeral line (IHL). The branches destined to the BR, ECRL, ECRB, SM and PIN muscles were dissected. The vascular structures were not preserved to facilitate nerve dissection. We used, at certain stages of dissection, a magnifying glass with 2.5 times of magnification. We analyzed the distance from the IHL both from the RN division point and from the emergence point of the RN in the arm, between the BM and BR muscles. The order of innervation of each muscle, the number of branches, and the number of motor points were recorded. With a digital caliper and a millimeter ruler, we measured the diameter and length of the branches to the BR, ECRL, ECRB, PIN, and SM. The present study was approved by the Ethics in Research Committee under opinion number 3,339,423.

Results

The RN crossed the lateral intermuscular septum, between the BM and BR, at an average of 9.2 cm (8.5 cm to 10.3 cm) proximal to IHL. The division into SBRN and PIN occurred at an average of 1.2 cm (0 cm to 2.3 cm) proximal to the IHL. We didn't record any RN division distal to the IHL.

Branches to the BM: we identified one branch from the RN to the BM in three limbs, and two branches in another limb, all of them above the IHL and proximal to the origin of the branches to the BR muscle (►Figure 1A).

Branches to the BR muscle: they detached to the other forearm muscles proximally in relation to the branches in all limbs. The presence of only 1 branch to the BR muscle was recorded in 23 limbs (76.5%) (►Figure 1A); in 7 (23.5%), we identified 2 branches (►Figure 1B). We did not identify more than two branches to the BR in any limb. The length of the branch to the BR was of 3.2 ± 0.8 cm, and the mean number of motor points was 2.4 ± 0.8 .

Branches to the ECRL: they originated in the RN before its division into 26 limbs (►Figure 2A). In two limbs, they originated at the division point of the RN; in two others, from the PIN. In 21 limbs (70%), we identified 1 branch to the ECRL (►Figure 2A), and there were 2 branches in 9 limbs (30%) (►Figure 1A). We did not identify more than two branches to the ECRL. In 6 limbs (20%), the branches to the BR and ECRL muscles originated from a common trunk (►Figure 1B). In one limb, they originated from a common trunk to the BR and ECRB (►Figure 2B). The length of the branch to the ECRL muscle was of 3.2 ± 1.0 cm, and the mean number of motor points was 2.9 ± 1.0 .




Fig. 1 A - Branch to BM (a); branch to BR (b); branches to ECRL (c); branch to ECRB (d); SBRN (e); PIN (f). B - Radial nerve (a); branch to BR (b); branches to ECRL (d); branch for ECRB (e); PIN (f); SBRN (g); branch to SM (h).

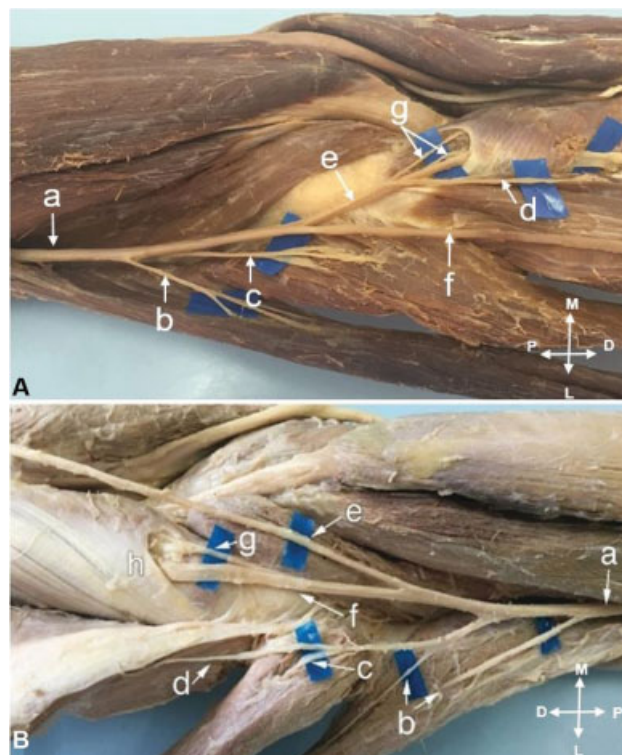


Fig. 2 A - Radial nerve (a); branch to BR (b); branch to ECRL (c); branch for ECRB (d); PIN (e); SBRN (f); branch to SM (g). B - Radial nerve (a); branch to BR (b); branch to ECRL (c); branch to ECRB (d); SBRN (e); PIN (f); branches to SM (g).

Branches to the ECRB: In all limbs, we identified only one branch to the ECRB. It originated in the PIN in 14 limbs (46.5%) (►Figure 2A), in the SBRN in 12 (40%) (►Figure 3A), and in the RN only in 4 (13.5%); 3 at the same point of division of the RN into SBRN and PIN (►Figure 3B), and 1 in the proximal division. The branch to the ECRB was divided, penetrating the anterior surface of the muscular body into at least two motor points. In 15 limbs, we recorded a distance between the proximal and distal motor points greater than 3 cm (►Figure 4A). The length of the branch to the ECRB muscle was of 4.5 ± 2.525 cm, and the mean number of motor points was 2.7 ± 1.2 .

Branches to the SM: They showed great variability, and we identified 2 to 5 branches, all from the PIN, with at least one branch destined to each of the superficial and deep heads (►Figure 4A and 4B). We identified branches to the SM proximal to the arcade of Frohse in 6 limbs, 2 branches to the SM in 11 limbs, and 3 branches in 4 limbs (►Figure 5A and 5B). In 7 limbs, we did not identify branches to the SM proximal to the arcade of Frohse. In them, the PIN emitted branches to the SM while passing through the muscle (►Figure 6A and 6B). In two limbs, only one branch detached from the PIN, but it was duplicated proximally to the arcade of Frohse. The length of the branches to the SM was of 1.0 ± 0.8 cm, and the mean number of motor points was 2.7 ± 1.2 . The number of motor points from the muscles innervated by the RN in the proximal, middle and distal thirds of the forearm are described in ►Table 1.

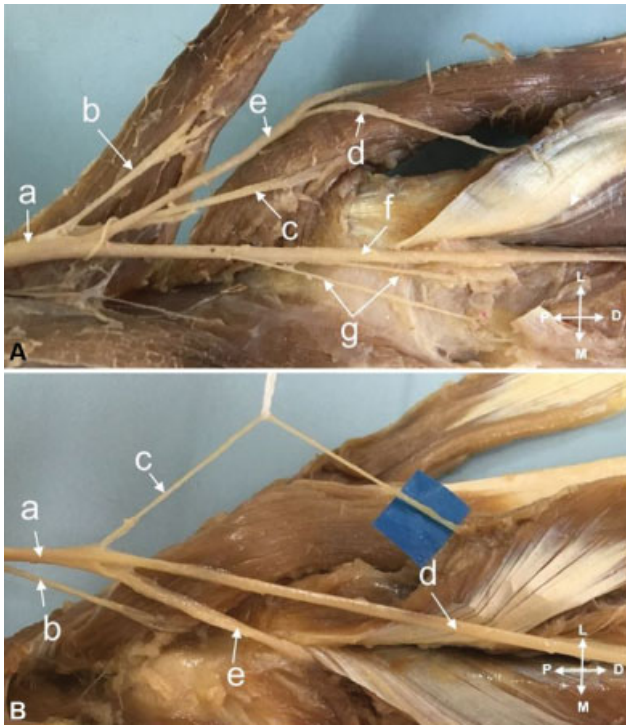


Fig. 3 A - Radial nerve (a); branch to BR (b); branch to ECRL (c); branch for ECRB (d); SBRN (e); PIN (f); branches to SM (g). B - Radial nerve (a); branch to ECRL (b); branch for ECRB (c); SBRN (d); PIN (e).




Fig. 5 A - Branches to SM (a); NIP (b); Frohse arcade (c); branch to ECRB (d); SBRN (e); median nerve (f); branches of the median nerve with its motor points (g). B - Radial nerve (a); branch to BR (b); branch to ECRL (c); branch to ECRB apparently originating in the RSNR (e) when the real origin is in the PIN (f); branch to SM (g); Frohse arcade (h).

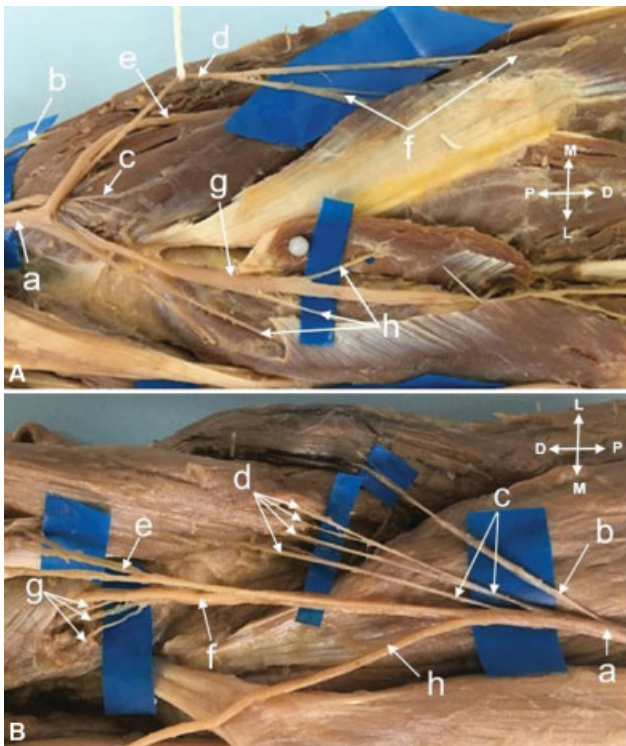


Fig. 4 A - Radial nerve (a); branches to BR (b); branch to ECRL (c); branch for ECRB (d); SBRN (e); motor points of the ECRB (f); PIN (g); branch to SM (h). B - Radial nerve (a); branches BR (b); branches to ECRL (c); ECRB motor points (d); branch to ECRB (e); PIN (f); branches to SM (g); SBRN (h).




Fig. 6 A - PIN (a); arcade of Frohse (b); SBRN (c); branch to the ECRB (d). B - branches to the MS (a); PIN (b); arcade of Frohse (c).

Table 1 Summary of the number of motor points of the muscles innervated by the radial nerve in the proximal, middle and distal thirds of the forearm

Muscle	1 motor point	2 motor points	3 motor points	4 motor points	5 motor points	Average motor points
Brachioradialis	10	16	4	—————	—————	2.4 ± 0.8
Extensor carpi radialis longus	7	17	5	1	—————	2.9 ± 1.0
Extensor carpi radialis brevis	3	12	10	5	—————	2.7 ± 1.2
Supinator	—————	4	16	7	3	3.4 ± 0.9

Discussion

Our results are in agreement with those of some authors,^{7–11} who report that the order of innervation of the forearm muscles by the RN is very variable. In the present study, we observed that the branch from the RN to the BR detached from the RN proximally to its division into the SBRN and PIN. The branches to the ECRL detached from the RN proximally to its division into 26 limbs, in 2, at the point of division, in 2 others, to the PIN. We did not identify the division of the RN distally to the IHL.

Abrams et al.⁸ studied 20 limbs from cadavers and identified more than 1 branch to the BM in 10 limbs. In 8 of these 10 limbs, the innervation of the BM occurred proximally in relation to the BR. Sunderland⁷ observed that, in 18 of 20 limbs, the BM received radial innervation. Our findings were different: we identified that in only 4 out of 30 limbs there was 1 branch of the RN to the BM, all of them proximal to the branches destined to the BR muscle.

Fuss and Wurzl¹⁰ studied 50 cadaver limbs and recorded that the BR muscle received 1 branch in 22 limbs, 2 branches in 12 limbs, and 3 branches in 16 limbs. In the present study, the first branch of the RN to the forearm muscles was to the BR muscle in all limbs. We identified only 1 branch in 23 limbs, 2 branches in 7 limbs, and we did not identify more than 2 branches to the BR. The reason for the discrepancy must have occurred due to the way of interpreting. We considered the number of branches that detached from the RN: those that branched out after their origin, forming several motor points, were considered as a single branch (► **Figure 4B**). Fuss and Wurzl¹⁰ also report that sometimes branches to the BR detached from the RN from a common trunk with branches to the BM or ECRL.

Branovacki et al.¹¹ dissected 60 limbs from cadavers, and reported that the BR was the first forearm muscle to be innervated in 42 limbs (70%); in 12 (20%), the innervation of the BR and ECRL originated at the same point; in 6 (10%), the branch to the ECRL originated proximally to that of the BR. In the present study, we identified in 6 limbs (20%) that the BR and ECRL originated from a common trunk. We did not identify, however, the ECRL innervated before the BR in any limb. Fuss and Wurzl¹⁰ reported an extremely rare case in which a branch to the BR carried motor and sensory fibers: the motor fibers penetrated the BR, and the sensory ones joined the SBRN.

Regarding the ECRL muscle, Fuss and Wurzl¹⁰ reported that they identified 1 branch in 22 limbs, 2 branches in 14, and 3 branches in 12 limbs. Our findings were divergent: we identified 2 branches only in 9 limbs; in the remaining 21, there was only 1 branch to the ECRL. The reason behind such different results must have been the way of interpretation, as occurred in relation to the branches to BR muscle. There are widely divergent conclusions regarding the origin of the branch to the ECRB. The origin in the RN itself, the SBRN, or the PIN has been described. The differences in incidence found in the literature are significant.⁸

Salsbury¹² dissected 50 limbs and stated that the innervation came from the SBRN in 56%, from the PIN in 36%, and from the point where the PIN and SBRN branch out in 8%. Cricenti et al.¹³ dissected 30 limbs and found the origin of the ECRB in the PIN in 28 (93%) limbs, and in the SBRN in 2 (7%) limbs. Nayak et al.¹⁴ reported that they dissected 72 limbs from cadavers and found that the branch destined to the ECRB originated in the RN in 11 limbs (15.2%), in the PIN in 36 limbs (50%), and in the SBRN in 25 limbs (34.7%). Abrams et al.⁸ recorded the origin of the ECRB in the PIN in 45%, in the SBRN in 25%, and in the RN in 30% of the limbs. Branovacki et al.¹¹ recorded the origin of the ECRB in the PIN in 45%, in the SBRN in 25%, and in the bifurcation of the SBRN and PIN in 30% of the limbs.

We agree with the explanation provided by Abrams et al.,⁸ that the discrepancies among studies can be explained by the inconsistency of dissection and measurement techniques. The ECRB branch is often a set of separate fascicles, but adherent to the SBRN or the PIN. Variation may occur depending on how much the nervous branch is proximally dissected before the measurement⁸ (► **Figure 5B**). We identified the origin of the ECRB in the PIN in 14 limbs (46.5%), in the SBRN in 12 (40%), and in the RN only in 4 (13.5%) limbs, and, in 3 of these, at the same point in which the RN divides into the PIN and SBRN, and, in another, the origin was proximal to the division of the RN.

Branovacki et al.¹¹ identified more than 1 branch to the SM in 73% of the limbs, and, Cricenti et al.,¹³ in 87%. In the present study, we identified two to five branches to the SM, with at least one branch destined to each of the superficial and deep heads, all originating in the PIN. Although Sunderland⁷ reported in his series that 20% of the branches to the SM originated from the RN, this was not observed in the present

Table 2 Summary of the mean distribution of motor points in the extension of the muscular body

Muscle	Average motor points	Proximal third of the muscle n (%)	Proximal and middle thirds n (%)	Distal third n (%)	Full extension of the muscular body n (%)
Brachioradialis	2.4 ± 0.8	30 (100%)	_____	_____	_____
Extensor carpi radialis longus	2.9 ± 1.0	30 (100%)	_____	_____	_____
Extensor carpi radialis brevis	2.7 ± 1.2	17 (56.5%)	13 (43.5%)	_____	_____
Supinator	3.4 ± 0.9	6 (20%)	19 (63.5%)	_____	5 (16.5%)

study. We agree with Spinner² and Liu et al.⁴ that the branches to the SM originated from the PIN. Bradovaki et al.¹¹ observed that in 12% of the limbs the branches to the SM detached from the PIN inside the muscle mass of the SM, and the authors reported that this variation, as far as they were aware, had not been previously reported. We identified this variation in 7 (23%) limbs (► **Figure 6A** and **6B**).

We analyzed the number of motor points of the BR, ECRL, ECRB and SM muscles, which are defined as entry points of the nerve branches into the muscular body. We recorded that most motor points are located in the proximal third of the muscles (► **Table 2**).

Segal et al.¹⁵ suggested the relationship between the number of motor points and neuromuscular compartments. Each motor point corresponds to a neuromuscular compartment with a function independent from other compartments. This explains why muscles with more complex functions, such as flexors and finger extensors have a greater number of motor points compared to other forearm muscles.¹⁶ Knowledge of the location of nerve branches and motor points facilitates the insertion of electrodes in the motor points of the forearm muscles for functional electrical stimulation in lesions to the upper motor neurons.³ The information in the present study can also be applied usefully in selective denervation procedures to balance spastic muscles.^{4,11}

Liu et al.⁴ reported that forearm injuries, although the main nerve trunks may be intact, segmental crush injuries will damage muscles by direct muscle damage or damage to their motor points.

Fuss and Wurzl¹⁰ reported that the attempt to correlate clinical signs and symptoms with surgical anatomy may cause some confusion because of the controversies regarding the innervation sequence recorded in the literature. For example, the sequences described by Clara¹⁶ (BM; BR; ECRL; ECRB; SM; and ECRL) and by Roseinstein¹⁷ (BR; ECRL; SM, extensor digitorum communis (EDC); and ECRB) may be criticized because they suggest that each muscle does not receive more than a single branch, and that there is a logical sequence of branches. We recorded that in most of our cases the sequence of motor branches was: BM; BR; ECRL; ECRB; PIN; and branches to the SM. However, in two limbs the branch to the ECRL originated from the PIN; in four, the branch to the ECRB originated from the RN; in three of these,

at the same point the RN divides into SBRN and PIN, and only one was proximal to the division. In six limbs, the branches to the BR and ECRL originated from a common trunk; in seven limbs, we identified more than one branch to the BR; and, in nine limbs, more than one branch to the ECRL. We agree with Fuss and Wurzl¹⁰ that the sequence reported by Rosenstein¹⁷ is very difficult to occur.

We suggest that the surgical approach to the branches of the RN in the elbow region can be performed with the forearm in pronation and the elbow in extension. The incision should have approximately 13 cm in length, starting from a point 3 cm proximal to the lateral epicondyle, accompanying the axis of the radius. We incise the fascia in the distal region of the arm and forearm and identify the space between the brachial and brachioradial muscles. Deepening the dissection in this space enables the identification of the RN with the branches to the BM, BR, ECRL and ECRB. The space between the ECRB and the EDC is more distally identified. The dissection is deepened in this space, enabling the identification of the SM and the arcade of Frohse. The PIN, proximally to the arcade of Frohse, can be identified by palpation against the diaphysis of the radius. The superficial head of the SM should be sectioned, following the path of the PIN, thus exposing the intramuscular portion of the PIN and the branches destined to the SM.

Conclusion

Knowledge of the anatomy of the RN branches to the forearm muscles is important when performing surgical procedures in the region (such as the approach of the proximal third and head of the radius, the release of compressive syndromes of the radial tunnel and PIN, and distal nerve transfers) in order to understand the order of recovery of muscle function after a nerve injury. Our data show the variability in that region.

Conflict of Interests

The authors have no conflict of interests to declare.

References

- Vergara-Amador E, Ramírez A. Anatomic study of the extensor carpi radialis brevis in its relation with the motor branch of the radial nerve. *Orthop Traumatol Surg Res* 2015;101(08):909–912

- 2 Spinner M. The arcade of Frohse and its relationship to posterior interosseous nerve paralysis. *J Bone Joint Surg Br* 1968;50(04):809–812
- 3 Safwat MD, Abdel-Meguid EM. Distribution of terminal nerve entry points to the flexor and extensor groups of forearm muscles: an anatomical study. *Folia Morphol (Warsz)* 2007;66(02):83–93
- 4 Liu J, Pho RW, Pereira BP, Lau HK, Kumar VP. Distribution of primary motor nerve branches and terminal nerve entry points to the forearm muscles. *Anat Rec* 1997;248(03):456–463
- 5 García-López A, Fernández E, Martínez F. Transfer of brachioradialis motor branch to the anterior interosseous nerve in C8-T1 brachial plexus palsy. An anatomic study. *Microsurgery* 2013;33(04):297–300
- 6 Bertelli JA, Ghizoni MF. Nerve transfers for restoration of finger flexion in patients with tetraplegia. *J Neurosurg Spine* 2017;26(01):55–61
- 7 Sunderland S. Metrical and non-metrical features of the muscular branches of the radial nerve. *J Comp Neurol* 1946;85:93–111
- 8 Abrams RA, Ziets RJ, Lieber RL, Botte MJ. Anatomy of the radial nerve motor branches in the forearm. *J Hand Surg Am* 1997;22(02):232–237
- 9 Linell EA. The distribution of nerves in the upper limb, with reference to variabilities and their clinical significance. *J Anat* 1921;55(Pt 2-3):79–112
- 10 Fuss FK, Wurzl GH. Radial nerve entrapment at the elbow: surgical anatomy. *J Hand Surg Am* 1991;16(04):742–747
- 11 Branovacki G, Hanson M, Cash R, Gonzalez M. The innervation pattern of the radial nerve at the elbow and in the forearm. *J Hand Surg [Br]* 1998;23(02):167–169
- 12 Salsbury CR. The nerve to the extensor carpi radialis brevis. *Br J Surg* 1938;26(101):95–97
- 13 Cricenti SV, Deangelis MA, Didio LJA, Ebraheim NA, Rupp RE, Didio AS. Innervation of the extensor carpi radialis brevis and supinator muscles: Levels of origin and penetration of these muscular branches from the posterior interosseous nerve. *J Shoulder Elbow Surg* 1994;3(06):390–394
- 14 Nayak SR, Ramanathan L, Krishnamurthy A, et al. Extensor carpi radialis brevis origin, nerve supply and its role in lateral epicondylitis. *Surg Radiol Anat* 2010;32(03):207–211
- 15 Segal RL. Neuromuscular compartments in the human biceps brachii muscle. *Neurosci Lett* 1992;140(01):98–102
- 16 Clara M. Das nervensystem des menschen. 3rd ed. Leipzig: Barth; 1959
- 17 Rosenstein A. Anatomie der peripheren nerven. In: Bumke O, Foerster O, editors *Handbuch der neurologie*. Berlin: Springer; 1935