

Tuberculosis of Sphenoid Sinus: Report of Two Cases

Vadisha Srinivas Bhat¹ Samatha K.J.¹ Devika T.¹ Shrinath D. Kamath P.¹ Rajeshwary Aroor¹
Satheesh Kumar Bhandary B.¹

¹Department of Otorhinolaryngology, K.S. Hegde Medical Academy, Deralakatte, Mangalore, Karnataka, India

Address for correspondence Vadisha Srinivas Bhat, MS, DNB, Department of Otorhinolaryngology, K.S. Hegde Medical Academy, Deralakatte, Mangalore, Karnataka 575018, India (e-mail: bvadish@yahoo.co.in).

J Health Allied Sci^{NU} 2020;10:42–45

Abstract

Keywords

- ▶ tuberculosis
- ▶ sphenoid sinus
- ▶ endoscopic sinus surgery
- ▶ antituberculosis treatment

Isolated lesions of the sphenoid sinus are uncommon and difficult to diagnose. In the absence of characteristic clinical findings, the diagnosis of such lesions depends mainly on imaging. However, as radiological appearance cannot provide the clinician with a definite diagnosis, histopathological examination of the specimen is mandatory for the diagnosis. Endoscopic sinus surgery has been an excellent approach for diagnosis as well as treatment of isolated sphenoid sinus lesions. The disease can be effectively treated by antituberculosis treatment. We report two cases of tuberculosis involving the sphenoid sinus only.

Introduction

Tuberculosis is a public health concern worldwide, and 80% of the total burden is borne by 10 countries with India (26%) leading the count. In 2017, the World Health Organization (WHO) gave an estimated incidence of 1,339 million cases for India.¹ However, tuberculosis of paranasal sinuses was unusual even in the countries with a high prevalence of the disease. The involvement of sphenoid sinus by tuberculosis is a rarity. Isolated sphenoid sinus lesions account for only 2.7 to 3% of the pathologies of the paranasal sinuses; the pathologies common are inflammatory, fibro-osseous, neoplastic, and fungal. Finding the tuberculosis pathology in the inflammatory category is most often by chance. Due to vague and nonspecific symptoms, most of these patients are treated by other specialists before being referred to otolaryngologists, usually after imaging.² A definite diagnosis of the tuberculosis of sphenoid sinus can be made only after the histopathological examination of a biopsy specimen obtained by endoscopic sphenoidotomy.

Case 1

An 18-year-old adult male presented with a history of diplopia and restricted movements of the right eye for 1 month. He also had a right-sided frontal headache. On examination, the nasal septum was deviated to the left. A provisional diagnosis

of superior orbital syndrome of the right side was made. Ophthalmological examination showed right abducent nerve palsy, and ophthalmoscopy showed cupping of the disc in both eyes. Computed tomography scan of the paranasal sinus revealed the destruction of the posterior wall of the sphenoid sinus with mucosal thickening (▶ Fig. 1).

Magnetic resonance imaging (MRI) of brain with contrast showed mucosal thickening in both sphenoid sinuses with an ill-defined enhancing lesion involving the sella and adjacent skull base, with the involvement of bilateral cavernous sinuses with bony destruction (▶ Fig. 2A–C).

Endoscopic sphenoidotomy was done, which showed a friable lesion in the left sphenoid sinus. Partial debridement of the lesion was done, and the tissue was sent for histological examination. Histopathology showed features of caseating granulomatous lesion suggestive of tuberculosis. The chest X-ray was normal. The patient was treated with antituberculosis drugs: directly observed treatment, short-course (DOTS)—category 1 for 6 months, which comprised of intensive phase for 2 months consisting of isoniazid, rifampicin, pyrazinamide, and ethambutol, followed by 4 months of continuation phase consisting of isoniazid, rifampicin, and ethambutol. The patient was symptom-free on second month of follow-up. On follow-up after 1 month, eye movements were normal. Review MRI showed a regression of the lesion (▶ Fig. 3A, B).

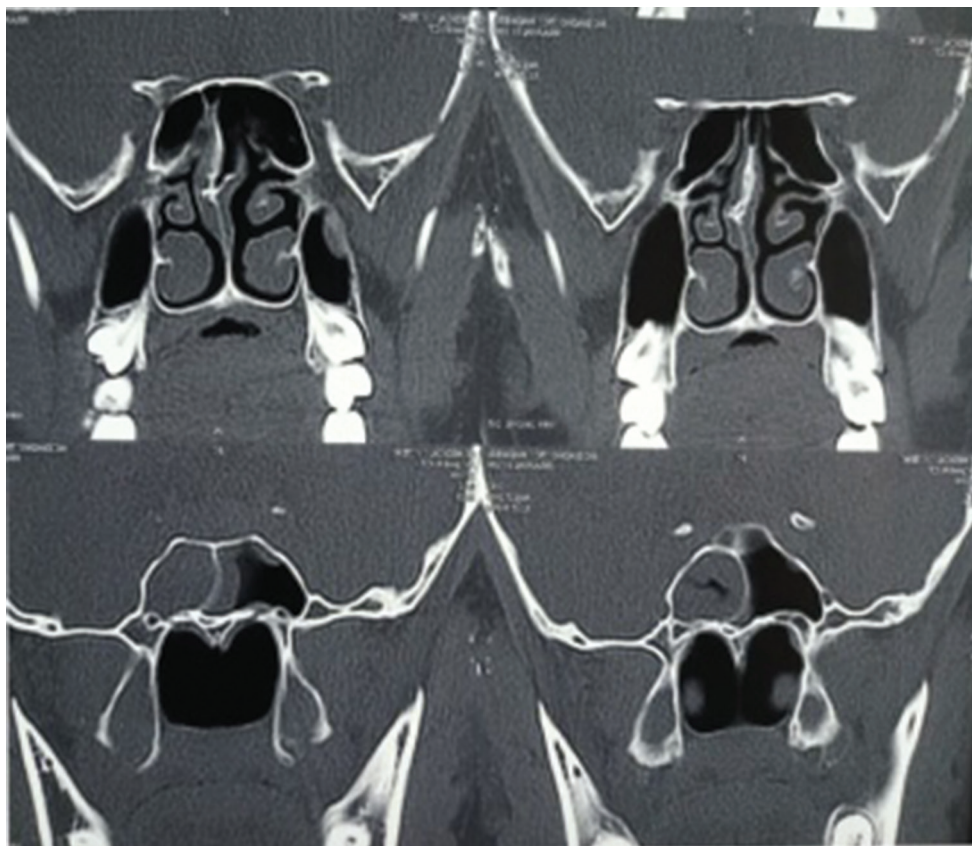


Fig. 1 Coronal computed tomography of paranasal sinuses showing mucosal thickening in the sphenoid sinus.

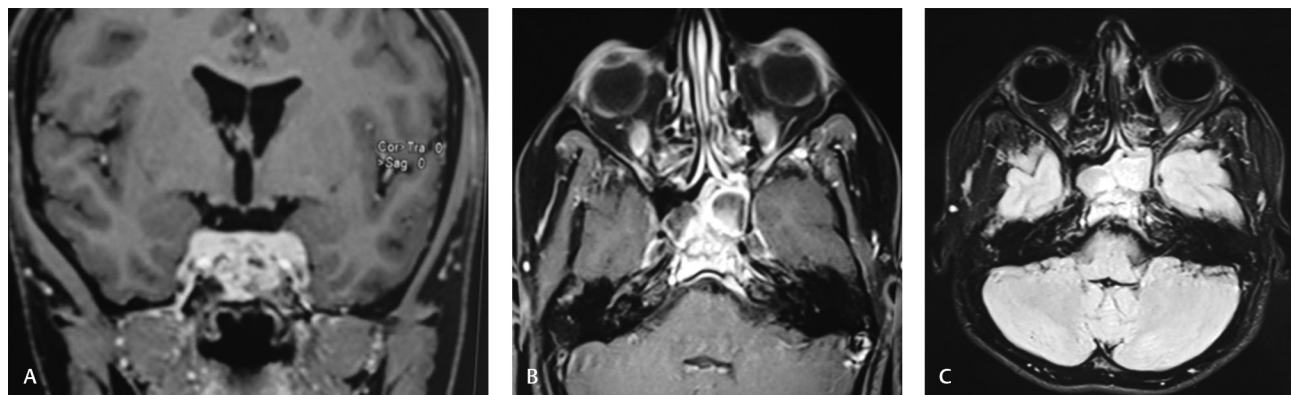


Fig. 2 (A–C) Coronal and axial magnetic resonance imaging scan showing ill-defined enhancing lesion involving the sella and adjacent skull base, with the involvement of bilateral cavernous sinuses with bony destruction.

Case 2

A 47-year-old male presented with complaints of a persistent, progressive headache for 1 year, which was not localized. There was progressive anosmia, occasional watery nasal discharge. Diagnostic nasal endoscopy did not show any significant abnormality. MRI showed a large soft tissue component with hemorrhagic foci within sphenoid sinuses extending to bilateral cavernous sinuses (→**Fig. 4A, B**). Differential diagnosis of fungal sinusitis, lymphoma, or mucocele was made.

Endoscopic sphenoidotomy was performed for obtaining tissue for histopathology. Histopathological features were suggestive of granulomatous necrotizing sinusitis consistent

with tuberculosis. The patient was treated with category I antituberculosis therapy for 6 months, which comprised of intensive phase for 2 months consisting of isoniazid, rifampicin, pyrazinamide, and ethambutol and 4 months of continuation phase consisting of isoniazid, rifampicin, and ethambutol. The patient was symptom-free on the second month of follow-up.

Discussion

The tuberculosis of paranasal sinus is extremely rare. Morgagni in 1761 reported the first case of paranasal sinus

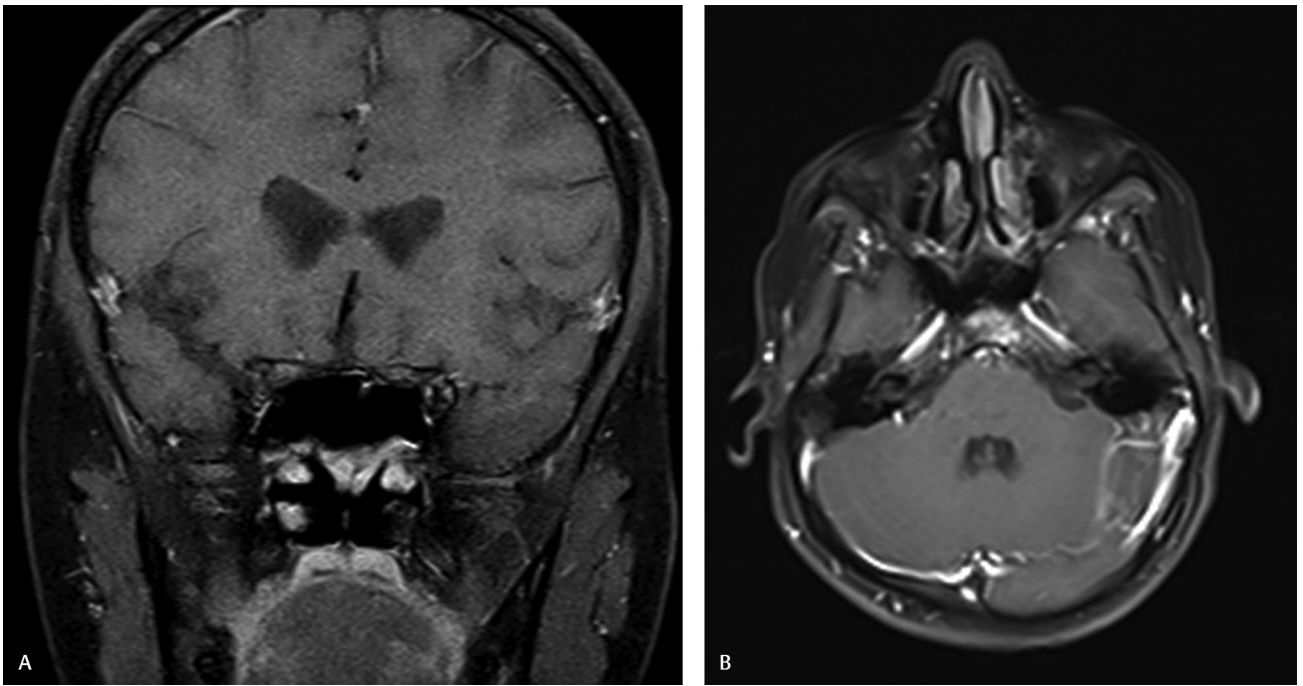


Fig. 3 (A, B) Axial and coronal magnetic resonance imaging showing regression of lesion after 1 month of treatment.

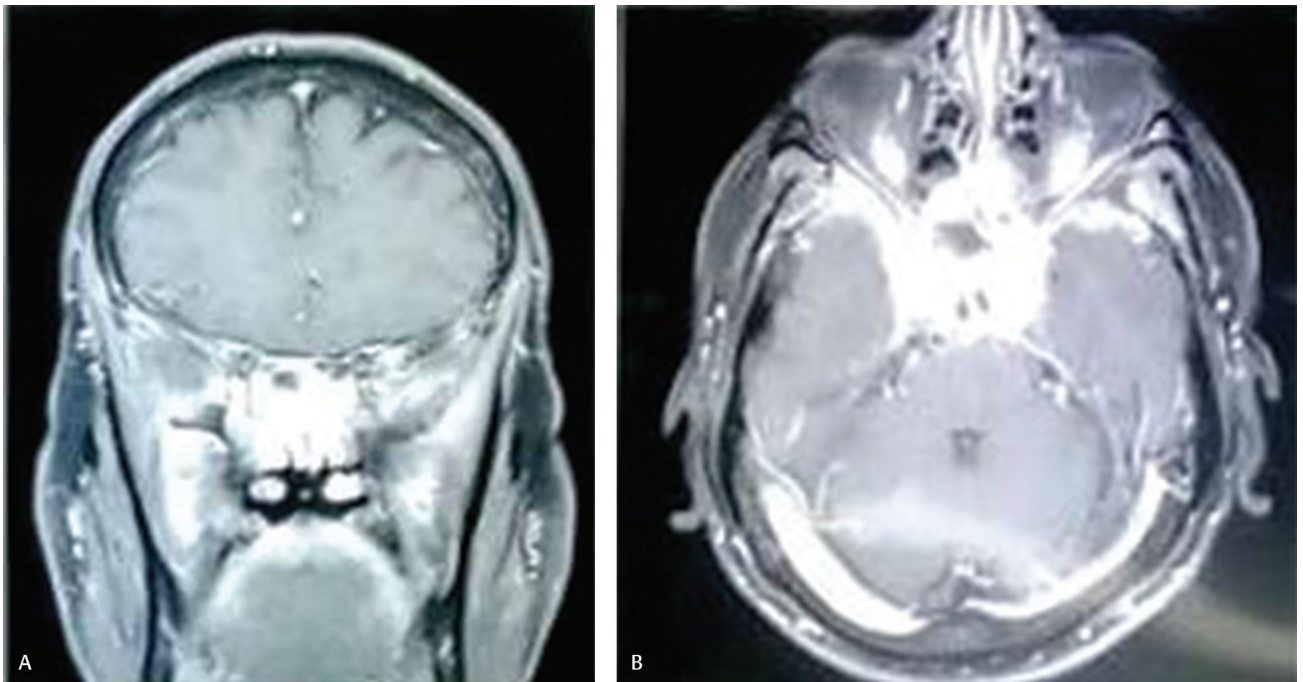


Fig. 4 (A, B) Coronal and axial magnetic resonance imaging of case 2, showing ill-defined enhancing lesion within sphenoid sinuses extending to bilateral cavernous sinuses.

tuberculosis.³ Maxillary and ethmoid sinuses more commonly affected by tuberculosis than the sphenoid sinuses.⁴ Kernan reported the first case of tuberculosis originating in the sphenoid sinus.⁵ Clinical presentations of patients with isolated sphenoid sinus disease include headache, nasal obstruction, postnasal drip, visual disturbances, and cranial nerve paresis. The radiological features of sphenoid sinus tuberculosis mimic other inflammatory and neoplastic

lesions such as chordoma, Wegener's granulomatosis, invasive fungal disease, allergic fungal sinusitis, sarcoma, carcinoma, and even metastasis. Sphenoid sinus tuberculosis may be limited to only one site or may be associated with pulmonary, central nervous system, lymph node, and skeletal tuberculosis. In our patient, no other site was involved.

Sharma and Baruah⁶ reported two cases of sphenoid sinus involvement with extension to the cavernous sinus in one and

the posterior ethmoids in the other. Turel and Rajshekhar⁷ also reported a case of sphenoid sinus tuberculosis with the involvement of clivus in an 11-year-old child.

Tuberculosis can be considered as a differential diagnosis for isolated sphenoid sinus lesions, especially in countries where the disease is endemic. The diagnosis is based on histological examination demonstrating granuloma consisting of Langhans' multinucleate giant cells and epithelioid cells associated with areas of caseous necrosis and infiltrate of lymphocytes and plasma cells. Endoscopic sphenoidotomy is the ideal procedure to obtain the tissue for histopathological examination. The disease can be effectively treated with standard antituberculosis drugs, combination therapy with rifampicin, isoniazid, ethambutol, and pyrazinamide.

Funding

None.

Conflict of Interest

None declared.

References

- 1 Global Tuberculosis Report 2018. Geneva: World Health Organization; 2018.
- 2 Sieskiewicz A, Lyson T, Olszewska E, Chlabicz M, Buonamassa S, Rogowski M. Isolated sphenoid sinus pathologies—the problem of delayed diagnosis. *Med Sci Monit* 2011;17(3):CR180–CR184
- 3 Shah NJ, Prashanth V, Garg S, Velimuthan N. Primary tuberculosis of the ethmoid and sphenoid sinuses – a rare entity. *Bombay Hosp J* 2010;52(1):86–89
- 4 Meyerson MC. Tuberculosis of the Ear, Nose, and Throat. In: Coates, Schenck, and Miller. *Otolaryngology*, S. W. F. Prior Co., Hagerstown, Maryland; 1956:5
- 5 Kernan JD. A case of tuberculosis of the sphenoid sinus. *Laryngoscope* 1919;29(5):276–279
- 6 Sharma SC, Baruah P. Sphenoid sinus tuberculosis in children—a rare entity. *Int J Pediatr Otorhinolaryngol* 2003;67(4):399–401
- 7 Turel MK, Rajshekhar V. Sphenoid sinus tuberculosis: a rare cause of visual dysfunction in an adolescent girl. *Neurol India* 2013;61(2):179–180