

Bile Duct Injury—Classification and Prevention

Mukesh Nasa¹ Zubin Dev Sharma¹ Mahesh Gupta¹ Rajesh Puri¹

¹Institute of Digestive and Biliary Sciences, Medanta—The Medicity, Gurugram, India

Address for correspondence Mukesh Nasa, MD, DM (gastroenterology), Institute of Digestive and Biliary Sciences, Medanta—The Medicity, Gurugram, Haryana 122001, India (e-mail: mukeshnasa78@gmail.com)

J Digest Endosc:2020;11:182–186

Abstract

Keywords

- ▶ bile duct injury
- ▶ cholecystectomy
- ▶ anatomical variation
- ▶ early recognition
- ▶ endoscopic management

Iatrogenic bile duct injuries (BDI) are commonly encountered after laparoscopic cholecystectomy. Timely recognition of these injuries is important as the outcome depends on the optimal management and there is significant impact on the patient's quality of life. Therapeutic management is guided by the type and extent of the bile duct injury and availability of expertise, and includes involvement of endoscopic, surgical, and radiological approaches.

Introduction

Bile duct injuries (BDIs) commonly occur after laparoscopic cholecystectomy and these are the cause of increase in post procedure morbidity with significant impact on the quality of life. Gastroenterologists are usually called in to manage such complications. Laparoscopic cholecystectomy, which has become a gold standard for gall stone disease over the years, is responsible for 80 to 85% of these injuries.¹ BDIs are more frequent during laparoscopic cholecystectomy compared with an open procedure (0.3% open vs. 0.6% laparoscopic)² and are mostly recognized postoperatively as bile leak and biliary obstruction.^{3,4} Despite the improvement in the surgical techniques for the laparoscopic cholecystectomy and the institution of preventive methods, the overall incidence of bile duct injuries have remained unchanged. With increasing costs of medical care, complications like bile duct injuries not only significantly add to the cost of management along with mental and physical stress on the patient, but are also one of the reasons for many medicolegal litigations. Early recognition of BDIs is important as timely management improves the postoperative outcome. The current review is to revisit the different classification systems to classify bile duct injuries and identifying the preventive factors to decrease its incidence

Classification of Bile Duct Injuries

Several classifications of bile duct injuries have been proposed over a period of time and these are based on different parameters like the site of injury relative to the biliary confluence, associated vascular injury, whether there is tangential or circumferential injury to the bile duct, and the mechanism of injury. These are as follows:

1. Bismuth–Corlette classification: This classification system is based on distance of site of injury from hepatic hilum, the level of injury, and the involvement of biliary bifurcation and right sectoral duct. The main basis of this classification is the length of proximal biliary stump which is the most important factor in determining the nature of biliary repair that can be done⁵ (▶ Fig. 1).

The advantages of this classification are as follows:

- This classification provides essential information on the nature, risks, and prognosis after the repair.
- There is an established correlation between the types of injury and the morbidity, mortality, success, and recurrence rates after repair and it also correlates with the cholangiographic appearances.

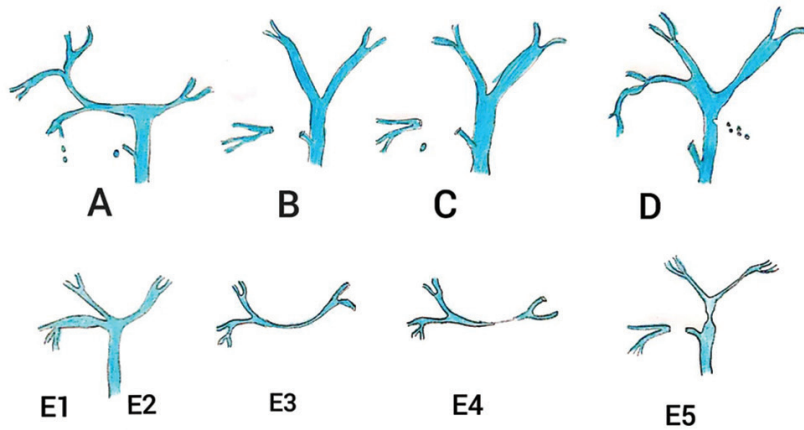


Fig. 1 Bismuth's classification of bile duct injuries.

The disadvantages of this classification are as follows:

- This classification was introduced before the era of laparoscopic cholecystectomy; therefore, it is difficult to apply this classification system in laparoscopic cholecystectomy as most of the technical factors and mechanisms of BDI in laparoscopic interventions are completely different to open surgery.
 - This classification does not include the length of BDI and has not included associated vascular injuries.
2. Strasberg–Bismuth classification (1995): This classification system was proposed with modification of the Bismuth classification and it includes some of the injuries commonly encountered during laparoscopic cholecystectomy, such as bile leaks. Type E is an analogue of the Bismuth–Corlette classification. The major disadvantage of this classification is that it does not describe vascular involvement, and right and left partial injuries are not included in this classification. Despite the fact that the latter are infrequent injuries, it is important for the surgeon to be aware of them to make a proper diagnosis and timely referral⁶ (► Fig. 2).
3. Lau/CUHK classification (2007):

This system of classification was proposed to include vascular injuries and complements the Bismuth classification. Advantages of this classification⁷—are—as—follows:

- The degree of injury is in ascending order of severity.
- The mechanisms of injury differ in each type.
- Preventive measures can be instituted to prevent each type of injury.
- The treatment differs according to the type of injury.

4. The Stewart–Way classification system: This classification system is based on the mechanism and anatomy of bile duct injuries and also includes concomitant vascular injuries.

- CBD is mistaken for cystic duct/cystic duct incision for intraoperative cholangiogram extends to CBD.
- Lateral injury to common hepatic duct.
- Complete transection of main bile duct, this is the most common injury and includes cystic duct–common hepatic duct junction as well.
- Leak/transaction of right hepatic duct/posterolateral sectoral duct.

Timing of Recognition

Early recognition of bile duct injuries is very important. Intraoperative cholangiography leads to early recognition and immediate surgical repair with best outcomes,⁸ but not all surgeons perform IOC. If BDI is suspected during cholecystectomy and the surgeon lacks expertise in biliary repair, intra-abdominal drain should be placed and the patient should be transferred to a center with expertise in hepatobiliary surgeries.

Postoperative recognition of BDIs immediately (within 6 weeks) or later (>6 weeks) depends on clinical presentation. Radiologic investigations in form of ultrasonography, computed tomography and/or magnetic resonance cholangiopancreatography (MRCP) should be done for the confirmation severity and to plan therapeutic strategies. MRCP with a gadolinium-based contrast agent is much more informative in bile leaks than plain MRCP.⁹

Types	Criteria
1	Lower common hepatic duct stricture and length of common hepatic duct stump above the injury is more than 2.0 cm
2	Middle duct stricture and length of hepatic duct stump is usually less than 2.0 cm
3	Hilar or high stricture. There is no serviceable common hepatic duct, but confluence is preserved
4	High or hilar stricture but the difference from type 3 is that the confluence is involved, and there is no communication between right and left hepatic ducts
5	Combined common hepatic and aberrant right hepatic duct injury separating both from the distal biliary tract

Clinical Presentation

Early recognition is crucial for the better postoperative outcome. Mostly recognized post operatively as bile leak and biliary obstructions, bile leak may present as diffuse abdominal pain, nausea, fever, bloating, and anorexia. Patients with stricture at the level of CBD present as classic Charcot's triad of right hypochondrium pain, fever, and jaundice. The short- and long-term complications include intra-abdominal abscess, biliary stricture, recurrent cholangitis, and secondary biliary cirrhosis.³

Risk Factors

There are various risk factors which can be attributed to higher risk of BDI. These factors can be divided into patient-related factors, anatomical abnormalities and technical factors.

1. Patient factors¹⁰-the-various-patient-factors-are-as-follows

- Obesity
- Previous hepatobiliary or pancreatic surgery
- Underlying liver disease

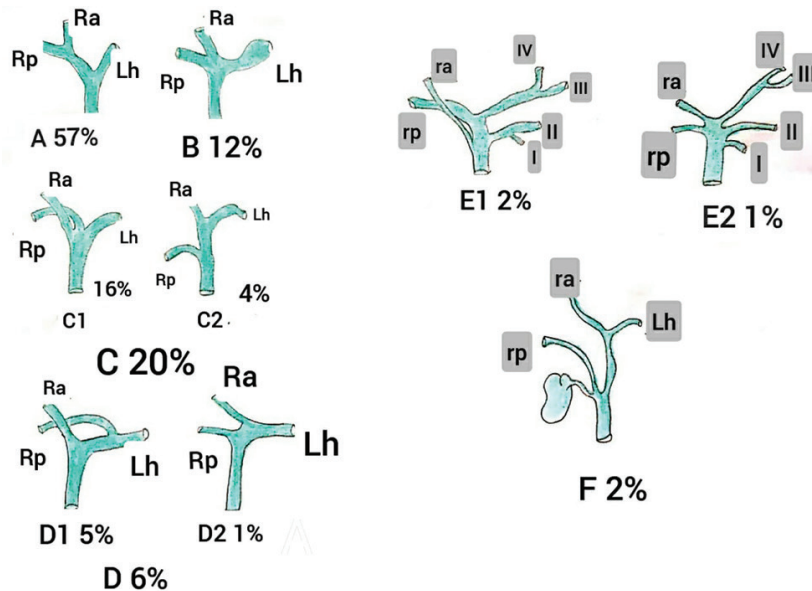


Fig. 2 Anatomical abnormalities of right hepatic duct.

Strasberg–Bismuth classification of bile duct injury	
Types	Criteria
A	Cystic duct leaks or leaks from small ducts in the liver bed
B	Occlusion of a part of the biliary tree, almost invariably the aberrant right hepatic ducts
C	Transection without ligation of the aberrant right hepatic ducts
D	Lateral injuries to major bile ducts
E	Subdivided as per Bismuth's classification types 1–5 as into E1–E5

Type	Criteria
1	Leaks from cystic duct stump or small ducts in liver bed
2	Partial CBD/CHD wall injuries without (2A) or with (2B) tissue loss
3	CBD/CHD transection without (3A) or with (3B) tissue loss
4	Right/left hepatic duct or sectorial duct injuries without (4A) or with (4B) tissue loss
5	Bile duct injuries associated with vascular injuries

Abbreviations: CBD, common bile duct; CHD, common hepatic duct.

2. Anatomical factors: In a retrospective study by Pece et al the main cause of BDI was misinterpretation of biliary anatomy during laparoscopic cholecystectomy.¹¹ Anatomical variations such as short cystic duct, the presence of hepatocystic duct, cystic duct running parallel to the CBD, accessory cystic duct, and the presence of aberrant bile ducts increase the risk of biliary injuries.

The aberrant right hepatic duct anomaly is the common cause of biliary injury. The direction of traction of the gallbladder has been known to contribute to its misidentification and injury¹² (► Fig. 3).

3. Technical factors: The various technical factors are as follows.

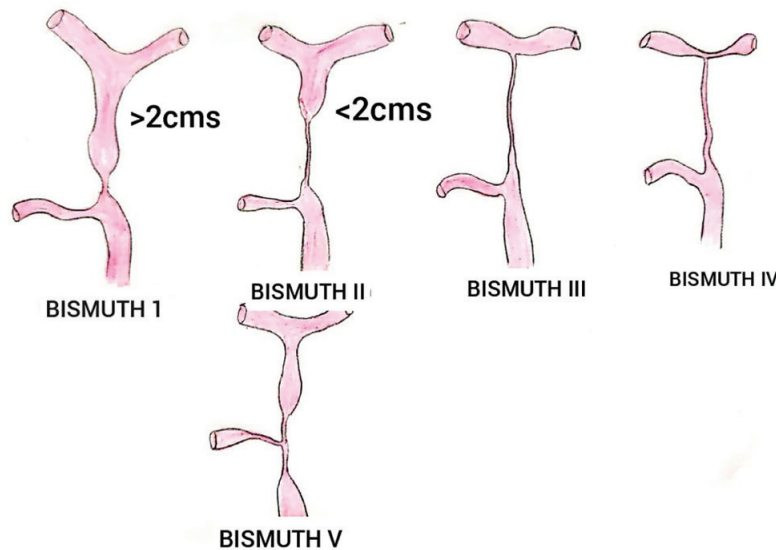


Fig. 3 Strasberg -Bismuth classification.

- Experience: The “learning curve” effect with high rate of injuries with inexperienced surgeons.¹³
- Procedure: Open cholecystectomy is associated with less biliary injuries as compared with laparoscopic cholecystectomy as seen in various studies.
- Timing of surgery: Emergency cholecystectomy has a three times more likelihood of causing biliary injury than elective surgery.¹⁴
- Failure to occlude the cystic duct securely.
- Too deep dissection on the liver bed.
- Thermal injuries.

Management of BDI

The aim of repair is to restore a durable bile conduit and to prevent short- and long-term complications. Strasberg classification is a helpful tool to decide the best intervention for each case according to etiological mechanism of the injury.

- *Strasberg A injury* As injuries maintain continuity with the rest of the bile ducts, they are easily treated through endoscopic intervention. The objective is to decrease intraductal pressure distal to the bile duct leak.
- *Strasberg B injury* Segmental bile duct occlusion is the etiological factor. Percutaneous drainage or surgical resections can be performed when cholangitis is not controlled with medical treatment.
- *Strasberg C injury* No continuity exists with the rest of the bile duct system. Subhepatic collections are frequent post-operatively and must be drained to avoid biliary peritonitis and sepsis.
- *Strasberg D injury* A partial injury of the common bile duct in its medial side characterizes this type. For small injury with no devascularization, monofilament suture is adequate. If there is devascularized duct, a multidisciplinary approach is the best option with endoscopy and radiological guided drainage as the first therapeutic option, and surgical intervention if needed.

- *Strasberg E injury* This injury is a complete loss of common and/or hepatic bile duct continuity. Devascularization and loss of bile duct tissue obliges the surgeon to perform a high-quality hepatojejunal anastomosis, choledochocholedochal or hepaticoduodenal anastomosis, or even more complicated surgeries, if required.

Preventive Measures for Iatrogenic BDI

The preventive measures for iatrogenic BDI are as follows:

- Recognition of biliary and vascular anatomy as cystic duct and artery require division during cholecystectomy, and the aim of dissection is to identify these structures.
- In laparoscopic surgery, techniques used are intraoperative cholangiography, the infundibular technique, and the critical view technique.
- Hunter and Troidl^{15,16} proposed several techniques to prevent injury: a 30° telescope, avoidance of diathermy close to the common hepatic duct, avoiding dissection close to the gallbladder–cystic duct junction, avoidance of unnecessary dissection close to the cystic duct–common hepatic duct junction, and conversion to an open approach when uncertain.
- Sarietal et al¹⁷ proposed injecting methylene blue in the gallbladder after aspirating bile with a Veress needle before starting dissection.
- Avoiding too much traction on gallbladder.
- Avoiding blind use of diathermy and clip.

Conclusion

BDIs commonly occur during laparoscopic cholecystectomy. Despite the improvement in the surgical techniques, the overall incidence of BDIs has remained unchanged. Postoperative early recognition is helpful for the best intervention according

to etiological mechanism of injury. Preventive measures also play a major role in the form of recognition of biliary and vascular anatomy.

Conflict of Interest

None declared.

References

- 1 Karvonen J, Gullichsen R, Laine S, Salminen P, Grönroos JM. Bile duct injuries during laparoscopic cholecystectomy: primary and long-term results from a single institution. *Surg Endosc* 2007;21(7):1069–1073
- 2 Mercado MA, Chan C, Orozco H, Tielve M, Hinojosa CA. Acute bile duct injury. The need for a high repair. *Surg Endosc* 2003;17(9):1351–1355
- 3 Brooks DC, Becker JM, Connors PJ, Carr-Locke DL. Management of bile leaks following laparoscopic cholecystectomy. *Surg Endosc* 1993;7(4):292–295
- 4 Chun K. Recent classifications of the common bile duct injury. *Korean J Hepatobiliary Pancreat Surg* 2014;18(3):69–72
- 5 Bismuth H. Postoperative strictures of the bile ducts. In: Blumgart LH, ed. *The Biliary Tract V*. New York, NY: Churchill-Livingstone; 1982 209–218
- 6 Strasberg SM, Hertl M, Soper NJ. An analysis of the problem of biliary injury during laparoscopic cholecystectomy. *J Am Coll Surg* 1995;180(1):101–125
- 7 Stewart L, Robinson TN, Lee CM, Liu K, Whang K, Way LW. Right hepatic artery injury associated with laparoscopic bile duct injury: incidence, mechanism, and consequences. *J Gastrointest Surg* 2004;8(5):523–530, discussion 530–531
- 8 Stewart L. Iatrogenic biliary injuries: identification, classification, and management. *Surg Clin North Am* 2014;94(2):297–310
- 9 Palmucci S, Mauro LA, La Scola S, et al. Magnetic resonance cholangiopancreatography and contrast-enhanced magnetic resonance cholangiopancreatography versus endoscopic ultrasonography in the diagnosis of extrahepatic biliary pathology. *Radiol Med (Torino)* 2010;115(5):732–746
- 10 Georgiades CP, Mavromatis TN, Kourlaba GC, et al. Is inflammation a significant predictor of bile duct injury during laparoscopic cholecystectomy? *Surg Endosc* 2008;22(9):1959–1964
- 11 Pesce A, Portale TR, Minutolo V, Scilletta R, Li Destri G, Puleo S. Bile duct injury during laparoscopic cholecystectomy without intraoperative cholangiography: a retrospective study on 1,100 selected patients. *Dig Surg* 2012;29(4):310–314
- 12 Hugh TB. New strategies to prevent laparoscopic bile duct injury—surgeons can learn from pilots. *Surgery* 2002;132(5):826–835
- 13 Davidoff AM, Pappas TN, Murray EA, et al. Mechanisms of major biliary injury during laparoscopic cholecystectomy. *Ann Surg* 1992;215(3):196–202
- 14 Russell JC, Walsh SJ, Mattie AS, Lynch JT. Bile duct injuries, 1989–1993. A statewide experience. *Connecticut Laparoscopic Cholecystectomy Registry. Arch Surg* 1996;131(4):382–388
- 15 Hunter JG. Avoidance of bile duct injury during laparoscopic cholecystectomy. *Am J Surg* 1991;162(1):71–76
- 16 Troidl H. Disasters of endoscopic surgery and how to avoid them: error analysis. *World J Surg* 1999;23(8):846–855
- 17 Sari YS, Tunali V, Tomaoglu K, Karagöz B, Güneyi A, Karagöz I. Can bile duct injuries be prevented? A new technique in laparoscopic cholecystectomy. *BMC Surg* 2005;5:14