Article published online: 2020-09-10

Imaging in the Diagnosis of Nonspecific Pyogenic Spondylodiskitis

Christoph Eckhard Heyde[1] Ulrich Josef Albert Spiegl[1] Anna Voelker[1] Nicolas von der Hoeh[1] Jeanette Henkelmann[2]

[1] Department of Orthopedics, Trauma and Reconstructive Surgery, University of Leipzig, Leipzig, Germany
[2] Department of Radiology, University of Leipzig, Leipzig, Germany

J Neurol Surg A Cent Eur Neurosurg 2023;84:69–76.

Address for correspondence Christoph Eckhard Heyde, MD, PhD, Department of Orthopedics, Trauma and Reconstructive Surgery, University of Leipzig, Liebigstrasse 20, Leipzig 04103, Germany (e-mail: ceheyde@aol.com).

Abstract

The prevalence of nonspecific pyogenic spondylodiskitis, associated with both a high morbidity and a high mortality, has increased in the last few decades. The diagnosis is often delayed because of the nonspecific clinical manifestation at the early stage. The reliability of radiographs is limited, particularly in early stage after the onset of infection. Computed tomography (CT) can reliably assess the bony condition with the possibility of spatial visualization. Contrast enhancement supports the detection of affected soft tissue. Magnetic resonance imaging (MRI) continues to be the gold standard in the diagnosis of spondylodiskitis. Sophisticated investigation protocols supported by gadolinium enhancement secure the diagnosis. MRI has a high resolution without radiation exposure. Different nuclear investigation techniques extend the diagnostic options. Reports of 18F-fluorodeoxyglucose-positron emission tomography (18-FDG-PET) are particularly promising to confirm the diagnosis. The drawback of the reduced image quality with respect to detailed anatomical information can be overcome by a combined simultaneous acquisition of CT or MRI. With respect to one of the greatest challenges, the differentiation between degenerative changes (Modic type 1) and infection at an early stage using differentiated MRI protocols and FDG-PET is promising. This overview presents a concise state-of-the-art look at radiologic investigations in case of suspected nonspecific pyogenic spondylodiskitis with the focus on a pragmatic approach.

Keywords
- spondylodiskitis
- spinal infection
- radiologic investigation

Introduction

Nonspecific pyogenic spondylodiskitis is a rare infectious disease, representing 2 to 7% of skeletal infections.[1] However, in the last few decades an increase in the incidence of this disease has been reported. This is due to demographics, improved diagnostic possibilities, and advances in medicine in general.[2–6] In the past, the incidence of pyogenic spondylodiskitis was reported as a ratio of 1:250,000, whereas newer studies reveal an increase up to 5:100,000.[7,8] Men are affected more frequently than women, and the peak age is 60 years of age and older.[9] The lumbar spine is affected most frequently, followed by the thoracic and the cervical spine.[10]

According to the etiopathogenesis as well as clinical findings and imaging results, the condition should be distinguished between diskitis, the isolated infection of the disk; spondylitis, the isolated infection of the vertebral body; and spondylodiskitis, the mixed picture of both entities (►**Fig. 1**). Isolated infections of the disks are mainly found in children related to the still existing vascular supply of the disk and possibly in cases after interventional intradiskal procedures.[11] Isolated spondylitis is commonly seen in specific infections

received
June 10, 2019
accepted after revision
October 21, 2019
article published online
September 10, 2020

© 2020. Thieme. All rights reserved.
Georg Thieme Verlag KG, Rüdigerstraße 14, 70469 Stuttgart, Germany

DOI https://doi.org/10.1055/s-0040-1709168.
ISSN 2193-6315.

This document was downloaded for personal use only. Unauthorized distribution is strictly prohibited.

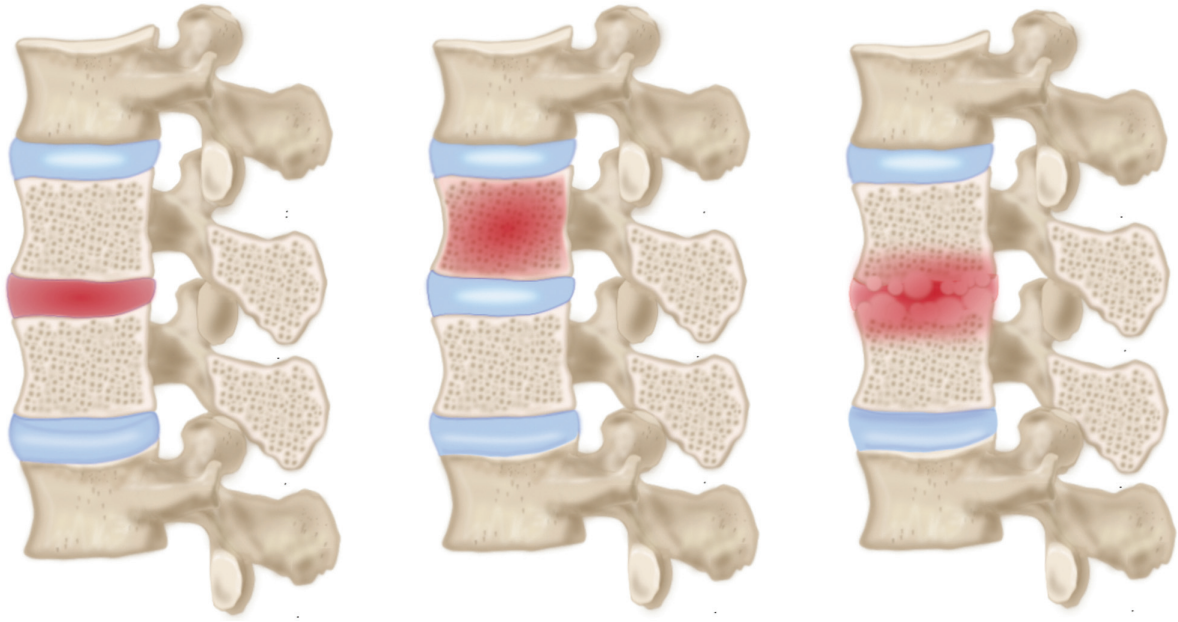

Fig. 1 Schematic drawing of the possible locations of infection of the spine: infection of the intervertebral disk, "diskitis"; infection of the vertebral body, "spondylitis"; and infection of both the vertebral body and the intervertebral disk, "spondylodiskitis."

such as tuberculosis. Spondylodiskitis represents the most common form of nonspecific pyogenic spondylodiskitis.

Abscess formation is possible and plays an important role in determining the therapeutic approach. Paraspinal abscesses, mainly located in the psoas muscle (whereby localization is possible everywhere in the surrounding tissue), can often be observed. Intraspinal abscess formation requires attention. It can be a result of spondylodiskitis, of facet joint infection or can be observed as primary abscess without any other infectious focus.[12] The extent and localization can be highly variable, and neurologic impairment must be ruled out in such a situation.

Isolated facet joint infection as a source of a spondylodiskitis is rarely described. However, in the context of an increase of invasive therapeutic procedures, there are an increasing number of reports in the recent literature.[12,13]

One major problem in this context remains the point of definitive proof of the diagnosis. It is well known that early diagnosis of this disease is associated with both better outcomes and more successful nonoperative therapeutic options . In contrast, delayed diagnosis is associated with bony defects, instability, and more concomitant deformities.[1,10,11] In addition, undiagnosed spondylodiskitis can cause secondary infections such as endocarditis. Accordingly, related inflammation should always be proven and treated.[14,15] In this context, a standardized diagnostic protocol including current imaging techniques is mandatory to confirm the diagnosis as early as possible.[14]

Detailed knowledge about the pathogenesis is helpful in the correct interpretation of specific imaging findings. Because the spread of germs is predominantly hematogenic, initial germ colonization takes place in the terminal intravertebral arteries near the subchondral layer. The resulting inflammatory reaction leads to an edema. Infection-caused microinfarctions and local necrosis lead to destruction of the subchondral bone with infection of the adjacent disk. Proteolytic enzymes enhance the destruction of the disk. Additional involvement of the adjacent vertebra and/or the surrounding tissue is possible.[3,9]

In this article we discuss the imaging techniques for the diagnosis of spondylodiskitis and the differential diagnosis of nonspecific pyogenic spondylodiskitis. The focus should be on a feasible and pragmatic approach for the treating clinician.

Radiography

The results of radiographic investigations are often unsatisfactory, based on nonspecific findings and low sensitivity. In the early phase of infection, no specific radiographic findings are commonly visible, and the differentiation to degenerative pathologies (Modic type 1) remains a challenge.[1,10]

These are the earliest typical radiographic signs described in the literature[1,10,16]:

- Loss of definition (irregularity) of the end plates
- Unspecific porotic changes (demineralization) in the subchondral layer
- Suspect changes typically begin anterosuperiorly

In the subacute and chronic phase, various changes such as loss of disk space height, end-plate erosion, bony destruction, reactive sclerosis (►**Fig. 2**), paravertebral soft tissue mass, defects, and resulting deformity can be observed. The degree of these changes depends on the progression of the disease and the treatment course.[15–18]

Plain radiographs, particularly in the standing position, are often used as a first overview in patients with persistent back pain. In case of spondylodiskitis, typical findings as

 © 2020. Thieme. All rights reserved.

This document was downloaded for personal use only. Unauthorized distribution is strictly prohibited.

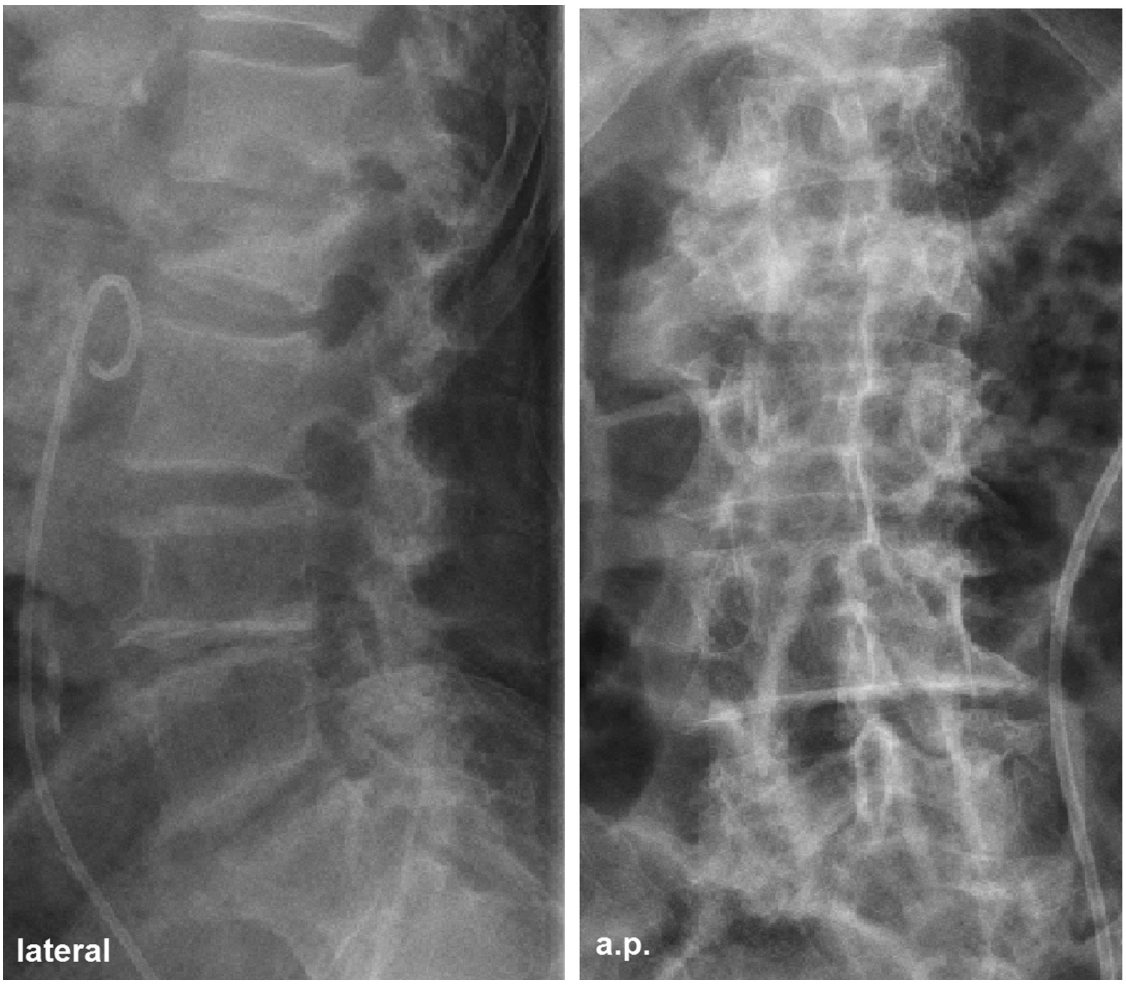

Fig. 2 Lateral and anteroposterior radiograph of the thoracolumbar spine with advanced destruction of end plates and disk in level L1–L2 in a 78-year-old male patient. A ureter splint is shown at the side.

mentioned appear later during the course of the disease. Thus this investigation is helpful for a differential diagnosis. In addition, plain radiographs are recommended to evaluate both the alignment in the sagittal and the coronal plane, and the degree of destruction.[19] Thus mechanical stability can be estimated.[20] However, the main problem of radiographs remains the delay of imaging findings in relation to the clinical course of 2 to 8 weeks after onset of infection.[1,10,16]

Computed Tomography

Computed tomography (CT) is very useful to evaluate the extent of bony changes such as end-plate erosion, sequestra, bone defects, reactive sclerosis, and reactive ossification as shown in ►**Fig. 3**.[1,10]

Contrast-enhanced CT enables improved assessment of affected soft tissue paravertebrally. Surrounding swellings and thickenings of the paravertebral fat tissue, increased enhancement and abscess formation, typically in the psoas muscle, should be sought. Gas inclusions are suggestive of inflammatory soft tissue infection. Even if intraspinal changes in CT are difficult to detect, epidural abscesses should be screened for specifically.

CT can detect bone changes earlier than radiographs. Preexisting osteochondritic changes can complicate the identification of spondylodiskitis. Intradiskal gas as a vacuum phenomenon and well-defined sclerosis of the end plates without bone resorption can primarily be observed in degenerative intervertebral disks.

Multiplanar reconstruction techniques and three-dimensional reconstruction techniques allow for a spatial visualization that could be helpful, especially for operative planning.[15,17]

Although CT is more sensitive regarding the previously mentioned changes compared with radiographs, the accompanying radiation exposure needs to be consided.[10] Disadvantages are the limited possibility to evaluate the disk and neural structures.[1]

CT is currently used in those patients where bony destruction is presumed or with a contraindication for magnetic resonance imaging (MRI).[21] Furthermore, if an abscess is present, a CT-assisted puncture can be performed to obtain tissue samples for microbiological diagnostics. In addition, CT is often recommended as the first method for a puncture of suspicious tissue (intervertebral disk, vertebral body) to identify causative germs.[16]

 © 2020. Thieme. All rights reserved.

This document was downloaded for personal use only. Unauthorized distribution is strictly prohibited.

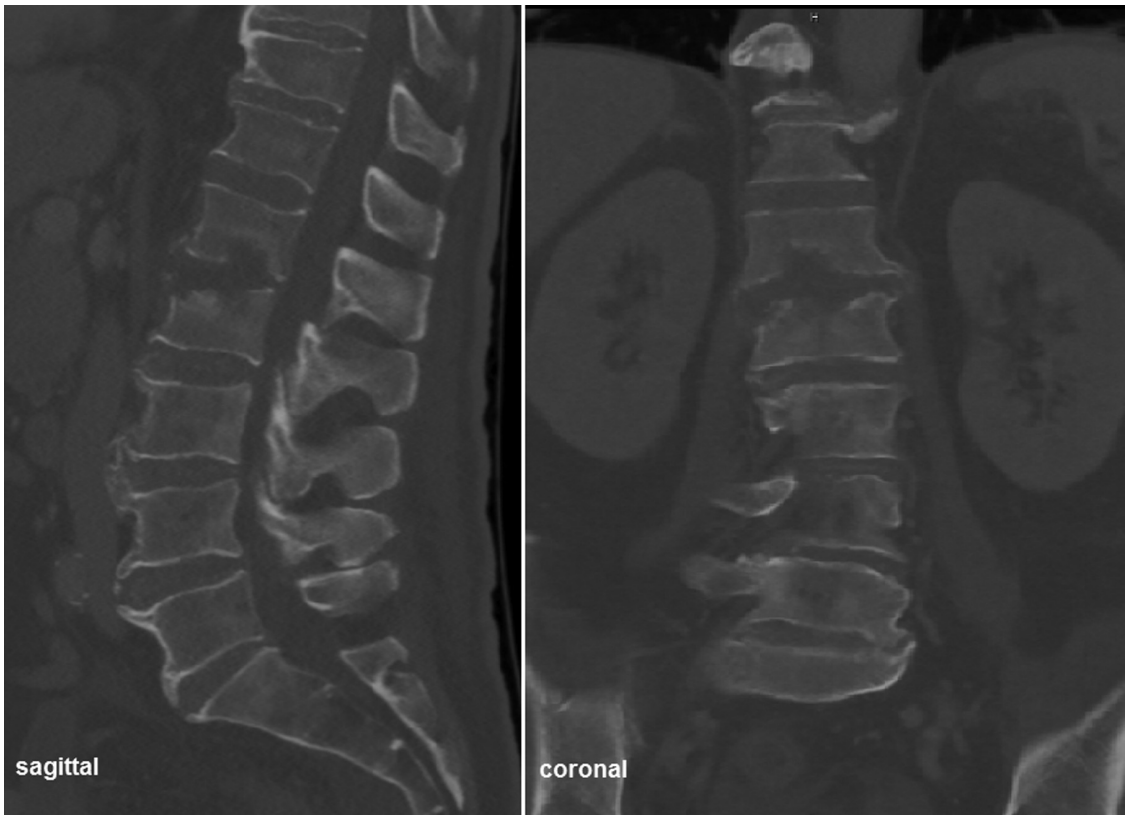

Fig. 3 Computed tomography scan with (left) sagittal and (right) coronal reconstruction. An 83-year-old male patient with pyogenic spondylodiskitis in level L1–L2 with marked erosion of the end plates.

Magnetic Resonance Imaging

MRI has the best sensitivity (up to 96%) and specificity (up to 94%) compared with other imaging techniques.[8,15,16] It provides precise anatomical information: The disk, neural structures, epidural space, and surrounding soft tissue are clearly depicted.[16] High resolution, the ability of multiplanar reconstruction, and the absence of radiation exposure are further advantages of the MRI. Thus MRI is seen as modality of choice to prove spondylodiskitis and accordingly recommended by the Infectious Diseases Society of America.[14,15,18,19]

The classic MRI findings of spondylodiskitis according to the literature are on T2-weighted images hyperintense signal alterations of the disk and the adjacent vertebral bodies with a worse delimitation of the normal intradiskal cleft.[16,18]

Fat-suppressed fluid-sensitive MRI sequences, most commonly short tau inversion recovery (STIR) or turbo inversion recovery magnitude (TIRM), help differentiate bony edema and circumscribed fluid collections from surrounding signal hyperintensity soft tissue (►**Fig. 4a**).

In native T1-weighted sequences, correlated reduced signal intensity can be observed in the adjacent vertebral bodies. Hypointense erosions and the loss of end-plate definition can also be detected (►**Fig. 4b**). In the further course of the disease, a lowering of the disk space height can be observed in all sequences.

Gadolinium enhancement improves the information value in general. The enhancement of the vertebral body, disk, and soft tissue improves the diagnostic accuracy (►**Figs. 4c** and **5**).[16] In MRI, a precise examination of the intraspinal structures is possible. An increased enhancement of the dura and possible epidural fluid collections should be explored (►**Fig. 6**).

In addition to excellent spatial resolution, the advantage of MRI is the differentiation between infectious and degenerative pathologies.[15] However, although MRI usually shows abnormal findings in the initial phase of infection, they do not always suggest spinal infection.[8] Very early findings are nonspecific and prone to misinterpretation. In particular, the differentiation of activated osteochondrosis Modic type 1, which can mimic infections, remains a major challenge. In Modic type 1, bone marrow edema is typically localized in the subchondral region and presents as a sharp margin with a still well-defined vertebral end plate. The degenerated intervertebral disk also has a lower signal in the T2-weighted image in contrast to spondylodiskitis. However, both contrast-enhanced MRI with sophisticated investigation protocols and, if the diagnosis remains uncertain, early follow-up MRI are useful for confirmation of the diagnosis.[11]

According to Leone et al, both the initial edema as well as hyperemia are the earliest signs of inflammation.[15] Thus the diagnosis can be made early in a relatively safe way.[7] Among imaging techniques, MRI is the method of choice to detect spondylodiskitis.[10,22]

Multifocal infection is reported to appear up to a double-digit percentage range. To detect possible multilevel infectious foci, whole-spine MRI protocols are suggested.[23] To gain an overview, for example, STIR-weighted MR images are recommended to detect suspicious areas (►**Fig. 7**). Afterward, these

 © 2020. Thieme. All rights reserved.

This document was downloaded for personal use only. Unauthorized distribution is strictly prohibited.

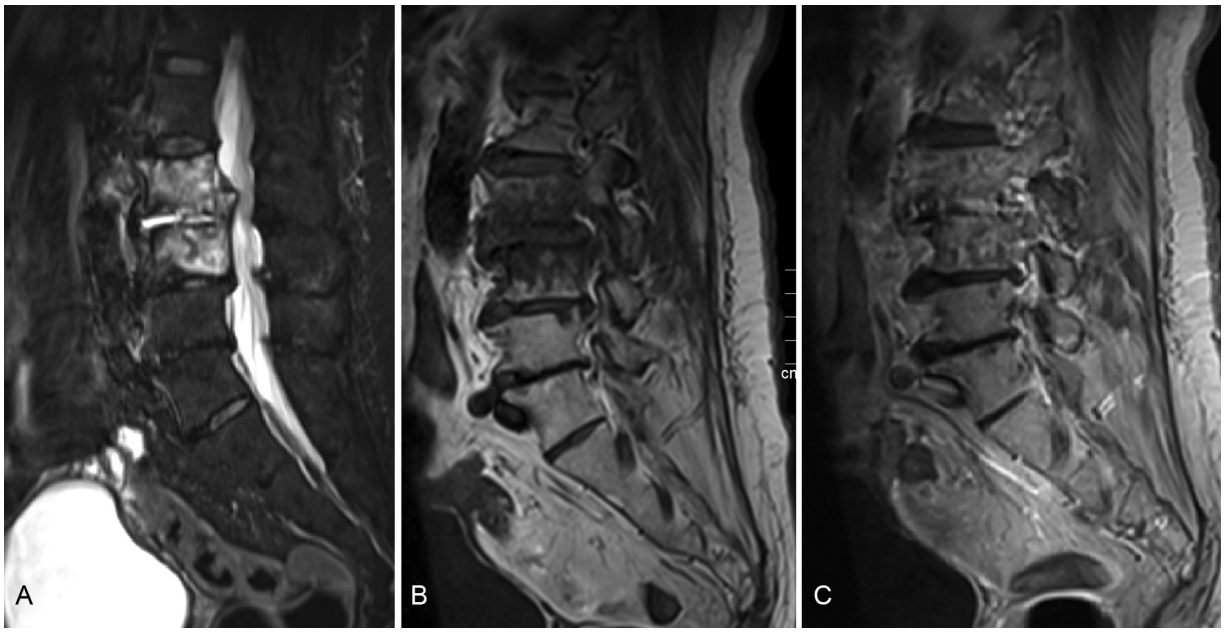

Fig. 4 Sagittal magnetic resonance image of the lumbar spine in a 76-year-old female patient with spondylodiskitis in L2–L3. Typically present are (left) short tau inversion recovery hyperintense, (middle) T1-weighted natively hypointense alterations in the end plates, and the disk with a marked enhancement (right) after contrast (gadolinium) administration.

regions can be evaluated following the usual standardized protocol for detailed information.[23]

Disadvantages of the MRI are the reduced visualization of cortical bone involvement and the rising number of contraindications related to the increasing number of patients with implants who are not suitable for MRI.[15]

Nuclear Medicine

If the radiologic findings are not clear and a persistent suspicion of a spinal infection continues, radionuclide imaging procedures may facilitate the diagnosis. Different techniques and tracers (e.g., technetium-99m-diphosphonates, gallium-67) are available to support the confirmation of the suspected diagnosis.[16] They differ regarding distribution pattern and uptake rate. Thus the sensitivities and specificities vary between the techniques. Combined investigations can improve the diagnostic accuracy in some situations. The addition of three-phase technetium-99m scintigraphy with CT (single-photon emission computed tomography) improves the diagnostic performance by superior localization of the infection. This additionally helps exclude differential diagnoses such as tumor, metastasis, and, in particular, degenerative disorders.[24] The combination of three-phase technetium-99m scintigraphy with gallium-67 scintigraphy or the combination of three-phase technetium-99m scintigraphy with a scan with indium-111 labeled white blood cells are also reported in the literature. Disadvantages are the reduced spatial visualization and the inferiority in detection of an epidural abscess formation.[1,16] Therefore some authors recommend these techniques only if MRI is contraindicated.[1] Others point out the high sensitivity in excluding infection if no uptake takes place.[24]

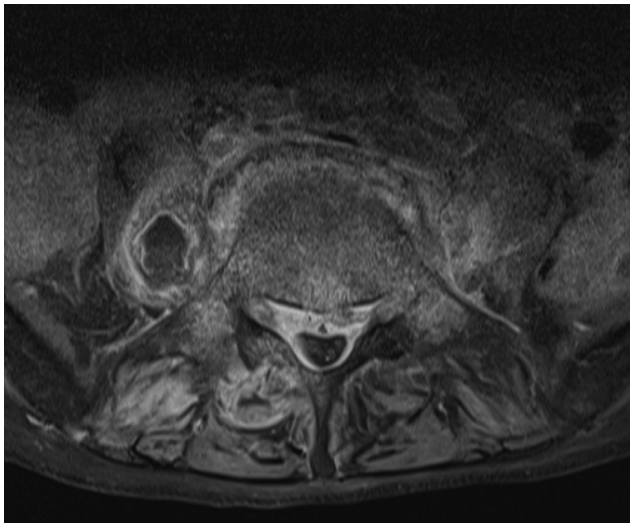

Fig. 5 Axial magnetic resonance image in a 67-year-old male patient with spondylodiskitis in L4–L5. Surrounding thickening of the soft tissue with increased enhancement.

It was found that 18F-fluorodeoxyglucose-positron emission tomography (F18-FDG-PET) is sensitive and allows an examination of the whole body in one session. It was also described as a useful tool to differentiate degenerative from infectious end-plate abnormalities, although the drawback is also the lack of anatomical information.[1,24] To overcome the low spatial resolution, a simultaneous acquisition with CT can be performed with a reported sensitivity up to 95%.[1,24–26] With the recent development of integrated PET/MRI scanners, new possibilities for multimodal molecular imaging have emerged. PET/MRI (►**Fig. 8**) and the application of the so-called one-stop shop principle enable analysis of simultaneously acquired metabolic and morphological parameters with excellent soft tissue definition along

 © 2020. Thieme. All rights reserved.

This document was downloaded for personal use only. Unauthorized distribution is strictly prohibited.

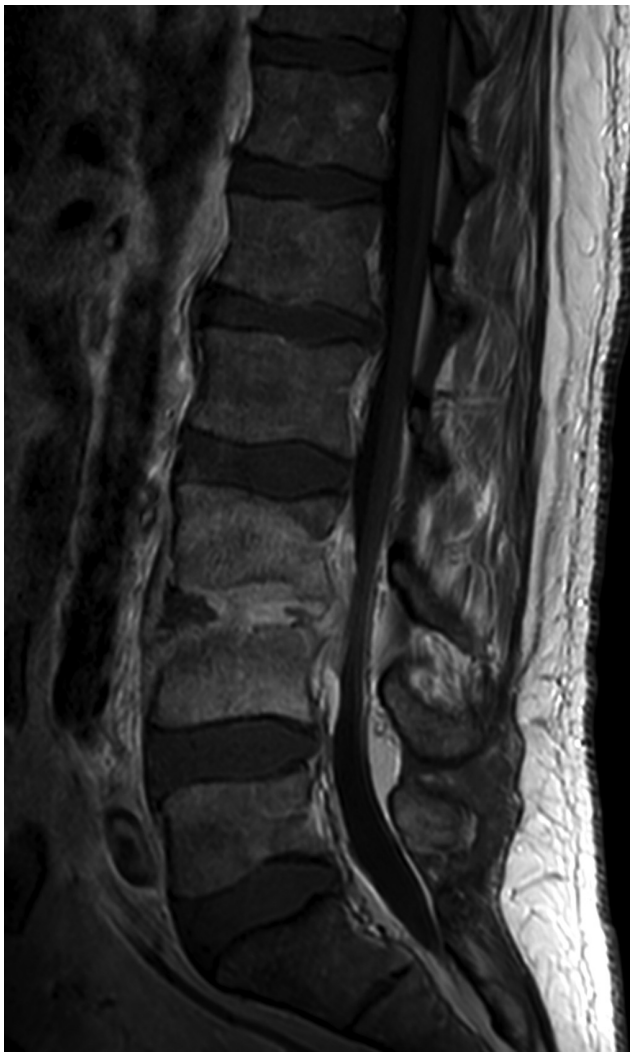

Fig. 6 T1-weighted sagittal postgadolinium magnetic resonance image. Pyogenic spondylodiskitis in L3–L4 with epidural expansion in a 52-year-old man.

with a significantly increased diagnostic certainty of spondylodiskitis. Particularly in cases with inconclusive MRI findings, the combination of F18-FDG-PET with MRI supports the diagnostic certainty markedly regarding both false-positive and false-negative results with a sensitivity of 100%.[27]

A drawback of isolated 18F-FDG-PET is the reduced image quality of detailed anatomical information. In combination with CT or MRI, spatial resolution can be improved markedly. This leads to both a safe assessment of the exact localization and the extent of infection and a good assessment of the condition of the soft tissue.

Some of the biggest advantages of this technique are the ability of very early diagnostic proof and its high diagnostic sensitivity, particularly in distinguishing between early stages of infection and degenerative changes. As mentioned earlier, the prognosis of pyogenic spondylodiskitis can be improved with an early diagnosis and thus immediate therapy. The sensitivity is reported as 95% and a specificity $>$ 87%.[28] In addition, if there is a suspicion of spondylodiskitis of more than one segment, F18-FDG-PET/CT or MRI is helpful to clarify

Fig. 7 Whole-spine magnetic resonance (MR) imaging revealed multilevel spondylodiskitis in the cervical, thoracic, and lumbar spine in a 78-year-old male patient. With sagittal short tau inversion recovery sequence as a search tool, a good overview of the entire spine can be obtained.

 © 2020. Thieme. All rights reserved.

This document was downloaded for personal use only. Unauthorized distribution is strictly prohibited.

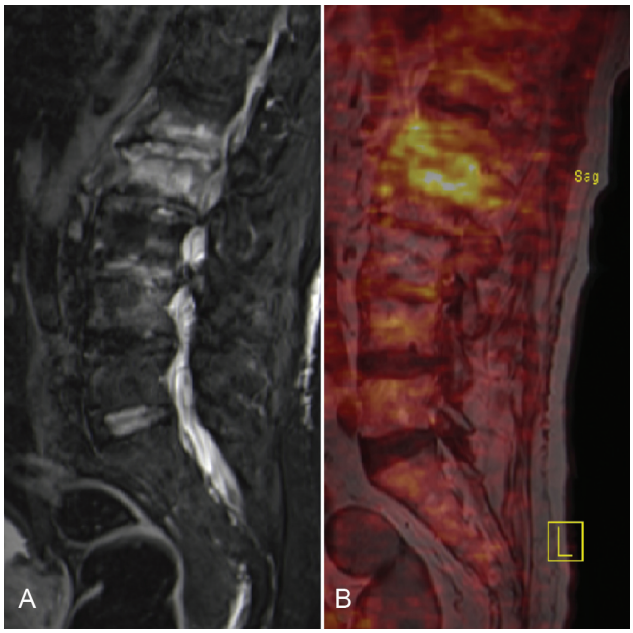

Fig. 8 Simultaneous F18-FDG-positrone emission tomography/magnetic resonance imaging in a 79-year-old male patient with suspected edema in the (left) short tau inversion recovery sequence in L1–L2 and L2–L3. Spondylodiskitis was detected by an increased tracer uptake in L1–L2. In L2–L3, spondylodiskitis was ruled out (right).

which of the levels is indeed affected from inflammation. Moreover, the PET component can also provide significant benefits, especially in patients with prior surgery and internal fixation, where MRI assessment may be significantly hampered. In addition, 18F-FDG showed potential for monitoring response to treatment.[29]

Unfortunately, these techniques are costly and not available everywhere. At this time PET/CT, and in particular PET/MRI, remain reserved for selected cases.

An important point applicable for all these techniques is the scanning of the entire body including the whole spine in one session. This allows the detection of additional clinically uneventful infection foci.[24]

Discussion

Today, different radiologic modalities are available for the diagnosis of nonspecific pyogenic spondylodiskitis. These modalities have various advantages and disadvantages, and knowledge of the pros and cons of each technique or rather of their combination facilitates an accurate diagnosis (►**Table 1**). In the early phase after onset of infection at the spine, the diagnosis can be challenging, particularly in the case of present degenerative disk changes (Modic type 1). However, sophisticated MRI examination protocols available today and, in uncertain cases, 18-FDG-PET with CT or MRI allow for a definitive diagnosis.

Table 1 Advantages and drawbacks of the different radiologic investigation modalities

Modality	Advantages	Drawbacks
Radiograph: standing position whenever possible	**General advantages** • Quick investigation • Broad availability • Inexpensive **Medical advantages** • Alignment evaluation • Hints for destructive processes in later stages of disease • Progress assessment	**General disadvantages** • Radiation exposure **Medical disadvantages** • Low spatial resolution • Poor assessment of the soft tissue • Low sensitivity • Detection of late-stage changes
CT: contrast enhanced if possible	**General advantages** • Quick investigation • Broad availability • Inexpensive **Medical advantages** • Safe and early evaluation of bony changes • Allows for multiplanar reconstruction	**General disadvantages** • Radiation exposure **Medical disadvantages** • Reduced ability to assess neural structures and intradiskal changes • Reduced sensitivity in early stages
MRI with gadolinium	**General advantages** • Broad availability • Radiation free • Inexpensive **Medical advantages** • Evaluation of the whole spine • Excellent soft tissue contrast • Detection of early-stage infection	**General disadvantages** • Long investigation time **Medical disadvantages** • Contraindications may exist (e.g., cardiac pacemaker, claustrophobia) • Artifact prone • Reduced assessment of bone quality
F18-FDG-PET	**General advantages** • Scanning of the whole body in one session **Medical advantages** • High sensitivity and specificity • Very early diagnostic proof • Potential for monitoring response to treatment • In combination with CT or MRI: high spatial anatomical resolution	**General disadvantages** • Radiation exposure • Not available everywhere • Expensive **Medical disadvantages** • Reduced detailed anatomical information without CT or MRI

Abbreviations: CT, computed tomography; MRI, magnetic resonance imaging; F18-FDG-PET, 18F-fluorodeoxyglucose-positron emission tomography.

This document was downloaded for personal use only. Unauthorized distribution is strictly prohibited.

 © 2020. Thieme. All rights reserved.

- In cases of suspected spondylodiskitis, an MRI of the entire spine with fat-suppressed fluid-sensitive MRI sequences is recommended as a search tool. If areas suspect for inflammation are detected, the standardized in-house protocol should be used for further evaluation. The use of gadolinium is recommended.
- A conventional radiograph of the affected region, whenever possible in a standing position, is useful to assess the alignment of the spine, to exclude advanced degrees of destruction and to obtain an overview regarding degeneration, reduced bone quality, and so on.
- CT is proposed if relevant bony defects are to be estimated, particularly for preoperative planning with the possibility of multiplanar reconstruction or in case of contraindications for MRI. Contrast enhancement improves the information value, particularly with regard to indicative inflammatory soft tissue reactions.
- 18-FDG-PET enables a whole-body investigation in one session. In case of uncertain cases, it is helpful to differentiate between the early stage of infection and degenerative Modic type 1 changes. In addition, this investigation is an option if MRI is contraindicated and CT remains inconclusive. If multilevel infection is suspected, this technique allows a safe identification of affected levels.
- The combination of 18-FDG-PET with CT or MRI improves the spatial resolution significantly, although it is reserved for selected cases.

Conclusion

MRI with gadolinium is defined as the gold standard in the diagnosis of pyogenic spondylodiskitis. An evaluation of the whole spine should be standard. Conventional radiographs, CT, and radionuclide imaging procedures are helpful to complete the diagnosis and to answer specific questions.

Conflict of Interest
None declared.

References

1 Prodi E, Grassi R, Iacobellis F, Cianfoni A. Imaging in spondylodiskitis. Magn Reson Imaging Clin N Am 2016;24(03):581–600
2 Aagaard T, Roed C, Dahl B, Obel N. Long-term prognosis and causes of death after spondylodiscitis: a Danish nationwide cohort study. Infect Dis (Lond) 2016;48(03):201–208
3 Duarte RM, Vaccaro AR. Spinal infection: state of the art and management algorithm. Eur Spine J 2013;22(12):2787–2799
4 Eren Gök S, Kaptanoğlu E, Celikbaş A, et al. Vertebral osteomyelitis: clinical features and diagnosis. Clin Microbiol Infect 2014;20 (10):1055–1060
5 Sur A, Tsang K, Brown M, Tzerakis N. Management of adult spontaneous spondylodiscitis and its rising incidence. Ann R Coll Surg Engl 2015;97(06):451–455
6 Kehrer M, Pedersen C, Jensen TG, Hallas J, Lassen AT. Increased short- and long-term mortality among patients with infectious spondylodiscitis compared with a reference population. Spine J 2015;15(06):1233–1240
7 Nickerson EK, Sinha R. Vertebral osteomyelitis in adults: an update. Br Med Bull 2016;117(01):121–138
8 Dunbar JAT, Sandoe JAT, Rao AS, Crimmins DW, Baig W, Rankine JJ. The MRI appearances of early vertebral osteomyelitis and discitis. Clin Radiol 2010;65(12):974–981
9 Yilmaz U. Spondylodiszitis [in German]. Radiologe 2011;51(09): 772–778
10 Diehn FE. Imaging of spine infection. Radiol Clin North Am 2012; 50(04):777–798
11 Yeom JA, Lee IS, Suh HB, Song YS, Song JW. Magnetic resonance imaging findings of early spondylodiscitis: interpretive challenges and atypical findings. Korean J Radiol 2016;17(05): 565–580
12 Babic M, Simpfendorfer CS. Infections of the spine. Infect Dis Clin North Am 2017;31(02):279–297
13 André V, Pot-Vaucel M, Cozic C, et al. Septic arthritis of the facet joint. Med Mal Infect 2015;45(06):215–221
14 Berbari EF, Kanj SS, Kowalski TJ, et al; Infectious Diseases Society of America. 2015 Infectious Diseases Society of America (IDSA) clinical practice guidelines for the diagnosis and treatment of native vertebral osteomyelitis in adults. Clin Infect Dis 2015;61 (06):e26–e46
15 Leone A, Dell'Atti C, Magarelli N, et al. Imaging of spondylodiscitis. Eur Rev Med Pharmacol Sci 2012;16(Suppl 2):8–19
16 Gouliouris T, Aliyu SH, Brown NM. Spondylodiscitis: update on diagnosis and management. J Antimicrob Chemother 2010;65 (Suppl 3):iii11–iii24
17 Skaf GS, Domloj NT, Fehlings MG, et al. Pyogenic spondylodiscitis: an overview. J Infect Public Health 2010;3(01):5–16
18 Arbelaez A, Restrepo F, Castillo M. Spinal infections: clinical and imaging features. Top Magn Reson Imaging 2014;23(05):303–314
19 Cheung WY, Luk KDK. Pyogenic spondylitis. Int Orthop 2012;36 (02):397–404
20 Cornett CA, Vincent SA, Crow J, Hewlett A. Bacterial spine infections in adults: evaluation and management. J Am Acad Orthop Surg 2016;24(01):11–18
21 Zimmerli W. Clinical practice. Vertebral osteomyelitis. N Engl J Med 2010;362(11):1022–1029
22 Sobottke R, Seifert H, Fätkenheuer G, Schmidt M, Gossmann A, Eysel P. Current diagnosis and treatment of spondylodiscitis. Dtsch Arztebl Int 2008;105(10):181–187
23 Cox M, Curtis B, Patel M, Babatunde V, Flanders AE. Utility of sagittal MR imaging of the whole spine in cases of known or suspected single-level spinal infection: overkill or good clinical practice? Clin Imaging 2018;51:98–103
24 Treglia G, Focacci C, Caldarella C, et al. The role of nuclear medicine in the diagnosis of spondylodiscitis. Eur Rev Med Pharmacol Sci 2012;16(Suppl 2):20–25
25 Seifen T, Rettenbacher L, Thaler C, Holzmannhofer J, Mc Coy M, Pirich C. Prolonged back pain attributed to suspected spondylodiscitis. The value of ^{18}F-FDG PET/CT imaging in the diagnostic work-up of patients. Nucl Med (Stuttg) 2012;51(05): 194–200
26 Fuster D, Tomás X, Mayoral M, et al. Prospective comparison of whole-body (18)F-FDG PET/CT and MRI of the spine in the diagnosis of haematogenous spondylodiscitis. Eur J Nucl Med Mol Imaging 2015;42(02):264–271
27 Fahnert J, Purz S, Jarvers J-S, et al. Use of Simultaneous 18F-FDG PET/MRI for the Detection of Spondylodiskitis. J Nucl Med 2016; 57(09):1396–1401
28 Glaudemans AWJM, de Vries EFJ, Galli F, Dierckx RA, Slart RH, Signore A. The use of (18)F-FDG-PET/CT for diagnosis and treatment monitoring of inflammatory and infectious diseases. Clin Dev Immunol 2013;2013:623036
29 Nanni C, Boriani L, Salvadori C, et al. FDG PET/CT is useful for the interim evaluation of response to therapy in patients affected by haematogenous spondylodiscitis. Eur J Nucl Med Mol Imaging 2012;39(10):1538–1544

This document was downloaded for personal use only. Unauthorized distribution is strictly prohibited.

 © 2020. Thieme. All rights reserved.