

Percutaneous Management of Inferior Thyroid Artery Pseudoaneurysm Developed after Central Line Placement in a Cirrhotic Patient

Ujjwal Gorski¹ Suresh Babu¹ Tejeshwar Singh Jugpal¹ Vikas Bhatia¹ Sunil Taneja²

¹Department of Radiodiagnosis and Imaging, Postgraduate Institute of Medical Education & Research, Chandigarh, India

²Department of Hepatology, Postgraduate Institute of Medical Education & Research, Chandigarh, India

Address for correspondence Ujjwal Gorski, MD, Department of Radiodiagnosis and Imaging, Postgraduate Institute of Medical Education & Research, Sector 12, Chandigarh, 160012, India (e-mail: ujjwalgorski@gmail.com).

J Clin Interv Radiol ISVIR:2020;4:115–117

Abstract

Keywords

- ▶ pseudoaneurysm
- ▶ central venous catheterization
- ▶ thrombin

Iatrogenic arterial injury is a life-threatening complication of central venous catheterization. We report a rare case of percutaneous ultrasound-guided occlusion of inferior thyroid artery pseudoaneurysm that developed after attempted internal jugular vein cannulation in a cirrhotic patient.

Introduction

Central venous catheterization is necessary for the monitoring of central venous pressure and the infusion of vasoactive drugs, or when hemodialysis or hemofiltration is required in the management of liver disease patients.¹ Complications of central venous catheterization include mechanical complications such as arterial injury, hematoma, pseudoaneurysm formation, pneumothorax, and hemothorax. Other complications include venous thrombosis and catheter-related complications.² We report a case of pseudoaneurysm of inferior thyroid artery that developed after attempted central venous catheterization, as well as its management by percutaneous thrombin injection at our institute.

Case Report

We report an interesting case of a 45-year-old male. We obtained informed consent from the patient for the publication of the case report and accompanying images. We have also taken the institutional ethical clearance. The patient was a known case of nonalcoholic steatohepatitis related cirrhosis with coagulopathy (platelet count of 35,000/mm³, prothrombin index of 38%), who developed swelling on the right side of the neck following attempted central venous line insertion. The swelling gradually increased in size. The

patient developed mild numbness and tingling in the right arm and forearm. On ultrasound examination, there was a large heteroechoic hematoma on the right side of the neck, which, on color Doppler, showed flow within it suggestive of pseudoaneurysm. CT angiogram was performed to localize the site, which revealed a narrow neck pseudoaneurysm from the inferior thyroid artery, a branch arising from thyrocervical trunk of the right subclavian artery (▶ Fig. 1). No venous component/arteriovenous (AV) fistula was seen. Since the patient's coagulation profile was abnormal, the patient was taken up for percutaneous thrombin injection in preference to endovascular embolization. Ultrasound Doppler revealed the classical *yin-yang* pattern of color flow within the pseudoaneurysm (▶ Fig. 2). Under ultrasound guidance, a 22-gauge needle was inserted into the pseudoaneurysm and approximately 1 mL of thrombin-500 IU (reconstituted with calcium chloride) was injected slowly. Immediate occlusion of pseudoaneurysm was noticed. Follow-up ultrasound the next day showed no color flow within the pseudoaneurysm (▶ Fig. 3). The patient was stable. No further increase in the size of hematoma was detected. No complications were encountered. No neurologic deficits occurred. Patient was discharged satisfactorily 4 days after the procedure. On the day of discharge, a significant reduction in neck swelling was observed clinically. A review USG on the day of discharge did not show any color flow.

published online
April 14, 2020

DOI <https://doi.org/10.1055/s-0040-1705264>
ISSN 2457-0214.

©2020 by Indian Society of
Vascular and Interventional
Radiology

License terms



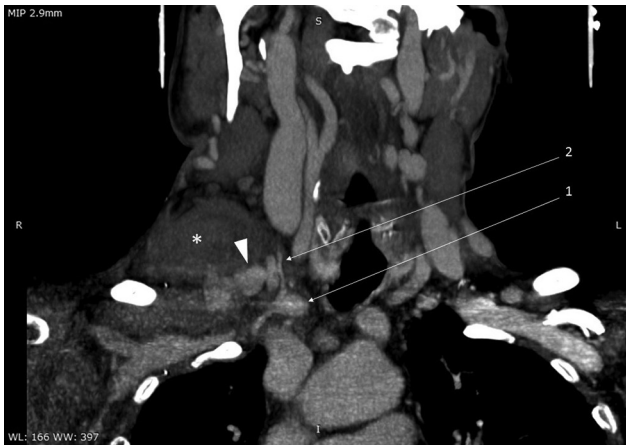


Fig. 1 Maximum intensity projection computed tomography angiography image showing the right subclavian artery (arrow 1) and the inferior thyroid artery (arrow 2) with a large hematoma (asterisk) with pseudoaneurysm (arrowhead).

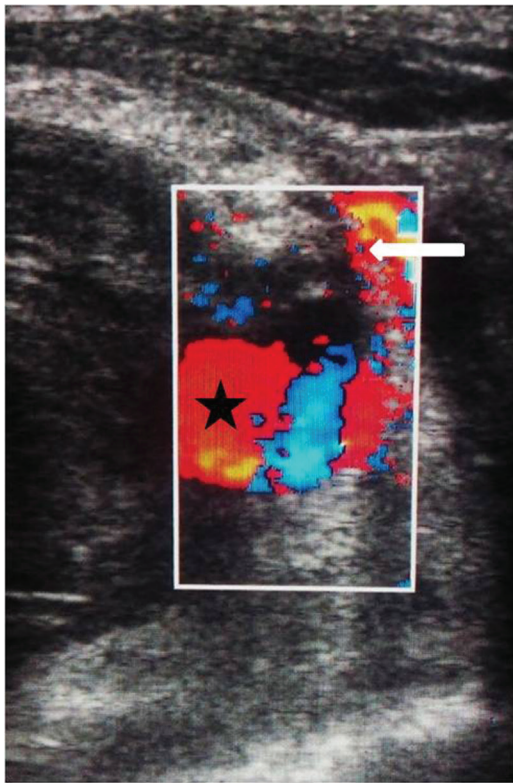


Fig. 2 Color Doppler image showing turbulent flow within the pseudoaneurysm (asterisk) with a narrow neck, with flow seen in the inferior thyroid artery (white arrow).

Discussion

Inadvertent arterial puncture occurs in approximately 5% of cases (0–11%) of central venous catheterization.³ Morbid complications such as hematoma, airway obstruction, hemothorax, pseudoaneurysm, and AV fistula can occur in 0.1 to 0.8% of cases.³ The vascular complications could be substantially reduced if ultrasound guidance is used for catheterization.²

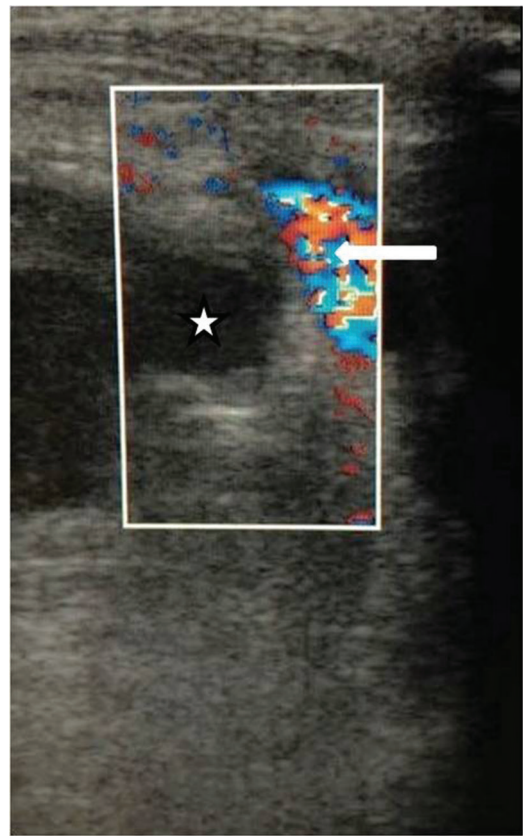


Fig. 3 Color Doppler image after percutaneous thrombin injection showing no residual color flow in the pseudoaneurysm (asterisk), with normal flow in the inferior thyroid artery (white arrow).

Only three previous reports of inferior thyroid artery pseudoaneurysm formed during attempted IJV cannulation have been reported in literature.^{4–6} To the best of our knowledge, our case is the first with inferior thyroid artery pseudoaneurysm successfully managed with percutaneous thrombin injection.

Management options for femoral artery pseudoaneurysms developed after endovascular procedure/diagnostic angiogram include compression, percutaneous thrombin injection, and endovascular management. Adequate compression to occlude a pseudoaneurysm in the cervical region is not possible without compromising cerebral perfusion.³ Endovascular management was not performed in the patient in view of underlying coagulopathy. Fresh frozen plasma can be given in few cases for the correction of coagulopathy, but it alters the prothrombin time and the prognostic information in patients with liver failure.¹ Percutaneous thrombin injection has been well established for the management of femoral artery pseudoaneurysms. Very few cases of percutaneous management of pseudoaneurysms in the neck region have been described in the literature.⁷ In our case, we performed percutaneous thrombin injection in the pseudoaneurysm of the inferior thyroid artery, and the procedure was successful without any complications. Few important considerations are worth mentioning in such cases. The neck of the pseudoaneurysm should be narrow (dome/neck ratio > 1) as there are high chances

of distal thromboembolism in case of short- and wide-neck aneurysms. Needle tip should not be placed close to the neck to prevent inadvertent injection into the main artery. Venous communication/AV fistula is an absolute contraindication for percutaneous thrombin injection and should be ruled out prior to the procedure. Superficial infection at the procedure site is a contraindication. Rate of injection should be slow. In cases of multilobulated pseudoaneurysm, the lobe closer to the neck should be injected first, as the thrombus formed could propagate into the rest of the pseudoaneurysm and may obviate the need for repeated injections. All the lobes must be reviewed by performing an ultrasound, and it should be ensured that no active component is left out to prevent recanalization.^{8,9} Thrombin acts by converting fibrinogen into fibrin in the terminal part of the coagulation cascade. Hence, thrombin injection is successful even when the coagulation profile is deranged because of any proximal defect in the coagulation cascade. Thrombin also acts at a different level of coagulation cascade. Thrombin activates factor XIII, which covalently links fibrin polymers and provides stability to fibrin within the platelet plug. Also, thrombin activates TAFI (thrombin-activatable fibrinolysis inhibitor), which protects the clot from fibrinolysis. The calcium chloride solution used for the reconstitution of thrombin provides the calcium ions necessary for various enzymatic processes of coagulation cascade. Percutaneous thrombin injection is a better cost-effective procedure as compared with endovascular management and may be the only effective method when there is severe coagulopathy. The most dreaded complication of thrombin injection is spillage of thrombus into the arterial circulation causing thromboembolic events. This rarely occurs as the thrombus formation is instantaneous after injecting thrombin, and continuous monitoring by performing sonography and directing the needle away from the neck of pseudoaneurysm help control the volume of thrombus. Even if a small amount of thrombin escapes into the artery, the normal fibrinolytic system dissolves the clot.

Conclusion

Percutaneous thrombin injection is an alternate cost-effective option for the treatment of endovascular or surgical repair in the management of pseudoaneurysms developed after inadvertent arterial injury during central venous catheterization in a selective subset of cases such as with severe coagulopathy.

Funding

None.

Conflict of Interest

None.

References

- 1 Fisher NC, Mutimer DJ. Central venous cannulation in patients with liver disease and coagulopathy—a prospective audit. *Intensive Care Med* 1999;25(5):481–485
- 2 Taylor RW, Palagiri AV. Central venous catheterization. *Crit Care Med* 2007;35(5):1390–1396
- 3 Guilbert MC, Elkouri S, Bracco D, et al. Arterial trauma during central venous catheter insertion: case series, review and proposed algorithm. *J Vasc Surg* 2008;48(4):918–925, discussion 925
- 4 Debek AH, Jammaleddine GW, Bou-Khalil PK. Inferior thyroid artery injury after attempts of internal jugular venous catheterization. *J Cardiothorac Vasc Anesth* 2007;21(3):422–424
- 5 Schummer W, Schummer C, Paxian M, Fröber R, Settmacher U. ECG recording of central venous catheter misplaced in inferior thyroid artery. *Br J Anaesth* 2005;94(3):296–299
- 6 Ruan J, Zhang C, Peng Z, Tang DY, Feng Z. Inferior thyroid artery pseudoaneurysm associated with internal jugular vein puncture: a case report. *BMC Anesthesiol* 2015;15:71
- 7 Jeganathan R, Harkin DW, Lowry P, Lee B. Iatrogenic subclavian artery pseudoaneurysm causing airway compromise: treatment with percutaneous thrombin injection. *J Vasc Surg* 2004;40(2):371–374
- 8 Hanson JM, Atri M, Power N. Ultrasound-guided thrombin injection of iatrogenic groin pseudoaneurysm: Doppler features and technical tips. *Br J Radiol* 2008;81(962):154–163
- 9 Lasne D, Jude B, Susen S. From normal to pathological hemostasis. *Can J Anaesth* 2006;53(6, Suppl):S2–S11