



A Case of Foramen Magnum and C1–C2 Meningiomas: Double Challenge, One Approach

Giada Toccaceli¹ Roberto Altieri¹ Francesco Certo¹ Giuseppe Barbagallo¹

¹Department of Neurosurgery, Azienda Ospedaliero Universitaria Policlinico Vittorio Emanuele Catania, Catania, Italy

Address for correspondence Giada Toccaceli, MD, Department of Neurosurgery, Azienda Ospedaliero Universitaria Policlinico Vittorio Emanuele Catania, via Santa Sofia, 79 Catania 95123, Italy (e-mail: toccaceli.giada@gmail.com).

J Neurol Surg B 2021;82(suppl S1):S25–S26.

Abstract

Objectives We present a challenging case of a 61-year-old male patient with a double meningioma. The first one was located on the right side of foramen magnum and the second one was located on left anterolateral side of C1–C2.

Background Patient referred at our institution for a progressive spastic paraparesis from approximately 1 year with a recent onset of numbness in right hand. Neuroradiological imaging showed an extra-axial enhancing tumor with a dural tail on the right border of foramen magnum and another contralateral extra-axial enhancing lesion at C1–C2 level (→ Fig. 1).

Results We have chosen a park bench position. Neurophysiological monitoring was used during both positioning and surgery. A linear skin incision in the occipital region extended to C7 was performed and a suboccipital craniotomy with the laminectomy of C1–C3 was performed (→ Fig. 2). Videofluorangiography was performed to the best visualization of the vertebral artery position during microsurgical dissection and exposure of craniovertebral junction region. An Y-shape dural opening was executed and two meningiomas was resected with the classical four D steps (devascularize, detach, debulking, and dissect). All anatomical structures were respected and there were no changes at neuromonitoring. Patient was discharged after 10 days in good neurological condition.

Conclusion a single approach for multiple meningiomas of the craniovertebral junction and upper cervical spine region is feasible and effective. Videofluorangiography as a way to achieve better visualization and control of the vertebral artery, and neurophysiological monitoring are crucial tools to reduce the morbidity of this surgical challenge.

The link to the video can be found at: <https://youtu.be/4w9HCfQZkgg>.

Keywords

- ▶ meningiomas
- ▶ Atlas
- ▶ craniocervical junction
- ▶ cervical spine
- ▶ skull base approaches



Conflict of Interest

None declared.

www.thieme.com/skullbasevideos

www.thieme.com/jnlsbvideos

received
February 28, 2019
accepted after revision
January 4, 2020
published online
August 24, 2020

DOI <https://doi.org/10.1055/s-0040-1705159>.
ISSN 2193-6331.

© 2020. The Author(s).

This is an open access article published by Thieme under the terms of the Creative Commons Attribution-NonDerivative-NonCommercial-License, permitting copying and reproduction so long as the original work is given appropriate credit. Contents may not be used for commercial purposes, or adapted, remixed, transformed or built upon. (<https://creativecommons.org/licenses/by-nc-nd/4.0/>)

Georg Thieme Verlag KG, Rüdigerstraße 14, 70469 Stuttgart, Germany

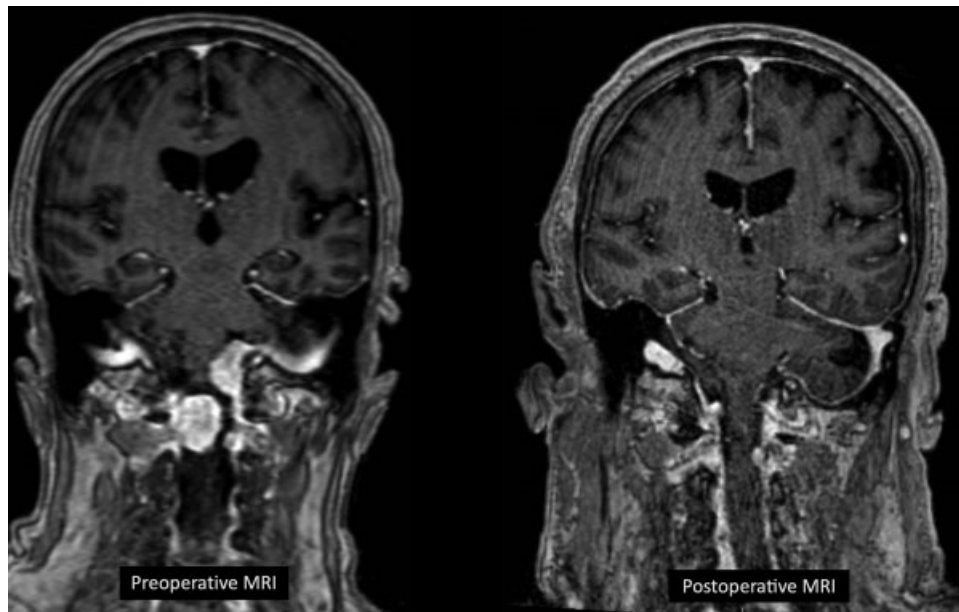


Fig. 1 Pre- and postoperative MRI. MRI, magnetic resonance imaging.

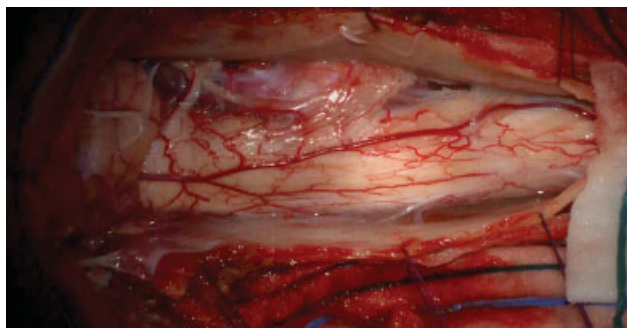


Fig. 2 Surgical field after suboccipital craniotomy and C1-C3 laminectomy.