

OUR EXPERIENCE OF A CASE OF TERRIBLE TRIAD OF ELBOW

Siddharth M. Shetty¹, Vikram Shetty², Arjun Ballal³ & Anoop Hegde⁴

^{1,2}Associate Professors, ^{3,4}P. G. Students, Department of Orthopaedic Surgery,
K.S. Hegde Medical Academy, Nitte University, Mangalore - 575 018, Karnataka, India.

Correspondence :

Arjun Ballal

P.G. Student, Department of Orthopaedic Surgery

K.S. Hegde Medical Academy, Nitte University, Mangalore – 575018, Karnataka, India.

Mobile : +91 84316 44077 E-mail : arjchess_lp@rediffmail.com

Abstract:

Dislocation of the elbow joint in association with fracture of radial head and fracture of coronoid process, is referred to as “terrible triad” of the elbow, the treatment of which provides a challenge to treating surgeon due to its complicated outcomes. The understanding of the elbow kinematics, the usage of various implants and surgical techniques in the recent years has led to the development of standard treatment protocols. The ‘terrible triad’ of the elbow is a severe injury that is difficult to treat and has a poor prognosis in the medium-to-long term. It is characterised most often by instability of the elbow, development of arthrosis and joint stiffness.

A 43 year old lady presented to us after a fall on outstretched dominant hand with severe pain and swelling around elbow. She had sustained a fracture of the radial neck and coronoid process with posterolateral dislocation of elbow. Immediate Closed reduction of the dislocation was performed under GA and elbow was immobilised in a plaster of paris slab for 3 weeks. She underwent operative procedure of open reduction and internal fixation of the radial head with a titanium plate and the coronoid process with a 4mm screw and washer after 10 days. After 3 weeks elbow rehabilitation was begun and at one year post surgery there was signs of fracture healing with full range of motion of the elbow.

Keywords : Terrible triad of elbow, humeroulnar dislocation, radial head fracture, coronoid fracture.

Introduction :

Posterolateral dislocation of the elbow joint is the most common acute traumatic elbow instability and occurs secondary to a traumatic elbow injury due to axial loading in supinated forearm with valgus stress.^{5,6} Such trauma will induce damage to the radial collateral ligament complex extending to the capsule and up to the ulnar collateral ligament compartment⁶. Early treatment will affect the overall outcome.⁵ Dislocation of the elbow joint is often associated with ligament injury, fracture of radial head, coronoid process, oleocranon process or humeral epicondyles. The “terrible triad injury” of the elbow, as described by Hotchkiss, consists of a combination of 3

lesions⁴. a) Fracture of the radial head. b) Fracture of the coronoid process of ulna. c) Humero-ulnar dislocation (generally posterior or posterolateral). The objective in the

management of such injuries is to restore anatomical relations of bony structures of the elbow and stability of ligament complex so as to convert an unstable dislocated joint into an anatomically reduced and stable one. Early intervention result in a favourable outcome.⁷ The principles of this treatment were detailed by McKee et al.⁸ as well as Ring et al.⁹, however relatively few clinical reports are available in the literature.

Case Report :

A 43 year old lady presented to us after a fall on outstretched dominant hand with severe pain and swelling around elbow. On clinical evaluation, there was raised local temperature over the elbow, there was tenderness and crepitus with loss of three point bony relation of elbow without any neurovascular injury. Radiologically, fracture of the radial neck, fracture of the coronoid process with posterior humero-ulnar dislocation were noted. (Figure 1). Immediate Closed reduction of the dislocation was performed under GA and elbow was immobilised in a plaster of Paris slab. (Figures 2). Post operative CT scan

Access this article online

Quick Response Code



(Figure 3) showed fracture coronoid process and radial neck and head in a displaced position. There was no incarceration of loose fragments in the joint. She was operatively treated after ten days when the swelling had subsided and an open reduction and internal fixation of the

radial head and neck with a titanium plate with 2.5 mm screws through the Kocher's approach and the coronoid process was fixed with a 4mm titanium cannulated cancellous screw with washer through an antero-medial approach under general anaesthesia and following fixation

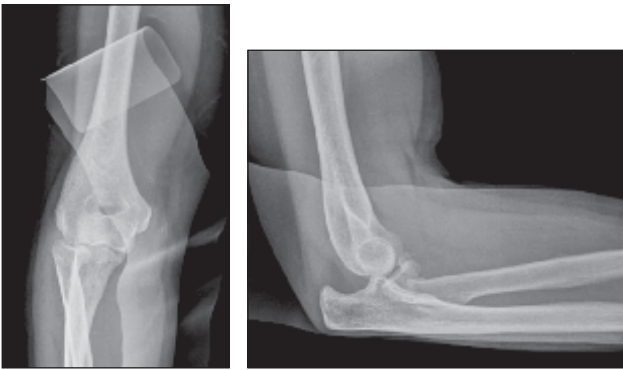


Fig 1 A

Fig 1 B

Fig 1(A/B): AP/Lateral views of the elbow showing posterior dislocation of the elbow with fracture of the radial neck and coronoid process

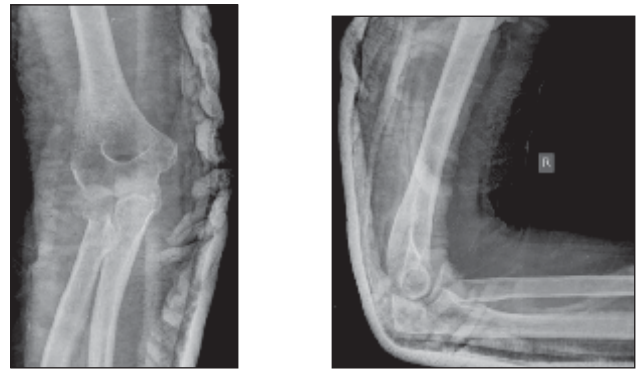


Fig 2 A

Fig 2 B

Figure 2(A/B): AP/Lateral views after closed reduction and POP slab application of the elbow dislocation with displaced fracture fragments.

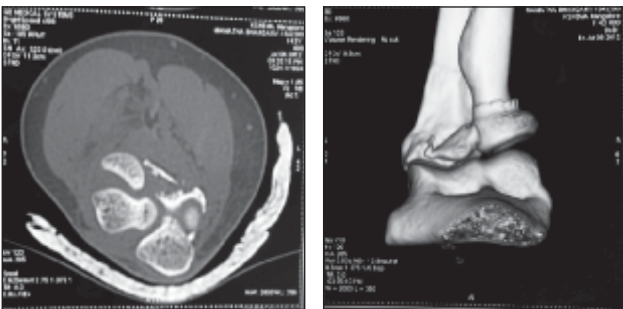


Fig 3 A

Fig 3 B

Fig 3 : (A) CT scan of the elbow after reduction, showing displaced radial neck and head and coronoid process fractures, (B) 3-dimensional reconstruction CT.

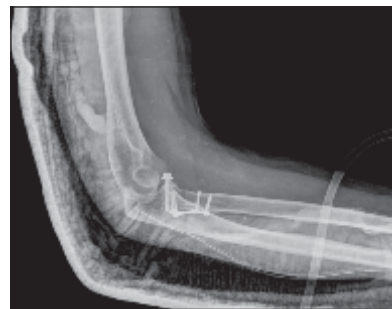


Fig 4: Post surgery X-ray of the elbow after open reduction and fixation with Titanium screws and plate with above elbow slab (Lateral view)

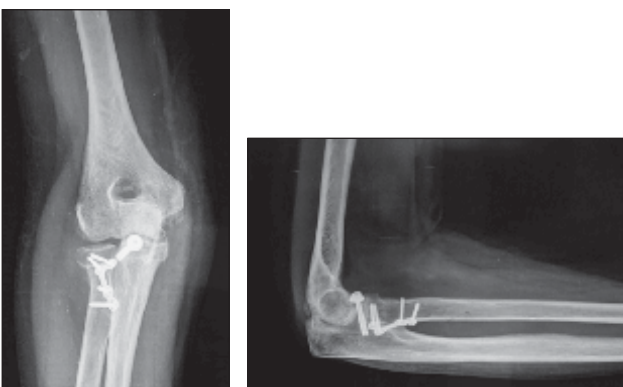


Fig 5 A

Fig 5 B

Fig 5(A/B): AP/Lateral views three months Post surgery showingsigns of healing of fracture with implant insitu

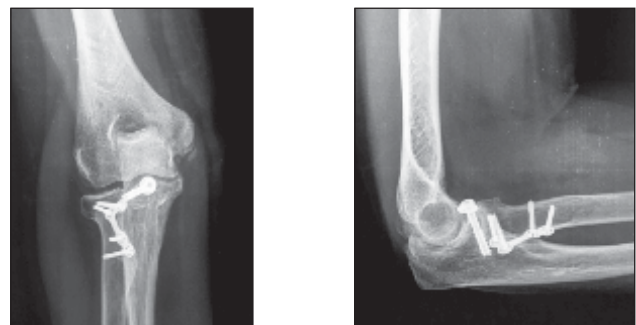


Fig 6 A

Fig 6 B

Fig 6(A/B): AP/Lateral views at one year radiological union is noted at the fracture site

stability of the elbow was assessed. The immobilisation was continued for a total period of three weeks to allow soft tissue healing. The post-surgery X-ray showed anatomical reduction (Figure 4). At the end of 3 weeks plaster slab and sutures were removed elbow rehabilitation was instituted with gentle active and active assisted flexion and extension and prono-supination

movements. She was continued on arm sling support for another three weeks. Patient recovered full range of motion by 3 months with satisfactory radiological progress of union (Figure 5). She was reviewed one year later with full range of motion with no subjective or objective evidence of instability and with radiological feature of fracture union. (Figures 6,7).



Fig 7(A) : Full range of elbow flexion



Fig 7(B): Full range of elbow extension




Fig 7(C) : Full range of elbow pronation



Fig 7(D) : Full range extension in full supination of elbow

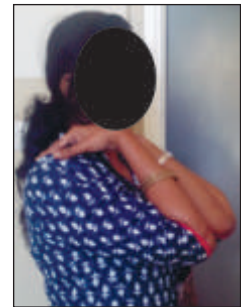

Fig 7(E): Full range of elbow flexion in full supination of elbow

Discussion :

The terrible triad of the elbow presents a challenge to surgeons and usually has poor outcomes, with frequent re-dislocation, arthrosis, loss of movement or.^{2,5,9,10} The most common injury mechanism is a simple fall on the outstretched hand, with axial transfer of the force on the hyper-extended elbow in supination and a position of elbow valgus. Despite the severity of the injury, the causative mechanism is not a high-energy trauma.^{8,9} The forces producing elbow luxation affect the joint by injuring structures sequentially from a lateral to medial direction.⁵ In the first phase, the lateral collateral complex is affected, which produces rotational instability of the elbow in varus. In the second phase, if the force continues to act, the radial head collides with the humeral condyle and fractures. In the third phase, the rotating instability produced by injury of the lateral complex enables the axial

force to dislocate the elbow, usually in a posterior or postero-lateral direction, and occurs together with fracture of the coronoid process.¹¹ The coronoid can also be affected at the beginning by rupture of the lateral ligament complex or by a direct impact of the humeral trochlea, although the second and third phases occur almost simultaneously. The medial ligament complex is also affected in most patients, but its injury is not an essential prerequisite for the terrible triad to occur.¹¹ B. Chemama et al conducted a study, concluded that: The principle of the surgical management is based on two main objectives: restoration of bony stabilizing structures (radial head and coronoid process) and lateral collateral ligament reconstruction. A medial surgical approach is recommended in the case of persistent postero-lateral instability following lateral collateral ligament reconstruction or when fixation of a large coronoid process

fragment is indicated. The use of an external fixator is only advocated in case of persistent instability following the reconstruction of bony and ligamentous structures.¹² Roberto Seijas et al conducted a study on 18 cases of the terrible triad of the elbow on whom he performed various surgical treatment approaches and concluded that patients had better recovery of range of motion than those reported in other studies, the terrible triad of the elbow can lead to joint instability, arthrosis, and joint stiffness, and may resort to total elbow arthroplasty in some cases.

Our patient presented with a similar mode of injury and underwent the aforementioned management. She recovered with full range of motion and no instability or stiffness.

Conclusion:

Hence, we conclude that planned staged surgical intervention, anatomical restoration of the bony and ligamentous structures of the elbow with aggressive rehabilitation will possibly yield best possible outcome.

References:

1. Juan Rodriguez-Martin, Juan Pretell-Mazzini, Eva Maria Andres-Esteban, and Ricardo Larrainzar-Garijo. Outcomes after terrible triads of the elbow treated with the current surgical protocols. A review. *Int Orthop*. 2011 June; 35(6): 851–860.
2. Hotchkiss RN. Fractures and dislocations of the elbow. In: Rockwood CA, Jr, Green DP, Bucholz RW, Heckman JD, editors. *Rockwood and Green's fractures in adults*. Vol I, 4th ed. Philadelphia: Lippincott-Raven; 1996:929-1024.
3. Lill H, Korner J, Rose T, Hepp P, Verheyden, P, Josten C. Fracture-dislocations of the elbow joint—strategy for treatment and results. *Arch Orthop Trauma Surg* 2001;121:31–7.
4. Pugh DM, McKee MD. The "terrible triad" of the elbow. *Tech Hand Up Extrem Surg* 2002;6:21–9.
5. S.W. O'Driscoll, J.B. Jupiter, G.J.W. King, R.N. Hotchkiss, B.F. Morrey The unstable elbow *J Bone Joint Surg Am*, 82 (2000), pp. 724–738
6. S.W. O'Driscoll, B.F. Morrey, S. Korinek, A.D. Kai-Nan. Elbow subluxation and dislocation. A spectrum of instability. *Clin Orthop*, 280 (1992), pp. 186–197
7. A.D. Armstrong. The terrible triad injury of the elbow. *Curr Opin Orthop*, 16 (2005), pp. 267–270
8. M.D. McKee, D.M.W. Pugh, L.M. Wild, E.H. Schemitsch, G.J.W. King. Standard surgical protocol to treat elbow dislocations with radial head and coronoid fractures. Surgical technique. *J Bone Joint Surg Am*, 87 (suppl. 1, part 1) (2005), pp. 22–32
9. D. Ring, J.B. Jupiter, J. Zilberfarb. Posterior dislocation of the elbow with fractures of the radial head and coronoid. *J Bone Joint Surg Am*, 84 (2002), pp. 547–551
10. Bousselmame N, Boussouga M, Bouabid S, Galuia F, Taobane H, Moulay I. Fractures of the coronoid process. *Chir Main* 2000;19:286–93.
11. Roberto Seijas, Oscar Ares-Rodriguez, Adolfo Orellana, Daniel Albareda, Diego Collado, Manel Llusa. Terrible triad of the elbow. *Journal of Orthopaedic Surgery* 2009;17(3):335-9
12. B. Chemama, N. Bonnevalle, O. Peter, P. Mansat Corresponding author contact information, E-mail the corresponding author, P. Bonnevalle. Terrible triad injury of the elbow: How to improve outcomes? *Orthopaedics & Traumatology: Surgery & Research* Volume 96, Issue 2, April 2010, Pages 147–154