

Case Report

PULMONARY AGENESIS-GROUP I WITH UPAA DIAGNOSED IN ELDERLY GERIATRIC AGE

Raghav Sharma¹, Vidya Upadhyaya², Nazir Attar³¹ Professor, Department of Medicine, K.S. Hegde Medical Academy, Deralakatte, Mangalore - 575 018² Assistant Professor, Department of Radio Diagnosis, K.S. Hegde Medical Academy, Deralakatte, Mangalore - 575 018³ Professor & Unit Head, Department of Medicine, K.S. Hegde Medical Academy, Deralakatte, Mangalore - 575 018

Correspondence :

Raghav Sharma

Professor, Department of Medicine, K.S. Hegde Medical Academy, Deralakatte, Mangalore- 575 018

Mobile : 94487 70919 E-mail : rrsharma1967@yahoo.com

Abstract :

Pulmonary agenesis and UPAA (unilateral pulmonary artery agenesis) is a rare developmental lung defect in which there is complete absence or hypoplasia of one or both lungs. It can be either isolated or associated with other congenital anomalies. The percentage of diagnosis of this condition during life has risen considerably, however it is true that more than 50% of the patients with this condition die in the first year of life. The symptoms and severity of this condition is often variable. Here with we present a male patient with left upper lobe pulmonary agenesis with left unilateral pulmonary artery agenesis (UPAA) which was detected and diagnosed for the first time at the ripe age of 70 years. Here we also review the relevant literature regarding the condition and the radiology including CT scan is described.

Keywords : Pulmonary agenesis, Agenesis of left upper lobe, Unilateral pulmonary artery agenesis-UPAA, Congenital lung malformations, CT chest.

Clinical Case Profile :

A 70 year old male person resident of a village in U.K. district of Karnataka presented to K S. Hegde Medical College hospital, Mangalore in the month of September 2011 with the complaints of fever, cough with expectoration of 12 days duration. He was apparently normal 12 days back when he developed intermittent type of high grade fever with chills and rigors. 4 days after the onset of fever he developed cough with expectoration, while sputum was minimal in amount, mucoid in consistency, non blood stained, non foul smelling and with no noticeable postural or diurnal variation. Systemic review of symptoms were non contributory.

He was treated for the same at a local hospital for 3 days with antibiotics and then was referred to K.S. Hegde college hospital for further management.

There was no history of any breathlessness, wheeze, respiratory infections in the past and he could do well all his activities as a farmer without any glitch. There was no history suggestive of any associated comorbid conditions. He was not an alcoholic or smoker but had the habit of

chewing tobacco. He gave a history of asthma and treated, cured tuberculosis in his father who survived healthy up to the age of 90 years.

His general physical examination revealed a moderately built and nourished person with a height of 152cm and weight of 44kgs with no evidence of pallor, icterus, cyanosis, clubbing or edema. He was afebrile with pulse rate of 100/min BP.120/70mmHg and a respiratory rate of 16 breaths/min.

His respiratory system examination revealed deviation of trachea to the left side, drooping of shoulder to the left side, supra clavicular hollowing on the left side scoliosis with concavity towards the left side. However the chest movements were equal on both sides with a chest expansion of 1cm, with no use of any accessory muscles of respiration. Percussion of the left hemithorax revealed a dull note over the left infraclavicular and left mammary areas. Auscultation revealed vesicular breath sounds with diminished intensity over the left infraclavicular and left mammary areas with crepitations, however vocal resonance (VR) being equal on both hemithorax. Other

systems were within normal limits.

Based on symptomatology and clinical findings, provisional diagnosis of "left upper lobe pneumonia" was considered. But however there were contradicting features in the form of preserved chest movements, unaltered VF & VR in the presence of tracheal deviation, drooping of shoulder and hollow supraclavicular region. Hence the patient and was investigated thoroughly to reach a definitive diagnosis

His investigations were as follows:

Table 1

Investigation	Patients values with normal range
Hb	12gm/dl (11-15)
TC(Total count)	11,500 cells/mm ³ (4000-10000)
DC Differential count %	N-48,L-50,E-2
ESR	40mm/hr (<15)
Platelet count	2,74,000/mm ³ (1.5-4 lakh)
MPFT	Negative
Random blood sugar	124mg/dl (70-140)
Urea	18mg/dl (13-45)
Creatinine	0.7mg/dl (<1.4)
Total protein	7.1gm/dl (6.6-8.3)
Albumin	3.5gm/dl (3.5-5)

Investigation	Patients values with normal range
Globulin	3.6gm/dl (2.3-3.5)
A/G ratio	0.9 (1-1.5)
Total bilirubin	0.6mg/dl (<1.0)
Direct bilirubin	0.3mg/dl (<0.25)
Indirect bilirubin	0.3mg/dl (<0.75)
SGOT	28 U/L (<40)
SGPT	29 U/L (<40)
Alkaline phosphate	27 U/L (60-170)
S. Sodium	142 mmol/L (135-148)
S. Potassium	4 mmol/L (3.5-5)
S. Chloride	96 mg/dl (98-110)
Urine routine & microscopy	Normal

The investigations confirmed the diagnosis of "left upper lobe pulmonary agenesis with absent left upper lobe bronchus and absent left pulmonary artery".

Conservative management for the super added lower respiratory tract infection in the backdrop of pulmonary agenesis was delivered in the form of broad spectrum antibiotics and mucolytics. Patient was discharged on the 5th day of admission when he was completely asymptomatic. He remained well and was asymptomatic on his follow-up after a gap of almost 6 months.

Table 1

Special Investigations	Findings
12 lead ECG	RSR' complex noted in V2 V3 leads suggestive of right bundle branch block
Chest x-ray PA view (Fig 1)	A veil like opacity in the left hemithorax-upper zone suggestive of a provisional diagnosis of left upper lobe obstructive collapse
Contrast CT chest (Fig 2,3,4)	Axial CT thorax (Fig 2) : main pulmonary artery and right pulmonary artery (marked by star mark) well seen with hypoplastic left pulmonary artery (marked by arrow mark) and trans mediastinal herniation of right lung (marked by plus mark) are seen. CT thorax Bronchus view (Fig 3) Agenesis of left upper lobe and absent left upper lobe bronchus well seen. CT thorax VR image (Fig 4) : Left upper lobe agenesis, absent left upper lobe bronchus, hypoplastic left pulmonary artery and trans mediastinal herniation of right lung well seen.
PSX parasternal short axis at Aortic root level: Echocardiogram (Fig 5,6,7)	Fig 5: main pulmonary artery (MPA) and right pulmonary artery (RPA) well seen while left pulmonary artery (LPA) is absent. Fig 6: MPA,RPA seen while fibrous strand evident at origin of LPA. Fig 7: Blood flow in MPA,RPA and absent blood flow in LPA No other abnormalities in rest of the cardia.

"The rarity of the present case is that a rare congenital condition being detected and diagnosed in a geriatric age and also it being found to be isolated with no other congenital abnormalities or facio skeletal abnormalities".

Discussion :

"Pulmonary agenesis" is a rare congenital anomaly¹. Pulmonary agenesis is listed as "rare disease" by the office of rare diseases (ORD) of the national institutes of health (NIH) and also by "Ophanet" a consortium of European Partners². Congenital lung malformations represent 5-18% of all congenital anomalies. However this range may be an underestimate due to high frequency of undetected or asymptomatic lesions. The prevalence of pulmonary agenesis is reported to be between 0.0034 % to 0.0097%³

and 1 in 3,00,000⁴. There is no data suggesting any apparent sex predilection for pulmonary agenesis. The etiology for the same still remains obscure³.

Pulmonary agenesis was characterized into 3 groups by Spencer initially. But presently the classification by Boyden⁵ is followed which is as follows:

Group 1: The lung its pulmonary artery and bronchus are absent.

Group 2: Absent lung and pulmonary artery with a rudimentary bronchus coming off the Trachea.

Group 3: Hypoplastic lung with pulmonary vessels and a fully formed bronchus.

Around 60% of cases with pulmonary agenesis do have other congenital anomalies⁶. Right pulmonary agenesis is associated with a higher frequency of other congenital anomalies than left pulmonary agenesis. However the cause for the same

remains unclear. Usually cardiac, gastrointestinal, genitourinary, skeletal and facial malformations are noted with pulmonary agenesis. The common congenital anomalies associated with the left pulmonary agenesis are as follows.⁷

1. Cardiac anomalies:

- G Anomalous pulmonary venous drainage to azygos vein
- G Persistent left superior vena cava
- G PDA
- G VSD

2. Gastrointestinal anomalies:

- G Tracheoesophageal fistula
- G Hiatus hernia

3. Genitourinary anomalies:

- G No particular pattern is associated with unilateral pulmonary agenesis. But when a kidney is absent, it is invariably absent on the ipsilateral side.

4. Skeletal (ipsilateral) anomalies:

- G Thoracic vertebral anomalies and hemi vertebrae
- G Left leg longer and thicker
- G Thickening of cortex and bowing of left femur
- G Bilateral talipes equinovarus
- G Short under developed left arm
- G Absent left radius
- G Absence of left 1st phalanx and metacarpal
- G Duplication of left 1st and 2nd phalanges
- G Digital positioning of thumb on left side
- G Hypoplastic left sterno cleido mastoid
- G Microcephaly

5. Facial (Ipsilateral) anomalies:

- G Hypoplasia of left side of face
- G Left sided mandibular hypoplasia
- G Left ptosis
- G Left palpebral fissure narrower
- G Left ear smaller
- G Deformed left external ear
- G Accessory auricles on left side
- G Cleft palate

The age of presentation of pulmonary agenesis is variable and depends on the type (group 1, 2, or 3) of lesion and also on the presence of other associated congenital anomalies.

The symptoms and severity of pulmonary agenesis is variable and may vary from completely asymptomatic to those with cardio respiratory embarrassment and recurrent respiratory infections since the early life. The most frequent symptoms encountered in patients with clinical manifestations of pulmonary agenesis are dyspnoea, tachycardia and occasionally accompanied by stridor and cyanosis. The commonest thoracic physical findings are asymmetry of the chest with respiratory lag of the affected side, which is accompanied by displacement of trachea, heart, mediastinum to the affected side with ipsilateral elevation of diaphragm. The degree of displacement varies with the degree of pulmonary agenesis.

"Diagnosing a case of pulmonary agenesis in an adult" necessitates a high index of suspicion as they are usually misdiagnosed."Pulmonary agenesis" should be suspected

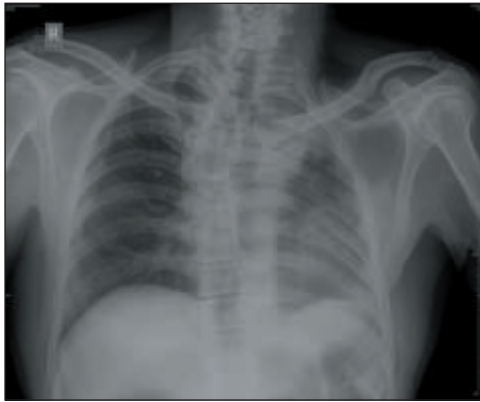


Fig 1: chest x-ray PA view

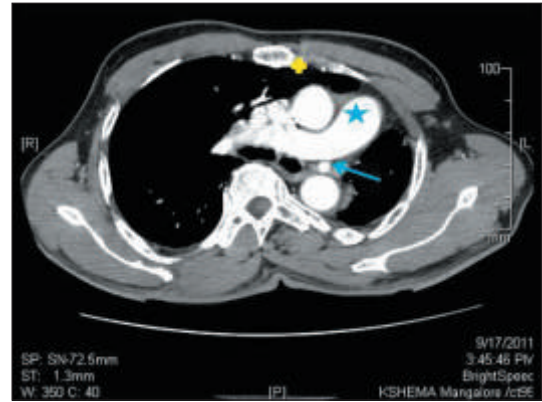


Fig 2: Axial CT thorax

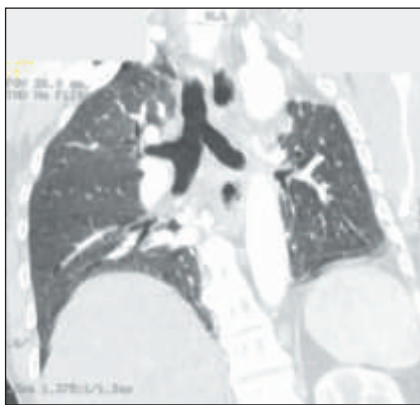


Fig 3: CT thorax bronchus view

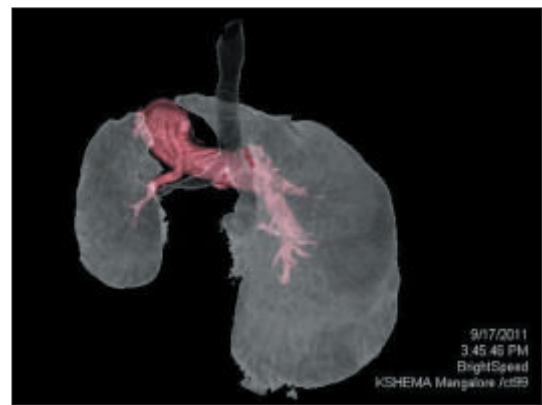


Fig 4: CT thorax VR image

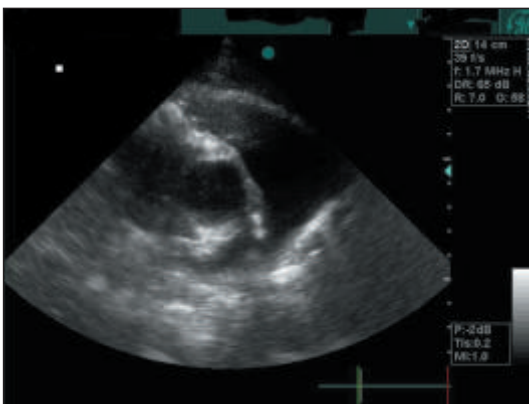


Fig 5: Echo PSx MPA RPA

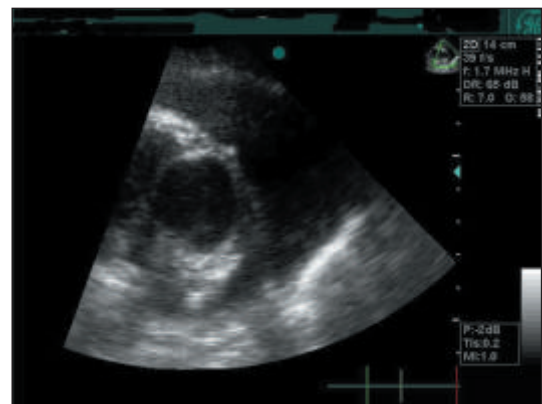


Fig 6: Echo, PSx, LPA fibrous strand

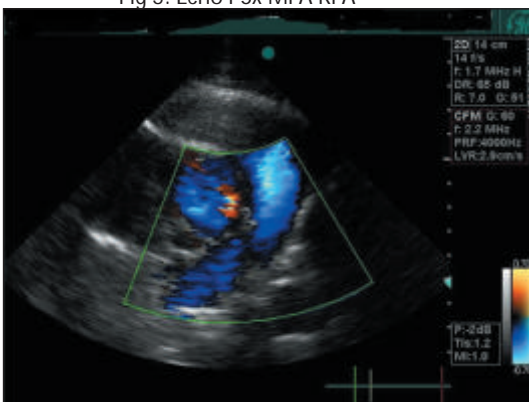

Fig 7: Echo PSX blood flow

as a possible diagnosis when the chest x-ray reveals bony symmetry, opaque hemithorax, with mediastinal shift and herniation of the contra lateral lung to the affected side. After the advent of advanced investigations like CT scan and echo cardiography, the invasive procedures like pulmonary angiography, bronchography and Bronchoscopy have been rendered redundant. The CT scan (CT thorax) clearly delineates lung parenchyma with pulmonary and bronchial tree and helps to confirm the

diagnosis of pulmonary agenesis⁸. Additionally Echocardiography helps to confirm the UPAA- Unilateral pulmonary artery agenesis and also detects presence of other associated cardiac malformations.

Treatment of pulmonary agenesis necessitates the treatment for chest infections; however no treatment is required in asymptomatic cases. Corrective surgeries for the associated congenital anomalies may be undertaken wherever feasible.

The long term prognosis is directly related to the degree of pulmonary agenesis and the presence of comorbidities. Asymptomatic cases and occasional minimally symptomatic cases raise the expectations of good prognosis despite the

advanced age. Left pulmonary agenesis has a better prognosis than right pulmonary agenesis due to the fact of lesser incidence of other associated congenital abnormalities, lesser shift of the heart and mediastinum and lesser distortion of great vessels and airway⁹.

Conclusions And Comments :

The present case- "Pulmonary agenesis with UPAA reiterates the following

1. Pulmonary agenesis is very rare and may remain

undiagnosed for many years and also frequently misdiagnosed in adult population.

2. Pulmonary agenesis with none of other congenital abnormalities (as seen in the present case) is extremely rare.
3. Diagnosing a developmental lung anomaly in a geriatric adult is a challenge for the clinician.
4. Clinicians and radiologists should always be aware of the possibility of rare congenital conditions like pulmonary agenesis even in geriatric age group and should demonstrate high index of suspicion to diagnose the same.
5. Multiple non invasive imaging modalities must be utilized to confirm the diagnosis of a rare condition like pulmonary agenesis. CT chest must be the preferred modality even before other invasive procedure like pulmonary angiography is considered.
6. Good prognosis can be expected in pulmonary agenesis with UPAA cases even despite the advanced age only if they do not suffer from recurrent respiratory infection. The best approach for these cases (as in the present case) will be close monitoring.

References :

1. Borja AR, Ransdell HT, Villa S. Congenital developmental arrest of the lung, Ann thorax Surg 1970; 10:317-26
2. Rare diseases.info.nih.gov/GARD-genetic and rare diseases information centre.
3. Fokstunen S, Schinzel A. Unilateral lobar pulmonary agenesis in sibs, J Med Genet 2000;37:557-9
4. Kadir IS, Thekudan J, congenital unilateral pulmonary artery agenesis and aspergilloma Ann.Thorac Surg 2002; 74(6):2169-2171
5. Schaffer AJ, Pulmonary agenesis and hypoplasia. In Schaffer AJ, Avery ME eds. Disease of the new born. Philadelphia:WB Saunders, 1960:124-209.
6. Wexels P: Agensis of lung. Thorax,6:171,1951
7. JP Booth, CL Berry, Unilateral pulmonary agenesis. Arch, Dis Childh, 1967,42,361.
8. Mendelson DS, Hahn P, Cohen BA, Hypoplasia of the lung -CT appearance, Mount Sinai J Med 1986; 53: 297-298.
9. Schaffer AJ, Rider AV, A note on the prognosis of pulmonary agenesis and hypoplasia according to the side affected. J Thorac Surg 1957; 33:379-82.