

Case Report

DIFFUSE XANTHOGRANULOMATOUS PYELONEPHRITIS OCCURRING IN A NON-FUNCTIONAL KIDNEY - A REPORT OF TWO CASES.

Harish S. Permi¹, Rajeev T.P.², Prajwal Ravinder³, Sajitha N.⁴ & Panna Hegde⁵¹Associate Professor, Department of Pathology, ^{2,3}Associate Professors, Department of Urology, ^{4,5}PG students in Pathology, K.S. Hegde Medical Academy of Nitte University, Deralakatte, Mangalore - 575 018, Karnataka, India.**Abstract :**

Xanthogranulomatous pyelonephritis is a rare debilitating illness resulting in focal or diffuse renal destruction. It is characterized pathologically by lipid-laden foamy macrophages which share many characteristics with true renal neoplasm in terms of its radiographic appearance and ability to involve adjacent structures or organs. It affects non-functioning kidney and is often associated with urinary tract obstruction, infection, nephrolithiasis, diabetes, and immunocompromised state. The treatment is almost universally extirpative and can pose a formidable challenge to the surgeon. We report two cases of diffuse Xanthogranulomatous pyelonephritis occurring in a non-functioning kidney of 38 year old diabetic male and 51 year old male with renal calculus.

Keywords: Xanthogranulomatous pyelonephritis, diabetic, calculus, non-functioning kidney.

Introduction :

Xanthogranulomatous pyelonephritis (XPN) is a variant of chronic pyelonephritis which is frequently associated with urinary tract obstruction or nephrolithiasis. Pre-operatively it may mimic renal tuberculosis or renal carcinoma due to its vague clinical presentation and radiological investigations.⁽¹⁾ It affects non-functioning kidney and is often associated with urinary tract obstruction, concomitant infection with *E. coli*, *Proteus mirabilis*, *Klebsiella*, *Staphylococcus aureus*, *Pseudomonas*, *Streptococcus*, anaerobic organisms; nephrolithiasis, diabetes, and immunocompromised state.

⁽²⁾ The confirmatory diagnosis of XPN is based on histopathological examination and surgery remains the treatment in almost all the cases. We report two cases of diffuse XPN occurring in a non-functional kidney, one in a 38 year male diabetic and another 51 year male with renal calculus, both underwent nephrectomy. On regular follow up both are free of signs and symptoms.

Case Reports :

Case 1) A 38 year old diabetic male presented with fever off and on since 3 months and pain in the right lumbar region since one month. He underwent right pyelo-lithotomy 4 years back and known diabetic since 2 years. Abdominal examination revealed scar and non tender mass in the right lumbar region. Laboratory investigations showed

neutrophilic leucocytosis with increase in fasting and post prandial blood sugar levels. Routine urinary evaluation showed increased number of pus cells but urine culture was negative. Serology for HIV & HBsAg was nonreactive. USG abdomen revealed enlarged right kidney with gross dilatation of pelvi-calyceal system and thinning of parenchyma. CECT showed enlarged kidney with thinned out parenchyma and multiple large loculated collection in the perirenal area. Right Nephrectomy was done and specimen sent for histopathology examination. Cut section of the kidney revealed loss of architecture with dilated calyces, thinned out parenchyma and multiple yellowish masses. (Figure 1) Microscopy showed features of chronic pyelonephritis with presence of foamy macrophages, foreign and touton body giant cells. (Figure 2) Final diagnosis of diffuse XPN was made. The postoperative period was uneventful and he is doing well on regular follow up.

Case 2) A 51 year old male presented with fever, pain and mass in the left lumbar region abdomen since 3 weeks. Abdominal examination revealed mass in the left lumbar region. Routine haematological, biochemical investigations were within normal limits. Serology for HIV & HBsAg was nonreactive. USG abdomen showed gross hydronephrosis due to PUJ obstruction with renal calculus measuring 2.5 cms on left side. DTPA renogram revealed

poorly functioning left kidney with around 15% relative uptake and mildly reduced uptake in right kidney. CECT showed gross hydronephrosis of left kidney with thinned out parenchyma, PUJ obstruction and left renal calculus. Left nephrectomy was done and sent for histopathology. Cut section of kidney and microscopic features and final diagnosis was similar to case one. On regular follow up he is free of signs and symptoms.

Discussion :

XGPN is a chronic renal infection characterised by destruction and replacement of the renal parenchyma with sheets of lipid laden macrophages, admixed acute and chronic inflammatory cells and frequent abscess formation. The peak incidence is in the sixth to seventh decade with a female predominance. (3) Symptoms are frequently nonspecific and include fever, flank pain, weight loss, malaise, anorexia, and constipation. Others include urinary symptoms like dysuria, frequent urination and hematuria. Physical examination usually reveals an ill-defined, palpable and tender flank mass. (4) Our both cases were males presented with fever, pain and ill-defined mass per abdomen. The etiological factors thought to be responsible for the pathogenesis include calculus or non calculus urinary obstruction, ineffectively treated

urosepsis, chronic renal ischemia causing localised alteration in renal metabolism, lymphatic obstruction, alteration in lipid metabolism and an altered immune response. (5) In our cases the etiological factors were renal calculus and diabetes. Two forms of XGPN have been described, a diffuse or global form (83-90%) as seen in our case, and a focal form (10-17%). More commonly it is a diffuse process involving whole kidney leading to reduced renal function. (3) XGPN has been described in three stages. The lesion is confined to kidney in stage I, extends to Gerota's space in stage II, to the perinephric space and other retroperitoneal structures in stage III. (3) Antibiotics usually do not resolve the problem and nephrectomy either partial or total remains the treatment of choice. (6) Our both cases underwent total nephrectomy and on regular follow are free of signs and symptoms.

Conclusion :

To conclude, XGPN is a rare cause of chronic pyelonephritis occurring in non-functioning kidney especially in diabetics and with renal calculus, poses a preoperative diagnostic dilemma which may mimic renal tuberculosis and tumors. Nephrectomy is the surgical treatment of choice and aid in definite histopathological diagnosis of this condition.

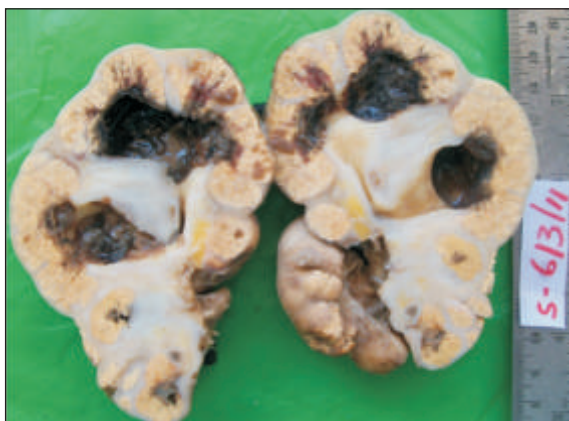

Figure 1) Gross specimen of non-functional kidney, cut section showing dilated calyces, thinned out parenchyma and multiple yellowish masses.

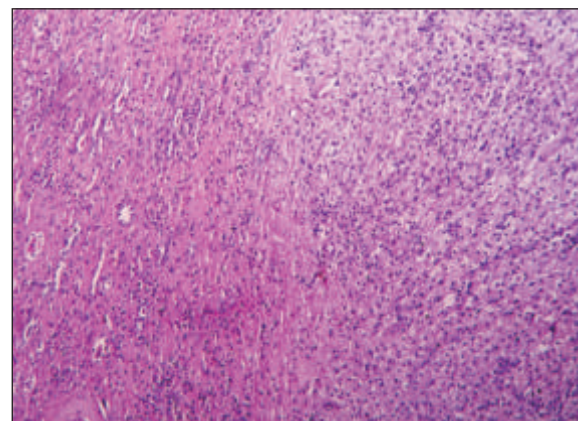


Figure 2) Microscopy showing features of chronic pyelonephritis with presence of foamy macrophages (Hematoxylin & Eosin, X 400)

References :

1. Goyal S, Gupta M, Goyal R. Xanthogranulomatous pyelonephritis: a rare entity. *North Am J Med Sci* 2011; 3: 249-50.
2. Leoni F, Kinleiner P, Revol M. Xanthogranulomatous Pyelonephritis: Review of 10 cases. *Arch Esp Urol* 2009; 62: 259-271.
3. Geethanjali Gupta, Reecha Singh, Dhananjay S Kotasthane, Vaishali D Kotasthane, Shailesh Kumar., Xanthogranulomatous Pyelonephritis in a male child with renal vein thrombus extending into the inferior vena cava: A Case Report. *BMC Paediatrics* 2010; 47:1-3.
4. Chang H, Wen Y K, Chen M L. Xanthogranulomatous Pyelonephritis: Successfully Treated with Antibiotics Only. *J Chin Med Assoc* 2008; 7:643-45.
5. Dwivedi Udai S, Goyal Neeraj, Saxena Vaibhav, Acharya Rajiba L, Trivedi Sameer, Singh Pratap B.: XGPN: Our experience with review of published reports. *ANZ Journal of Surgery* 2006; 76:1007-9.
6. Nawaz H, Khan S, Hussain I., Xanthogranulomatous Pyelonephritis due to calculi: Report of 63 cases and review of literature. *JPMA* 2005; 55:387-89.